

namely 10% and 34%, respectively in 1988, compared with 5% and 28% (if seborrhoea is included) or 18% (for eczema excluding seborrhoea).<sup>8</sup> The differences might indicate a lower threshold for referral or an actual increase in disease prevalence.

The apparent surge in impetigo and tinea in the first quarter of the twentieth century, as judged by Radcliffe Crocker's hospital data and the 1921–22 Edinburgh figures, in comparison with McCall Anderson's 1873 observations, is possibly from close contact of school children.<sup>5,6</sup> It is notable that Radcliffe Crocker's 1903 private patients had lower prevalences of infections and infestations, suggesting a social class difference.<sup>6</sup> By the mid-twentieth century, effective treatments had largely conquered such contagions irrespectively of social class.

The biggest surprise for the present-day dermatologist must be the very low rate of skin cancers of any description in the 1920s, something that was still apparent in 1950s Northern Ireland.<sup>7</sup> Accepting the evidence that skin cancer incidence increased in the last quarter of the twentieth century, an additional explanation for the low prevalence of skin cancers may be that in the 1920s presentations were delayed and, because life expectancies, as mentioned, were lower, those affected may have died from other causes before their cutaneous malignancies precipitated referral. An additional possibility, impossible to quantify, is that some or indeed most skin cancers, such as basal cell carcinoma, were referred directly to surgeons.

A major criticism of this and other clinic-based case mix studies is one of selection referral, something that can only be overcome by true population studies, of which there are very few for skin disease. A recent such study by Svensson *et al.* of 12 377 participants aged 18–74 years, drawn from Germany, Italy, the Netherlands, Portugal and Sweden, showed that, for 'active manifestation' (rather than lifetime prevalence), eczema was the most common diagnosis, at a point prevalence of 16% (most frequently, contact dermatitis), with psoriasis at 3%, acne 5%, vitiligo 1.4% and skin cancer 0.5%.<sup>9</sup>

The study by Svensson *et al.* suffers from the drawback that it excludes children and those older than 74 years, thus skewing the findings away from atopic dermatitis and skin cancers. No similar population study exists for the early part of the twentieth century to indicate whether the 1921–22 data are applicable to the populace at large. However, some inference might be drawn by looking at the ranking of diseases. In 1921–22 data, tinea, impetigo and scabies were the second, third and fourth most common diagnoses (accounting for 39% of referrals), implying significant prevalence in the public at large, whereas for Svensson *et al.* these conditions did not merit their own diagnostic categories.<sup>9</sup>

The dermatological case mix of a century ago at the founding of the British Association of Dermatologists shows both similarities and differences from that of the present day. A wide range of factors, including environmental, social, medical referral practice and demographic, seem to be involved in the observed shifting pattern of case mix.

D.J. Gawkrödger <sup>1</sup> and J.A.A. Hunter<sup>2</sup>

<sup>1</sup>Department of Infection, Inflammation and Cardiovascular Disease, University of Sheffield, Sheffield S10 2RX, UK and <sup>2</sup>Department of Dermatology, Deanery of Clinical Sciences, University of Edinburgh, Edinburgh EH16 4SB, UK

Email: djgawkrödger@yahoo.com

## References

- Office for National Statistics. How has life expectancy changed over time? Available at: <https://www.ons.gov.uk/peoplepopulationandcommunity/birthsdeathsandmarriages/lifeexpectancies/articles/howhaslifeexpectancychangedovertime/2015-09-09> (last accessed 1 September 2020).
- Chief Medical Officer. On the State of the Public Health. Annual Report of the Chief Medical Officer of the Ministry of Health for the Year 1920. London: HMSO, 1921.
- Levene A. *Cradle to Grave: Municipal Medicine in Inter-War England*. Oxford: Peter Lang, 2011.
- Gorsky M, Mohan J, Powell M. The financial health of voluntary hospitals in interwar Britain. *Econ Hist Rev* 2002; **55**:533–57.
- McCall Anderson T. *On the Treatment of Diseases of the Skin With an Analysis of Eleven Thousand Consecutive Cases*. Philadelphia: Henry C. Lea, 1873.
- Radcliffe Crocker H. *Diseases of the Skin: Their Description, Pathology, and Treatment, With Special Reference to the Skin Eruptions of Children and an Analysis of Fifteen Thousand Cases of Skin Disease*, 3rd edn. London: H.K. Lewis, 1905.
- Hall R, Burrows D. An analysis of 30,000 cases of skin disease in Northern Ireland. *Br J Dermatol* 1957; **57**:400–4.
- Harris DWS, Benton EC, Hunter JAA. The changing face of dermatology out-patient referrals in the south-east of Scotland. *Br J Dermatol* 1990; **123**:745–50.
- Svensson A, Ofenloch RF, Bruce M *et al.* Prevalence of skin disease in a population-based sample of adults from five European countries. *Br J Dermatol* 2018; **178**:1111–18.

Funding sources: none.

Conflicts of interest: The authors declare they have no conflicts of interest.

---

## Co-reactivation of the human herpesvirus alpha subfamily (herpes simplex virus-1 and varicella zoster virus) in a critically ill patient with COVID-19

DOI: 10.1111/bjd.19484

DEAR EDITOR, Coronavirus disease 2019 (COVID-19) is already well known globally.<sup>1</sup> Severe acute respiratory syndrome coronavirus 2 (SARS-CoV-2) infection causes a spectrum of severe clinical manifestations, which lead to a high rate of intensive care unit admissions and mortality. We report a first case of COVID-19 with reactivation of the human herpesvirus (HHV) alpha subfamily – herpes simplex virus (HSV)-1 and varicella zoster virus (VZV). Due to the immunosuppressive state

associated with COVID-19, infection with the HHV alpha subfamily could be potentially life-threatening.

A 73-year-old man, with respiratory symptoms and positive nucleic acid test of throat swab specimens, was diagnosed with SARS-CoV-2 infection on 2 February 2020. As the respiratory symptoms deteriorated, he was admitted to intensive care. Due to the rapid aggravation of respiratory distress, onset of septic shock, and progression of chest imaging, the application of venovenous extracorporeal membrane oxygenation for respiratory support was performed on 15 February. After comprehensive treatment and assisted ventilation, the oxygenation index and relevant indicators improved. The patient's clinical condition stabilized with downtrending SARS-CoV-2 viral load and improvement in his sepsis biomarkers.

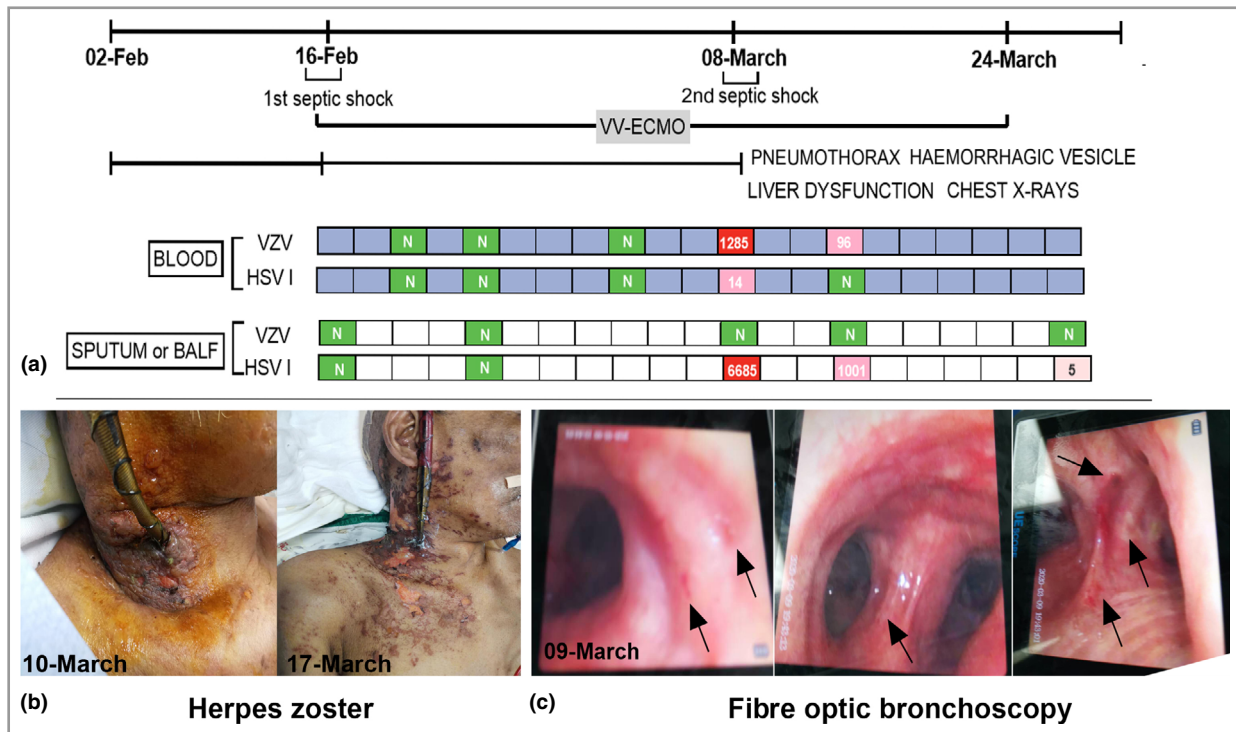
For continuous monitoring of the infection status, serial follow-up pathogen next-generation sequencing (NGS) tests were performed (Figure 1a), including tests on blood, sputum and bronchoalveolar lavage fluid (BALF). On 8 March, the patient had a second septic shock. The blood pathogen NGS report (8 March) revealed the onset of VZV and HSV-1 reactivation. Two days later, multiple clusters of haemorrhagic blisters, bullae and diffuse erosions covered the right lateral arm, shoulder and neck of the patient (Figure 1b). Meanwhile, liver function showed the second highest peak during the treatment course.

The report from BALF also showed a higher sequence number of HSV-1 on 8 March. Accordingly, his chest radiograph suddenly worsened with a left pneumothorax. In addition, we

found several small ulcers on the bronchial mucosa during fibre optic bronchoscopy, as shown in Figure 1c. After antiviral treatment (aciclovir 0.5 g intravenous drip, every 8 h), all parameters gradually improved.

HSV-1 and VZV are DNA viruses belonging to the neurotropic alpha herpesvirus subfamily.<sup>2</sup> After primary infection, they can both formulate a latent infection. However, once the interactional balance between the host immunity and the virus is broken, the following battle in the immune system might be complicated and fierce, involving multiple organs (cutaneous, liver, kidney and brain).<sup>3</sup> In our case, the onset of viraemia (VZV and HSV-1) might have triggered the second septic shock. During fibre optic bronchoscopy, we found several small ulcers on the mucosal membrane of bronchi (Figure 1c), and the reports of BAFL and blood tests illustrated the onset of VZV and HSV-1 reactivation. Meanwhile, the serial chest radiographs suddenly aggravated. Besides the manifestation in lung and skin, the second highest peak of liver dysfunction might have been related to the reactivation of the HHV alpha subfamily.

The immunological characteristics of patients with COVID-19 are variable. They show a cytokine storm syndrome and immunosuppression, especially in a subgroup of critically ill patients,<sup>4</sup> which suggests an unbalanced immune response and exhaustion of multiple cytokines; this could be one of the




**Figure 1** (a) Next-generation sequencing tests of pathogen from blood and deep sputum or bronchoalveolar lavage fluid (BALF) samples. Viraemia [varicella zoster virus (VZV) and herpes simplex virus (HSV)-1] and BALF (HSV-1) were detected on 8 March 2020 (N, not detected; red, high; pink, low), which might have resulted in aggravation of the disease course. The symptoms and laboratory indicators both improved after acyclovir treatment. (b) Clinical manifestation of herpes zoster. (c) Several small ulcers on the bronchial mucosa during the fibre optic bronchoscopy. VV-ECMO, venovenous extracorporeal membrane oxygenation.

reasons for the HSV-1 and VZV reactivation. The SARS-CoV-2 infection affects T lymphocytes, particularly CD4<sup>+</sup> T cells, CD8<sup>+</sup> T cells<sup>4</sup> and natural killer cells,<sup>5</sup> resulting in functional exhaustion and decreases in numbers. The resulting immunosuppressive state may encourage reactivation of latent viral infection, resulting in sudden worsening of symptoms in the course of recovery.

Until now, most reports of inpatients with COVID-19 have characterized the data without including screening tests for other viral infections. In this case, we identified a viraemia (HSV-1 and VZV) that resulted in an aggravated disease course. Simultaneous infection with VZV and HSV-1 has rarely been reported. The clinical presentation of co-reactivation could be skin manifestations, localized in the same or different dermatomal areas,<sup>6</sup> or, due to their different anatomical latent sites, they could be separately or simultaneously detected in isolated organs. Severe and lethal cases are prone to occur in older immunocompromised patients.<sup>7</sup>

In conclusion, co-reactivation of latent viruses could aggravate the COVID-19 disease course. Viral-related screening and detection tests should take cognizance of the following points. Firstly, despite improvements in chest imaging or decreases in SARS-CoV-2 RNA load or IgG and IgM, respiratory symptoms and chest imaging can suddenly worsen along with symptoms related to other organ system injuries (unexplainable liver or kidney injury). Thus, in addition to suspicion of secondary bacterial infection, viral infection should also be considered. Secondly, if scattered vesicles or ulcers are found during fibre optic bronchoscopy, HSV-1- and VZV-related pulmonary infection should be suspected.

R. Xu ,<sup>1</sup> Y. Zhou,<sup>2</sup> L. Cai,<sup>3</sup> L. Wang,<sup>4</sup> J. Han,<sup>1</sup> X. Yang,<sup>3</sup> J. Chen,<sup>3</sup> J. Chen,<sup>3</sup> C. Ma<sup>1</sup> and L. Shen<sup>3</sup>

<sup>1</sup>Department of Dermatology; <sup>2</sup>Department of Pulmonary and Critical Care Medicine and <sup>3</sup>Department of Critical Care Medicine, Affiliated Dongguan People's Hospital, Southern Medical University, Dongguan, China; and

<sup>4</sup>Department of Critical Care Medicine, The First Affiliated Hospital of Sun Yat-sen University, Guangzhou, China

Correspondence: Lihan Shen.

Email: shenlihan@hotmail.com

R.X. and Y.Z. contributed equally to this work.

## References

- Zhang JJ, Dong X, Cao YY et al. Clinical characteristics of 140 patients infected with SARS-CoV-2 in Wuhan, China. *Allergy* 2020; **75**:1730–41.
- Ouwendijk WJ, Laing KJ, Verjans GM, Koelle DM. T-cell immunity to human alphaherpesviruses. *Curr Opin Virol* 2013; **3**:452–60.
- Mitchell BM, Bloom DC, Cohrs RJ et al. Herpes simplex virus-1 and varicella-zoster virus latency in ganglia. *J Neurovirol* 2003; **9**:194–204.
- Chen G, Wu D, Guo W et al. Clinical and immunologic features in severe and moderate coronavirus disease 2019. *J Clin Invest* 2020; **130**:2620–9.
- Zheng M, Gao Y, Wang G et al. Functional exhaustion of antiviral lymphocytes in COVID-19 patients. *Cell Mol Immunol* 2020; **17**:533–5.
- Giehl KA, Muller-Sander E, Rottenkolber M et al. Identification and characterization of 20 immunocompetent patients with simultaneous varicella zoster and herpes simplex virus infection. *J Eur Acad Dermatol Venereol* 2008; **22**:722–8.
- Curley MJ, Hussein SA, Hassoun PM. Disseminated herpes simplex virus and varicella zoster virus coinfection in a patient taking thalidomide for relapsed multiple myeloma. *J Clin Microbiol* 2002; **40**:2302–4.

Funding sources: this project was supported by the Key Projects of Dongguan City Social Science and Technology Development Plan (2018507150011645), the National Natural Science Foundation of China (81570008) and the National Science Foundation for Young Scientists of China (81903231).

Conflicts of interest: The authors declare they have no conflicts of interest.