



Since January 2020 Elsevier has created a COVID-19 resource centre with free information in English and Mandarin on the novel coronavirus COVID-19. The COVID-19 resource centre is hosted on Elsevier Connect, the company's public news and information website.

Elsevier hereby grants permission to make all its COVID-19-related research that is available on the COVID-19 resource centre - including this research content - immediately available in PubMed Central and other publicly funded repositories, such as the WHO COVID database with rights for unrestricted research re-use and analyses in any form or by any means with acknowledgement of the original source. These permissions are granted for free by Elsevier for as long as the COVID-19 resource centre remains active.



Case Report

Case studies of SARS-CoV-2 treated with favipiravir among patients in critical or severe condition



Hidenori Takahashi^{a,*}, Yoshinobu Iwasaki^a, Takayasu Watanabe^a, Naoki Ichinose^b, Yasusei Okada^c, Akito Oiwa^d, Takehiro Kobayashi^d, Mariko Moriya^d, Toshimi Oda^b

^a Division of Pulmonary Medicine, Showa General Hospital, Kodaira, Japan

^b Department of Infectious Control, Showa General Hospital, Kodaira, Japan

^c Department of Critical Care and Emergency Medicine, Showa General Hospital, Kodaira, Japan

^d Emergency and Critical Care Medicine, Tokyo Medical University Hachioji Medical Center, Hachioji, Japan

ARTICLE INFO

Article history:

Received 1 June 2020

Received in revised form 8 August 2020

Accepted 16 August 2020

Keywords:

COVID-19

SARS-CoV-2

Viral pneumonia

Favipiravir

Acute respiratory distress syndrome

ABSTRACT

• The severe acute respiratory syndrome coronavirus 2 (SARS-CoV-2) outbreak is spreading globally. However, clinically effective antiviral treatments are not established. Favipiravir may prevent pneumonia and acute respiratory distress syndrome aggravation. We describe SARS-CoV-2-positive patients, two of whom were in a critical condition and one of whom was in a severe condition, who were administered favipiravir for their deteriorating conditions and were cured.

© 2020 The Authors. Published by Elsevier Ltd on behalf of International Society for Infectious Diseases. This is an open access article under the CC BY-NC-ND license (<http://creativecommons.org/licenses/by-nc-nd/4.0/>).

Introduction

Severe acute respiratory syndrome coronavirus 2 (SARS-CoV-2) quickly became a worldwide health emergency. The resulting coronavirus disease (COVID-19) can rapidly progress to dyspnea and hypoxemia, develop into acute respiratory distress syndrome (ARDS), and be fatal. As of May 11, 2020, the World Health Organization reported over 4,500,000 confirmed cases and over 300,000 deaths, and incidence and mortality continue to rise globally (World Health Organization, 2020).

Effective antiviral treatments for COVID-19 are not sufficiently established, and knowledge regarding antiviral treatment for SARS-CoV-2 is limited. Favipiravir, developed to treat influenza by inhibiting the RNA polymerase of RNA viruses, may be effective against SARS-CoV-2 (Furuta et al., 2013; Shiraki and Daikoku, 2020). For example, a clinical trial of favipiravir reported reduced pyrexia and cough in all patients and an improved recovery rate in patients with moderate severity; however, the recovery rate among patients in severe or critical condition remained unchanged (Chen et al., 2020a).

In these case reports, we present our experience with three COVID-19 patients; two in a critical condition and one in a severe condition. All three patients needed high dose oxygen therapy or extracorporeal membrane oxygenation (ECMO). After treatment with favipiravir, they recovered from SARS-CoV-2 pneumonia, and we could taper oxygenation. This study was approved by the Ethics Review Committee of our hospital (protocol REC-222), and all patients provided their written informed consent for the publication of de-identified medical histories.

Patient 1

A 64-year-old man with a smoking history of 42-pack years and a mild fever and fatigue since late March 2020 (day 1: the first day symptoms begin) presented to our hospital in early April (day 10) because of worsening dyspnea. He had no significant travel history or contact with COVID-19 patients. Physical examination revealed a fever of 37.8 °C with an oxygen saturation of 93% under an 8 L/min reservoir mask. Computed tomography (CT) detected emphysema and showed bilateral diffuse multiple ground glass opacities (Figure 1a).

We performed a nasopharyngeal swab test for SARS-CoV-2 using a reverse transcriptase-polymerase chain reaction (RT-PCR) assay and promptly admitted the patient to an isolated

* Corresponding author at: Department of Pulmonary Medicine, Showa General Hospital, Kodaira, Japan.

E-mail address: hidenori.takahashi@showa-hp.jp (H. Takahashi).

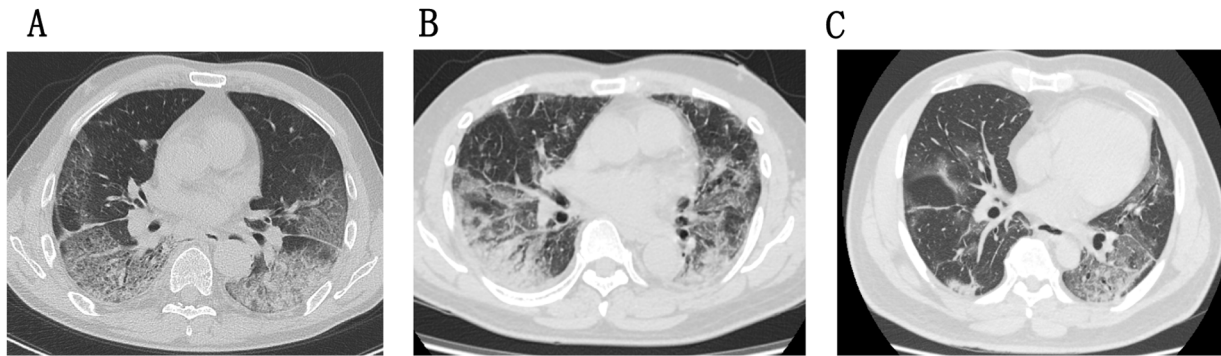


Figure 1. Chest computed tomography (CT) scans for three patients.

(A) Patient 1: CT scan detected bilateral subpleural reticular shadows and emphysema.

(B) Patient 2: CT scan showed bilateral diffuse ground glass lesions with bronchiectasis.

(C) Patient 3: CT scan revealed bilateral multiple patchy ground glass opacities with bronchiectasis.

Table 1

Dynamics of the patients' fever and respiratory condition during the administration of favipiravir.

Case	Day after onset	11	12	13	14	15	16	17	18	19	20	21	22	23	24
1	Oxygen administration	14 L/min	MV	MV	V-V	V-V	V-V	V-V	V-V	V-V	V-V	MV	MV	MV	5 L/min
	SpO ₂ (%)	88	97	91	98	98	95	97	95	99	95	94	96	96	93
	Body temperature (°C)	37.6	38.5	39.0	36.5	36.1	36.7	36.5	36.1	36.8	36.9	37.0	37.5	36.6	37.1
2	Oxygen administration	6 L/min	8 L/min	5 L/min	6 L/min	5 L/min	5 L/min	4 L/min	2 L/min	3 L/min	1 L/min	1 L/min	1 L/min	1 L/min	1 L/min
	SpO ₂ (%)	97	96	96	99	95	98	95	91	95	95	95	94	95	94
	Body temperature (°C)	37.6	37.7	38.1	37.3	38.0	37.0	36.8	36.6	36.8	36.3	36.2	36.4	36.7	36.5
3	Oxygen administration	6 L/min	NHF	NHF	NHF	NHF	NHF	NHF	NHF	NHF	NHF	NHF	NHF	NHF	4 L/min
	SpO ₂ (%)	97	94	95	94	96	97	95	96	94	97	95	98	99	99
	Body temperature (°C)	37.2	38.3	38.2	36.6	36.0	36.6	36.8	36.5	37.3	36.0	37.1	36.0	37.1	37.0

MV: mechanical ventilation; SpO₂: oxygen saturation; V-V ECMO: veno-venous extracorporeal membrane oxygenation; NHF: nasal high flow.

negative pressure room. The RT-PCR test returned positive the next day. Thereafter, the patient was started on favipiravir orally (1800 mg twice daily [day 1], followed by 800 mg twice daily [days 2–14]).

Within 12 h after admission, his respiratory condition worsened, and his oxygen saturation decreased to 90% under a 14 L/min reservoir mask. Approximately 24 h after admission, the patient's oxygen saturation declined to 88% (oxygen concentration 100%, 50 L/min via nasal high flow), and mechanical ventilation was performed by orotracheal intubation. The patient underwent intensive care unit (ICU) monitoring. Favipiravir was continued for 14 days via a nasogastric tube (Table 1).

After intubation, the patient's blood oxygen saturation was maintained at an oxygenation index of approximately 100 mmHg (ventilator conditions: Pressure Support 10 cmH₂O, Positive End Expiratory Pressure 15 cmH₂O, FiO₂ 70%). Veno-venous ECMO (VV-ECMO) rescue therapy was performed from days 13–20, applying a rest lung strategy and treatment with steroids, azithromycin, sivelestat, and nafamostat. After evacuation from ECMO, tapering ventilation continued until day 23.

His RT-PCR test returned negative on day 27. A chest radiograph showed consolidation, with reticular shadows in both outermost lung fields that had progressed and thickened until day 35 and then started to regress. Oxygen administration was tapered and was subsequently stopped on day 51. He is continuing rehabilitation.

Patient 2

A 60-year-old man with no history of smoking, recent travel, or contact with COVID-19 patients, complaining of a 38 °C fever since early March (day 1) and being subsequently tested positive for COVID-19 via RT-PCR on day 8, was admitted to our hospital in mid-March 2020 (day 11).

On admission, physical examination revealed a fever of 37.6 °C with an oxygen saturation of 97% under a 6 L/min reservoir mask.

CT showed bilateral diffuse ground glass opacities with bronchiectasis, suggesting ARDS (Figure 1b). Although he was promptly treated with favipiravir, his respiratory condition worsened, and he needed a maximum oxygen intake of 8 L/min via reservoir mask for over 36 h. However, within 5 days, his symptoms were alleviated, his respiratory condition improved, and oxygen administration was tapered (Table 1). A chest radiograph showed consolidation with a reticular shadow that had progressed for a week and then started to regress.

He did not need treatments such as steroids or antiviral drugs, and he was free of oxygen administration on day 24. His RT-PCR test returned negative on day 34, and he was discharged on day 38.

Patient 3

A 51-year-old man with no history of smoking, recent travel, or contact with COVID-19 patients, who had persistent fever and

dyspnea since early April 2020 (day 1) presented to our hospital in mid-April (day 11).

On admission, physical examination revealed fever of 37.2 °C with an oxygen saturation of 97% under a 6 L/min reservoir mask. CT showed bilateral multiple patchy ground glass opacities with bronchiectasis, suggesting ARDS (Figure 1c).

We tested for COVID-19 via RT-PCR, and the patient was promptly admitted to an isolated negative pressure room. Within 6 h, his respiratory condition worsened, and he needed a maximum oxygen intake of 100% via 40 L/min nasal high flow. He underwent ICU monitoring, and treatment with favipiravir was initiated; treatments with steroids (7 days) and nafamostat (14 days) were started on day 12.

Within 3 days, his symptoms were alleviated, his respiratory condition improved, and oxygen administration was tapered (Table 1). A chest radiograph showed consolidation, with reticular shadows in the left mid and right lower lung fields that had progressed until day 14 and then started to regress, but remained unchanged after day 31. His RT-PCR test returned negative on day 23. He did not require oxygen administration from day 33 and was discharged on day 36.

Discussion

In these reports, we present our experience treating COVID-19 patients with favipiravir. Two patients in a critical condition needed 100% oxygen via nasal high flow or ECMO rescue therapy, and one patient in a severe condition needed a maximum oxygen intake of 8 L/min. All patients began favipiravir administration on day 11 after symptom onset for deteriorating conditions.

SARS-CoV-2 proliferates over 10 days after symptom onset (Zou et al., 2020), and cytokine storms or ARDS typically begin 8–14 days after symptom onset (Huang et al., 2020). SARS-CoV-2 viremia may induce these conditions (Chen et al., 2020b). ARDS leads to a higher mortality risk, with a mortality rate of approximately 74% (Yang et al., 2020). Favipiravir potentially inhibits SARS-CoV-2 proliferation (Furuta et al., 2013; Shiraki and Daikoku, 2020), which may lead to reduced cytokine production and protect the lung from fibrosis in subsequent hypoxemia (Yamamura et al., 2020). A recent study of favipiravir among non-severe patients showed an earlier time of viral clearance (medians of 4 vs. 11 days) (Cai et al., 2020); however, our patients had viral clearance at 18, 27, and 13 days, respectively, possibly reflecting higher viral replication amidst worsening symptoms (Liu et al., 2020). Additionally, the study showed chest imaging improvement in patients being treated with favipiravir, which was also observed among our patients. Favipiravir can work effectively even in severe cases with high viral load (Takahashi et al., 2003). The predominant mechanisms by which favipiravir inhibits SARS-CoV-2 virus replication are its considerable inhibitory activity against RNA synthesis and lethal mutagenesis (Shannon et al., 2020).

Our report of three COVID-19 cases suggests that favipiravir may slow/stop pneumonia progression and cytokine increase, improve respiratory function, and produce immediate effects even in severe or critical condition patients. Favipiravir clinical trials generally exclude patients in critical or severe conditions (Cai et al., 2020; Chen et al., 2020a; NIPH Clinical Trials, 2020; Ivashchenko

et al., 2020). However, our observations suggest that favipiravir can be considered for treating severe or critical patients.

Funding

None declared.

Conflicts of interest

None declared.

Ethical approval

All study participants provided informed consent, and the study design was approved by the appropriate ethics review board. This case study was ethically approved by the Human Research Ethics Committee of our hospital (Approval number: REC-222.)

References

- Cai Q, Yang M, Liu D, Chen J, Shu D, Xia J, et al. Experimental treatment with favipiravir for COVID-19: an open-label control study. *Engineering* 2020; doi: <http://dx.doi.org/10.1016/j.eng.2020.03.007>.
- Chen C, Zhang Y, Huang J, Yin P, Cheng Z, Wu J, et al. Favipiravir versus arbidol for COVID-19: a randomized clinical trial. *medRxiv* 2020a; doi: <http://dx.doi.org/10.1101/2020.03.17/20037432>.
- Chen X, Zhao B, Qu Y, Chen T, Xiong J, Feng Y, et al. Detectable serum SARS-CoV-2 viral load (RNAemia) is closely correlated with drastically elevated interleukin 6 (IL-6) level in critically ill COVID-19 patients. *Clin Infect Dis* 2020b; doi: <http://dx.doi.org/10.1093/cid/ciaa449>.
- Furuta Y, Gowen BB, Takahashi K, et al. Favipiravir (T-705), a novel viral RNA polymerase inhibitor. *Antiviral Res* 2013;100:446–54, doi: <http://dx.doi.org/10.1016/j.antiviral.2013.09.015>.
- Huang C, Wang Ym, Li X, Ren L, Zhao J, Hu Y, et al. Clinical features of patients infected with 2019 novel coronavirus in Wuhan, China. *Lancet* 2020;395:497–506, doi: [http://dx.doi.org/10.1016/S0140-6736\(20\)30183-5](http://dx.doi.org/10.1016/S0140-6736(20)30183-5).
- Ivashchenko Andrey A, Dmitriev Kirill A, Vostokova Natalia V, Azarova Valeria N, Blinow Andrew A, Egorova Alina N. AVIFAVIR for Treatment of Patients with Moderate COVID-19: Interim Results of a Phase II/III Multicenter Randomized Clinical Trial. 2020. <https://www.medrxiv.org/content/10.1101/2020.07.26.20154724v2>.
- Liu Y, Yan LM, Wan L, Xiang TX, Le A, Liu JM, et al. Viral dynamics in mild and severe cases of COVID-19. *Lancet Infect Dis* 2020;20:656–7, doi: [http://dx.doi.org/10.1016/S1473-3099\(20\)30232-2](http://dx.doi.org/10.1016/S1473-3099(20)30232-2).
- NIPH Clinical Trials. Multicenter, Adaptive, Randomized, Placebo-Controlled, Comparative Study to Evaluate the Efficacy and Safety of Favipiravir in Patients with COVID-19 Non-Severe Pneumonia [JapicCTI-205238]. 2020. <https://www.clinicaltrials.jp/cti-user/trial/ShowDirect.jsp?japicid=JapicCTI-205238>.
- Shannon A, Selisko B, Le NTT, Huchting J, Touret F, Piorkowski G, et al. Favipiravir strikes the SARS-CoV-2 at its Achilles heel, the RNA polymerase. *bioRxiv* 2020; doi: <http://dx.doi.org/10.1101/2020.05.15.098731>.
- Shiraki K, Daikoku T. Favipiravir, an anti-influenza drug against life-threatening RNA virus infections. *Pharmacol Ther* 2020;209:107512, doi: <http://dx.doi.org/10.1016/j.pharmthera.2020.107512>.
- Takahashi K, Furuta Y, Fukuda T, et al. In vitro and in vivo activities of T-705 and oseltamivir against influenza virus. *Antivir Chem Chemother* 2003;14:235–41, doi: <http://dx.doi.org/10.1177/095632020301400502>.
- World Health Organization. Coronavirus Disease (COVID-19) Situation Report 118. 2020. https://www.who.int/docs/default-source/coronavirus/situation-reports/20200517-covid-19-sitrep-118.pdf?sfvrsn=21c0d4fe_10.
- Yamamura H, Matsuura H, Nakagawa J, et al. Effect of favipiravir and an anti-inflammatory strategy for COVID-19. *Crit Care* 2020;24:413, doi: <http://dx.doi.org/10.1186/s13054-020-03137-5>.
- Yang X, Yuan Y, Xu J, Shu H, Xia J, Liu H, et al. Clinical course and outcomes of critically ill patients with SARS-CoV-2 pneumonia in Wuhan, China: a single-centered, retrospective, observational study. *Lancet Respir Med* 2020;8:475–81, doi: [http://dx.doi.org/10.1016/S2213-2600\(20\)30079-5](http://dx.doi.org/10.1016/S2213-2600(20)30079-5).
- Zou L, Ruan F, Huang M, Liang L, Huang H, Hong Z, et al. SARS-CoV2 viral load in upper respiratory specimens of infected patients. *N Engl J Med* 2020;382; doi: <http://dx.doi.org/10.1056/NEJMc200173>.