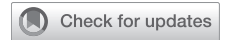



Since January 2020 Elsevier has created a COVID-19 resource centre with free information in English and Mandarin on the novel coronavirus COVID-19. The COVID-19 resource centre is hosted on Elsevier Connect, the company's public news and information website.

Elsevier hereby grants permission to make all its COVID-19-related research that is available on the COVID-19 resource centre - including this research content - immediately available in PubMed Central and other publicly funded repositories, such as the WHO COVID database with rights for unrestricted research re-use and analyses in any form or by any means with acknowledgement of the original source. These permissions are granted for free by Elsevier for as long as the COVID-19 resource centre remains active.

Lung Ultrasound for Patients With Coronavirus Disease 2019 Pulmonary Disease



Scott J. Millington, MD; Seth Koenig, MD; Paul Mayo, MD; and Giovanni Volpicelli, MD

Given the general utility of lung ultrasound for the evaluation of respiratory failure in acutely ill patients, it is logical to consider its specific advantages in coronavirus disease 2019-related pulmonary disease. The authors, representing the extensive experience of the North American and European coronavirus disease 2019 epicenters, present an ultrasound scanning protocol and report on the common associated ultrasound findings. CHEST 2021; 159(1):205-211

KEY WORDS: acute lung injury; critical care; lung ultrasound

An obese 62-year-old man with hypertension and type 2 diabetes presents to a New York City hospital with a 7-day history of progressive dyspnea and nonproductive cough. On presentation, he is hypoxemic (oxygen saturation of 82% on room air) and febrile (38.9°C), with a normal BP reading and a heart rate of 115 beats/min. Results of his laboratory tests, including coronavirus disease 2019 (COVID-19) testing, are pending.

Utility of Lung Ultrasound in COVID-19 Infection

It is useful for purposes of comparison to summarize the changes expected on chest CT scan and lung ultrasound (LUS). Findings from three recent coronavirus outbreaks (severe acute respiratory syndrome,¹ Middle East respiratory syndrome-related,² and COVID-19³) are similar; each is associated with ground-glass opacities (GGO) with or without consolidation, a predilection for the lower

lobes, typical peripheral/subpleural locations of GGO lesions, multifocal and bilateral lung involvement, and the absence of large pleural effusions. One large study³ reported the following specific patterns in COVID-19 disease: presence of GGO and consolidation (41% of 121 patients), presence of GGO alone (34%), presence of consolidation alone (2%), and absence of both GGO and consolidation (22%). The disease was bilateral or multifocal in most cases and favored the lower lobes.

In addition to its diagnostic utility (discussed later in detail), LUS has a potential role in monitoring patients for signs of improvement or deterioration, although the specific details remain unclear at present. Other parts of the point-of-care ultrasound toolkit, such as cardiac or vascular ultrasound, likely also have an important role to play, especially in severely ill patients in whom diagnostic uncertainty exists. Limitations of LUS generally can be grouped into operator factors (given its operator-dependent nature)

ABBREVIATIONS: COVID-19 = coronavirus disease 2019; CXR = chest radiograph; GGO = ground-glass opacities; LUS = lung ultrasound

AFFILIATIONS: From the University of Ottawa/The Ottawa Hospital (Dr Millington), Ottawa, ON, Canada; Montefiore Medical Center/Albert Einstein College of Medicine (Dr Koenig), New York, NY; Long Island Jewish Medical Center (Dr Mayo), New York, NY; and the San Luigi Gonzaga University Hospital (Dr Volpicelli), Torino, Italy.

CORRESPONDENCE TO: Scott J. Millington, MD, Intensive Care Unit, The Ottawa Hospital, Box 207, 501 Smyth Rd, Ottawa, ON, Canada K1H 8L6; e-mail: smillington@toh.ca

Copyright © 2020 American College of Chest Physicians. Published by Elsevier Inc. All rights reserved.

DOI: <https://doi.org/10.1016/j.chest.2020.08.2054>

and patient factors (with obesity and immobility being particularly relevant).

Scanning Protocol

There are differing opinions within the ultrasound community with respect to specific scanning protocols. Clinicians who are less familiar with LUS can refer to two related articles published in this issue of *CHEST*: a hands-on guide to performing basic LUS⁴ and a review of the utility of general LUS in acutely ill patients.⁵ Most providers will have access to a lower frequency transducer, either phased-array (“cardiac”) or convex/curvilinear (“abdominal”). Either can be used effectively, depending mostly on user preference.

Depending on the clinical context, some providers favor a simple three-point-per-hemithorax sequence, essentially copying the seminal BLUE protocol.⁶ Others prefer a more comprehensive scanning protocol such as that described in the 2012 international evidence-based recommendations for point-of-care LUS.⁷ Specifically for patients with suspected COVID-19, it is appropriate to focus attention on the posterior and dependent lung areas, as the disease tends to manifest itself in these areas,³ which are not well covered by many traditional protocols. Although other similar protocols exist,⁸ the following scanning sequence is recommended:

(1) At the second intercostal space in the mid-clavicular line, the operator examines the anterior pleural line for lung sliding. Some providers also use the high-frequency linear transducer here to examine pleural

line morphology in more detail, although others use the single, lower frequency transducer for the entire examination.

- (2) Using the lower frequency transducer for the remainder of the examination, the operator examines the intercostal spaces of the anterior area (zone 1) (Fig 1A). Steps 2 to 5 focus on the identification of common LUS findings, including A-lines, B-lines, pleural effusions, and consolidation.
- (3) The operator examines the intercostal spaces of the upper lateral area (zone 2) (Fig 1B).
- (4) The operator examines the costophrenic angle for pleural effusion or dependent areas of consolidation above the diaphragm.
- (5) The patient is placed in the lateral decubitus to scan the posterior thorax. The operator examines the area between the scapula and the spine (zone 3) (Fig 1C) and the basal area below the inferior margin of the scapula (zone 4).
- (6) Additional scans are performed as needed to further characterize focal areas of abnormality.

Given the heterogeneous nature of this disease, a systematic examination remains paramount. As many intercostal spaces as possible should be scanned, and each point should be interrogated for a full respiratory cycle.

LUS Findings in COVID-19 Infection

The typical LUS findings reported in COVID-19-infected patients include⁹ (Fig 2):

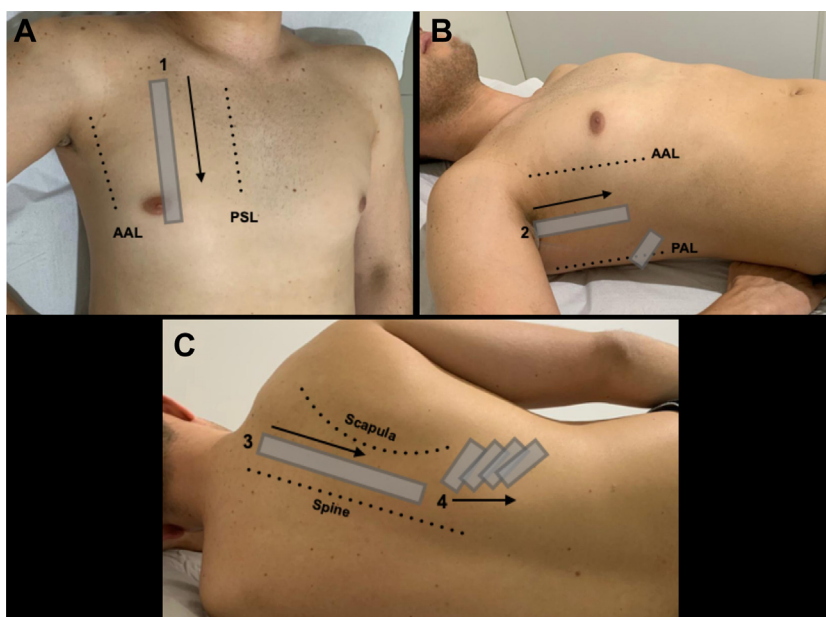


Figure 1 – Proposed scanning protocol, placing extra emphasis on the posterior lung regions given the tendency of coronavirus disease 2019 to manifest in these areas. A, Zone 1, the intercostal spaces in the mid-clavicular line. B, Zone 2, the intercostal spaces in the mid-axillary line, plus the area just above the diaphragm in the posterior axillary line. C, Zone 3 (the intercostal spaces between the spine and scapula) and Zone 4 (the area beneath the scapula). AAL = anterior axillary line; PAL = posterior axillary line; PSL = parasternal line.

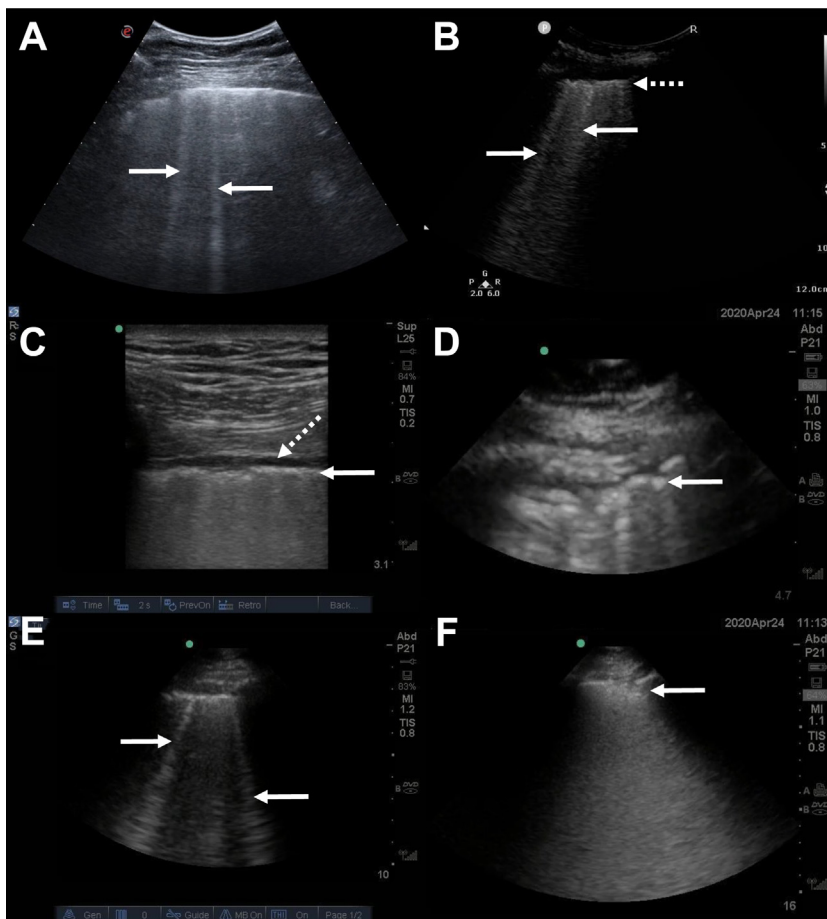


Figure 2 – A-F, Typical lung ultrasound findings in coronavirus disease 2019. A, Multiple B-lines (arrows), seen using a convex transducer oriented parallel to the ribs. B, Multiple B-lines (arrows) and a thickened irregular pleural line (dotted arrow), seen using a convex transducer oriented perpendicular to the ribs. C, Thickened irregular pleura (arrow) and an associated small pleural effusion (dotted arrow), seen using a linear transducer oriented perpendicular to the ribs. D, Thickened irregular pleura (arrow), seen using a phased-array transducer oriented perpendicular to the ribs. E, Multiple B-lines (arrows), seen using a phased-array transducer oriented perpendicular to the ribs. F, A subpleural consolidation (arrow), seen using a phased-array transducer oriented perpendicular to the ribs.

- B-lines, usually multifocal, separated, and confluent, accompanied by segments of irregular pleural line alternating with small peripheral consolidations. B-lines are visualized in various intensities and distributions depending on the severity of illness
- Bilateral disease affecting multiple lobes
- Areas of patchy B-lines alternating with regular A-lines zones (spared areas or “skip” lesions)
- Small peripheral consolidations present in any lung zone but more common at the lung bases
- Less commonly larger consolidations with or without dynamic air bronchograms; large areas of consolidated lung should prompt consideration of a superimposed bacterial pneumonia
- Absent or small pleural effusions

All of these findings are nonspecific, and therefore LUS cannot be used by itself to establish a definitive diagnosis of COVID-19 infection; the same problem applies, of course, to chest radiograph and chest CT findings.¹⁰ A patchy B-line pattern is typical for patients with ARDS, for example, and the subpleural consolidations can be found with other viral infections. As such, the

integration of typical LUS findings with patient history, physical examination, laboratory results, and prevalence of the disease during the pandemic phases is required. A correlation between LUS findings and pathologic severity has been proposed,¹¹ which also highlights the fact that milder cases may present more of a diagnostic challenge.

The authors have noted an unusual LUS finding that may be more specific to COVID-19: a thick hyperechoic band of confluent B-lines arising from a portion of the pleural line that appears relatively spared (comparatively smooth).^{12,13} This finding is best appreciated by using the convex transducer with the scanning plane oriented along the long-axis of an intercostal space (parallel to the ribs), such that a long uninterrupted length of pleura is visualized; it is worth noting that this is different from the transducer orientation preferred by many providers. Some clinicians refer to this finding using the descriptive but nonstandard term “light beam.” These areas of hyperechoic confluent B-lines stand out as they often alternate with spared areas of relatively normal lung, seen on ultrasound as A-lines and representing spared

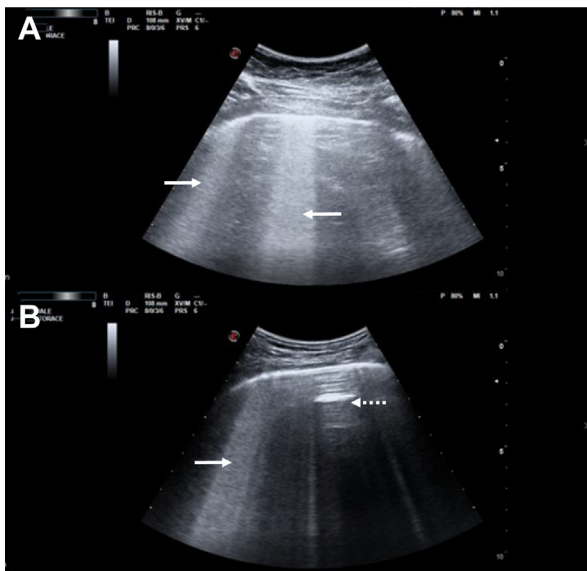


Figure 3 – A-B, Two examples of the “light beam” artifact, both generated using the convex ultrasound transducer oriented parallel to the ribs. Areas of thick confluent B-lines can be seen (arrows), emanating from a pleural line that is relatively spared from inflammation, along with interspaced regions of normally aerated lungs where A-lines are seen (spared areas or “skip” lesions; dotted arrows).

areas. Light beams commonly move back-and-forth in tune with the respiratory cycle (Fig 3, Videos 1, 2, and 3). We speculate that this sign tends to occur in early disease because of the patchy nature of the GGO lesions seen on chest CT imaging, which are concentrated at the lung periphery and subject to respiratory movement. They may evolve, as the disease progresses, toward coalescent B-lines associated with pleural line irregularities and small subpleural consolidations. This evolution may correspond to progressive thickening of the interlobular septa (crazy paving as seen on chest CT imaging) and alveolar filling (consolidation as seen on CT imaging).

LUS Disease Patterns

The various combinations of signs typically observed in patients with COVID-19 disease allow LUS findings to be clustered into patterns. Each may help differentiate the probability of having the disease and can be classified as follows:

(1) High probability LUS pattern

The most typical LUS pattern, as described earlier, consists of bilateral and multifocal clusters of B-lines alternating with normal lung (spared areas or “skip” lesions), with or without small peripheral consolidations. An associated light beam pattern may

be present. Increased density of B-lines in posterior and inferior regions is typical.

(2) Intermediate probability LUS pattern

A less typical pattern includes unilateral clusters of B-lines or focal multiple B-lines with or without peripheral consolidations.

(3) Alternate LUS pattern

An isolated large lobar consolidation with air bronchograms, a large pleural effusion, or diffuse and very symmetrical B-lines with a gravity-related distribution are less common in COVID-19 lung disease (being more consistent with bacterial pneumonia, pleural effusion, and cardiogenic pulmonary edema, respectively). These findings alert the clinician to search for an alternate diagnosis.

(4) Low probability LUS pattern

A generalized bilateral A-line pattern with lung sliding indicates normal lung aeration. Significant dyspnea presenting with this ultrasound pattern requires consideration of an alternate diagnosis other than COVID-19. This pattern is also seen in pulmonary embolism, potentially important due to the association between COVID-19 infection and thromboembolic disease.¹⁴ In patients who are well, a normal LUS pattern does not exclude infection with COVID-19 without pulmonary involvement.

Clinical COVID-19 Patient Phenotypes

Correlation of the LUS pattern with clinical information is crucial to increase diagnostic confidence while test results are pending, and the patient presentations can be divided as follows: (1) mild phenotype, patients with relatively mild nonrespiratory symptoms and no signs of respiratory failure; (2) severe phenotype, patients with significant dyspnea at rest or on exertion, or signs of respiratory failure; and (3) mixed phenotype, patients with dyspnea or respiratory failure but with preexisting significant chronic pulmonary or cardiac disease that may confound their presentation.

Another related variable to consider is timing of symptom onset. Patients with more severe clinical or LUS findings earlier in their disease course may be at higher risk of progression to respiratory failure.

Triage

Triageing patients with suspected COVID-19 is challenging due to the need for rapid decision-making in the absence of test results and in the presence of limited

resources. Patients must be isolated and personal protective equipment donned where uncertainty exists, and decisions regarding admission to the hospital and potential treatments must be made quickly and prior to test results being available. These decisions are particularly challenging in a scenario in which patients suspected of COVID-19 flock to the ED during the height of an outbreak.

The interface between the patient phenotype (severity of clinical presentation) and the ultrasound pattern

may be useful and will be immediately available assuming the presence of providers proficient in LUS. Immediate use of LUS for triage decisions may result in a lower risk of dissemination in crowded EDs compared with the routine use of chest radiograph or CT scan. Combining clinical phenotypes and LUS patterns can guide triage (Fig 4), as follows:

For the mild phenotype (patients with mild symptoms and no signs of respiratory failure):

	Mild Phenotype Mild nonrespiratory symptoms and no signs of respiratory failure	Severe Phenotype Significant dyspnea or signs of respiratory failure	Mixed Phenotype Dyspnea or respiratory failure, but with confounding pre-existing lung or heart disease
High Probability LUS Pattern Typical LUS pattern: bilateral and multifocal clusters of B-lines alternating with normal lung; often an irregular pleural line and small peripheral consolidations	High probability of COVID-19 pneumonia. Testing should be performed; here negative results are at high risk of representing a false-negative finding	High probability of COVID-19 pneumonia. Testing should be performed; here negative results are at high risk of representing a false-negative finding	Likely related to COVID-19 but underlying cardiopulmonary disease may confound the presentation
Intermediate Probability LUS Pattern Less typical patterns including unilateral clusters of B-lines or focal multiple B-lines, with or without peripheral consolidations	Uncertain; may define a group of patients where isolation and close monitoring, whether at home or in the hospital, should be considered while awaiting test results	Presents a mismatch between LUS finding and patient signs and symptoms, and may need further investigation by CT scan and confirmation with testing	Uncertain; requires integration of LUS findings with current clinical scenario in the context of the patient's comorbid medical conditions; CT scan may be helpful
Alternate LUS Pattern Patterns more consistent with other diagnoses such as an isolated large lobar consolidation with air bronchograms, a large pleural effusion, or diffuse and very symmetrical B-lines	Suggests an alternative diagnosis to explain the patient's symptoms. These patients should be isolated until test results are available while management of the alternate diagnosis is undertaken	Suggests an alternative diagnosis to explain the patient's symptoms. These patients should be isolated until test results are available, admitted to hospital, and treated for their alternate diagnosis	Uncertain; requires integration of LUS findings with current clinical scenario in the context of the patient's comorbid medical conditions, CT scan may be helpful
Low Probability LUS Pattern A normal or near-normal exam; generalized bilateral A-lines with lung sliding	Rules out severe COVID-19-related lung disease but not the possibility of infection with the virus itself; these patients can be considered for discharge to home quarantine	Suggests an alternative diagnosis such as pulmonary embolism, asthma, or COPD exacerbation; these patients should be isolated until test results are available	Unlikely to be found in patients with significant preexisting pulmonary or cardiac disease

Figure 4 – Combining the clinical phenotype with the LUS pattern to aid in patient triage. COVID-19 = coronavirus disease 2019; LUS = lung ultrasound.

- A high probability LUS pattern indicates a high probability of COVID-19 pneumonia. Testing should be performed, but a negative result would be at high risk of representing a false-negative finding.
- An intermediate probability LUS pattern may define a group of patients in which close monitoring, whether at home or in the hospital, should be considered.
- An alternate LUS pattern, with signs such as a large consolidation or pleural effusion, suggests an alternate diagnosis to explain the patient's symptoms. These patients should be isolated until test results are available while management of the alternate diagnosis is undertaken and a lower threshold for admission to hospital applied.
- A normal LUS pattern rules out severe COVID-19-related lung disease but not the possibility of infection with the virus itself; these patients can be considered for discharge to home quarantine and monitoring while test results are pending, assuming they are otherwise well.

For the severe phenotype (patients with signs of significant dyspnea or respiratory failure, all of whom should be considered for hospital admission):

- A high probability LUS pattern establishes a high probability of COVID-19 pneumonia. Testing should be performed, but here again a negative result may well represent a false-negative finding.
- An intermediate probability LUS pattern presents a mismatch between LUS finding and patient signs and symptoms, and may need further investigation by using CT scanning and confirmation with testing.
- An alternate LUS pattern, with signs such as a large consolidation or pleural effusion, suggests an alternate diagnosis as an explanation for the patient's symptoms. These patients should be isolated until test results are available, admitted to the hospital, and treated for their alternate diagnosis.
- A low probability LUS pattern in association with significant dyspnea or respiratory failure suggests an alternative diagnosis such as pulmonary embolism, asthma, or COPD exacerbation. In doubtful cases with cough and fever, these patients should be isolated until test results are available given the possibility of COVID-19 coinfection without pneumonia.

For the mixed phenotype (patients with respiratory failure and preexisting pulmonary or cardiac disease):

- A high probability LUS pattern is likely to be related to COVID-19 but must be viewed in the context of an

underlying disease that may confound the symptoms and severity of the clinical presentation.

- The intermediate probability and alternative LUS patterns, as described earlier, require integration of LUS findings with a current clinical scenario in the context of the patient's comorbid medical conditions; here great uncertainty with respect to the possibility of COVID-19 remains, and CT scanning may be crucial.
- A low probability LUS pattern is unlikely to be found in patients with significant preexisting pulmonary or cardiac disease.

Conclusions

Although the specific role for LUS in the management of COVID-19 is still evolving, its utility in the management of patients with respiratory failure in general is very well established. Given the severity of illness associated with this particular pathogen and the need for strict isolation protocols, there is evidence to suggest that LUS will emerge as the best available imaging modality for these patients.

Acknowledgments

Financial/nonfinancial disclosures: None declared.

Additional information: The [Videos](#) can be found in the Multimedia section of the online article.

References

1. Antonio GE, Wong KT, Chu WCW. Imaging in severe acute respiratory syndrome (SARS). *Clin Radiol.* 2003;(58):825-832.
2. Ajlan AM, Ahyad RA, Jamjoom LG. Middle East respiratory syndrome coronavirus (MERS-CoV) infection: chest CT findings. *AJRM.* 2014;203:782-787.
3. Bernheim A, Mei X, Huang M. Chest CT findings in coronavirus disease-19 (COVID-19): relationship to duration of infection. *Radiology.* 2020;295(3):200463.
4. Hendin A, Koenig S, Millington SJ. Better with ultrasound: thoracic ultrasound. *Chest.* 2020;158(5):2082-2089.
5. Koenig S, Mayo P, Volpicelli G, Millington SJ. Lung ultrasound scanning for respiratory failure in acutely ill patients: a review. *Chest.* 2020;158(6):2511-2516.
6. Lichtenstein DA, Mezière GA. The BLUE-points: three standardized points used in the BLUE-protocol for ultrasound assessment of the lung in acute respiratory failure. *Crit Ultrasound J.* 2011;3:109-110.
7. Volpicelli G, Elbarbary M, Blaivas M. International Liaison Committee on Lung Ultrasound (ILC-LUS) for International Consensus Conference on Lung Ultrasound (ICC-LUS) (2012) International evidence-based recommendations for point-of-care lung ultrasound. *Intensive Care Med.* 2012;38(4):577-591.
8. Soldati G, Smargiassi A, Inchingolo R, et al. Proposal for international standardization of the use of lung ultrasound for patients with COVID-19. *J Ultrasound Med.* 2020;39(7):1413-1419.
9. Peng QY, Wang XT, Zhang LN; Chinese Critical Care Ultrasound Study Group (CCUSG). Findings of lung ultrasonography of novel corona virus pneumonia during the 2019-2020 epidemic. *Intensive Care Med.* 2020;46(5):849-850.

10. Dinga X, Xu J, Zhou J, Long Q. Chest CT findings of COVID-19 pneumonia by duration of symptoms. *Eur J Radiol.* 2020;127:109009.
11. Almeida Monteiro RA, de Oliveira EP, Nascimento Saldiva PH, Dolhnikoff M, Duarte-Neto AN; BIAS-Brazilian Image Autopsy Study Group. Histological-ultrasonographical correlation of pulmonary involvement in severe COVID-19. *Intensive Care Med.* 2020;46(9):1766-1768.
12. Volpicelli G, Gargani L. Sonographic signs and patterns of COVID-19 pneumonia. *Ultrasound J.* 2020;12(1):22.
13. Volpicelli G, Lamorte A, Villén T. What's new in lung ultrasound during the COVID-19 pandemic. *Care Med.* 2020;46(7):1445-1448.
14. Bompard F, Monnier H, Saab I. Pulmonary embolism in patients with Covid-19 pneumonia. *Eur Respir J.* 2020;56(1):2001365.