

# Intracranial high-resolution vessel wall imaging in CADASIL

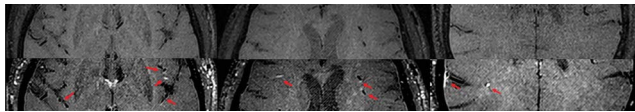
Eric D. Goldstein, MD, Jennifer J. Majersik, MD, MS, and Scott McNally, MD, PhD

*Neurology*® 2020;94:1040-1041. doi:10.1212/WNL.0000000000009588

## Correspondence

Dr. Goldstein  
eric.goldstein@hsc.utah.edu

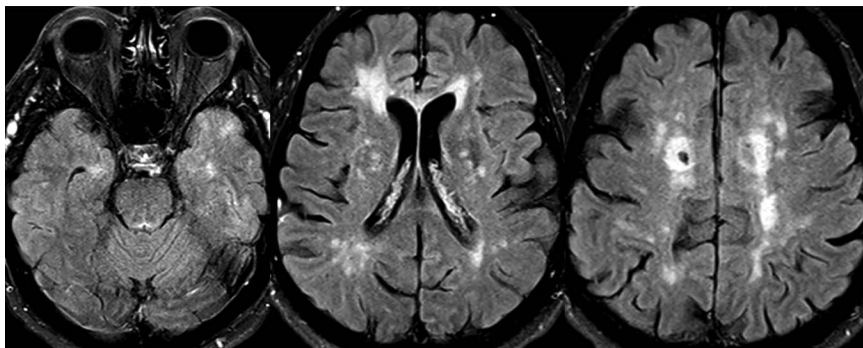
**Figure 1** Intracranial vessel wall MRI of cerebral autosomal dominant arteriopathy with subcortical infarcts and leukoencephalopathy



Top row showing T1 precontrast axial images compared with bottom row showing T1 postcontrast mural enhancement of the subcortical and leptomeningeal arteries. Note cortical venous mural enhancement in the bottom right pane. Arrows indicate intramural enhancement.

A 64-year-old man with cerebral autosomal dominant arteriopathy with subcortical infarcts and leukoencephalopathy (CADASIL) (heterozygous, c.544C>T; p.Arg182Cys) underwent an intracranial high-resolution black-blood protocol vessel wall MRI (vwMRI). Intramural patchy gadolinium enhancement in the subcortical and leptomeningeal arteries and veins was noted, consistent with the histopathologic findings of CADASIL (figures 1 and 2).<sup>1,2</sup> We hypothesize that vwMRI allowed for an in vivo view of the vasculopathy intrinsic to CADASIL. Pending investigation of larger cohorts, this imaging technique may provide a novel mechanism for understanding CADASIL progression and pathogenesis, as well as potentially serving as

**Figure 2** Baseline white matter burden



Axial fluid-attenuated inversion recovery sequences show T2 subcortical white matter hyperintensities consistent with cerebral autosomal dominant arteriopathy with subcortical infarcts and leukoencephalopathy. Images provided for comparison.

From the Departments of Neurology (E.D.G., J.J.M.) and Neuroradiology (S.M.), University of Utah, Salt Lake City.

Go to [Neurology.org/N](https://www.neurology.org/N) for full disclosures. Funding information and disclosures deemed relevant by the authors, if any, are provided at the end of the article.

a biomarker in future disease modification trials and aiding in the differential diagnosis for interpreting clinicians.

## Study funding

No targeted funding reported.

## Disclosure

The authors report no relevant disclosures. Go to [Neurology.org/N](http://Neurology.org/N) for full disclosures.

## Appendix Authors

Name	Location	Contribution
<b>Eric D. Goldstein, MD</b>	University of Utah, Salt Lake City	Design and conceptualization, drafted manuscript for intellectual content

## Appendix (continued)

Name	Location	Contribution
<b>Jennifer J. Majersik, MD, MS</b>	University of Utah, Salt Lake City	Drafting and revision of manuscript for intellectual content
<b>Scott McNally, MD, PhD</b>	University of Utah, Salt Lake City	Drafting and revision of manuscript for intellectual content

## References

1. Coupland K, Lendahl U, Karlström H. Role of NOTCH3 mutations in the cerebral small vessel disease cerebral autosomal dominant arteriopathy with subcortical infarcts and leukoencephalopathy. *Stroke* 2018;49:2793–2800.
2. Rafalowska J, Fidzianska A, Dziewulska D, Podlecka A, Szpak GM, Kwiecinski H. CADASIL or CADVaSIL? *Neuropathology* 2004;24:16–20.

## The AAN is at Your Side


When you're in the office, the AAN is at your side. The AAN is your #1 resource to support you and your care team. Whether it's resources to help you and your staff provide the best care for your patients, ensure proper reimbursement, or maximize practice performance, the AAN is at your side. Access these resources today at [AAN.com/view/practiceresources](http://AAN.com/view/practiceresources).

## Visit the *Neurology*<sup>®</sup> Resident & Fellow Website

Click on Residents & Fellows tab at [Neurology.org](http://Neurology.org).

Now offering:

- *Neurology*<sup>®</sup> Resident & Fellow Editorial team information
- “Search by subcategory” option
- E-pearl of the Week
- RSS Feeds
- Direct links to Continuum<sup>®</sup>, Career Planning, and AAN Resident & Fellow pages
- Recently published Resident & Fellow articles
- Podcast descriptions
- Blogs by Editors and Resident & Fellow team members

 Find *Neurology*<sup>®</sup> Residents & Fellows Section on Facebook: [facebook.com/AANResidentsAndFellows](https://facebook.com/AANResidentsAndFellows)

 Follow *Neurology*<sup>®</sup> on Twitter: @GreenJournal #NeurologyRF

 Find *Neurology*<sup>®</sup> Residents & Fellows Section on Instagram: @aanbrain #NeurologyRF