

Pathological Complete Response from Pyrotinib Combined with Trastuzumab, Paclitaxel and Cisplatin in a Postpartum Woman with HER2-Positive Locally Advanced Breast Cancer: A Case Report

This article was published in the following Dove Press journal:
OncoTargets and Therapy

Lina He ^{1,*}
Fengchun Zhang^{2,*}
Yue Ma^{1,*}
Li Zuo³
Yingchun Xu¹

¹Department of Oncology, Renji Hospital, Shanghai Jiaotong University School of Medicine, Shanghai, People's Republic of China; ²Department of Oncology, Suzhou Kowloon Hospital, Shanghai Jiaotong University School of Medicine, Suzhou, People's Republic of China; ³Department of Oncology, Fudan University Shanghai Cancer Center, Minhang Branch, Shanghai, People's Republic of China

*These authors contributed equally to this work

Background: Overexpression of human epidermal growth factor receptor 2 (HER2) is associated with aggressive disease and poor prognosis. Traditional HER2-targeted agents can improve clinical outcome and have played an essential role in therapy. Pyrotinib is a newly irreversible tyrosine kinase inhibitor (TKI) that is well developed for the treatment of HER2-positive advanced breast tumors.

Case Presentation: A 37-year-old postpartum female was presented at a local hospital and was diagnosed with HER2-positive stage IIIB (cT4N1M0) invasive micropapillary adenocarcinoma in the left breast with left axillary metastatic lymph nodes. The patient failed to respond to two cycles of the doxorubicin plus cyclophosphamide (AC) regimen but achieved clinical partial response (cPR) after 4 cycles of the combination of pyrotinib, trastuzumab, paclitaxel and cisplatin (PTPC) regimen according to radiologic assessments. Then, she underwent left-side modified radical mastectomy (MRM) and achieved pathologic complete response (pCR), as confirmed by postoperative pathology. The patient held on receiving 2 cycles of the targeted therapy plus chemotherapy with trastuzumab, paclitaxel plus cisplatin (TPC) and adjuvant radiation therapy but continued to receive targeted therapy with trastuzumab and pertuzumab during the 1-year follow-up period. There has been no clinical evidence of disease progression so far.

Conclusion: Breast cancer overexpressing HER2 is a malignant tumor responsible for many cancer-related deaths. The combination of pyrotinib plus other targeted chemotherapy can dramatically improve the outcome of locally advanced disease.

Keywords: pyrotinib, locally advanced breast cancer, anti-HER2 targeted therapy

Background

Breast cancer, a heterogeneous phenotypically diverse disease, is composed of four biologic subtypes that have distinct behaviors and responses to therapy. Overexpression of human epidermal growth factor receptor 2 (HER2) has been reported in 15% to 20% of breast cancer patients and is associated with aggressive biological behavior, short time to recurrence, and poor prognosis.¹ There has been a significant improvement in relapse-free survival of HER2-positive disease, supporting the efficacy of anti-HER2 agents.² However, the reduced but persistent peak of early recurrence in estrogen receptor (ER)-negative/HER2-positive disease signals the need for new treatment strategies, including dual HER2 blockade.

Correspondence: Li Zuo; Yingchun Xu
Email zuohuang2005@163.com;
xiaoxu2384@163.com

Pyrotinib is a new irreversible, pan-ErbB receptor tyrosine kinase inhibitor that is well developed for the treatment of HER2-positive advanced breast tumors. In a Phase I clinical trial, pyrotinib was well tolerated and demonstrated promising antitumor activity in patients with HER2-positive metastatic breast cancer—the overall response rate was 50.0%, the clinical benefit rate (complete response + partial response + stable disease ≥ 24 weeks) was 61.1%, and the median progression-free survival was 35.4 weeks.³ Moreover, pyrotinib plus capecitabine significantly prolonged median progression-free survival (PFS) versus lapatinib plus capecitabine (18.1 vs 7.0 months) in patients with advanced or metastatic breast cancer previously treated with anthracycline or taxane chemotherapy according to the Phase II study, and the ongoing Phase III trial is to validate the superiority of pyrotinib plus capecitabine.^{4,5} With regard to pyrotinib-related adverse events, common side effects include diarrhea, nausea, oral ulceration, leukopenia and others.³ Grade 3 diarrhea was a dose-limiting toxicity.³ The maximum tolerated dose was established as 400 mg, and the minimum dosage of pyrotinib is 240 mg once daily.⁶

Pyrotinib is still in clinical trials, and recently, many studies have been performed with great efforts to evaluate the clinical efficacy of pyrotinib combined with other chemotherapies in neoadjuvant or adjuvant settings. Here, we present a case of a HER2-positive locally advanced breast tumor in a postpartum woman responding excellently to the combination of pyrotinib, trastuzumab, paclitaxel and cisplatin (PTPC) as neoadjuvant therapy with no response to prior doxorubicin plus cyclophosphamide (AC) chemotherapy.

Case Presentation

Our patient, a 37-year-old postpartum female, presented to the Tianjin Tumor Hospital in China. Her B-ultrasonography results showed a left breast mass with the largest measuring up to 8 * 7cm in size and with left axillary multiple lymph node metastasis (BI-RADS 5). The pathology of the left breast by core needle biopsy revealed invasive micropapillary adenocarcinoma with the following results: estrogen receptor (ER) (<1%), progesterone receptor (PR) (<1%), HER-2 (3+), and Ki-67 (25%); moreover, the fine needle axillary lymph node biopsy samples confirmed metastatic and poorly differentiated adenocarcinoma with the following findings: ER (<1%), PR (<1%), HER-2 (3+) and Ki-67 (25%). The patient had undergone chemotherapy with an AC regimen (liposomal doxorubicin 40 mg on day 1 +

cyclophosphamide 800 mg on day 1, q3w) for two cycles. However, no obvious reduction in breast mass was observed, and she felt pain in the left breast. Then, she presented to Shanghai Renji Hospital. Physical examination showed 9.0cm mass in left breast with diffuse edema and erythema in skin and several fixed and matted enlarged lymph nodes in the left axilla. The chest CT showed internal nodular foci in the left breast and multiple enlarged lymph nodes in the left armpit. Mammography found a diffusely increased density of the left mammary gland with local distortion and fine sand-like calcification (BI-RADS.6) (Figure 1). Breast MRI was carried out and showed a widely abnormal signal (with the largest measuring up to 8.7cm) and skin thickening in the left breast (BI-RADS.6), left nipple depression, fat pad edema in the subcutaneous and anterior areas of the pectoralis major muscle, and enlargement of the left axillary lymph node (Figure 2, Figure 3A). Therefore, the clinical stage was designated IIIB (cT₄N₁M₀). Moreover, vacuum-assisted breast biopsy and fine needle aspiration of left axillary lymph node were performed for the patient. The pathology indicated infiltrating carcinoma with ER (-), PR (-), HER2 (2+) and Ki67 (10%). The HER2 fluorescence in situ hybridization test was positive, and the HER2/CEP17 ratio was 4.5. Then the patient started to receive neoadjuvant chemotherapy (pyrotinib 400 mg once daily + weekly trastuzumab (first 4 mg/kg, then 2 mg/kg) + paclitaxel (120 mg (80 mg/m²) on days 1, 8, 15, and 22, q28d) + cisplatin (40 mg (25 mg/m²) on days 1, 8, and 15, q28d)) (PTPC). She experienced grade 3 diarrhea and grade 2 neutropenia, and the dosage of pyrotinib was reduced to 320 mg and then 240 mg once daily for diarrhea. After 2 cycles, breast MRI showed a significant reduction in the lesion size in the left breast (with the largest measuring up to 0.7cm) (Figure 3B) and a visibly reduced size of the lymph node in the left armpit, which was evaluated as clinical partial response (cPR) by efficacy assessment according to Response Evaluation Criteria in Solid Tumors version 1.1 (RECIST1.1). After 4 cycles, the breast MRI results showed close to a clinical complete response (cCR) (Figure 3C). The most frequent tolerated adverse events were grade 2 neutropenia and grade 2 diarrhea, which were observed in the patient but were not mitigated with further dose reduction. Modified radical mastectomy of the left breast was performed. The specimen suggested hyperplasia of the breast interstitial fibrous tissue with a few infiltrating inflammatory cells and no tumor tissue residue. The tissues from the nipple, dissected surface, lymph nodes, fibrous adipose tissue, and the left axillary lymph node were negative for disease. The postoperative pathology revealed

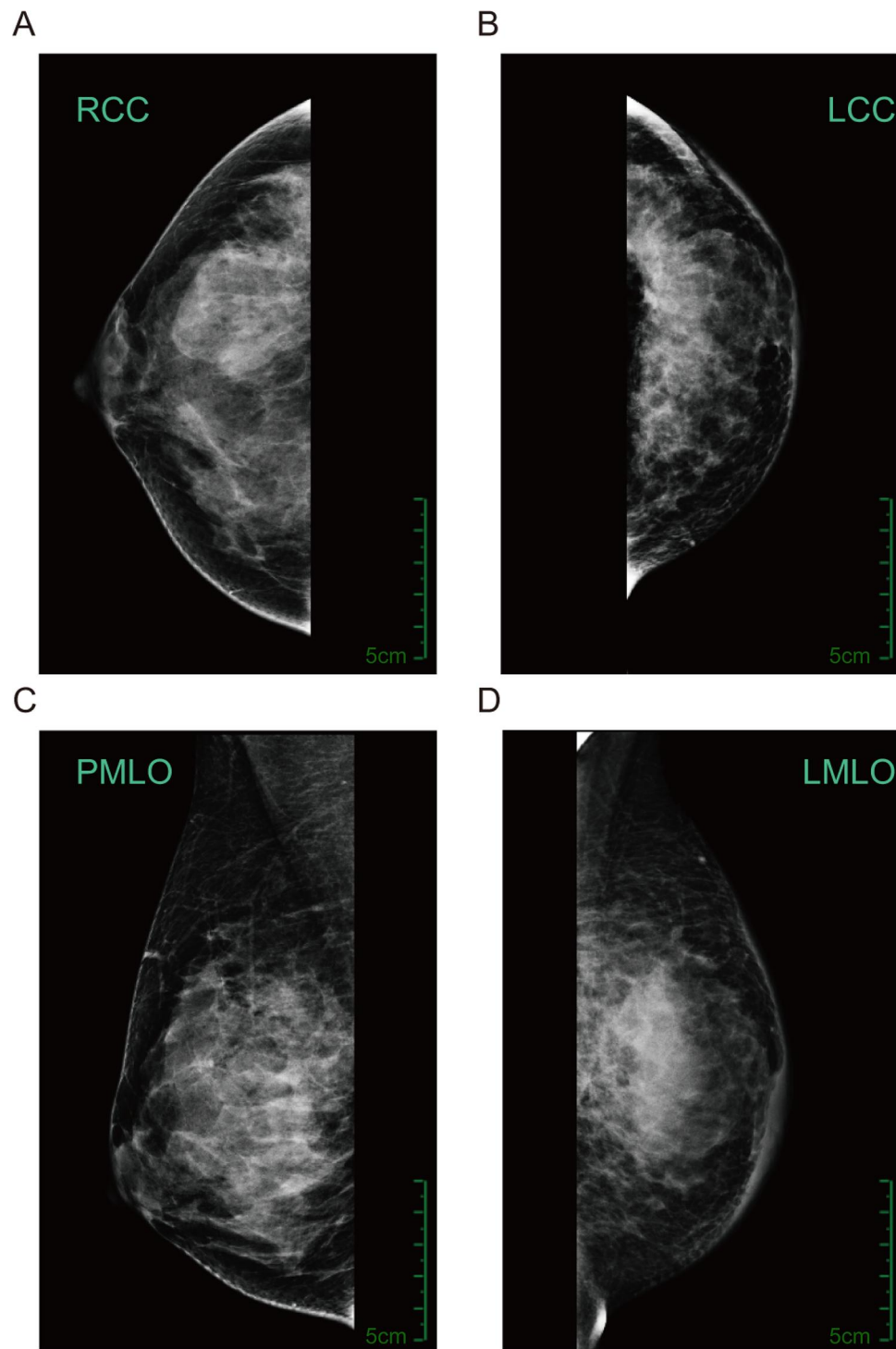


Figure 1 Mammography presentations (2019.02.14). **Notes:** Mammography shows that bilateral breast was asymmetrical, and the density of the left breast was abnormal with focal architectural distortion and fine sand-like calcification (BI-RADS.6). (A) right craniocaudal (RCC), (B) left craniocaudal (LCC), (C) right mediolateral oblique (RMLLO), and (D) left mediolateral oblique (LMLO).

pathological complete remission (pCR). The patient held on receiving 2 cycles of the targeted therapy plus chemotherapy with TPC, but adjuvant radiation therapy and HER2-targeted therapy with trastuzumab were administered in the

neoadjuvant setting, and pertuzumab was administered over the 1-year follow-up duration. There has been no clinical evidence of disease progression so far. The disease-free survival is currently 8 months.

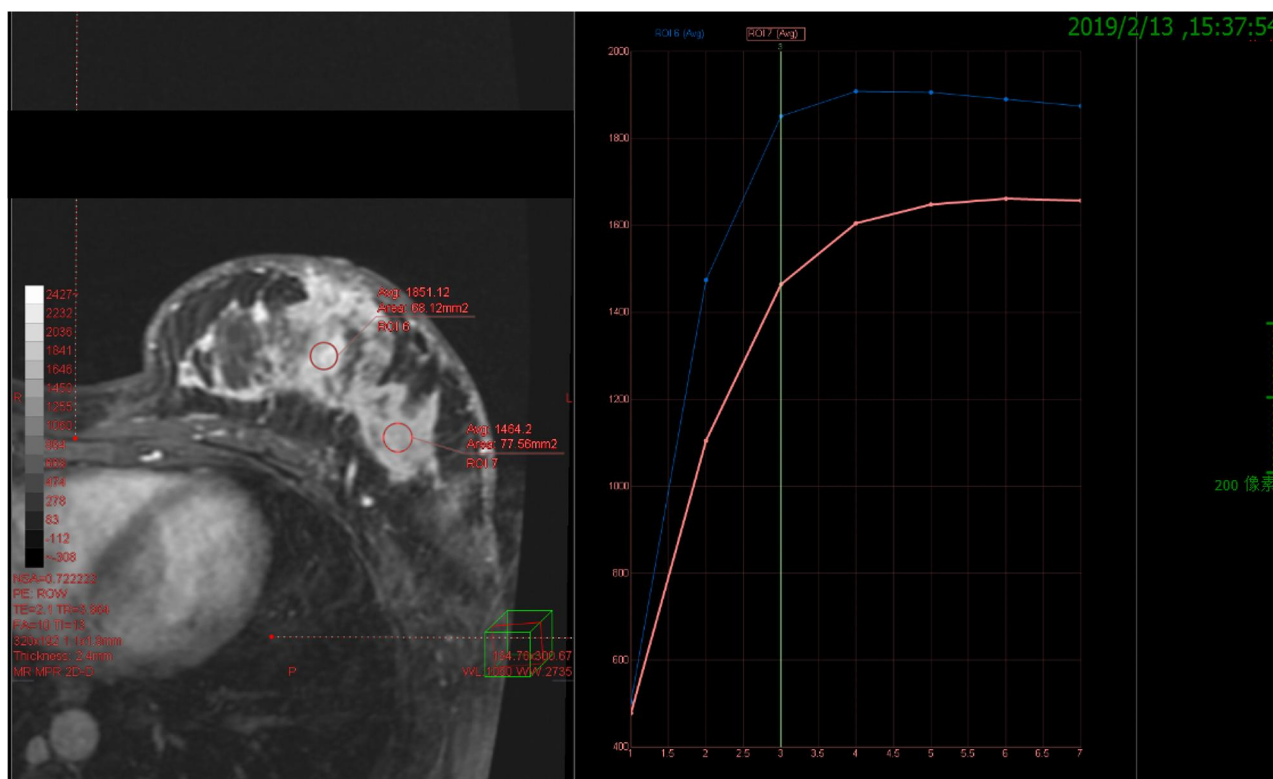


Figure 2 Breast MRI (2019.02.13). **Notes:** The time-intensity curve (TIC) shows a platform-type or outflow-type curve, and the Apparent Diffusion Coefficient (ADC) value was approximately $0.95 \times 10^{-3} \text{ mm}^2/\text{s}$, suggesting a malignant tumor (BI-RADS.6).

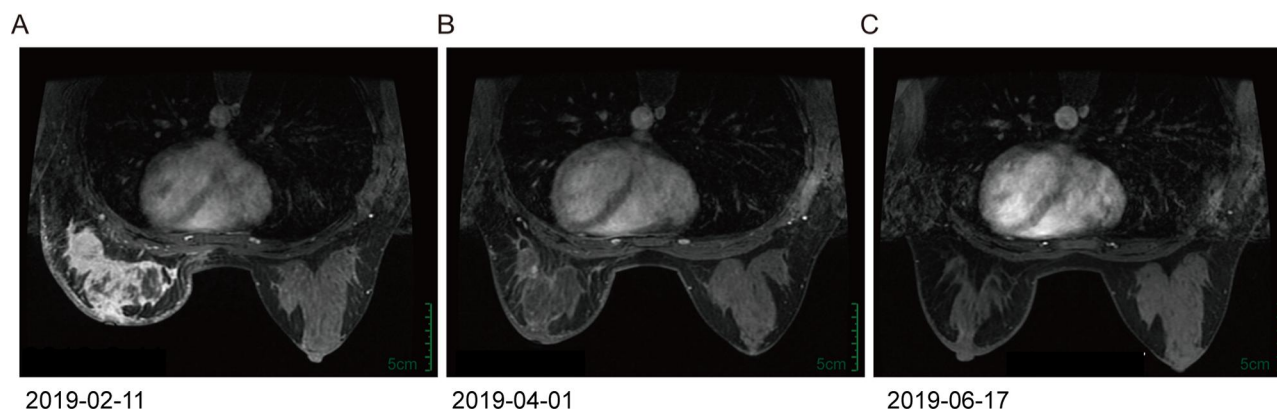

Figure 3 Breast MRI imaging. **Notes:** (A) MRI presents with a left breast mass (8.7cm in diameter) which was apparently intensified before treatment. (B) The imaging was scanned after 2-cycle treatment with PTPC (the combination of pyrotinib, trastuzumab, paclitaxel and cisplatin). It shows us a significant decrease in lesion size (0.7cm in diameter) and visibly reduced lymph node size in the left armpit, which was evaluated as a clinical partial response (cPR). (C) After 4-cycle treatment with PTPC, the imaging results were similar to those seen in the right breast on the imaging, suggesting a response close to a clinical complete response (cCR).

Discussion

Breast cancer is the most common malignant tumor in the Chinese female population, accounts for approximately 15% of female cancers, and has high morbidity and mortality. The gene that encodes HER2 (ERBB2, formerly known as neu) is amplified and overexpressed in approximately 20% of newly diagnosed breast cancers and is

associated with aggressive disease, lymph node or vascular metastasis and poor survival. HER2 belongs to the human epidermal receptor family, which contains three other receptors, EGFR (also known as HER1), HER3 and HER4, that are known to bind to at least 11 peptide ligands; this binding results in homodimerization and heterodimerization among these receptors and subsequent downstream tyrosine kinase

signaling cascades. These signaling cascades stimulate subsequent cell proliferation, migration, invasion and survival, all of which are hallmarks of cancer. HER2 has no known ligand but is a preferred dimerization partner of the other three receptors.⁷ Over the past two decades, multiple HER2-targeted therapies, including trastuzumab, pertuzumab, lapatinib, neratinib and the antibody–drug conjugate trastuzumab emtansine (T-DM1), have dramatically changed the clinical outcomes of patients with HER2-positive breast cancer in neoadjuvant, adjuvant and metastatic settings. Trastuzumab, pertuzumab, and T-DM1 bind to the extracellular domain of HER2. Trastuzumab and pertuzumab either alter normal tyrosine kinase signaling or induce antibody-dependent complement-mediated cytotoxicity (ADCC). Trastuzumab emtansine is internalized, and the chemotherapeutic agent is enzymatically cleaved, which leads to cytotoxic cell death.⁸ The tyrosine kinase inhibitors lapatinib and neratinib cross the cell membrane and inhibit intracellular tyrosine kinase domain activities.⁹ Despite the improvement in survival thanks to the first HER2-targeted agent trastuzumab, unclear mechanisms of resistance occur in approximately 70% of patients within one year.¹ The continuous development of anti-HER2 therapies such as lapatinib, pertuzumab, and T-DM1 has improved the outcomes of patients with HER2-positive breast cancer, but efficacy is still limited in different settings. Lapatinib is considered one of the key agents used in combination with capecitabine or trastuzumab in managing metastatic HER2-positive breast cancer that fails treatment with trastuzumab (as reported in NCT00078572).¹⁰ Lapatinib has been tested as a second-line therapy in patients with advanced HER2-positive breast cancer but failed in the early adjuvant setting (reported in the ALTTO trial) and the advanced first-line therapy setting (reported in the COMPLETE trial) in clinical trials. Neratinib is only indicated and approved for use in the extended adjuvant setting (as reported in the ExteNET trial) and has not been shown to be effective in the neoadjuvant and first-line therapy settings according to the I-SPY2 and NefERT-T trials, respectively.¹¹ Nevertheless, pertuzumab has demonstrated survival benefits for patients with metastatic HER2-positive breast cancer in first-line therapy settings according to CLEOPATRA study and has also been studied in the neoadjuvant setting and adjuvant setting (APHINITY trial); the addition of pertuzumab to trastuzumab and docetaxel improved pCR rates from 29% to 45.8% for early-stage HER2-positive breast cancer (as reported in the NeoSphere trial). It reminded us of the relatively higher

pCR rates (51.3%) of additional lapatinib to trastuzumab in NeoALLTO study; therefore, additional agents need to be developed further to improve the current results and overcome resistance, and the optimal combination of targeted drugs in different treatment settings is still uncertain.

Pyrotinib is an oral, irreversible dual pan-ErbB TKI developed as an antitumor agent for patients with HER2-positive advanced solid tumors, including breast cancer, by Jiangsu Hengrui Pharmaceutical.¹ The 3-cyanoquinoline derivative pyrotinib has activity against epidermal growth factor receptor (EGFR)/HER1, HER2, and HER4, inhibits HER2-driven tumor growth and HER2-mediated downstream signaling, and blocks tumor cells in the G1 phase of the cell cycle.¹² Pyrotinib induces potent inhibition of tyrosine kinase activity.¹² Compared with the reversible TKI lapatinib, pyrotinib forms a conjugated double-bond and is permanently bound to the ATP-binding site, making its actions irreversible and more effective.¹² In contrast to the irreversible TKI neratinib, pyrotinib has higher bioavailability and stronger efficacy.¹² In the pharmacokinetic experiments of rats, the absorption of pyrotinib is three times that of neratinib; and it has a higher AUC value and relatively low side effects.¹² Though in animal studies, the inhibition rates of pyrotinib and neratinib in breast cancer and lung cancer were similar. Until now, there is no report or trial to verify efficacy in the clinic of pyrotinib in comparison with neratinib. Moreover, pyrotinib is highly effective in trastuzumab-resistant patients, which has been confirmed by the superior median PFS for pyrotinib in combination with capecitabine versus placebo (11.1 months vs 4.1 months) in women with HER2-positive metastatic breast cancer who previously received taxane and trastuzumab therapy (as reported at ASCO; the PHENIX trial).¹³ In August 2018, pyrotinib received its first global conditional approval in China for use in combination with capecitabine for the treatment of HER2-positive, advanced or metastatic breast cancer in patients previously treated with anthracycline or taxane chemotherapy.⁴ Pyrotinib plus capecitabine yielded a statistically significant better overall response rate and progression-free survival (PFS) than lapatinib plus capecitabine in women with HER2-positive metastatic breast cancer previously treated with taxanes, anthracyclines, and/or trastuzumab in a randomized, open-label, active comparator-controlled, multicenter phase II trial (NCT02422199).¹⁴ The overall response rate was 78.5% in the pyrotinib group and 57.1% in the lapatinib group, representing a statistically significant objective response

Table I The Ongoing Clinical Trials of Pyrotinib in HER2 Breast Cancer Treatment

Study Phase	Registration Number	Trial Arm	Condition	Subjects	Status	Location
II	NCT03910712	Pyrotinib +Trastuzumab +Aromatase inhibitor vs Trastuzumab + Aromatase inhibitor	HER2-positive Breast Cancer; Hormone Receptor Positive Metastatic Breast Cancer	250	Not yet recruiting	Peking Union Medical College Hospital, China
II	NCT03847818	Pyrotinib + Trastuzumab + Docetaxel + Carboplatin vs Trastuzumab + Docetaxel + Carboplatin	HER2-positive Breast Cancer	268	Not yet recruiting	Shandong University, China
II	NCT04033172	Pyrotinib + Fulvestrant	HER2-positive Breast Cancer	40	Recruiting	Chinese Academy of Medical Sciences, China
II	NCT03933982	Pyrotinib + Vinorelbine	Breast Cancer; Brain Metastases	30	Recruiting	Chinese Academy of Medical Sciences, China
II	NCT04126525	Pyrotinib	Breast Cancer Female	52	Recruiting	Renji Hospital, China
II	NCT04001621	Pyrotinib + capecitabine	Metastatic Breast Cancer	100	Recruiting	Fudan University, China
III	NCT03980054	Pyrotinib vs Placebo	Breast Cancer	1192	Not yet recruiting	Jiangsu HengRui Medicine Co., Ltd. China
III	NCT03863223	Pyrotinib + Trastuzumab + Docetaxel vs Placebo+ Trastuzumab+ Docetaxel	Metastatic Breast Cancer	590	Recruiting	Jiangsu HengRui Medicine Co., Ltd. China
III	ChiCTR1900022293	Epirubicin + cyclophosphamide + pyrotinib + trastuzumab vs Epirubicin + cyclophosphamide + trastuzumab	Stage I to III HER2-positive breast cancer	210	Not yet recruiting	First Affiliated Hospital of Army Medical University, China
IV	ChiCTR1900020670	Pyrotinib + standard treatment	HER2-positive brain metastatic breast cancer	48	Not yet recruiting	Affiliated Cancer Hospital of Harbin Medical University, China
IV	ChiCTR1900021819	Pyrotinib	HER2-positive locally advanced breast cancer	1000	Not yet recruiting	Jiangsu Cancer Hospital, China

rate (ORR) increase of 21.3% with pyrotinib versus lapatinib. The median progression-free survival (PFS) was 18.1 months with pyrotinib and 7.0 months with lapatinib. Furthermore, the median PFS was longer with pyrotinib than lapatinib regardless of prior trastuzumab treatment.¹⁴ Based on its superior tolerability and efficacy, pyrotinib was newly added as a Level II recommendation for anti-HER2 second-line rescue treatment in place of trastuzumab for patients with HER2-positive advanced or

metastatic breast cancer in the 2019 Chinese Society of Clinical Oncology breast cancer guidelines.

The NeoALTTO trial is a neoadjuvant, multicenter, randomized phase III trial in which patients with HER2-positive early breast cancer were randomly assigned to receive lapatinib 1500 mg/day, trastuzumab, or the combination of lapatinib 1000 mg/day and trastuzumab for 6 weeks followed by the addition of paclitaxel for 12 weeks before surgery. Lapatinib was shown to

significantly improve the pCR rate, and the combination group had nearly double the pCR rate compared with the other two groups.¹⁵ As such, we wondered if pyrotinib is better than lapatinib in the metastatic setting,¹⁶ is it effective as a neoadjuvant treatment in combination with trastuzumab? In previous data in neoadjuvant settings, a paclitaxel plus cisplatin (PC) regimen combined with trastuzumab was proven to have a high pCR rate.¹⁷ Therefore, the antitumor activities of the combination of dual HER2-targeted agents (trastuzumab plus pyrotinib) and the PC regimen in the neoadjuvant setting may be promising. In our case, the patient failed to respond to the AC regimen but achieved cCR after receiving only 4 cycles of pyrotinib with trastuzumab, paclitaxel and cisplatin according to radiologic assessments. She achieved pCR as confirmed by postoperative pathology. Further exploration of efficacy and toxicities with PTPC in neoadjuvant setting in breast cancer is ongoing (NCT03947242) (Table 1). Recently, a one-arm exploratory clinical study was designed to test pyrotinib combined with albumin paclitaxel and trastuzumab for Her2-positive early or locally advanced breast cancer with the aim of assessing efficacy and safety and exploring the efficacy of tumor-associated molecular markers such as residual cancer burden (RCB) scores and tumor-infiltrating lymphocyte (TIL) proportions for predicting pyrotinib treatment efficacy (NCT04152057). Intriguingly, the biomarker analysis of previous trials suggested that PIK3CA and TP53 mutation status in ctDNA in tumor tissues correlated with response and even PFS.^{3,18-20} Interestingly, our patient had the PIK3CA H1047R mutation, but the value of the detection of biomarkers in the adjuvant setting still needs to be proven.

In one study, pyrotinib had a manageable toxicity profile in patients with HER2-positive metastatic breast cancer.¹⁴ The common treatment-emergent adverse events (TEAEs) of any grade (occurring in $\geq 20\%$ of patients and with a numerically higher incidence in the pyrotinib plus capecitabine group than the lapatinib plus capecitabine group) were diarrhea, hand-foot syndrome, vomiting, leukopenia, neutropenia, and others. Diarrhea is the most common adverse effect observed with tyrosine kinase inhibitors targeting EGFR/HER2.^{3,21} In a randomized phase II trial, grade 3 diarrhea occurred mostly during the first treatment cycle, with 50% of instances occurring on days 2 to 15 after starting treatment. Diarrhea was generally reversible with symptomatic treatment (eg, loperamide or montmorillonite) or by suspending or decreasing the dose of pyrotinib. It is

recommended that pyrotinib should be permanently discontinued when grade 4 diarrhea occurs.¹⁴ The grade 3 TEAE that inevitably occurred in our patient was diarrhea. Luckily, this symptom was quickly relieved by dose reduction.

There are many clinical trials underway to further confirm the efficacy of pyrotinib combined with trastuzumab and/or other chemotherapy agents in different settings, such as in the neoadjuvant, adjuvant, and rescue therapy settings and even in the management of brain-metastatic HER2-positive breast cancer (Table 1).

Conclusion

Pyrotinib is a newly developed agent, what we could learn from this case is that our case further strengthens the evidence of the efficacy of pyrotinib combined with trastuzumab and other chemotherapy agents in patients with HER2-positive advanced breast cancer in the neoadjuvant setting, but the potential side effects of the combination treatment should be highly concerned, and fully discussed with the patients in clinical practice. Pyrotinib combined with trastuzumab may present a new potential treatment option for the dual anti HER2 targeted therapy in the future; however, its efficacy and safety need further investigation in randomized Phase 3 study.

Abbreviations

ADC, apparent diffusion coefficient; ADCC, antibody-dependent complement-mediated cytotoxicity; cCR, clinical complete response; cPR, clinical partial response; EGFR, epidermal growth factor receptor; ER, estrogen receptor; HER2, human epidermal growth factor receptor 2; ORR, objective response rate; OS, overall survival; pCR, pathologic complete response; PFS, progression-free survival; PR, progesterone receptor; RCB, residual cancer burden; RR, recurrence rate; T-DM1, antibody-drug conjugate trastuzumab emtansine; TEAEs, treatment-emergent adverse events; TILs, tumor infiltrating lymphocytes; TKI, tyrosine kinase inhibitor.

Ethics Approval and Consent to Participate

This study has been approved by Ethics Committee of Renji Hospital of Shanghai Jiaotong University School of Medicine and the patient has signed an informed consent.

Consent for Publication

The patient was informed that the information published may potentially compromise anonymity. Publication was consented by the patient. Written informed consent was obtained from the case patient for publication of this report and any accompanying images.

Acknowledgments

The authors would like to thank the patient for giving consent and for providing the detailed information of this case.

Disclosure

All authors report no conflicts of interest in this work.

References

- Slamon DJ, Clark GM, Wong SG, et al. Human breast cancer: correlation of relapse and survival with amplification of the HER-2/neu oncogene. *Science*. 1987;235:177–182. doi:10.1126/science.3798106
- Cossetti RJ, Tyldesley SK, Speers CH, Zheng Y, Gelmon KA. Comparison of breast cancer recurrence and outcome patterns between patients treated from 1986 to 1992 and from 2004 to 2008. *J Clin Oncol*. 2015;33(1):65–73.
- Ma F, Li Q, Chen S, et al. Phase I study and biomarker analysis of pyrotinib, a novel irreversible pan-erbB receptor tyrosine kinase inhibitor, in patients with human epidermal growth factor receptor 2-positive metastatic breast cancer. *J Clin Oncol*. 2017;35(27):3105–3112. doi:10.1200/JCO.2016.69.6179
- De Leon J China approves Hengrui breast cancer drug on phase II data; 2018. Available from: <https://www.biocentury.com/bc-extra/company-news/2018-08-22/china-approveshengrui-breast-cancer-drug-phase-ii-data>. Accessed Sep 25, 2018.
- Blair HA. Pyrotinib: first global approval. *Drugs*. 2018.
- State Food and Drug Administration. Pyrotinib maleate tablets: prescribing information; 2018. Available from: <http://202.96.26.102>. Accessed Sep 25, 2018.
- Hayes DF. HER2 and breast cancer – a phenomenal success story. *N Engl J Med*. 2019;381(13):1284–1286. doi:10.1056/NEJMcibr1909386
- Barok M, Tanner M, Koninki K, et al. Trastuzumab-DM1 causes tumour growth inhibition by mitotic catastrophe in trastuzumab-resistant breast cancer cells in vivo. *Breast Cancer Res*. 2011;13:R46. doi:10.1186/bcr2868
- Traxler P. Tyrosine kinases as targets in cancer therapy-successes and failures. *Expert Opin Ther Targets*. 2003;7(2):215–234. doi:10.1517/14728222.7.2.215
- Geyer CE, Forster J, Lindquist D, et al. Lapatinib plus capecitabine for HER2-positive advanced breast cancer. *N Engl J Med*. 2006;355(26):2733–2743. doi:10.1056/NEJMoa064320
- Martin M, Holmes FA, Ejlertsen B, et al. Neratinib after trastuzumab-based adjuvant therapy in HER2-positive breast cancer (ExteNET): 5-year analysis of a randomised, double-blind, placebo-controlled, phase 3 trial. *Lancet Oncol*. 2017;S1470204517307179
- Li X, Yang C, Wan H, et al. Discovery and development of pyrotinib: a novel irreversible EGFR/HER2 dual tyrosine kinase inhibitor with favorable safety profiles for the treatment of breast cancer. *Eur J Pharm Sci*. 2017;110:51–61.
- Jiang Z, Yan M, Hu X, et al. Pyrotinib combined with capecitabine in women with HER2+ metastatic breast cancer previously treated with trastuzumab and taxanes: a randomized phase III study. *J Clin Oncol*. 2019;37(12):1001. doi:10.1200/JCO.18.00938
- Ma F, Ouyang Q, Li W, et al. Pyrotinib or lapatinib combined with capecitabine in HER2-positive metastatic breast cancer with prior taxanes, anthracyclines, and/or trastuzumab: a randomized, phase II study. *J Clin Oncol*. 2019;37(29):2610–2619. doi:10.1200/JCO.19.00108
- de Azambuja E, Holmes AP, Piccart-Gebhart M, et al. Lapatinib with trastuzumab for HER2-positive early breast cancer (NeoALTT0): survival outcomes of a randomised, open-label, multicentre, phase 3 trial and their association with pathological complete response. *Lancet Oncol*. 2014;15(10):1137–1146. doi:10.1016/S1470-2045(14)70320-1
- Gourd E. Pyrotinib versus lapatinib in HER2-positive breast cancer. *Lancet Oncol*. 2019;20(10):e562. doi:10.1016/S1470-2045(19)30568-6
- Zhou L, Xu S, Yin W, et al. Paclitaxel and cisplatin as neoadjuvant chemotherapy with locally advanced breast cancer: a prospective, single arm, phase II study. *Oncotarget*. 2017;8(45):79305–79314. doi:10.18632/oncotarget.17954
- Gourd E. Pyrotinib shows activity in metastatic breast cancer. *Lancet Oncol*. 2017;18(11):e643. doi:10.1016/S1470-2045(17)30755-6
- Li Q, Guan X, Chen S, et al. Safety, efficacy, and biomarker analysis of pyrotinib in combination with capecitabine in HER2-positive metastatic breast cancer patients: a phase I clinical trial. *Clin Cancer Res*. 2019;25(17):5212–5220. doi:10.1158/1078-0432.CCR-18-4173
- Ma F, Guan Y, Yi Z, et al. Assessing tumor heterogeneity using ctDNA to predict and monitor therapeutic response in metastatic breast cancer. *Int J Cancer*. 2019. doi:10.1002/ijc.32536
- Chan A. Neratinib in HER-2-positive breast cancer: results to date and clinical usefulness. *Ther Adv Med Oncol*. 2016;8(5):339–350. doi:10.1177/1758834016656494

OncoTargets and Therapy

Dovepress

Publish your work in this journal

OncoTargets and Therapy is an international, peer-reviewed, open access journal focusing on the pathological basis of all cancers, potential targets for therapy and treatment protocols employed to improve the management of cancer patients. The journal also focuses on the impact of management programs and new therapeutic

agents and protocols on patient perspectives such as quality of life, adherence and satisfaction. The manuscript management system is completely online and includes a very quick and fair peer-review system, which is all easy to use. Visit <http://www.dovepress.com/testimonials.php> to read real quotes from published authors.

Submit your manuscript here: <https://www.dovepress.com/oncotargets-and-therapy-journal>