



CASE REPORT

Unexpected favorable outcome to sintilimab plus bevacizumab in an *EGFR*-mutated non-small cell lung cancer patient: A case report

Yiruo Zhang¹, Mei Zhao¹, Shuliang Cao², Xuchao Zhang³  & Yingying Du¹ 

1 Department of Oncology, The First Affiliated Hospital of Anhui Medical University, Hefei, China

2 Burning Rock Biotech, Guangzhou, China

3 Guangdong Lung Cancer Institute, Guangdong Provincial Key Laboratory of Translational Medicine in Lung Cancer, Medical Research Center, Cancer Center, Guangdong Provincial People's Hospital & Guangdong Academy of Medical Sciences, Guangzhou, China

Keywords

EGFR-mutant; NSCLC; PD-1; resistance; sintilimab.

Correspondence

Xuchao Zhang, Guangdong Lung Cancer Institute, Guangdong Provincial Key Laboratory of Translational Medicine in Lung Cancer, Medical Research Center, Cancer Center, Guangdong Provincial People's Hospital & Guangdong Academy of Medical Sciences, Guangzhou, Guangdong 510080, China.
Tel: +86 139 2602 7885
Fax: +86 20 8382 6085
Email: zhxuchao3000@126.com;

Yingying Du, Department of Oncology, The First Affiliated Hospital of Anhui Medical University, Hefei, Anhui 230022, China.
Tel: +86 139 5601 2561
Fax: +86 551 6363 3742
Email: duyinying@126.com

Received: 12 May 2020;

Accepted: 18 June 2020.

doi: 10.1111/1759-7714.13569

Thoracic Cancer **11** (2020) 2717–2722

Introduction

Lung cancer continues to be the most common malignant tumor and the leading cause of cancer death worldwide. Despite the discovery of *EGFR* (epidermal growth factor receptor) gene alterations and development of targeted therapies which has revolutionized the treatment of NSCLC, the mortality of lung cancer has continued to increase over time.^{1, 2} More importantly, most of patients will inevitably experience acquired resistance within less than one year.³

Abstract

A 53-year-old man diagnosed with disease stage IIIB pulmonary adenocarcinoma underwent chemotherapy and radiotherapy in the first-line setting. After disease progression, he received targeted therapy because of subsequent detection of *EGFR* exon 19 del mutation. Following an increase in his adrenal metastases, a combination of immunotherapy and antiangiogenic therapy (sintilimab plus bevacizumab) was commenced. After one month, imaging showed that the adrenal metastases had shrunk and a progression-free survival (PFS) of 6.0 months was achieved. In this case, we showed that the PD1 inhibitor sintilimab plus bevacizumab was effective in a refractory advanced *EGFR*-mutant NSCLC with positive PD-L1 expression.

Key points

Our case report provides clinical evidence of the durable response of a patient with advanced *EGFR*-mutant lung adenocarcinoma to a combination of immunotherapy and anti-angiogenic agent, sintilimab and bevacizumab, as subsequent-line therapy. Sintilimab and bevacizumab combination therapy was well-tolerated and effective, resulting in dramatic tumor reduction and improvement in clinical symptoms.

On the other hand, there has been some recent breakthroughs in cancer immunotherapy for the treatment of solid tumor patients. The activation of PD-1 (programmed cell death protein-1)/PD-L1 (programmed death ligand-1) pathway can prevent tumors from immune surveillance. Nivolumab and pembrolizumab as anti-PD-1 antibody and atezolizumab as PD-L1 antibody, the immune checkpoint inhibitor (ICI), have proved their efficacy and safety in patients with pretreated advanced NSCLC in clinical trials.^{4–6} However, one of the greatest challenges is that

patients harboring *EGFR* mutations may have very little opportunity to benefit from immunotherapy.⁵

Here, we report a patient with advanced NSCLC where chemotherapy and *EGFR* target therapy failed and who was administered bevacizumab in combination with sintilimab, a new anti-PD-1 antibody, which has shown antitumor effects and tolerability in preclinical in vitro and phase I clinical trials. The patient in this study achieved a partial response (PR) with a progression-free survival (PFS) of six months.

Case report

A 53-year-old man with a history of smoking (30 pack-years) presented to the hospital for physical examination in March 2017. Chest computed tomography (CT) scan showed space-occupying lesions of the lower left lung. A CT-guided percutaneous pneumocentesis biopsy was performed and histological adenocarcinoma was diagnosed. There was no opportunity for surgery at that time because he was already at stage IIIB (cT3N2M0) of diagnosis, with mediastinal lymph node metastasis. He subsequently underwent four courses of chemotherapy (pemetrexed 800 mg D1 plus cisplatin 30 mg D1-4) and achieved a partial response (PR) based on the Response Evaluation Criteria In Solid Tumors 1.1 (RECIST), during March 2017 to June 2017. Subsequently, primary lung lesions and mediastinal lymph node metastases received intensity modulated radiation therapy (60 Gy/30 F) and the patient also received oral TS-1 treatment. In October 2017, polymerase chain reaction (PCR) test of the tumor showed *EGFR* exon 19del, but targeted therapy was refused at the time of genotyping. Unfortunately, he was found to have PD (progressive disease) with enlarged primary lung lesions and

left hilar nodes in January 2018 after a PFS of 9.6 months receiving first-line chemotherapy. Based on this, he received gefitinib (250 mg once a day) as the second-line of treatment. In May 2018, the patient was evaluated and confirmed to have PD following the emergence of right adrenal and liver metastasis, despite a shrunken lung lesion and PFS which had lasted 4.1 months. In consideration of the benefits of gefitinib, treatment with gefitinib was continued until July 2018. On 3 July 2018, the patient underwent rebiopsy of the right adrenal through CT-guided percutaneous puncture and the histology still indicated adenocarcinoma, and notably PD-L1 expression 15% + by IHC on Roche Vantana Benchmark IHC (immunohistochemistry) platform with antibody of SP142. Next-generation sequencing (NGS, Burning Rock, Guangzhou, People's Republic of China) test for a large panel containing 520 oncogenic genes was used for molecular testing of the adrenal biopsy sample, which confirmed the presence of *MET* (*MET* proto-oncogene, receptor tyrosine kinase) gene amplification (copy number 10.3) (Fig 1), in addition to the baseline *EGFR* exon 19 del with an allele frequency of 47.5%, and tumor mutation burden (TMB) was calculated (7.9 mutations/Mb). The patient was subsequently switched to bevacizumab (375 mg) combined with gefitinib (250 mg once a day) from July to October 2018. Unfortunately, the disease continued to progress with increases in left adrenal lesions and other metastases (Fig 2).

Due to the poor response to bevacizumab plus gefitinib therapy and PD-L1 expression 15% + (IHC) on adrenal puncture sample, sintilimab combined with bevacizumab treatment was commenced on 11 November 2018, at a dose of 200 mg and 400 mg, respectively, every three weeks for four times and a PR was obtained after four weeks (Fig 3). During the sintilimab plus bevacizumab treatment,

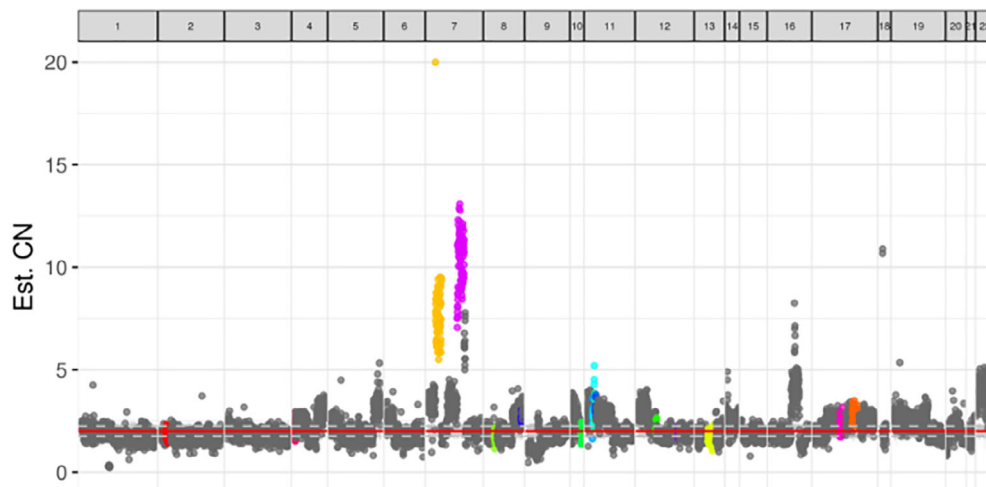


Figure 1 Distribution of gene copy number (purple blot: *MET* gene amplification). (●) *ALK*; (●) *BRCA1*; (●) *BRCA2*; (●) *CCND1*; (●) *CDK4*; (●) *EGFR*; (●) *ERBB2*; (●) *FGF19*; (●) *FGF3*; (●) *FGF4*; (●) *FGFR1*; (●) *FGFR2*; (●) *FGFR3*; (●) *KRAS*; (●) *MET*; (●) *MYC*; (●) others.

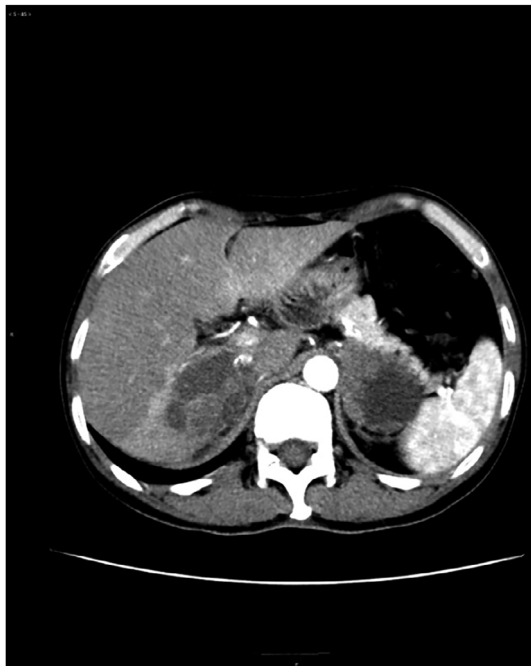

Figure 2 Bilateral adrenal metastases before sintilimab plus bevacizumab treatment (27 June 2018).

the patient developed grade 3 rashes which can reoccur spontaneously. Myelosuppression, hypertension, diarrhea, or other adverse events were not apparent. Symptoms of dry cough and pain were improved during ICI plus

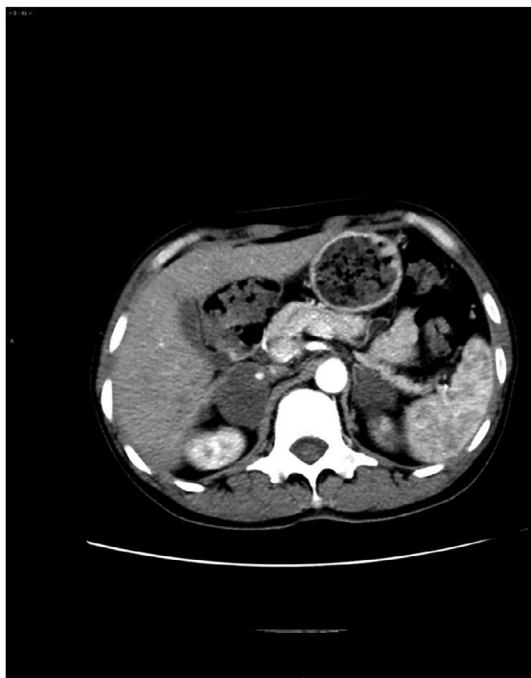

Figure 3 Bilateral adrenal metastases one month after sintilimab plus bevacizumab treatment (20 December 2018).

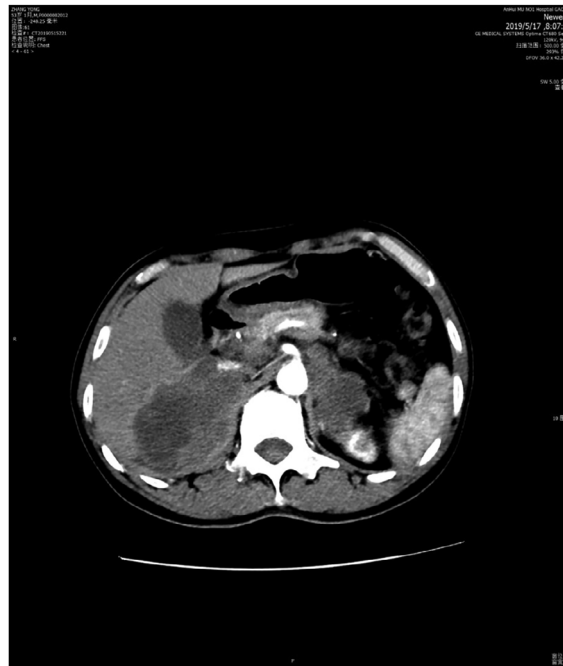


Figure 4 Bilateral adrenal metastases six months after sintilimab plus bevacizumab treatment (15 May 2019).

angiogenesis inhibitor treatment. A PFS of 6.0 months was achieved.

Unfortunately, thereafter, the patient had progression of bilateral adrenal metastases (Fig 4), his general condition worsened, and he had a dry cough, expectoration and pain. Even if we had attempted to use sintilimab combined with anlotinib or docetaxel, it would not have stopped the disease from deteriorating. The patient died in June 2019.

Discussion

Over the past decade, many studies have shown that *EGFR* tyrosine kinase inhibitors (TKIs) are preferred for the treatment of advanced NSCLC with *EGFR* mutation.^{7, 8} Despite initial efficacy, almost all patients will inevitably develop resistance to these agents.⁹ The molecular mechanisms underlying acquired resistance to *EGFR* TKIs are very complex.^{10–12}

In this case, after our patient progressed following first-line treatment, targeted therapy was applied because the patient harbored *EGFR* exon 19 del, but only 4.1 months of PFS was obtained. We considered that the patient's rapid resistance to targeted therapy may have resulted from secondary mutations, or a combination of other mutations. Therefore, molecular testing of the adrenal biopsy sample by NGS was therefore carried out, which confirmed the presence of *MET* gene amplification and *EGFR* exon 19 del. We thought *MET* amplification may have led to acquired resistance to gefitinib, as previous studies have

noted that *MET* amplification is a major cause of acquired resistance to the first and third generation *EGFR*-TKIs, such as erlotinib, gefitinib and osimertinib.^{13–15} Crizotinib is effective for patients with *MET* amplification,¹⁶ but the clinical efficacy of combination therapy of crizotinib and *EGFR*-TKIs in patients who acquired *MET* amplification during treatment with *EGFR*-TKIs remains controversial. Based on this, and the poor response to gefitinib, we added bevacizumab, an antiangiogenic drug, when the tumor progressed. However, the response to bevacizumab plus gefitinib therapy was poor.

Recently, ICIs, such as pembrolizumab have been recommended for first-line treatment in advanced NSCLC patients, whose tumor cell PD-L1 expression is $\geq 50\%$ (IHC) and PS (performance status) 0–1. In addition, pembrolizumab and other ICIs combined with platinum or bevacizumab have become one of the first-line treatment of choice for NSCLC without oncogenic drivers, irrespective of PD-L1 expression.^{17, 18} The emergence of immunotherapy brings a new choice for lung cancer with poor prognosis.

As the PD-L1 expression was 15% + (IHC) on adrenal puncture sample of this patient, we chose treatment with sintilimab combined with bevacizumab. Sintilimab, a fully human IgG4 monoclonal antibody which can bind to PD-1 to block the interaction of PD-1 with PD-L1 and PD-L2, has demonstrated its antitumor activity and safety in classical Hodgkin's lymphoma. In phase IA clinical trials in solid tumors it has also been shown to have similar pharmacokinetic characteristics to nivolumab and pembrolizumab.¹⁹ In our case, the treatment with sintilimab plus bevacizumab conferred six months of PFS in the *EGFR*-mutant patient with advanced NSCLC who had undergone multiline therapies, which demonstrate its powerful antitumor efficacy. In addition, the toxicity during treatment is mild and controllable. However, it has been suggested that patients with *EGFR* mutations treated with PD-1/L1 inhibitors (pembrolizumab, nivolumab, and atezolizumab) as second-line therapy receive very limited benefit from immunotherapy.^{5, 20, 21} On the other hand, positive results are still being reported following immunotherapy treatment in *EGFR*-mutated patients. The ATLANTIC study demonstrated that an objective response was achieved in 12.2% patients who had *EGFR*+/*ALK*+ NSCLC with tumor cell PD-L1 expression $\geq 25\%$, treated with durvalumab (anti-PD-L1).²²

Additionally, preclinical and clinical trials have demonstrated synergistic and increased efficacy of antiangiogenic therapy combined with immunotherapy in the treatment of pretreated advanced NSCLC, owing to the immunosuppressive activity of proangiogenic factors,²³ and it has also been suggested that immunotherapies can be antiangiogenic.²⁴ Taken together, it suggests that the combination of these

two therapies can act synergistically on the target tumors. Based on this, several trials are currently investigating combinations of angiogenesis inhibitors and ICIs in patients with NSCLC. Preliminary data from such combination therapies are promising. In the study by Reck *et al.* on IMpower150, there was an improved overall survival with ABCP (atezolizumab plus bevacizumab plus carboplatin plus paclitaxel) versus BCP (bevacizumab plus carboplatin plus paclitaxel) observed in patients with sensitizing *EGFR* mutations.²⁵ A phase I study evaluated the safety and efficacy of switching to nivolumab maintenance therapy, as monotherapy or combined with bevacizumab in patients with advanced NSCLC who did not progress on first-line chemotherapy. The results showed improved median PFS of patients treated with nivolumab + bevacizumab compared with nivolumab monotherapy, and the toxicity was well tolerated.²⁶ Herbst *et al.* evaluated the safety and tolerability of pembrolizumab combined with ramucirumab in patients with various solid tumors including advanced NSCLC and found that the objective response rate was 30%, while the disease control rate was 85%. The treatment-related AE was well tolerated.²⁷ Based on these results above, in our case, a possible explanation for the achievement of clinical benefit from immunotherapy might be the treatment of sintilimab combined with bevacizumab.

After a PFS of six months, the patient had disease progression without significant change in gene mutation profile, but there was positive downregulation of PD-L1 (5%) after acquired resistance to immunotherapy. The PD-L1 expression of tumor tissue may represent a predictive biomarker to ICI immunotherapies and the persistence of PD-L1 positive tumor tissue in this patient after immunotherapy resistance might reflect a mechanism of immunotherapy escape. In NSCLC, it has been proven that PD-L1 overexpression is correlated with poor prognosis in patients.²⁸ A previous study noted the importance of PD-L1-expressing cells promoting dysfunction in tumor-responding CD8⁺ T cells from pleural effusions in lung cancer patients.²⁹ Similar to our results, a previous study has demonstrated that after treatment with nivolumab for six months, patients with PD-L1 negative circulating tumor cells (CTCs) all obtained a clinical benefit, while patients with PD-L1 positive CTCs all had PD.³⁰

In addition to this, other mechanisms of ICI immunotherapy acquired resistance also include blockade of antigen presentation and new immune escape mutations in tumors (JAK/STAT, B2M).^{31, 32} Clinical trials of a combination of immunotherapy with metabolic inhibitors, chemotherapy, and cancer vaccines are underway to provide patients with durable disease control.³³ Choosing or combining with another immunotherapeutic agent after resistance is also an option, but the preliminary results of clinical trials have so far been unsatisfactory.³⁴ In our case,

after disease progression following immunotherapy, a combination of sintilimab with cytotoxic chemotherapy, docetaxel and the antiangiogenic drug, anlotinib, were instigated, yet the efficacy was limited.

Although the patient eventually died of disease progression, we have reason to believe that sintilimab plus bevacizumab is a potential option for NSCLC patients with oncogene drivers who progressed in targeted therapy. High expression of PD-L1 and/or immune cells infiltration might be predictive biomarkers for choosing PD1 inhibition to treat *EGFR*-mutant NSCLC, and this merits further investigation.

References

- Siegel RL, Miller KD, Jemal A. Cancer statistics, 2017. *CA Cancer J Clin* 2017; **67** (1): 7–30.
- Bray F, Ferlay J, Soerjomataram I, Siegel RL, Torre LA, Jemal A. Global cancer statistics 2018: GLOBOCAN estimates of incidence and mortality worldwide for 36 cancers in 185 countries. *CA Cancer J Clin* 2018; **68** (6): 394–424.
- Camidge DR, Pao W, Sequist LV. Acquired resistance to TKIs in solid tumours: Learning from lung cancer. *Nat Rev Clin Oncol* 2014; **11** (8): 473–81.
- Gettinger SN, Horn L, Gandhi L *et al.* Overall survival and long-term safety of nivolumab (anti-programmed death 1 antibody, BMS-936558, ONO-4538) in patients with previously treated advanced non-small-cell lung cancer. *J Clin Oncol* 2015; **33** (18): 2004–12.
- Herbst RS, Baas P, Kim DW *et al.* Pembrolizumab versus docetaxel for previously treated, PD-L1-positive, advanced non-small-cell lung cancer (KEYNOTE-010): A randomised controlled trial. *Lancet* 2016; **387** (10027): 1540–50.
- Fehrenbacher L, Spira A, Ballinger M *et al.* Atezolizumab versus docetaxel for patients with previously treated non-small-cell lung cancer (POPLAR): A multicentre, open-label, phase 2 randomised controlled trial. *Lancet* 2016; **387** (10030): 1837–46.
- Maemondo M, Inoue A, Kobayashi K *et al.* Gefitinib or chemotherapy for non-small-cell lung cancer with mutated *EGFR*. *N Engl J Med* 2010; **362** (25): 2380–8.
- Rosell R, Carcereny E, Gervais R *et al.* Erlotinib versus standard chemotherapy as first-line treatment for European patients with advanced *EGFR* mutation-positive non-small-cell lung cancer (EURTAC): A multicentre, open-label, randomised phase 3 trial. *Lancet Oncol* 2012; **13** (3): 239–46.
- Engelman JA, Janne PA. Mechanisms of acquired resistance to epidermal growth factor receptor tyrosine kinase inhibitors in non-small cell lung cancer. *Clin Cancer Res* 2008; **14** (10): 2895–9.
- Engelman JA, Zejnullahu K, Mitsudomi T. MET amplification leads to gefitinib resistance in lung cancer by activating ERBB3 signaling. *Science* 2007; **316** (5827): 1039–43.
- Kobayashi S, Boggon TJ, Dayaram T *et al.* *EGFR* mutation and resistance of non-small-cell lung cancer to gefitinib. *N Engl J Med* 2005; **352** (8): 786–92.
- Nagano T, Tachihara M, Nishimura Y. Mechanism of resistance to epidermal growth factor receptor-tyrosine kinase inhibitors and a potential treatment strategy. *Cell* 2018; **7** (11): 212.
- Bean J, Brennan C, Shih JY *et al.* MET amplification occurs with or without T790M mutations in *EGFR* mutant lung tumors with acquired resistance to gefitinib or erlotinib. *Proc Natl Acad Sci U S A* 2007; **104** (52): 20932–7.
- Yu HA, Arcila ME, Rekhtman N *et al.* Analysis of tumor specimens at the time of acquired resistance to *EGFR*-TKI therapy in 155 patients with *EGFR*-mutant lung cancers. *Clin Cancer Res* 2013; **19** (8): 2240–7.
- Planchard D, Loriot Y, André F *et al.* *EGFR*-independent mechanisms of acquired resistance to AZD9291 in *EGFR* T790M-positive NSCLC patients. *Ann Oncol* 2015; **26** (10): 2073–8.
- Zou HY, Li Q, Lee JH *et al.* An orally available small-molecule inhibitor of c-Met, PF-2341066, exhibits cytoreductive antitumor efficacy through antiproliferative and antiangiogenic mechanisms. *Cancer Res* 2007; **67** (9): 4408–17.
- Proto C, Ferrara R, Signorelli D *et al.* Choosing wisely first line immunotherapy in non-small cell lung cancer (NSCLC): What to add and what to leave out. *Cancer Treat Rev* 2019; **75**: 39–51.
- Remon J, Besse B, Soria JC. Successes and failures: What did we learn from recent first-line treatment immunotherapy trials in non-small cell lung cancer? *BMC Med* 2017; **15** (1): 55.
- Hoy SM. Sintilimab: First Global Approval. *Drugs* 2019; **79** (3): 341–6.
- Borghaei H, Paz-Ares L, Horn L *et al.* Nivolumab versus docetaxel in advanced nonsquamous non-small-cell lung cancer. *N Engl J Med* 2015; **373** (17): 1627–39.
- Rittmeyer A, Barlesi F, Waterkamp D *et al.* Atezolizumab versus docetaxel in patients with previously treated non-small-cell lung cancer (OAK): A phase 3, open-label, multicentre randomised controlled trial. *Lancet* 2017; **389** (10066): 255–65.
- Garassino MC. Durvalumab as third-line or later treatment for advanced non-small-cell lung cancer (ATLANTIC): An open-label, single-arm, phase 2 study. *Lancet Oncol* 2018; **19** (4): 521–36.
- Garber K. Promising early results for immunotherapy-antiangiogenesis combination. *J Natl Cancer Inst* 2014; **106** (11): dju392.
- Manegold C, Dingemans AMC, Gray JE *et al.* The potential of combined immunotherapy and antiangiogenesis for the synergistic treatment of advanced NSCLC. *J Thorac Oncol* 2017; **12** (2): 194–207.
- Reck M, Mok TSK, Nishio M *et al.* Atezolizumab plus bevacizumab and chemotherapy in non-small-cell lung cancer (IMpower150): Key subgroup analyses of patients with *EGFR* mutations or baseline liver metastases in a

- randomised, open-label phase 3 trial. *Lancet Respir Med* 2019; **7** (5): 387–401.
- 26 Rizvi NA, Antonia SJ, Shepherd FA *et al.* Nivolumab (anti-PD-1; BMS-936558, ONO-4538) maintenance as monotherapy or in combination with bevacizumab (BEV) for non-small cell lung cancer (NSCLC) previously treated with chemotherapy: Metastatic non-small cell lung cancer. *Int J Radiat Oncol Biol Phys* 2014; **90** (5): S32.
- 27 Herbst RS, Bendell JC, Isambert N *et al.* A phase 1 study of ramucirumab (R) plus pembrolizumab (P) in patients (pts) with advanced gastric or gastroesophageal junction (G/GEJ) adenocarcinoma, non-small cell lung cancer (NSCLC), or urothelial carcinoma (UC): Phase 1a results. *J Clin Oncol* 2016; **34** (15_suppl): 3056–6.
- 28 Zhou Z-J, Zhan P, Song Y. PD-L1 over-expression and survival in patients with non-small cell lung cancer: A meta-analysis. *Transl Lung Cancer Res* 2015; **4** (2): 203.
- 29 Prado-Garcia H, Romero-Garcia S, Puerto-Aquino A, Rumbo-Nava U. The PD-L1/PD-1 pathway promotes dysfunction, but not “exhaustion”, in tumor-responding T cells from pleural effusions in lung cancer patients. *Cancer Immunol Immunother* 2017; **66** (6): 765–76.
- 30 Nicolazzo C, Raimondi C, Mancini M *et al.* Monitoring PD-L1 positive circulating tumor cells in non-small cell lung cancer patients treated with the PD-1 inhibitor Nivolumab. *Sci Rep* 2016; **6** (1): 1–8.
- 31 Nowicki TS, Hu-Lieskovan S, Ribas A. Mechanisms of resistance to PD-1 and PD-L1 blockade. *Cancer J* 2018; **24** (1): 47–53.
- 32 Sharma P, Hu-Lieskovan S, Wargo JA, Ribas A. Primary, adaptive, and acquired resistance to cancer immunotherapy. *Cell* 2017; **168** (4): 707–23.
- 33 Jenkins RW, Barbie DA, Flaherty KT. Mechanisms of resistance to immune checkpoint inhibitors. *Br J Cancer* 2018; **118** (1): 9–16.
- 34 Saleh K, Khalifeh-Saleh N, Kourie HR. Is it possible to rechallenge with PD-1/PD-L1 inhibitors after progression. *Immunotherapy* 2018; **10** (5): 345–7.