



Case Report

Ethylmalonic encephalopathy: Clinical course and therapy response in an uncommon mild case with a severe *ETHE1* mutationMelike Ersoy^{a,*}, Valeria Tiranti^b, Massimo Zeviani^c^a Department of Pediatrics, Division of Pediatric Metabolism, Health Sciences University, Bakirkoy Dr. Sadi Konuk Research and Education Hospital, Istanbul, Turkey^b Molecular Pathogenesis of Mitochondrial Disorders Unit of Medical Genetics and Neurogenetics Fondazione IRCCS Istituto Neurologico Carlo Besta, Milan, Italy^c The Clinical School, University of Padova Department of Neurosciences Veneto Institute of Molecular Medicine Via Orus 2, Padova, Italy

ARTICLE INFO

Keywords:

ETHE1 gene

H₂S

Mild course

Therapy response

ABSTRACT

Ethylmalonic encephalopathy (EE) is a rare metabolic disorder caused by dysfunction of *ETHE1* protein, a mitochondrial dioxxygenase involved in hydrogen sulfide (H₂S) detoxification. EE is usually a fatal disease with a severe clinical course mainly associated with developmental delay and regression, recurrent petechiae, orthostatic acrocyanosis, and chronic diarrhoea. Treatment includes antioxidants, antibiotics that lower H₂S levels and antispastic medications, which are not curative. The mutations causing absence of the *ETHE1* protein, as is the case for the described patient, usually entail a severe fatal phenotype. Although there are rare reported cases with mild clinical findings, the mechanism leading to these milder cases is also unclear. Here, we describe an 11-year-old boy with an *ETHE1* gene mutation who has no neurocognitive impairment but chronic diarrhoea, which is controlled by oral medical treatment, and progressive spastic paraparesis that responded to Achilles tendon lengthening.

1. Introduction

Ethylmalonic encephalopathy (EE) (MIM #602473) is an autosomal recessive severe metabolic disorder of infancy affecting the brain, gastrointestinal tract, and peripheral vessels. The disorder is characterized by neurodevelopmental delay and regression, prominent pyramidal and extrapyramidal signs, seizures, recurrent petechiae, orthostatic acrocyanosis, and chronic diarrhoea [1]. Brain magnetic resonance imaging (MRI) shows widespread necrotic lesions in deep grey matter structures [2]. The onset and degree of severity of these symptoms vary from patient to patient, even with the same mutation, but mostly occur early in development [3].

EE is characterized by an unusual combination of biochemical findings, which include persistent lactic acidemia, elevated concentrations of C4 and C5 plasma acylcarnitine species, markedly elevated urinary excretion of ethylmalonic acid (EMA), and elevated C4–6 acylglycines, notably isobutyrylglycine and 2-methylbutyrylglycine. In 2004, the EE locus was identified by autozygosity mapping in a region

on chromosome 19, and the gene was identified and termed *ETHE1*, for Ethylmalonic Encephalopathy gene 1 [4]. *ETHE1* is a 30-kDa polypeptide located in the mitochondrial matrix, which functions as a homodimeric, Fe-containing, sulfur dioxygenase (SDO) involved in the catabolic oxidation of hydrogen sulfide (H₂S) to sulfate [5].

Low concentrations (< 125 μM) of H₂S has many physiological functions in healthy humans, including signalling between neurons, cardioprotection, heart rate regulation, vasorelaxation, angiogenesis, and antioxidant, anti-inflammatory and cytoprotective effects in the epithelium. H₂S is synthesized through cystathionine β-synthase (CBS), cystathionine γ-lyase (CSE), and 3-mercaptopyruvate sulfurtransferase (3-MST) from cysteine, and a rather relevant amount is synthesized also by intestinal bacteria (Fig. 1). Although H₂S acts in traces as a cytoprotective agent, at high concentrations, it is a powerful toxic agent that inhibits some important enzymes with antioxidative and energy-producing effects. Cytochrome c oxidase, carbonic anhydrase, and short-chain acylCoA dehydrogenase (SCAD) are the main enzymes which impairment causes clinical and laboratory findings during H₂S

Abbreviations: cIII, complex III; cIV, complex IV; CAT, cysteine aminotransferase; CBS, cystathionine β-synthase; CSE, cystathionine γ-lyase; EE, ethylmalonic encephalopathy; EMA, ethylmalonic acid; GSH, glutathione; H₂S, hydrogen sulfide; MTZ, metronidazole; NAC, N-acetylcysteine; 3-MST, 3-mercaptopyruvate sulfurtransferase; H₂SO₃, persulfide; SCAD, short-chain acyl-CoA dehydrogenase; SQR, sulfide quinone oxidoreductase; SDO, sulfur dioxygenase; SUOX, sulfite oxidase; TST, thiosulfate sulfur transferase; UQ, quinone

* Corresponding author at: Department of Pediatrics, Division of Pediatric Metabolism, Health Sciences University, Bakirkoy Dr. Sadi Konuk Research and Education Hospital, Istanbul, Turkey.

E-mail addresses: zeynepcey@hotmail.com (M. Ersoy), Valeria.Tiranti@istituto-besta.it (V. Tiranti), massimo.zeviani@unipd.it (M. Zeviani).

<https://doi.org/10.1016/j.ymgmr.2020.100641>

Received 1 July 2020; Received in revised form 15 August 2020; Accepted 16 August 2020

2214-4269/© 2020 The Author(s). Published by Elsevier Inc. This is an open access article under the CC BY-NC-ND license (<http://creativecommons.org/licenses/by-nc-nd/4.0/>).

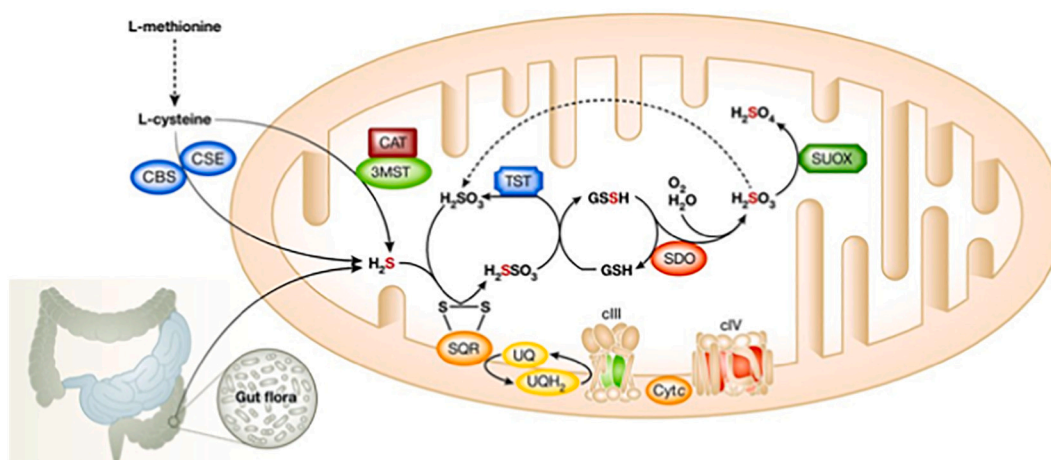


Fig. 1. The pathways of H_2S synthesis and removal (CBS: cystathionine β -synthase; CSE: cystathionine γ -lyase; CAT: cysteine aminotransferase; 3-MST: 3-mercaptopyruvate sulfurtransferase; SQR: sulfide quinone oxidoreductase; SDO/ETHE1: sulfite dioxygenase; SUOX: sulfite oxidase; TST: thiosulfate sulfur transferase; GSH: glutathione; UQ: quinone; cIII: complex III; cIV: complex IV).

intoxication [6].

A major mitochondrial enzymatic pathway is responsible for the removal of H_2S from tissues. H_2S is initially fixed by a membrane-bound sulfide quinone oxidoreductase (SQR). The electrons extracted from H_2S enter the respiratory chain at the level of the quinone pool (UQH/UQ), are then transferred to complex III (cIII), and are finally fixed by cytochrome *c* oxidase (complex IV, cIV) to molecular oxygen with the formation of water. Sulfur dioxygenase (SDO/ETHE1), present as an Fe-binding dimer in the mitochondrial matrix, oxidizes the sulfur atom of H_2S fixed in a persulfide moiety (H_2SSO_3) to sulfite (SO_3^{2-}) in a reaction that includes molecular oxygen and water (Fig. 1). Sulfite is further oxidized into sulfate (SO_4) by sulfite oxidase [4]. These systems are likely to have an important physiological function in maintaining the low tissue concentrations of H_2S . Impaired activity of ETHE1-SDO leads to the accumulation of H_2S in critical tissues, which inhibits short-chain acyl-CoA dehydrogenase (SCAD), therefore accounting for EMA aciduria and high levels of C4 and C5 acylcarnitines; COX deficiency causes diffuse hypoxic tissue damage and SCAD deficiency causes elevated lactate and EMA in plasma, both resulting in severe oxidative stress and faulty bioenergetics [5]. H_2S directly damages endothelial cells and alters the vessel tone determining vasodilation, thus accounting for the petechiae, orthostatic acrocyanosis and mucosal damage with chronic diarrhoea.

2. Case report

An 11-year-old boy was referred to the hospital with spastic paraparesis and intractable diarrhoea from 5 years of age. He was the first child of consanguineous parents with an unremarkable family history. He was born at term, following an uneventful pregnancy and delivery. His birth weight was 3250 g (50th–75th percentile), and his height was 53 cm (75th–90th percentile). He was breastfed until six months after birth. During weaning, he began complaining of nutrition therapy-resistant diarrhoea. Endoscopy and colonoscopy were performed considering food allergies or malabsorption syndromes. Both were normal. He began walking at 14 months of age. He was assessed at the orthopaedics unit because of frequent falls, and metabolic tests were suggested.

Upon physical examination, the only finding was spasticity in the lower limbs. The patient had normal neurodevelopmental progression. Plasma lactate was within normal levels. Metabolic tests showed slightly elevated C5-carnitine (0.39 μ mol/L; n.v. 0.31–0.01) in plasma and elevated ethylmalonic acid (EMA) (46 mmol/mol creatinine; n.v. < 8.4), isovaleryl glycine (19 mmol/mol creatinine; n.v. 0), and

isobutyryl glycine (10 mmol/mol creatinine; n.v. < 1,6). When mild clinical findings and these metabolites were evaluated together, they suggested SCAD deficiency. Brain MR imaging was performed to reconcile the unexpected lower limb spasticity with SCAD deficiency. Brain MRI and spectroscopy results were normal. The rest of the biochemical and metabolic work-up was unremarkable. EMG did not indicate muscle or nerve involvement. We repeated the analyses because the EMA excretion was rather low compared to canonical EE and obtained the same metabolic profile. For a conclusive diagnosis, mutation analysis revealed homozygosity for a c.3G > T (p.Met-1-Ile-) mutation in the *ETHE1* gene. *ETHE1* gene sequence analysis was done with MiSeq next generation sequencing (NGS) platform (Illumina, San Diego, CA, USA). Genomic DNA isolation was done according to the manufacturer's standard procedure with Anatolia magnetic bead kit (Anatolia, Turkey). Since this mutation is responsible for the severe phenotype, parental genetics and functional tests were performed to confirm the diagnosis. Western blot analysis of ETHE1 indicated that the protein was virtually absent in mutant skin fibroblasts (Fig. 2) showing only a very faint band. We can't exclude the presence of a shorter ETHE1 protein starting at a second methionine at position 28, which could not be visualised with the western blot conditions utilized.

The patient received oral metronidazole (MTZ) and *N*-acetylcysteine (NAC) for 6 months. This regimen caused abdominal pain and

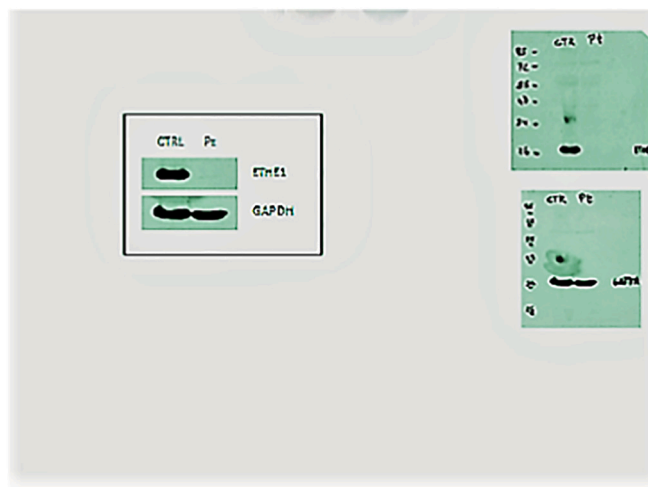


Fig. 2. Virtual absence of ETHE1 protein in the case according to western blotting.

Table 1
Clinical and laboratory findings for the case.

	0 days	1 month	6 months	1 year	2 years	3 years	4 years
		NAC-MTZ	NAC-MTZ	NAC-MTZ CoQ10-B2	NAC-MTZ CoQ10-B2	NAC-MTZ CoQ10-B2	NAC-MTZ CoQ10-B2 operation
Clinic							
Spastic paraparesis	++	++	++	++	+++	+++	+
Diarrhoea (times/day)	15-20	15	10	4	4	3	2
Laboratory							
ethylmalonic acid (U)†	46	36	10	23	31	28	19
n.v. < 8.4*							
isovaleryl glycine (U)	19	16	16	3	1.5	2.4	–
n.v. 0*							
isobutyryl glycine (U)	10	8.4	6.6	4.1	2	3.5	0.12
n.v. < 1.6*							
methylsuccinic acid (U)	1.6	0.4	–	0.8	1	0.16	–
n.v. < 4.4*							
2-methylbutyrylglycine (U)	0.8	–	–	–	0.4	0.21	–
n.v. 0*							
C4-Carnitine (P)‡	1.26	1.08	1.15	1.2	1.2	1.25	1
n.v. 0-1.3**							
C5-Carnitine (P)	0.39	0.32	0.29	0.27	0.3	0.31	0.25
n.v. 0.31- 0.01**							
Lactate (P)	14	15	12	13	15	17	11
n.v. 4.5-19.8***							

*mmol/mol creatinine; **µmol/L; ***mg/dl; ‡ plasma; † urine

discomfort. He was then given a supplementary probiotic agent (*Saccharomyces boulardii* CNCM I-745®) at the dosage 5 billion colony-forming units that limited the number of bowel discharges. To prevent oxidative damage due to H₂S, coenzyme Q10 and riboflavin therapy were added to the therapeutic protocol. As a result of all these treatments, some clinical and biochemical benefits were observed as the EMA levels decreased. He never experienced a metabolic attack or encephalopathic coma (Table 1). Diarrhoea was under control, with marked amelioration of his quality of life, but spastic paraparesis progressively worsened. Lengthening of the Achilles tendons allowed him to walk without support, although muscle weakness persisted. Muscle strength was supported by regular physiotherapy, in addition to medical treatment. In the 2-year follow-up after the operation, rapid growth in height caused some deterioration in walking. However, this deterioration did not prevent him from walking without support. Currently, he has normal cognitive development with an IQ of 104, with good proficiency.

3. Discussion

EE is a metabolic disorder characterized by an unusual combination of specific and unique clinical phenotypes and biochemical features, leading to characteristic psychomotor retardation, chronic mucoid diarrhoea and relapsing pectichiae with acrocyanosis. The biochemical profile includes lactic acidemia, elevated plasma C4 and C5 acylcarnitines as well as C4–6 acylglycines and markedly increased urinary excretion of ethylmalonic acid. EE is caused by homozygous or compound heterozygous mutations in the *ETHE1* gene, which is located on chromosome 19q13 and encodes a mitochondrial matrix sulfur dioxygenase. The association of *ETHE1* gene mutations with the disease was reported by Tiranti et al. [4] in 2004. c.3G > T (p.Met-1-Ile-) mutation in the *ETHE1* gene has also been identified by the tiranti as a severe mutation [5]. Since then, there has been an increase in the number of associated mutations and reported cases. No genotype-phenotype correlations have been shown with biallelic pathogenic variants to date. Clinical heterogeneity exists even in cases with the same mutation [7]. Despite the fact that the majority of typical cases have severe findings, some atypical individuals have also been reported [7,8]. It is also known that there are a few cases with mild atypical findings, whose diagnosis is often delayed until adolescence or adulthood [9].

Western blot analysis of the *ETHE1* protein indicated that some of the missense mutations are associated with the presence of the protein, suggesting that the mutant amino acid impairs catalytic function [5]. Concentrations of EMA and other short-chain acylglycines were found to be lower in these mild cases than in severe cases, but it has been shown that metabolites increase rapidly in blood and urine during acute attacks. While it is understandable that there are mild clinical findings due to the presence of some detectable *ETHE1* protein, it is difficult to explain the cases where the protein is absent, as in our case. The mutation in our case is a known loss-of-function change usually associated with a severe phenotype [4]. Accordingly, in our patient fibroblast cell line, the *ETHE1* protein was undetectable by western blot analysis. Thus, additional genetic factors, including the activation of alternative pathways for the disposal of H₂S, such as that involvement of cysteine dioxygenase, must play a compensatory role in this case. It is hard to explain why the clinical phenotype and biochemical findings are so mild when there is no synthesized *ETHE1* protein. Although these three systems are said to have an equally important function in maintaining physiologically relevant tissue concentrations of H₂S, the pathways may not be equally effective in each person. Interactions among antioxidant mechanisms have been reported in H₂S detoxification [10].

Individual genetic differences, such as modifying genes or suppressor genes, may be other or additional influencing factors. The possibility of significant environmental factors or alternative non-*ETHE1*-related genetic factors influencing mutant gene expression must be considered. Another explanation is that the amount of *ETHE1*-protein produced can differ among tissues. The important difference in this case compared with other cases is that there was no pathology detected by brain MRI, whereas in other cases with milder symptoms, typical signs of brain disease were observed by MRI.

Treatment is mostly supportive, including antioxidants, antispastic medications, muscle relaxants, and antiepileptic drugs [11,12]. Among these drugs, NAC and metronidazole are prominent in treatment due to their H₂S-reducing effects. NAC is a cell-permeable precursor of glutathione (GSH), an abundant compound in mitochondria, where it acts as one of the physiological acceptors of the sulfur atom of H₂S via SQR [10,13,14]. Metronidazole is an antibiotic widely used to combat anaerobic infections by reducing the bacterial load in the large intestine, which is a major source of H₂S [15]. The beneficial effects of both agents have been shown in most of the affected cases [10,14], but to

date, curative treatment has not been achieved. Antioxidant cocktails have been tested, but their benefit is controversial [16] despite the observation that an untargeted metabolic approach on EE fibroblasts demonstrated an alteration of the redox state [17]. In our case, we observed laboratory and clinical benefits of such a cocktail when given in addition to NAC and metronidazole. Gene therapy and liver transplant, reported in some publications, are not routine treatments, and their effects encouraging, but the numbers of cases is insufficient to prove unequivocally their efficacy [18,19]. In addition to chronic treatments, cases that benefit from continuous dialysis renal replacement therapy (CRRT) in acute metabolic coma have been reported [9]. The Achilles tendon lengthening operation, performed on our patient to reduce the progressive lower limb spasticity that occurred despite medical treatments, improved his quality of life. This interventional method is suggested to improve the quality of life, especially in cases with good neurocognitive development.

4. Conclusion

Ethylmalonic encephalopathy can occasionally occur with a late onset and mild clinical symptoms, in addition to the severe clinical presentation that is more frequently observed. The metabolic profile may be subtle and thus create difficulty in the diagnosis of these mild cases. It can be argued that the response of these cases to antioxidant treatments is more obvious than that of more severe cases, and their prognosis is better. Our case allowed us to evaluate and discuss an unusually mild presentation of ethylmalonic encephalopathy, despite the absence of ETHE1 protein in functional tests.

Author contributions

ME: Data analysis and interpretation and planning and drafting of most of the article.

VT: Data analysis and interpretation and article contribution and revision.

MZ: Data analysis and interpretation and planning and drafting of the article.

Funding

This work did not receive any funding.

Patient consent

The patient and his parents provided informed consent for publication of this case report.

Ethical standards

The authors declare that the experiments complied with the current laws of Canada, the country in which they were performed.

Declaration of Competing Interest

The authors have no competing interests to declare.

References

- [1] X. Chen, L. Han, H. Yao, Novel compound heterozygous variants of ETHE1 causing ethylmalonic encephalopathy in a Chinese patient: A case report, *Front. Genet.* 11 (2020) 341, <https://doi.org/10.3389/fgene.2020.00341>.
- [2] A.Z. Tavasoli, P. Rostami, M.R. Ashrafi, P. Karimzadeh, Neurological and vascular manifestations of ethylmalonic encephalopathy, *Iran J. Child Neurol.* 11 (2017) 57–60.
- [3] N. Pigeon, P.M. Campeau, D. Cyr, B. Lemieux, J.T.R. Clarke, Clinical heterogeneity in ethylmalonic encephalopathy, *J. Child Neurol.* 24 (2009) 991–996, <https://doi.org/10.1177/0883073808331359>.
- [4] V. Tiranti, P. D'Adamo, E. Briem, G. Ferrari, R. Miner, E. Lamantea, H. Mandel, P. Balestri, M.T. Garcia-Silva, B. Vollmer, P. Rinaldo, S.H. Hahn, J. Leonard, S. Rahman, C. Dionisi-Vici, B. Garavaglia, P. Gasparini, M. Zeviani, Ethylmalonic encephalopathy is caused by mutations in ETHE1, a gene encoding a mitochondrial matrix protein, *Am. J. Hum. Genet.* 74 (2004) 239–252, <https://doi.org/10.1086/381653>.
- [5] V. Tiranti, ETHE1 mutations are specific to ethylmalonic encephalopathy, *J. Med. Genet.* 43 (2006) 340–346, <https://doi.org/10.1136/jmg.2005.036210>.
- [6] I. Di Meo, C. Lamperti, V. Tiranti, Mitochondrial diseases caused by toxic compound accumulation: from etiopathology to therapeutic approaches, *EMBO Mol. Med.* 7 (2015) 1257–1266, <https://doi.org/10.15252/emmm.201505040>.
- [7] M. Di Rocco, U. Caruso, E. Briem, A. Rossi, A.E.M. Allegri, D. Buzzi, V. Tiranti, A case of ethylmalonic encephalopathy with atypical clinical and biochemical presentation, *Mol. Genet. Metab.* 89 (2006) 395–397, <https://doi.org/10.1016/j.ymgme.2006.05.010>.
- [8] L.C. Heberle, A.A. Al Tawari, D.G. Ramadan, J.K. Ibrahim, Ethylmalonic encephalopathy—report of two cases, *Brain Dev.* 28 (2006) 329–331, <https://doi.org/10.1016/j.braindev.2005.10.005>.
- [9] T.M. Kitzler, I.R. Gupta, B. Osterman, C. Poulin, Y. Trakadis, P.J. Waters, D.C. Buhas, Acute and chronic management in an atypical case of ethylmalonic encephalopathy, *JIMD Rep.* 45 (2018) 57–63, https://doi.org/10.1007/8904_2018_136.
- [10] M. Luna-Sánchez, A. Hidalgo-Gutiérrez, T.M. Hildebrandt, J. Chaves-Serrano, E. Barriocanal-Casado, Á. Santos-Fandila, M. Romero, R.K.A. Sayed, J. Duarte, H. Prokisch, M. Schuelke, F. Distelmaier, G. Escames, D. Acuña-Castroviejo, L.C. López, CoQ deficiency causes disruption of mitochondrial sulfide oxidation, a new pathomechanism associated with this syndrome, *EMBO Mol. Med.* 9 (2016) 78–95, <https://doi.org/10.15252/emmm.201606345>.
- [11] C. Viscomi, A.B. Burlina, I. Dweikat, M. Savoiano, C. Lamperti, T. Hildebrandt, V. Tiranti, M. Zeviani, Combined treatment with oral metronidazole and N-acetylcysteine is effective in ethylmalonic encephalopathy, *Nat. Med.* 16 (2010) 869–871, <https://doi.org/10.1038/nm.2188>.
- [12] R. Miner, M. Rimoldi, A.B. Burlina, S. Koskull, C. Perletti, B. Heese, U. von Döbeln, P. Mereghetti, I. Di Meo, F. Invernizzi, M. Zeviani, G. Uziel, V. Tiranti, Identification of new mutations in the ETHE1 gene in a cohort of 14 patients presenting with ethylmalonic encephalopathy, *J. Med. Genet.* 45 (2008) 473–478, <https://doi.org/10.1136/jmg.2008.058271>.
- [13] C. Garone, C. Viscomi, Towards a therapy for mitochondrial disease: an update, *Biochem. Soc. Trans.* 46 (2018) 1247–1261, <https://doi.org/10.1042/bst20180134>.
- [14] V. Tiranti, M. Zeviani, Altered sulfide (H₂S) metabolism in ethylmalonic encephalopathy, *Cold Spring Harb. Perspect. Biol.* 5 (2013) a011437, <https://doi.org/10.1101/cshperspect.a011437>.
- [15] J. Samuelson, Why metronidazole is active against both bacteria and parasites, *Antimicrob. Agents Chemother.* 43 (1999) 1533–1541, <https://doi.org/10.1128/aac.43.7.1533>.
- [16] G. Kleiner, E. Barca, M. Ziosi, V. Emmanuele, Y. Xu, A. Hidalgo-Gutierrez, C. Qiao, S. Tadesse, E. Area-Gomez, L.C. Lopez, C.M. Quinzii, CoQ10 supplementation rescues nephrotic syndrome through normalization of H₂S oxidation pathway, *Biochim. Biophys. Acta Mol. basis Dis.* 1864 (2018) 3708–3722, <https://doi.org/10.1016/j.bbadis.2018.09.002>.
- [17] N. Sahebkhari, C.B. Nielsen, M. Johannsen, J. Palmfeldt, Untargeted metabolomics analysis reveals a link between ETHE1-mediated disruptive redox state and altered metabolic regulation, *J. Proteome Res.* 15 (5) (2016 May 6) 1630–1638.
- [18] I. Di Meo, A. Auricchio, C. Lamperti, A. Burlina, C. Viscomi, M. Zeviani, Effective AAV-mediated gene therapy in a mouse model of ethylmalonic encephalopathy, *EMBO Mol. Med.* 4 (2012) 1008–1014, <https://doi.org/10.1002/emmm.201201433>.
- [19] C. Dionisi-Vici, D. Diodato, G. Torre, S. Picca, R. Pariente, S. Giuseppe Picardo, I. Di Meo, C. Rizzo, V. Tiranti, M. Zeviani, J.D.V. De Goyet, Liver transplant in ethylmalonic encephalopathy: a new treatment for an otherwise fatal disease, *Brain* 139 (2016) 1045–1051, <https://doi.org/10.1093/brain/aww013>.