

# Therapy results of pericallosal aneurysms: A retrospective unicenter study

Cornelius Deuschl,<sup>1</sup> Marvin Darkwah Oppong,<sup>2</sup> Hanna Styczen,<sup>1</sup> Lisa Markhardt,<sup>1</sup> Karsten Wrede,<sup>2</sup> Ramazan Jabbarli,<sup>2</sup> Ulrich Sure,<sup>2</sup> Alexander Radbruch,<sup>1</sup> Michael Forsting,<sup>1</sup> Isabel Wanke,<sup>1,3</sup> Christoph Mönninghoff,<sup>4</sup>

<sup>1</sup>Institute for Diagnostic and Interventional Radiology and Neuroradiology, University Hospital Essen, Essen, Germany; <sup>2</sup>Clinic for Neurosurgery, University Hospital Essen, Essen, Germany; <sup>3</sup>Center for Neuroradiology, Clinic Hirslanden, Zurich, Switzerland; <sup>4</sup>Clinic for Neuroradiology, Clemenshospital Muenster, Germany

## Abstract

This retrospective study aims to compare treatment results of ruptured and unruptured pericallosal artery aneurysms (PAAs) regarding patient outcome and aneurysm recurrence after endovascular treatment (EVT) and neurosurgical treatment (NT). A total of 67 patients with PAA were admitted to our hospital, 44 patients with subarachnoidal hemorrhage (SAH) due to a ruptured PAA and 23 patients with unruptured PAA. The radiographic features of PAA were collected from pre-treatment digital subtraction angiography. In addition, demographic, clinical and radiographic parameters of all patients were recorded. Outcome was measured based on the modified Rankin scale (mRS) at 6 months after admission (favorable mRS score, 0-2 vs unfavorable mRS score, 3-6). Overall 46 patients underwent EVT and 21 patients NT. Six months after discharge 24 patients with SAH had a favorable outcome (mRS 0-2) and 16 patients an unfavorable outcome (mRS 3-6). Mortality rate of patients with SAH was 9.1% (4/44). Overall aneurysm recurrence was treated in 13 % of patients in the EVT cohort (6/46), whereas patients treated with NT had no recurrence. All patients with unruptured PAA had a favorable outcome. EVT and NT of PAA show comparable good results, although aneurysm recurrence occurs more often after EVT.

## Introduction

Aneurysms of the pericallosal artery (PA) tend to rupture more frequently and cause higher morbidity and mortality rates compared to other supratentorially located aneurysms.<sup>1-3</sup>

Generally, neurosurgical treatment (NT) and endovascular treatment (EVT) are the therapeutic options and are both challenging due to the anatomical localization, small vessel size, and limited microsurgical or endovascular access.<sup>4</sup>

The aim of this study was to compare treatment results of ruptured and unruptured PAAs regarding treatment modality, patient outcome and aneurysm recurrence.

## Materials and Methods

All patient with ruptured and unruptured PAA treated at our neurovascular center in a 15 years period (1998 to 2013) were enrolled in this retrospective study. A total of 64 patients with PAA were admitted to our university hospital and treated either by EVT or NT. The patients records and imaging data were retrospectively analyzed by use of the clinical information system and picture archiving and communication system (PACS). Radiologic data were retrospectively reviewed by two board certified neuroradiologists by consensus reading. The ethics approval for this study was provided by the local ethics committee (13-5580-BO).

Patients of all ages were included, if the presence of a PAA was proven by computed tomography angiography (CTA) and/or magnetic resonance angiography (MRA) and digital subtraction angiography (DSA). Patient characteristics comprised age, sex, PAA aneurysm size, presence of additional aneurysms in other locations, neurosurgical, endovascular or conservative aneurysm treatment. Complications of SAH (early hydrocephalus, vasospasm, and cerebral ischemia), and the presence of intracranial hemorrhage were registered from the CT scan and patients records.

PAAs were treated after interdisciplinary consensus of neurosurgeons and interventional neuroradiologists regarding the anatomical features of each aneurysm. Clipping or endovascular treatment were performed as soon as possible after SAH. Applied treatment methods were clipping and coil-embolization. All neuroradiological and neurosurgical procedures were performed under endotracheal intubation and general anesthesia. Single microcatheter coiling was performed in all endovascular

Correspondence: Cornelius Deuschl, Institute of Diagnostic and Interventional Radiology and Neuroradiology University Hospital Essen, Germany.  
E-mail: cornelius.deuschl@uk-essen.de

Key words: Pericallosal artery aneurysm; recurrence; endovascular therapy; neurosurgical therapy.

Conflict of interests: The authors declare no conflict of interests.

Availability of data and materials: All data are available within this manuscript

Ethics approval and consent to participate: All procedures performed in the studies involving human participants were in accordance with the ethical standards of the institutional and/or national research committee and with the 1964 Helsinki Declaration and its later amendments or comparable ethical standards. Informed consent was obtained from all individual participants included in the study.

Received for publication: 20 April 2020.

Revision received: 19 July 2020.

Accepted for publication: 30 July 2020.

This work is licensed under a Creative Commons Attribution NonCommercial 4.0 License (CC BY-NC 4.0).

©Copyright: the Author(s), 2020  
Licensee PAGEPress, Italy  
Clinics and Practice 2020; 10:1257  
doi:10.4081/cp.2020.1257

treated cases.

Treatment results of neurosurgical clipping were assessed by DSA a few days after operations. Results of EVT were judged on the grading system proposed by Raymond-Roy *et al.*:<sup>5</sup> i) Grade I: Complete obliteration; ii) Grade II: Residual neck; iii) Grade III: Residual aneurysm.

Results of NT were judged using the grading system by Sindou *et al.*:<sup>6</sup> i) Grade I: Less than 50% of neck size remnant; ii) Grade II: More than 50% of neck size remnant; iii) Grade III: Residual lobe of multilobulated aneurysm; iv) Grade IV: Residual sack that is less than 75% of original aneurysm size; v) Grade V: Residual sack that is more than 75% of original aneurysm size.

The results of EVT were monitored by magnetic resonance imaging or CTA during in-patient stay and 6 months after discharge.

Patient outcome was specified with regard to the modified Rankin Scale (mRS) at discharge and 6 months after discharge from hospital. Data were collected from the clinical information system based on neurosurgical follow-up visits, repetitive hospital stays, and discharge letters.

All patients with aneurysmal SAH were daily monitored for vasospasm with transcranial Doppler sonography at the neurosurgical intensive care unit and received oral nimodipine for 3 weeks from the day of ictus. In case of increased flow velocity (>120 cm/s) of intubated patients or extubated patients with delayed neurological deterioration a CT scan was performed prior to DSA to rule out infarctions. If necessary, DSA was performed daily in the vasospasm phase after SAH to confirm severe cerebral vasospasm and to treat them with intraarterial Nimodipine infusions.

## Results

A total of 1827 patients with cerebral aneurysms were admitted to our hospital over 15 years. Overall 67 patients with saccular PAA were treated in this time period in our neurovascular center. The total study population included 44 (65.7%) patients with ruptured PAAs and 23 (34.3%) patients with unruptured PAAs. The gender ratio of our PAA study population showed a female predominance (f=56, m=10).

Treatment decisions in all 67 patients were made in interdisciplinary consensus of neurosurgeons and interventional neuroradiologists based on findings of DSA. In the subgroup of ruptured aneurysms 28 patients were treated with EVT and 16 patients with NT. Within the subgroup of unruptured PAA 17 were treated with EVT and 6 with NT (Tables 1 and 2).

### Outcome of ruptured pericallosal artery aneurysms

At the time of discharge 34 patients had an unfavorable outcome (mRS 3-6) due to major neurological deficits, whereas 10 patients had a favorable outcome (mRS 0-2) (Table 3 and Figure 1). At 6-month follow-up 16 of the 44 patients had an unfavorable outcome (mRS 3-6), whereas 24 patients had a favorable outcome (mRS 0-2). A total of four patients died (9.1%) after therapy (Table 4).

### Outcome of unruptured pericallosal artery aneurysms

At the time of discharge 6 patients had an unfavorable outcome (mRS 3-6), whereas 17 patients had a favorable outcome (mRS 0-2) (Table 3). At 6-month follow-up 22 of the 23 patients had a favorable outcome (mRS 0-2), one patient with an unfavorable outcome (mRS 3-6) at 6-month follow-up already had a mRS of 5 before treatment due to a stroke 5 years before (Table 4).

## Therapy results and recurrence of pericallosal artery aneurysms

Immediately after NT or EVT complete aneurysm occlusion was achieved in 59/67 (88.1%) patients and near-complete occlusion in 8 (11.9%) patients (Table 5). Two patients (n=21) treated with NT were classified as Sindou II. All patients treated with NT had no change of aneurysm appearance in the follow-up imaging 6 months after therapy.

Within the subgroup of EVT patients, 6/46 patients had a residual neck after therapy. Six months after discharge within the subgroup of EVT imaging revealed recurrence of PAA in 6/46 patients (Raymond Roy II) and 4/46 patients (Raymond Roy III) (Table 6). In 6 patients with aneurysm recurrence was treated. Five cases were treated by recoiling, and one patient by neurosurgical clipping. No rebleeding occurred in all patients.

## Discussion

This study provides evidence that EVT and NT should be regarded as equivalent methods in the treatment of PAA. However, both modalities showed clear advantages and disadvantages. EVT treated patients

had a better mRS at discharge compared to NT, although at the 6 month-control no significant difference between treatment modalities was found. Patients treated with EVT had a better mRS at discharge but tend to have aneurysm recurrence more often than patients treated with NT. Since micro-

**Table 1. Treatment of ruptured aneurysms.**

(n=44)	Ruptured PAA	
	EVT	NT
Treatment modality	28	16
Recoiling	3	0
Reclipping	1	0
Mortality	2	2

PAA, pericallosal artery aneurysms; EVT, endovascular treatment; NT, neurosurgical treatment.

**Table 2. Treatment of unruptured aneurysms.**

(n=23)	Unruptured PAA	
	EVT	NT
Treatment modality	18	5
Recoiling	2	0
Reclipping	0	0
Mortality	0	0

PAA, pericallosal artery aneurysms; EVT, endovascular treatment; NT, neurosurgical treatment.

**Table 3. Treatment results after therapy at discharge.**

Ruptured PAA mRS	At discharge		6 months after discharge	
	EVT	NT	EVT	NT
Favorable outcome (0-2)	8	2	17	7
Unfavorable outcome (3-6)	20	14	9	7

PAA, pericallosal artery aneurysms; EVT, endovascular treatment; NT, neurosurgical treatment.

**Table 4. Treatment results 6 months after therapy.**

Unruptured PAA mRS	At discharge		6 months after discharge	
	EVT	NT	EVT	NT
Favorable outcome (0-2)	15	2	18	4
Unfavorable outcome (3-6)	3	3	0	1

PAA, pericallosal artery aneurysms; EVT, endovascular treatment; NT, neurosurgical treatment.

**Table 5. Aneurysm occlusion after therapy.**

Aneurysm occlusion after therapy	EVT	NT	Total
Raymond Roy I	40		59
Raymond Roy II	6		8
Raymond Roy III	0		0
Sindou I		19	
Sindou II		2	
Sindou III		0	
Sindou IV		0	
n.a.	0	0	0
Total	46	21	67

surgical and endovascular therapeutic options reach comparable good outcome results, interdisciplinary treatment decisions should be based on the aneurysm morphology, the need for decompression of larger intracranial hemorrhage, and the individual operative experience of neurosurgeons and neurointerventionalists to guarantee a prompt aneurysm occlusion.

In our study population deterioration from SAH after PAA rupture caused a mortality rate of 9.1%, which is comparable or lower than reported in other studies.<sup>4,7</sup> Six months after discharge an independent daily living activity level (mRS score 0-2) was achieved by 46/67 (68.7%) patients without statistically significant difference between both treatment groups.

After early occlusion of the ruptured aneurysm to prevent rebleeding interdisciplinary therapy is focused on SAH to treat or avoid subsequent complications like hydrocephalus, vasospasm, and cerebral infarction. Delayed cerebral ischemia from vasospasm is a decisive cause of morbidity in patients with aneurysmal SAH independent of successful occlusion of the ruptured intracranial aneurysm.<sup>4,8,9</sup> Cerebral infarction not related to vasospasm is also known as an independent risk factor for poor outcome.<sup>4,9</sup> The burden of blood at the time of SAH has been identified as the most predictive factor of cerebral vasospasm especially in ruptured PAAs.<sup>8,10</sup> In a prospective randomized controlled trial including 250 patients with different ruptured intracranial aneurysms, aneurysms of the posterior circulation and pericallosal arteries had the worst outcome in 1-year follow up.<sup>8</sup> Poor admission status, cerebral infarction, and smoking were described as risk factors for an unfavorable outcome in ruptured PAAs. Our retrospective monocentric study of 67 PAA patients, including 44 patients with ruptured PAAs, shows equally good therapy results (mRS 0-2) in 54.5% (24/44) of patients with ruptured aneurysms and EVT or NT six month after discharge. Dinc *et al.* found a favorable outcome in 17 (53.1%) of 32 patients with ruptured PAA.<sup>4</sup> In both studies neither NT nor EVT were superior for treatment results between the groups. A series of 132 surgically managed aneurysms showed a favorable outcome in 71 (53.8%) cases with 6 or more month follow up.<sup>7</sup> A summary of nine studies on endovascular treated ruptured PAAs reported a favorable outcome (mRS  $\leq$  2) in 164/219 (74.9%, range 53% - 100%) cases.<sup>11</sup>

### Treatment options

Deeply located in the interhemispheric fissure PAAs mostly afford a frontal interhemispheric approach.<sup>12</sup> The small neuro-

surgical access and the high rate of intraoperative hemorrhage are combined with a relatively high surgical morbidity ranging from 0 to 25%.<sup>13-15</sup> Giant or complex pericallosal aneurysms may be treated microsurgically by bypass graft and/or a bypass from one to the other pericallosal artery followed by trapping of the aneurysm.<sup>16</sup>

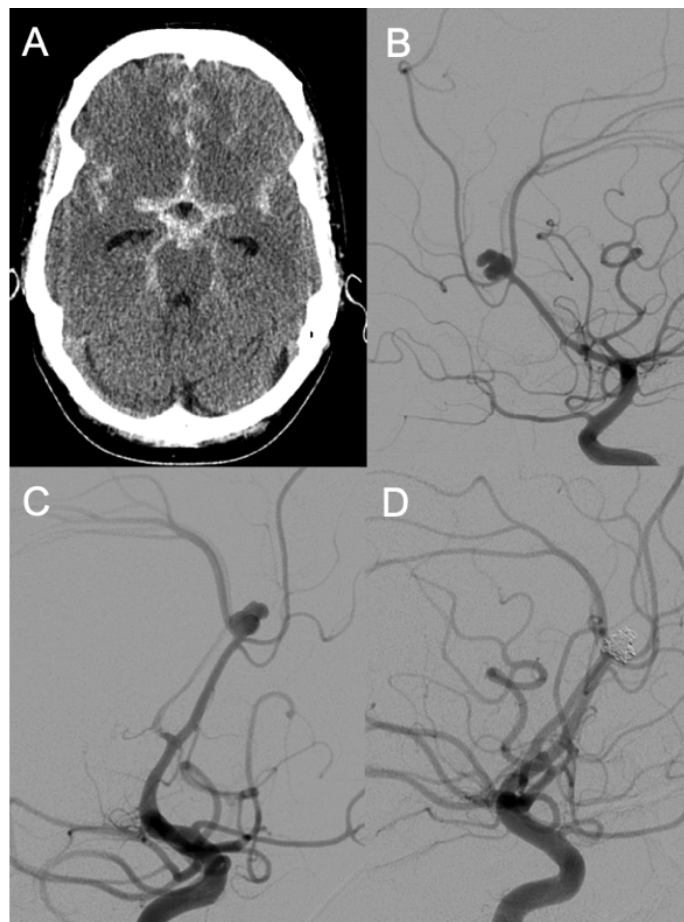
Endovascular treatment of PAAs with

detachable platinum coils has proven to be a reliable technique and alternative to surgical clipping.<sup>17,18</sup> Especially the intraprocedural intraarterial infusion of the calcium channel blocker nimodipine is an adjunctive technique for the endovascular treatment in the early vasospasm phase.<sup>19</sup> The dome-to-neck ratio is a decisive parameter for interdisciplinary treatment decisions of intracra-

**Table 6. Aneurysm occlusion after therapy 6 months after therapy.**

Aneurysm occlusion after therapy	EVT	NT	Total
Raymond Roy I	30		45
Raymond Roy II	6		8
Raymond Roy III	4		4
Sindou I		15	
Sindou II		2	
Sindou III		0	
Sindou IV		0	
n.a.	6	4	10
<b>Total</b>	<b>46</b>	<b>21</b>	<b>67</b>

EVT, endovascular treatment; NT, neurosurgical treatment.



**Figure 1. 41-year old female patient with subarachnoid hemorrhage on contrast-computed tomography (A) due to an irregular, ruptured pericallosal aneurysm in digital subtraction angiography; (B, C) with complete occlusion after endovascular treatment (D).**

nial aneurysms. A high dome-to-neck ratio is more applicable for EVT, whereas aneurysms with a low ratio may preferably be treated by neurosurgical clipping.<sup>4</sup>

In the postprocedural phase repeated or even continuous intraarterial nimodipine infusions are suitable to relieve affected patients from symptomatic cerebrovascular vasospasm and to reduce the risk of delayed cerebral infarction.<sup>20,21</sup> Smaller endovascular devices offer new treatment options for small and wide-necked aneurysms in peripheral locations. Stent-assisted coiling is challenging in pericallosal arteries due to the small vessel diameter and peripheral location of most PAAs.<sup>22</sup>

### Limitations

The crucial issue of this retrospective analysis is the lower quality/completeness of data compared with prospective data storage.

### Conclusions

In this retrospective monocentric study EVT and NT reach comparable good treatment results and favorable patient outcome of ruptured and not ruptured PAAs.

### References

- de Sousa AA, Dantas FL, de Cardoso GT, Costa BS. Distal anterior cerebral artery aneurysms. *Surg Neurol* 1999;52:128-35.
- Jackson A, Fitzgerald JB, Hartley RW, et al. CT appearances of hematomas in the corpus callosum in patients with subarachnoid hemorrhage. *Neuroradiol* 1993;35:420-3.
- Lehecka M, Dashti R, Lehto H, et al. Distal anterior cerebral artery aneurysms. *Acta Neurochir Suppl* 2010;107:15-26.
- Dinc N, Lescher S, Quick-Weller J, et al. Outcome, prognostic factors, and follow-up results after subarachnoid hemorrhage from pericallosal artery aneurysms. *World Neurosurg* 2017;99:566-71.
- Roy D, Milot G, Raymond J. Endovascular treatment of unruptured aneurysms. *Stroke* 2001;32:1998-2004.
- Sindou M, Acevedo JC, Turjman F. Aneurysmal remnants after microsurgical clipping: classification and results from a prospective angiographic study (in a consecutive series of 305 operated intracranial aneurysms). *Acta Neurochir (Wien)* 1998;140:1153-9.
- Shukla D, Bhat DI, Srinivas D, et al. Microsurgical treatment of distal anterior cerebral artery aneurysms: A 25-year institutional experience. *Neurol India* 2016;64:1204-9.
- Abla AA, Wilson DA, Williamson RW, et al. The relationship between ruptured aneurysm location, subarachnoid hemorrhage clot thickness, and incidence of radiographic or symptomatic vasospasm in patients enrolled in a prospective randomized controlled trial. *J Neurosurg* 2014;120:391-7.
- Vergouwen MD, Ilodigwe D, Macdonald RL. Cerebral infarction after subarachnoid hemorrhage contributes to poor outcome by vasospasm-dependent and -independent effects. *Stroke* 2011;42:924-9.
- Harrod CG, Bendok BR, Batjer HH. Prediction of cerebral vasospasm in patients presenting with aneurysmal subarachnoid hemorrhage: a review. *Neurosurg* 2005;56:633-54.
- Ko JK, Kim HS, Choi HJ, et al. Endovascular treatment of ruptured pericallosal artery aneurysms. *J Korean Neurosurg Soc* 2015;58:197-204.
- Monroy-Sosa A, Nathal E, Rhoton AL, Jr. Operative management of distal anterior cerebral artery aneurysms through a mini anterior interhemispheric approach. *World Neurosurg* 2017;108:519-28.
- Chalif DJ, Weinberg JS. Surgical treatment of aneurysms of the anterior cerebral artery. *Neurosurg Clin N Am* 1998;9:797-821.
- Martines F, Blundo C, Chiappetta F. Surgical treatment of the distal anterior cerebral artery aneurysms. *J Neurosurg Sci* 1996;40:189-94.
- Oshiro S, Tsugu H, Sakamoto S, et al. Ruptured aneurysm of the distal anterior cerebral artery: clinical features and surgical strategies. *Neurol Med Chir (Tokyo)* 2007;47:159-63.
- Navarro R, Chao K, Steinberg GK. Microsurgical management of distal anterior cerebral artery aneurysms: from basic to complex, a video review of four cases. *Acta Neurochir (Wien)* 2013;155:2115-9.
- Menovsky T, van Rooij WJ, Sluzewski M, Wijnalda D. Coiling of ruptured pericallosal artery aneurysms. *Neurosurg* 2002;50:11-4.
- Nguyen TN, Raymond J, Roy D, et al. Endovascular treatment of pericallosal aneurysms. *J Neurosurg* 2007;107:973-6.
- Kostron H, Twerdy K, Grunert V. The calcium entry blocker nimodipine improves the quality of life of patients operated on for cerebral aneurysms. A 5-year follow-up analysis. *Neurochirurgia (Stuttg)* 1988;31:150-3.
- Pala A, Schneider M, Brand C, et al. The evolution of invasive cerebral vasospasm treatment in patients with spontaneous subarachnoid hemorrhage and delayed cerebral ischemia-continuous selective intracarotid nimodipine therapy in awake patients without sedation. *Neurosurg Rev* 2018;42:463-9.
- Ditz C, Neumann A, Wojak J, et al. Repeated endovascular treatments in patients with recurrent cerebral vasospasms after subarachnoid hemorrhage: a worthwhile strategy? *World Neurosurg* 2018;112:e791-8.
- Lee K, Park H, Park I, et al. Y-configuration stent-assisted coil embolization for wide-necked intracranial bifurcation aneurysms. *J Cerebrovasc Endovasc Neurosurg* 2016;18:355-62.