



NOTE

Pathology

Inclusion body hepatitis caused by *Aviadenovirus* in a tropical screech owl (*Megascops choliba*)

Tetsuya KOMATSU¹⁾, Takashi KUBO¹⁾, Rena KITOU¹⁾, Naomi KAWAMOTO¹⁾, Masaji MASE²⁾, Yu YAMAMOTO³⁾ and Tomoyuki SHIBAHARA^{3,4)*}¹⁾Aichi Prefectural Chuo Livestock Hygiene Service Center, 1-306 Jizono, Miaicho, Okazaki, Aichi 444-0805, Japan²⁾Division of Viral Disease and Epidemiology Research, National Institute of Animal Health, National Agriculture and Food Research Organization (NARO), 3-1-5 Kannondai, Tsukuba, Ibaraki 305-0856, Japan³⁾Division of Pathology and Pathophysiology, National Institute of Animal Health, National Agriculture and Food Research Organization (NARO), 3-1-5 Kannondai, Tsukuba, Ibaraki 305-0856, Japan⁴⁾Department of Veterinary Science, Graduate School of Life and Environmental Sciences, Osaka Prefecture University, 1-58 Rinku-oraikita, Izumisano, Osaka 598-8531, Japan*J. Vet. Med. Sci.*

82(9): 1341–1345, 2020

doi: 10.1292/jvms.20-0316

Received: 26 May 2020

Accepted: 7 July 2020

Advanced Epub:

17 July 2020

ABSTRACT. In 2016, tropical screech owl (*Megascops choliba*) (Tso) chicks were suddenly found dead in a Japanese breeding facility. We autopsied a 9-day-old Tso and discovered white spots scattered on the liver surface. Multifocal necrosis was diffused, and macrophages had infiltrated the necrotic hepatic lesions. Hepatocytes contained numerous intranuclear inclusion bodies. Immunohistochemical staining detected *Adenovirus* antigen only in the liver. Next, PCR and sequencing (LC536616) identified Tso *Adenovirus* (TsoAd). Basic Local Alignment Search Tool (BLAST) and phylogenetic analyzes suggested TsoAd is an owl *Aviadenovirus*. Our study contributes to an improved understanding of infectious disease among captive raptors.

KEY WORDS: *Aviadenovirus*, inclusion body hepatitis, Japan, tropical screech owl

Adenoviruses infect numerous species of mammals, birds, reptiles, and amphibians [6]. Adenoviridae is divided into five groups, with *Aviadenovirus* and *Atadenovirus* being infectious-disease agents in birds [6].

Aviadenovirus is a major cause of inclusion body hepatitis [12], gizzard erosion, and ulceration [4] in chickens. Inclusion body hepatitis has high mortality [9], and outbreaks have been reported worldwide [19], including in Japan [17]. Although inclusion body hepatitis caused by *Aviadenovirus* infection has been observed in birds other than chicken, including turkey, duck [26], racing pigeon [8], and Gambel's quail [1], it is limited in raptors, except in falcon [2, 15, 20, 21, 23].

The tropical screech owl (*Megascops choliba*) is a common raptor occasionally kept as a pet. Endemic to South America, pet screech owls are typically imported to Japan, although some are bred domestically. Although this species is widespread, we know little regarding infectious diseases that affect them, especially in breeding facilities.

In this study, we report the detection of inclusion body hepatitis in the tropical screech owl, caused by an owl *Aviadenovirus*. Our research aims to improve current understanding of owl infectious disease in captive conditions, using pathological and phylogenetic data.

From March to May 2016, numerous tropical screech owls (age range 1–20 days) in a breeding facility were presented anorexia, vomiting, diarrhea, and sudden mortality. Owls were treated with toltrazuril as an anticoccidial agent and manually fed. Most birds died within one week. The facility houses other raptors, such as Eurasian eagle owl (*Bubo bubo*), rock eagle owl (*Bubo bengalensis*), barn owl (*Tyto alba*), and several falcon species. Most were imported, with some individuals used for breeding. Juvenile screech owls were housed in independent cages that caretakers disinfected with chlorine once a day. Their diet was a commercial feed comprising minced chicks of chicken and Japanese quail.

A 9-day-old tropical screech owl that died suddenly without external symptoms was moved to Aichi Prefectural Chuo Livestock Hygiene Service Center by a veterinary hospital and was autopsied (Fig. 1a). We observed white spots scattered across the liver surface (Fig. 1b) and hemorrhaging in the gizzard. No other gross lesions were detected. Intestinal contents did not contain coccidian oocysts.

At autopsy, the liver, kidney, heart, lung, pancreas, trachea, stomach, intestine, and brain tissue samples were fixed in 10% neutral-buffered formalin. Fixed tissues were then embedded in paraffin wax, sectioned (~3 μm), then stained with hematoxylin

*Correspondence to: Shibahara, T.: tshiba@affrc.go.jp

©2020 The Japanese Society of Veterinary Science



This is an open-access article distributed under the terms of the Creative Commons Attribution Non-Commercial No Derivatives (by-nc-nd) License. (CC-BY-NC-ND 4.0: <https://creativecommons.org/licenses/by-nc-nd/4.0/>)

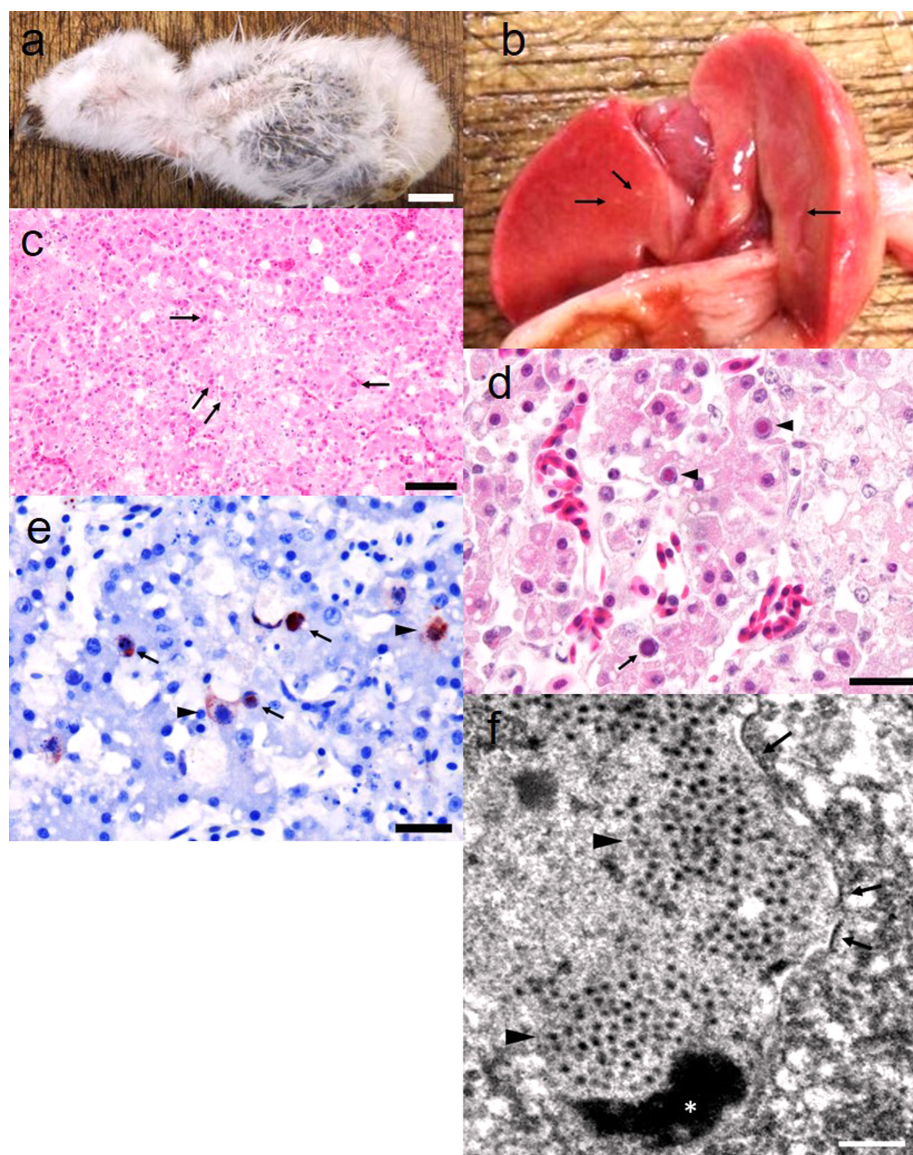


Fig. 1. a) Nine-day-old tropical screech owl chick, found dead in the breeding facility. Bar=1 cm. b) White spots were scattered on the liver surface (arrows). c) Hepatic necrosis. Intranuclear inclusion bodies were detected in surrounding necrotic area (arrows). Hematoxylin and eosin (H&E) staining. Bar=50 μ m. d) Full basophilic (arrow) and Cowdry type A eosinophilic (arrowheads) inclusion bodies in the liver. H&E staining. Bar=20 μ m. e) Immunohistochemical staining detected numerous positive reactions in hepatocyte nuclei (arrows) and cytoplasm of infiltrated macrophages (arrowheads). Bar=20 μ m. f) Transmission electron microscopy of TsoAd. Nonenveloped isometric viral particles (~90 nm in size) were arrayed in hepatocyte nuclei (arrowheads). The nuclear membrane was deformed (arrows). *Chromatin. Bar=500 nm.

and eosin (H&E) for histological examination. Gram staining was also performed on the liver, kidney, and gizzard sections. For immunohistochemical examination, formalin-fixed paraffin-embedded (FFPE) sections of the liver, gizzard, pancreas, and intestines were deparaffinized and incubated with 3% hydrogen peroxide in methanol solution to suppress endogenous peroxidase activity. Antigen retrieval was conducted using 0.1% actinase E solution in phosphate buffered saline at 37°C for 20 min. After adding 10% normal goat serum to block non-specific reactions, sections were incubated with rabbit anti-*Aviadenovirus* antibody [18] for 1 hr. Sections were incubated with secondary antibody (Histofine Simple Stain MAX-PO Multi; Nichirei Bioscience Inc., Tokyo, Japan) for 30 min at room temperature, then treated with aminoethyl carbazole (AEC) substrate solution (Histofine Simple Stain AEC solution; Nichirei Bioscience Inc.), also at room temperature. Finally, sections were counterstained with hematoxylin.

To identify the virus associated with intranuclear inclusion bodies, formalin-fixed liver tissue was observed under transmission electron microscopy (TEM) (JEM-1400 Flash; JOEL, Tokyo, Japan), as described previously [14].

Histopathological examination revealed that multifocal necrosis was randomly diffused in the liver (Fig. 1c). Macrophages had infiltrated into necrotic lesions, and we also observed a few granulomatous necrotizing lesions. Hepatocytes in the surrounding necrotic areas contained numerous full, basophilic, and Cowdry type A, eosinophilic intranuclear inclusion bodies (Fig. 1d). Kidney

interstitium exhibited infiltration of lymphocytes and a few macrophages. Gizzard surface displayed hemorrhaging and heterophil infiltration. Gram staining revealed a few gram-positive bacteria on the surface of the gizzard although no bacteria were detected in the liver and kidney.

Immunohistochemical staining revealed positive reactions in hepatocyte nuclei and infiltrated macrophage cytoplasm (Fig. 1e). We did not observe reactions in other tissues.

TEM observation revealed that hepatocyte nuclei had deformed membranes and contained nonenveloped isometric viral particles of approximately 90 nm in size (Fig. 1f).

Next, we conducted PCR on FFPE sections to investigate viruses associated with inclusion body hepatitis. Genomic DNA was extracted from liver sections using the QIAamp DNA FFPE Tissue kit (Qiagen GmbH, Hilden, Germany), following manufacturer protocol. Primers used targeted those encoding hexon [11], DNA-dependent *Adenovirus* DNA polymerase [25], and *Herpesvirus* DNA polymerase [24]; only *Adenovirus* DNA polymerase was amplified (516 bp). Amplicons of the first degenerate PCR were sequenced. Basic Local Alignment Search Tool (BLAST) searches of the National Center for Biotechnology Information (NCBI) revealed that partial nucleotide and amino acid sequences exhibited the highest similarity with those of fowl *Aviadenovirus* E (accession number: MK572855) (74.61%) and fowl *Aviadenovirus* A (accession number: APP94056) (86.63%). This result implies that the tropical screech owl *Adenovirus* (TsoAd) that we detected possibly represents a novel *Aviadenovirus* because the novelty threshold for an *Aviadenovirus* is a 5–15% sequence gap in the DNA-dependent DNA polymerase amino acid sequence [5]. However, the full-length sequence of DNA polymerase, genome organization, cross-neutralization, and other characteristics should be investigated for greater certainty [5]. The TsoAd sequence was deposited to the DNA Data Bank of Japan (accession number: LC536616).

We performed a phylogenetic analysis of the TsoAd amino acid sequence with the other aviadenoviruses. Sequences included were those of fowl, goose, duck, psittacine, pigeon, and owl adenoviruses, with egg drop syndrome virus set as an outgroup. Multiple alignments were performed in MEGA version 7.0, using Clustal W. All candidate sequences were retrieved from the NCBI nucleotide database. A neighbor-joining phylogenetic tree was constructed in MEGA 7. The TsoAd amino acid sequence was classified as an *Aviadenovirus* and is closely related to barn owl *Adenovirus* (Fig. 2).

These results confirmed *Aviadenovirus* infection in the dead specimen and provides an explanation for the outbreak of inclusion body hepatitis. Another recent study had also detected novel *Adenovirus* in tropical screech owls, but classified it as *Atadenovirus* and used fecal samples of owls without clinical symptoms [7]. Therefore, our findings are the first report of *Aviadenovirus* infection with clinical symptoms in the tropical screech owl. To the best of our knowledge, *Aviadenovirus* infection in an owl is limited [27]. Among a captive breeding colony of taita falcons that experienced an *Aviadenovirus* outbreak, adult females had started laying eggs before dying [2]. Pathogenicity of *Aviadenovirus* against chickens differed across strains [10] and age [16]. In our study,

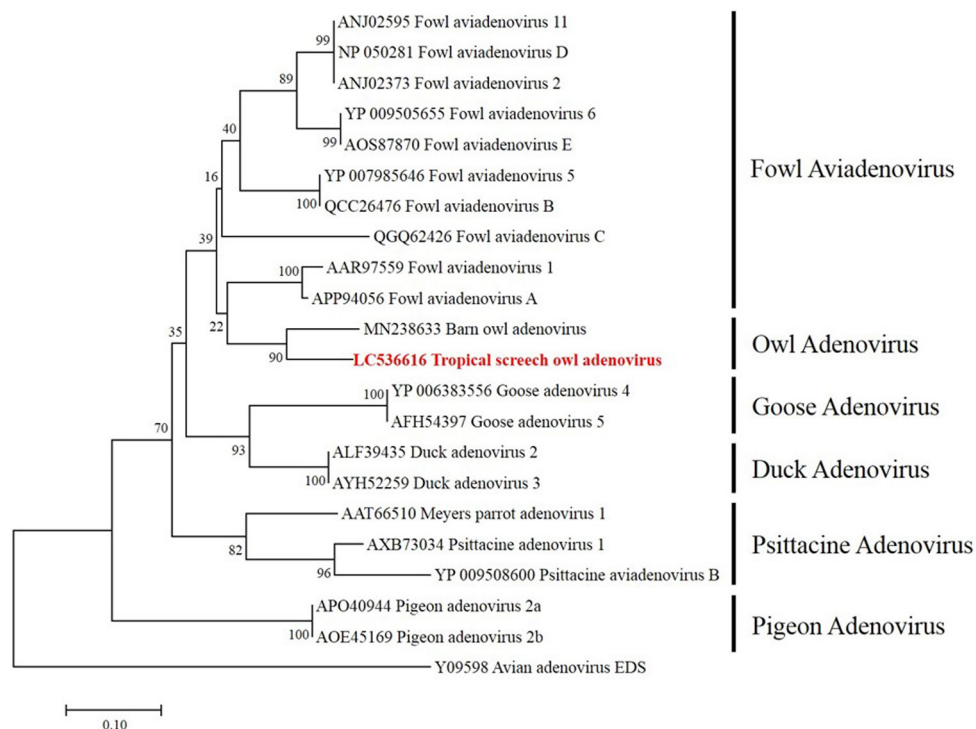


Fig. 2. Phylogenetic tree based on partial adenoviral DNA-dependent DNA polymerase amino acid sequences. The scale bar represents genetic distances among strains. Egg drop syndrome (EDS) virus (accession number: Y09598) was the outgroup.

characteristic symptoms were diarrhea, sudden death, and high mortality. Our observations imply that the disease is highly virulent, as owls were probably too young to express other symptoms before dying.

Multifocal necrosis was diffused widely in the liver. We detected inclusion bodies mainly around, rather than in, necrotic lesions. Immunohistochemical staining revealed that *Adenovirus* antigens were present only in the liver. This was not the case for other birds; infected taita falcons exhibited inclusion bodies or lesions in the liver, spleen [2, 23], and kidneys [2], while chickens had lesions in pancreatic acinar cells [13] and small-intestine epithelial cells [17]. In addition, despite being infected with the same *Aviadenovirus* infection, broiler and layer chickens differed in clinical symptoms and mortality rates [13]. This variation in lesion appearance may be partly attributable to our specimen's rapid death, which may have prevented viral spread throughout the rest of the body. To verify this hypothesis, we require more research using other viral strains and owls of different ages.

We could not identify the source of *Aviadenovirus* infection. We initially thought the virus may have been introduced via the feed (containing minced chicken and quail), because owls were maintained in separate cages that are frequently disinfected with chlorine. However, BLAST and phylogenetic analysis indicated that the detected *Aviadenovirus* was different from chicken *Aviadenovirus*. Although chickens and quails do not appear susceptible to infection from falcon-derived *Aviadenovirus* [20], cross-species transmission between chickens and falcons has been documented [15]. We used the hexon gene [11] to compare our owl *Aviadenovirus* with strains isolated in Japan [12], but this PCR was unsuccessful, possibly due to the influence of formalin fixing [3, 22].

Although phylogenetic analysis indicated that TsoAd was close to barn owl *Adenovirus*, barn owls housed in the same facility did not express any symptoms. Some other owls and falcons were also housed in this facility, however, we were not able to investigate whether these raptors had adenoviruses or not. A previous study reported that wild and captive peregrine falcons presented high seropositivity rates for falcon *Adenovirus* (80% and 100%) and that they act as a primary reservoir for the virus [20]. Similarly, we suspect that imported barn owls or the other raptors may be subclinical carriers of adenoviruses. To clarify the mechanisms of cross-species transmission among tropical screech owl, chicken, and quail in Japan, we recommend conducting molecular epidemiological studies using DNA polymerase region and next-generation sequencing technology in addition to using hexon region [12].

In conclusion, we identified an owl *Aviadenovirus* that caused an outbreak of inclusion body hepatitis in captive tropical screech owls. Few reports are available regarding *Adenovirus* infection in this raptor species, despite its popularity as a companion animal. Our study provides important insight on diseases in tropical screech owls that should benefit both veterinarians and raptor breeders.

ACKNOWLEDGMENTS. We thank Dr. N. Tanimura for advice on the manuscript, as well as Mr. M. Kobayashi and Ms. M. Shimada for histopathological assistance.

REFERENCES

- Bradley, G. A., Shupe, M. R., Reggiardo, C., Noon, T. H., Lozano-Alarcon, F. and Bicknell, E. J. 1994. Inclusion body hepatitis in Gambel's quail (*Callipepla gambelii*). *J. Wildl. Dis.* **30**: 281–284. [Medline] [CrossRef]
- Dean, J., Latimer, K. S., Oaks, J. L., Schrenzel, M., Redig, P. T. and Wünschmann, A. 2006. Falcon adenovirus infection in breeding Taita falcons (*Falco fasciinucha*). *J. Vet. Diagn. Invest.* **18**: 282–286. [Medline] [CrossRef]
- Feldman, M. Y. 1973. Reactions of nucleic acids and nucleoproteins with formaldehyde. *Prog. Nucleic Acid Res. Mol. Biol.* **13**: 1–49. [Medline] [CrossRef]
- Gjevre, A. G., Kaldhusdal, M. and Eriksen, G. S. 2013. Gizzard erosion and ulceration syndrome in chickens and turkeys: a review of causal or predisposing factors. *Avian Pathol.* **42**: 297–303. [Medline] [CrossRef]
- Harrach, B., Benko, M., Both, G. W., Brown, M., Davison, A. J., Echavarría, M., Hess, M., Jones, M. S., Kajon, A., Lehmkuhl, H. D., Mautner, V., Mittal, S. K. and Wadell, G. 2011. Family adenoviridae. pp. 125–141. *In: Virus Taxonomy, 9th Report of the International Committee on Taxonomy of Viruses* (King, A. M. Q., Lefkowitz, E., Adams, M. J. and Carstens, E. B. eds.), Elsevier, San Diego.
- Harrach, B., Tarján, Z. L. and Benkő, M. 2019. Adenoviruses across the animal kingdom: a walk in the zoo. *FEBS Lett.* **593**: 3660–3673. [Medline] [CrossRef]
- Jejesky de Oliveira, A. P., Valdetaro Rangel, M. C. Z., Z Vidovszky, M., Rossi, J. L. Jr., Vicentini, F., Harrach, B. and L Kaján, G. 2020. Identification of two novel adenoviruses in smooth-billed ani and tropical screech owl. *PLoS One* **15**: e0229415. [Medline] [CrossRef]
- Ketterer, P. J., Timmins, B. J., Prior, H. C. and Dingle, J. G. 1992. Inclusion body hepatitis associated with an adenovirus in racing pigeons in Australia. *Aust. Vet. J.* **69**: 90–91. [Medline] [CrossRef]
- Li, L., Wang, J., Chen, P., Zhang, S., Sun, J. and Yuan, W. 2018. Pathogenicity and molecular characterization of a fowl adenovirus 4 isolated from chicken associated with IBH and HPS in China. *BMC Vet. Res.* **14**: 400. [Medline] [CrossRef]
- Liu, Y., Wan, W., Gao, D., Li, Y., Yang, X., Liu, H., Yao, H., Chen, L., Wang, C. and Zhao, J. 2016. Genetic characterization of novel fowl aviadenovirus 4 isolates from outbreaks of hepatitis-hydropericardium syndrome in broiler chickens in China. *Emerg. Microbes Infect.* **5**: e117. [Medline] [CrossRef]
- Mase, M., Mitake, H., Inoue, T. and Imada, T. 2009. Identification of group I-III avian adenovirus by PCR coupled with direct sequencing of the hexon gene. *J. Vet. Med. Sci.* **71**: 1239–1242. [Medline] [CrossRef]
- Mase, M., Nakamura, K. and Minami, F. 2012. Fowl adenoviruses isolated from chickens with inclusion body hepatitis in Japan, 2009–2010. *J. Vet. Med. Sci.* **74**: 1087–1089. [Medline] [CrossRef]
- Matos, M., Grafl, B., Liebhart, D. and Hess, M. 2016. The outcome of experimentally induced inclusion body hepatitis (IBH) by fowl aviadenoviruses (FAdVs) is crucially influenced by the genetic background of the host. *Vet. Res.* **47**: 69. [Medline] [CrossRef]
- Matsubayashi, M., Murakoshi, N., Komatsu, T., Tokoro, M., Haritani, M. and Shibahara, T. 2015. Genetic identification of *Entamoeba polecki* subtype 3 from pigs in Japan and characterisation of its pathogenic role in ulcerative colitis. *Infect. Genet. Evol.* **36**: 8–14. [Medline] [CrossRef]
- Mohamed, M. H. A., El-Sabagh, I. M., Abdelaziz, A. M., Al-Ali, A. M., Alramadan, M., Lebda, M. A., Ibrahim, A. M. and Al-Ankari, A. S. 2018.

- Molecular characterization of fowl aviadenoviruses species D and E associated with inclusion body hepatitis in chickens and falcons indicates possible cross-species transmission. *Avian Pathol.* **47**: 384–390. [Medline] [CrossRef]
16. Nakamura, K., Mase, M., Yamaguchi, S. and Yuasa, N. 2000. Induction of hydropericardium in one-day-old specific-pathogen-free chicks by adenoviruses from inclusion body hepatitis. *Avian Dis.* **44**: 192–196. [Medline] [CrossRef]
 17. Nakamura, K., Mase, M., Yamamoto, Y., Takizawa, K., Kabeya, M., Wakuda, T., Matsuda, M., Chikuba, T., Yamamoto, Y., Ohyama, T., Takahashi, K., Sato, N., Akiyama, N., Honma, H. and Imai, K. 2011. Inclusion body hepatitis caused by fowl adenovirus in broiler chickens in Japan, 2009–2010. *Avian Dis.* **55**: 719–723. [Medline] [CrossRef]
 18. Nakamura, K., Shoyama, T., Mase, M., Imada, T. and Yamada, M. 2003. Reproduction of hydropericardium syndrome in three-week-old cyclophosphamide-treated specific-pathogen-free chickens by adenoviruses from inclusion body hepatitis. *Avian Dis.* **47**: 169–174. [Medline] [CrossRef]
 19. Niu, Y., Sun, Q., Zhang, G., Sun, W., Liu, X., Xiao, Y., Shang, Y. and Liu, S. 2018. Epidemiological investigation of outbreaks of fowl adenovirus infections in commercial chickens in China. *Transbound. Emerg. Dis.* **65**: e121–e126. [Medline] [CrossRef]
 20. Oaks, J. L., Schrenzel, M., Rideout, B. and Sandfort, C. 2005. Isolation and epidemiology of falcon adenovirus. *J. Clin. Microbiol.* **43**: 3414–3420. [Medline] [CrossRef]
 21. Schrenzel, M., Oaks, J. L., Rotstein, D., Maalouf, G., Snook, E., Sandfort, C. and Rideout, B. 2005. Characterization of a new species of adenovirus in falcons. *J. Clin. Microbiol.* **43**: 3402–3413. [Medline] [CrossRef]
 22. Sikorsky, J. A., Primerano, D. A., Fenger, T. W. and Denvir, J. 2007. DNA damage reduces Taq DNA polymerase fidelity and PCR amplification efficiency. *Biochem. Biophys. Res. Commun.* **355**: 431–437. [Medline] [CrossRef]
 23. Tomaszewski, E. K. and Phalen, D. N. 2007. Falcon adenovirus in an American kestrel (*Falco sparverius*). *J. Avian Med. Surg.* **21**: 135–139. [Medline] [CrossRef]
 24. VanDevanter, D. R., Warrenner, P., Bennett, L., Schultz, E. R., Coulter, S., Garber, R. L. and Rose, T. M. 1996. Detection and analysis of diverse herpesviral species by consensus primer PCR. *J. Clin. Microbiol.* **34**: 1666–1671. [Medline] [CrossRef]
 25. Wellehan, J. F., Johnson, A. J., Harrach, B., Benkő, M., Pessier, A. P., Johnson, C. M., Garner, M. M., Childress, A. and Jacobson, E. R. 2004. Detection and analysis of six lizard adenoviruses by consensus primer PCR provides further evidence of a reptilian origin for the atadenoviruses. *J. Virol.* **78**: 13366–13369. [Medline] [CrossRef]
 26. Yugo, D. M., Hauck, R., Shivaprasad, H. L. and Meng, X. J. 2016. Hepatitis virus infections in poultry. *Avian Dis.* **60**: 576–588. [Medline] [CrossRef]
 27. Zsivanovits, P., Monks, D. J., Forbes, N. A., Ursu, K., Raue, R. and Benkő, M. 2006. Presumptive identification of a novel adenovirus in a Harris Hawk (*Parabuteo unicinctus*), a Bengal Eagle Owl (*Bubo bengalensis*), and a Verreaux's Eagle Owl (*Bubo lacteus*). *J. Avian Med. Surg.* **20**: 105–112. [CrossRef]