



Since January 2020 Elsevier has created a COVID-19 resource centre with free information in English and Mandarin on the novel coronavirus COVID-19. The COVID-19 resource centre is hosted on Elsevier Connect, the company's public news and information website.

Elsevier hereby grants permission to make all its COVID-19-related research that is available on the COVID-19 resource centre - including this research content - immediately available in PubMed Central and other publicly funded repositories, such as the WHO COVID database with rights for unrestricted research re-use and analyses in any form or by any means with acknowledgement of the original source. These permissions are granted for free by Elsevier for as long as the COVID-19 resource centre remains active.



Multicenter Clinicopathologic Correlation of Kidney Biopsies Performed in COVID-19 Patients Presenting With Acute Kidney Injury or Proteinuria

Shreeram Akilesh, Cynthia C. Nast, Michifumi Yamashita, Kammi Henriksen, Vivek Charu, Megan L. Troxell, Neeraja Kambham, Erika Bracamonte, Donald Houghton, Naila I. Ahmed, Chyi Chyi Chong, Bijin Thajudeen, Shehzad Rehman, Firas Khoury, Jonathan E. Zuckerman, Jeremy Gitomer, Parthassarathy C. Raguram, Shanza Mujeeb, Ulrike Schwarze, M. Brendan Shannon, Iris De Castro, Charles E. Alpers, Behzad Najafian, Roberto F. Nicosia, Nicole K. Andeen, and Kelly D. Smith

Rationale & Objective: Kidney biopsy data inform us about pathologic processes associated with infection with severe acute respiratory syndrome coronavirus 2 (SARS-CoV-2). We conducted a multicenter evaluation of kidney biopsy findings in living patients to identify various kidney disease pathology findings in patients with coronavirus disease 2019 (COVID-19) and their association with SARS-CoV-2 infection.

Study Design: Case series.

Setting & Participants: We identified 14 native and 3 transplant kidney biopsies performed for cause in patients with documented recent or concurrent SARS-CoV-2 infection treated at 7 large hospital systems in the United States.

Observations: Men and women were equally represented in this case series, with a higher proportion of Black (n = 8) and Hispanic (n = 5) patients. All 17 patients had SARS-CoV-2 infection confirmed by reverse transcriptase–polymerase chain reaction, but only 3 presented with severe COVID-19 symptoms. Acute kidney injury (n = 15) and proteinuria (n = 11) were the most common

indications for biopsy and these symptoms developed concurrently or within 1 week of COVID-19 symptoms in all patients. Acute tubular injury (n = 14), collapsing glomerulopathy (n = 7), and endothelial injury/thrombotic microangiopathy (n = 6) were the most common histologic findings. 2 of the 3 transplant recipients developed active antibody-mediated rejection weeks after COVID-19. 8 patients required dialysis, but others improved with conservative management.

Limitations: Small study size and short clinical follow-up.

Conclusions: Cases of even symptomatically mild COVID-19 were accompanied by acute kidney injury and/or heavy proteinuria that prompted a diagnostic kidney biopsy. Although acute tubular injury was seen among most of them, uncommon pathology such as collapsing glomerulopathy and acute endothelial injury were detected, and most of these patients progressed to irreversible kidney injury and dialysis.

Visual Abstract online

Complete author and article information provided before references.

Correspondence to S. Akilesh (shreeram@uw.edu) or N.K. Andeen (andeen@ohsu.edu) or K.D. Smith (kelsmith@uw.edu)

Am J Kidney Dis. 77(1):82-93. Published online October 10, 2020.

doi: [10.1053/j.ajkd.2020.10.001](https://doi.org/10.1053/j.ajkd.2020.10.001)

© 2020 by the National Kidney Foundation, Inc.

Since its identification, severe acute respiratory syndrome coronavirus 2 (SARS-CoV-2) and its resulting disease, coronavirus disease 2019 (COVID-19), has grown into a worldwide pandemic with devastating medical and financial impacts. Though the primary targets of injury are the lungs and airways, heart and kidney involvement are common and portend a worse prognosis.¹⁻⁴ Pre-existing kidney disease or diseases known to contribute to decreased kidney function such as hypertension and diabetes are risk factors for an aggressive clinical course.^{2,5-8} De novo kidney manifestations in SARS-CoV-2–infected patients include acute kidney injury (AKI), proteinuria, and hematuria.^{3,9} Various mechanisms have been proposed for kidney injury, including ischemia related to severe pulmonary injury, high levels of circulating proinflammatory cytokines (cytokine storm) and bradykinin, and possible direct infection of the renal parenchyma by SARS-CoV-2. However, very few patients with COVID-19 undergo kidney biopsy to identify the pathologic processes affecting the kidney because management of

pulmonary disease and infection precautions often take precedence. Therefore, we aggregated kidney biopsies performed on patients with documented COVID-19 from multiple large medical centers in the United States to identify clinicopathologic correlations of decreased kidney function.

Methods

Identification of Kidney Biopsies of Patients With COVID-19

A request for collaboration and case contribution was sent to renal pathologists at large medical centers. When cases were identified at each institution, biopsy and electronic health record review were performed locally as human subjects exempt research with the approval of waiver of consent by local institutional review boards (IRBs): University of Washington (6 cases; STUDY00010368), Oregon Health Sciences University (2 cases;

PLAIN-LANGUAGE SUMMARY

Acute kidney injury (AKI) is common in patients with coronavirus disease 2019 (COVID-19). We undertook a multicenter study to evaluate kidney biopsy findings in living patients to identify different kidney disease pathology in patients with COVID-19. Most patients in this case series developed AKI concurrent with mild COVID-19 symptoms. AKI and proteinuria were the most common indications for biopsy. Both common and rare pathologic processes such as acute tubular injury, collapsing glomerulopathy, and endothelial injury/thrombotic microangiopathy were the most common histologic findings. Two of the 3 transplant recipients developed active antibody-mediated rejection weeks after COVID-19. These data suggest that even symptomatically mild COVID-19 can be associated with AKI and/or heavy proteinuria and may warrant diagnostic kidney biopsy.

STUDY00017467), Cedars-Sinai Medical Center (3 cases; STUDY00000903); University of Chicago (1 case; IRB20-1260), University of Arizona (2 cases; protocol 2005664752), Stanford University (1 case; IRB 43782), and University of California Los Angeles (2 cases; IRB 20-001635).

APOL1 Genotyping

For case 1, genetic testing was performed at GeneDx Laboratories (Gaithersburg, MD). For case 6, genomic DNA was isolated from ethylenediaminetetraacetic acid–anticoagulated blood with the PureLink Genomic DNA kit (ThermoFisher Scientific). The region of the apolipoprotein L1 gene (*APOL1*) containing the G1 and G2 risk alleles was amplified by polymerase chain reaction (PCR) and the product was sequenced by automated sequencing in 2 reactions. Sequence data were analyzed by the most recent version of the Mutation Surveyor software (SoftGenetics).

Immunohistochemistry and In Situ Hybridization for SARS-CoV-2

For SARS-CoV-2 nucleocapsid protein, formalin-fixed paraffin-embedded tissue sections were immunohistochemically stained with an antibody to SARS-CoV nucleocapsid protein (catalogue #40143-T62; Sinobiological) at 1:2,000 dilution on Leica Bond III instruments after 20 minutes of antigen retrieval with epitope retrieval 2, followed by Leica Bond Polymer Refine detection chemistry. For RNA in situ hybridization, formalin-fixed paraffin-embedded tissue was stained with a SARS-CoV-2 probe (ACD Bio RNAScope Probe - V-nCoV2019-S; catalogue #848568) on Leica platform with 3,3'-diaminobenzidine, protease retrieval, and hybridization per manufacturer protocols.

Results

Clinical Presentation

We identified 17 patients (8 men and 9 women) with SARS-CoV-2 infection confirmed by reverse transcriptase (RT)-PCR. Clinical characteristics of patients in this case series are summarized in Table 1. Additional information for baseline laboratory and clinical parameters, medication use, and pathologic findings are detailed in Table S1. Median age of our patients was 54 (range, 34-77) years. The case series predominantly consisted of Black (n = 8; 47%) and Hispanic (n = 5; 29%) patients. Most patients had only mild COVID-19–related symptoms such as upper respiratory tract infection, cough, fatigue, or low-grade fevers, though at least 3 required hospitalization for hypoxic pulmonary failure. The patients presented with markers of decreased kidney function or kidney damage affecting either their native (n = 14) or in allograft (n = 3) kidneys. AKI (n = 15; median serum creatinine, 5.5 [range, 0.7-12] mg/dL) and heavy proteinuria (n = 11) were the most common indications for biopsy. Hypertension was almost uniformly present in this case series, while diabetes and obesity were less frequent.

The most severe AKI presentations were in the 6 patients who presented with severe hypertension (often >150/100 mm Hg; cases 6-11). Four of these (cases 8-11) had characteristic laboratory features of thrombotic microangiopathy (TMA), including anemia, thrombocytopenia, elevated serum lactate dehydrogenase level, and low haptoglobin level with normal ADAMTS13 (von Willebrand factor protease) activity. Three of 4 had additional conditions that may have contributed to TMA, including cytotoxic and/or illicit drug use and poorly controlled hypertension.

The first of these patients (case 8) presented with mental status changes and intracranial hemorrhage and ultrasound imaging revealed atrophic-appearing kidneys, suggesting long-standing poorly controlled blood pressure. The second patient (case 9) had mental status changes, normal complement levels, and had previously been treated with gemcitabine for adenocarcinoma. She presented with oliguric AKI and nephrotic-range proteinuria. The third patient (case 10) had evidence of activation of the alternative complement pathway (low serum C3 with normal C4 levels), which has been reported in patients with COVID-19.¹⁰ The fourth patient initially presented only with fatigue (case 11) and 2 days later COVID-19 was diagnosed. At that time, his serum creatinine level was 1.62 mg/dL, and 23 days later, his pulmonary symptoms had worsened and he was admitted for pulmonary edema and high blood pressure (165/87 mm Hg). His social history was significant for active cocaine use and he was being treated with gemcitabine, vinorelbine, and doxorubicin for primary refractory classic Hodgkin lymphoma (first diagnosed in 2017, followed by multiple cycles of chemotherapy with failure and progression). His serum creatinine level was 3.9 mg/dL on

Table 1. Clinical Characteristics of Patients With COVID-19 and Kidney Biopsies

Case	Demographics	COVID-19 Symptoms	HTN & DM Status	Kidney Markers	Additional Pertinent Labs	Reason for Kidney Bx	Bx Diagnosis
Podocytopathy							
1	46-yo Black man	Acute respiratory failure	HTN ^a	Scr, 8.7 mg/dL; UPCR, 13.7 g/g; no hematuria	<i>APOL1</i> G1/G1	Nephrotic syndrome, AKI	Collapsing FSGS, ATN
2	60-yo Black woman	None	HTN	Scr, 5.7 mg/dL; UPCR, 21 g/g; no hematuria	NA	Nephrotic-range proteinuria, AKI	Collapsing FSGS, ATN
3	58-yo Black woman	None	HTN	Scr, 10.2 mg/dL; UPCR, 20 g/g; no hematuria	NA	Nephrotic syndrome, AKI	Collapsing FSGS, ATN, AIN
4	59-yo Black man	Abdominal pain, weakness, fever	Both	Scr, 11.9 mg/dL; proteinuria, >12 g/d; no data on hematuria	NA	Nephrotic-range proteinuria, AKI	FSGS, ATN, AIN
5	52-yo White woman	Loss of exercise tolerance, splenomegaly	Neither	Scr, 0.7 mg/dL; proteinuria, 20 g/d; no hematuria	Leukopenia	Nephrotic syndrome	Minimal change disease
Podocytopathy + Renal TMA							
6	44-yo Hispanic man	Mild upper respiratory symptoms	Neither	Scr, 12 mg/dL; UPCR, 11.4 g/g; no hematuria	<i>APOL1</i> G2/G2	Nephrotic-range proteinuria, AKI	Collapsing FSGS, EM evidence of endothelial injury, ATN, TIN
7	58-yo Black man	Cough, fever, hypoxia	Neither	Scr, 11.3 mg/dL; proteinuria, 4 g/d; hematuria	NA	Nephrotic-range proteinuria, AKI	Collapsing FSGS, TMA, ATN
Clinically Overt TMA ± Podocyte Injury							
8	47-yo Black man	None	HTN	Scr, 6.6 mg/dL (on dialysis); UPCR, 7.6 g/g; hematuria	Hb, 7.6 g/dL; Plt, 226 × 10 ³ /μL	Concern for TMA, AKI	Arteriolar-prominent TMA, collapsing FSGS, ATN
9	63-yo Black woman	Fatigue	HTN	Scr, 6 mg/dL; UPCR, 20 g/g; hematuria	Anemia; thrombocytopenia; negative ANA; normal C3 & C4; normal ADAMTS13	Concern for TMA; oliguric AKI and nephrotic-range proteinuria	Arteriolar and glomerular-prominent TMA, collapsing FSGS, ATN
10	77-yo Hispanic woman	None	Both	Scr, 3.99 mg/dL; UPCR, 13.41 g/g; no hematuria	C3, 51 μg/mL; normal C4; HP, <9 mg/dL; elevated D-dimer; LDH, 365 U/L; BNP, 397 pg/mL; ADAMTS13, 45%; Hb, 10.0 g/dL; Plt, 32 × 10 ³ /μL	Concern for TMA, AKI, nephrotic syndrome	Arteriolar-prominent TMA, FSGS, mesangial immune complex deposition, ATN
11	34-yo Hispanic man	Fatigue, weakness, shortness of breath	HTN	Scr, 11.4 mg/dL; UPCR, 2.1 g/g; no data on hematuria	Hb, 8.6 g/dL; thrombocytopenia; schistocytes; elevated D-dimer	Concern for TMA	Arteriolar and glomerular-prominent TMA
AKI + Underlying Disease							
12	69-yo White woman	Upper respiratory symptoms	Both	Scr, 4.0 mg/dL; UPCR, 5.7 g/g; no data on hematuria	Urinary tract infection; <i>Escherichia coli</i>	Nephrotic-range proteinuria, AKI	Postinfectious GN, advanced diabetic nephropathy, ATN
13	34-yo White woman	Cough and runny nose; no fever	Both	Scr, 1.26 mg/dL; UPCR, 7 g/g; proteinuria, 2.5 g/d; no hematuria	NA	Nephrotic syndrome, AKI	Advanced diabetic nephropathy with FSGS, ATN

(Continued)

Table 1 (Cont'd). Clinical Characteristics of Patients With COVID-19 and Kidney Biopsies

Case	Demographics	COVID-19 Symptoms	HTN & DM Status	Kidney Markers	Additional Pertinent Labs	Reason for Kidney Bx	Bx Diagnosis
14	67-yo Hispanic woman	Hypoxia, fever to 100.4 °F	HTN	Scr, 1.42 mg/dL; UA, 1+ proteinuria; hematuria	LDH, 451 U/L; Elevated D-dimer	AKI	ATN with κ light chain staining bias
Allograft AKI							
15	47-yo Black woman	Sore throat, nasal congestion, anosmia, cough, malaise, pleuritic chest pain, fever	HTN	Scr, 1.63 mg/dL; UA, 2+ proteinuria; no hematuria	Newly elevated donor-specific antibodies against HLA-DR53, DP, DQ4 and B44	AKI in transplant recipient	Active AMR
16	54-yo Asian man	Acute respiratory failure, fever to 104 °F, nausea/vomiting	Both	Scr, 1.9→5.2 mg/dL; UPCr, 3 g/g; no hematuria	Hb, 9.7 g/dL; Plt, 109 × 10 ³ /μL; aPL negative	AKI, proteinuria, edema in a transplant recipient	Chronic active AMR, IgAN, FSGS, possible TMA
17	42-yo Hispanic man	Cough, sore throat, anosmia, headache, arthralgia, fever to 100.5 °F	HTN	Scr, 1.27→1.43 mg/dL; UPCr, 0.15 g/g; no hematuria	No DSAs	AKI in a transplant kidney	ATN

Note: Reference ranges for clinical values: LDH, 100-200 U/L; BNP, <167 pg/mL; HP, 26-185 mg/dL; Hb, 14-17.5 g/dL; Plt, 150-350 × 10³/μL.

Abbreviations: AIN, acute interstitial nephritis; AKI, acute kidney injury; AMR, antibody-mediated rejection; ANA, antinuclear antibody; aPL, antiphospholipid antibody; APO_{L1}, apolipoprotein L1 gene; ATN, acute tubular necrosis; BNP, brain natriuretic peptide; Bx, biopsy; COVID-19, coronavirus disease 2019; DM, diabetes mellitus; DSAs, donor-specific antibodies; EM, electron microscopy; FSGS, focal segmental glomerulosclerosis; GN, glomerulonephritis; Hb, hemoglobin; HP, haptoglobin; HTN, hypertension; IgAN, immunoglobulin A nephropathy; Labs, laboratory test results; LDH, lactate dehydrogenase; NA, not available; Plt, platelet count; Scr, serum creatinine; TIN, tubulointerstitial nephritis; TMA, thrombotic microangiopathy; UA, urinalysis; UPCr, urinary protein-creatinine ratio; yo, year-old.

^aDM status not available.

the day of admission to the hospital and he had evidence of hemolytic anemia (hemoglobin, 8.6 g/dL; hematocrit, 27%; schistocytes on blood smear (2+); activated partial thromboplastin time, 22.7 seconds; fibrinogen activity, 180 mg/dL; and D-dimer level, 7,546 ng/mL).

For the kidney transplant recipients, the original cause of kidney failure for case 15 was focal segmental glomerulosclerosis (FSGS) in the setting of HIV infection. She received a deceased donor allograft in 2015. Her course was complicated by acute vascular rejection approximately 10 months after transplantation. The patient was out of state when she was hospitalized with a 4-day history of COVID-19 symptoms and elevated serum creatinine level (baseline, 1.1 mg/dL). She eventually recovered without requiring intubation. Upon return to her home state and follow-up with her transplant nephrologist, her serum creatinine level was found to be persistently elevated with the appearance of several new high-titer donor-specific antibodies. This prompted a kidney biopsy and initiation of treatment for antibody-mediated rejection after the report was returned.

The original cause of kidney failure for case 16 was unknown, presumed due to undiagnosed hypertension or calculi. He received a deceased donor allograft in 2000 and his subsequent course was relatively uncomplicated without biopsy-diagnosed episodes of rejection. In 2019, he presented with elevated serum creatinine

level increasing from his baseline of 1.5 to 2.2 mg/dL and increasing proteinuria (urinary protein-creatinine ratio [UPCr], 3 g/g). At that time, chronic transplant glomerulopathy with negative C4d and focal glomerulitis (g2) in the setting of a low positive HLA-DQ titer was biopsy diagnosed. In spring 2020, the patient presented with progressive hypoxemia requiring up to 4 L/min of oxygen by nasal canula (he never required intubation) and AKI. At this time, tacrolimus and mycophenolate mofetil treatments were discontinued and he was maintained on 10 mg/d of prednisone until he was stable enough to undergo biopsy approximately 6 weeks after COVID-19 symptom onset.

Patient 17 had kidney failure due to FSGS, and he received a living related kidney transplant 19 months before the diagnosis of COVID-19. His posttransplantation course had been uncomplicated. He developed AKI in the setting of mild COVID-19 symptoms.

There was often a delay between the onset of kidney symptoms or COVID-19 diagnosis and performance of the kidney biopsy. Reasons for this delay were varied but included an abundance of caution with infectious precautions at the onset of the pandemic (cases 5, 9, 16, and 17), hemodynamic instability (cases 1 and 8), observation during initial improvement that was followed by further decline (cases 2, 3, and 11), and scheduling hurdles (cases 12 and 15). These delays were not unique to a given

institution and are likely comparable to biopsy-scheduling practices at large referral centers nationwide.

Pathologic Findings

Native Biopsies

The findings on kidney biopsy are summarized in Table 2, with clinical follow-up summarized in Table 3. Clinically, 15 of 17 patients presented with an acute increase in serum creatinine level, and 13 of these patients demonstrated histologic evidence of acute tubular injury in their biopsy specimens (Fig 1A). Eleven patients demonstrated FSGS, which in 7 patients assumed the form of collapsing glomerulopathy (Fig 1B-D). One of these patients (case 6) had collapsing glomerulopathy diagnosed 3 years prior and had been clinically stable with a baseline serum creatinine level of 2 mg/dL and UPCR of 2 g/g. During his COVID-19 course, his serum creatinine increased to 12 mg/dL with a UPCR of 11.4 g/g. All 11 patients with FSGS, as well as the patient with minimal change disease diagnosed (case 5), presented with UPCR > 3 g/g, which correlated with diffuse podocyte foot-process effacement by electron microscopy. Two patients were tested and found to have high-risk APOL1 genotypes (cases 1 and 6).

Six patients (cases 6-11) demonstrated evidence of acute endothelial cell injury by light and/or electron microscopy including all 4 clinically suspected of having acute TMA (cases 8-11). This ranged from mild injury with ultrastructural evidence of glomerular subendothelial space widening and/or loss of endothelial cell fenestrae to severe injury manifest by endothelial cell swelling and fibrin thrombi within glomerular hilar arterioles and small arteries evident by light microscopy (Fig 1D-F). Peritubular capillary thrombi were not seen in any cases in this series. Microangiopathic features were seen in the setting of collapsing glomerulopathy (cases 6-9) and/or with prominent arteriolar involvement in the background of severe hypertension (cases 8-11). Additional findings of acute interstitial nephritis, immunoglobulin A (IgA) nephropathy, mesangial immune complex deposition of uncertain significance, monoclonal gammopathy (later diagnosed as Waldenström macroglobulinemia), post-infectious glomerulonephritis, minimal change disease, and diabetic nephropathy were also identified (cases 3, 5, and 12-15).

Allograft Biopsies

Two of the 3 transplant recipients (cases 15 and 16) demonstrated microvascular inflammation and positive C4d staining in peritubular capillaries in association with elevated levels of donor-specific antibodies, meeting Banff criteria for active antibody-mediated rejection. The discovery of IgA nephropathy in case 16 was considered incidental de novo disease because the patient's original cause of kidney failure 20 years prior was considered to be hypertension/calculi. Glomeruli in this case showed mild mesangial expansion and focal mesangial hypercellularity,

but these findings could also be attributed to chronic and active antibody-mediated rejection. A third allograft biopsy specimen (case 17) showed acute tubular injury, and the patient's serum creatinine level returned to baseline shortly after the biopsy.

Lack of Evidence for Direct Infection of the Kidney by SARS-CoV-2

Using electron microscopy, earlier reports have suggested direct viral infection of the kidney.^{11,12} However, unambiguous identification of viral particles in autopsy tissue is difficult due to post mortem degradation artifacts. We therefore reasoned that 3 criteria were required to establish direct viral infection of tissues: (1) viral particles of expected size (80-140 nm) with the electron-dense dots of the nucleocapsid cores and, when visible, spikes facing the lumen of vacuoles^{13,14}; (2) viral particles present in the appropriate subcellular compartment (eg, intracisternal spaces of the endoplasmic reticulum and Golgi, cytoplasmic vesicles, and extracellular spaces) compatible with known viral replication and trafficking pathways¹⁵; and (3) orthogonal validation by immunohistochemistry or RNA in situ hybridization (with appropriate clinical validation and controls). These criteria were not met in any of our cases and therefore we could not establish direct viral infection of the kidney in the patients in this case series. Viral particles were not identified by ultrastructural examination in any of our cases. Electron microscopy revealed intracellular vesicular structures with diameters of ~100 nm, which by consensus expert opinion represented normal cytoplasmic organelles (eg, clathrin-coated vesicles and multivesicular bodies) and not true viral particles. In addition, immunohistochemistry for SARS-CoV-2 nucleocapsid and RNA in situ hybridization for viral genomes were negative for all 4 patient samples on which it was performed (cases 1, 5, 10, and 12).

Clinical Outcome and Follow-up

There were often several weeks of delay between kidney manifestations and the biopsy procedure, and most patients were RT-PCR negative for SARS-CoV-2 at the time of biopsy (Table 3). Because most patients had only mild COVID-19-related symptoms, treatment focused on managing their kidney disease diagnosed on biopsy, usually with diuretics and blood pressure control. This resulted in improvement in 7 of 12 patients; at least 8 patients required dialysis, including 6 of 7 patients with collapsing glomerulopathy diagnosed, and all 6 presenting with suspected or clinically confirmed TMA. Seven patients remain on dialysis at the time of writing.

Discussion

In this series of patients with COVID-19, the most frequent indications for biopsy were an acute increase in serum creatinine level (15/17; 88%), new onset of proteinuria

Table 2. Kidney Biopsy Findings in Patients With SARS-CoV-2 Infection

Case	Diagnosis	ATN	TMA Features	Chronic Vascular Disease	LM Findings	IF Findings	EM Findings
Podocytopathy							
1	Collapsing FSGS, ATN ^a	Present	None	Mild AS	9 glomeruli: 55% global GS; 10% FSGS (1 collapsing); 75% IFTA	Not performed	Diffuse FPE; no immune deposits; no TRIs; no viral particles
2	Collapsing FSGS, ATN	Severe	None	Mod AS	4 glomeruli: 25% global GS; 50% FSGS (2 collapsing); 20% IFTA	Negative	Segmental FPE; no TRIs; no viral particles
3	Collapsing FSGS, ATN, AIN ^a	Severe	None	Severe AS	25 glomeruli: 50% global GS; 24% FSGS (6 collapsing); 10% IFTA	Negative	75% FPE; no TRIs; no viral particles
4	FSGS, ATN, AIN	Severe	None	Mod AS, severe arteriosclerosis	19 glomeruli: 42% global GS; 5% FSGS; 25% IFTA	Negative	Diffuse FPE; TRIs present; no viral particles
5	Minimal change disease	No	None	Minimal AS	23 glomeruli: 17% global GS; 0% FSGS; 5% IFTA	Negative	Diffuse FPE; no TRIs; probable clathrin-coated vesicles in endothelial cells and podocytes
Podocytopathy + Renal TMA							
6	Collapsing FSGS, EM evidence of endothelial injury, ATN, TIN	Present	EM evidence of endothelial injury	None	4 glomeruli: 25% global GS; 25% FSGS (1 collapsing); mod IFTA	Negative	Diffuse FPE; mild subendothelial space expansion; no TRIs; no viral particles
7	Collapsing FSGS, TMA, ATN ^a	Severe	Thrombi in 1 glomerulus and arteriole	Mild AS	21 glomeruli: 10% global GS; 15% FSGS (3 collapsing); 0% IFTA	Negative	Diffuse FPE; TRIs present; no viral particles
Clinically Overt TMA ± Podocyte Injury							
8	Arteriolar-prominent TMA, collapsing FSGS, ATN	Present	Arterial fibrin thrombi, swollen endothelium	Mod AS	14 glomeruli: 25% global GS; 7% FSGS (1 collapsing); 30% IFTA	Medulla only	Extensive FPE; variable subendothelial space expansion; no immune deposits; no TRIs; no viral particles
9	Arteriolar and glomerular-prominent TMA, FSGS, ATN ^a	Severe	Arterial and glomerular fibrin thrombi, segmental GBM duplication	Severe AS	36 glomeruli: 0% global GS; 3% FSGS (1 collapsing); 10% IFTA	Negative	Diffuse FPE; endothelial swelling, ischemic wrinkling and occasional duplication of GBMs
10	Arteriolar-prominent TMA, FSGS, mesangial immune complex deposition, ATN	Severe	Arteriolar TMA	Severe AS	10 glomeruli: 0% global GS; 50% FSGS; 30% IFTA	Segmental granular mesangial & capillary wall staining for polyclonal IgG (2+), IgM (1+), C1q (1+)	Diffuse FPE; mesangial immune deposits; no subendothelial expansion; TRIs present; probable multivesicular bodies in podocytes, no viral particles

(Continued)

Table 2 (Cont'd). Kidney Biopsy Findings in Patients With SARS-CoV-2 Infection

Case	Diagnosis	ATN	TMA Features	Chronic Vascular Disease	LM Findings	IF Findings	EM Findings
11	Arteriolar and glomerular-prominent TMA	Mild	Arterial and glomerular fibrin thrombi, endothelial swelling, mesangiolytic, GBM duplication	None	11 glomeruli: 0% global GS; 0% FSGS; 0% IFTA	Negative	Segmental FPE; marked subendothelial space expansion and accumulation of flocculent material; segmental duplication of GBMs
AKI + Underlying Disease							
12	Postinfectious GN, advanced diabetic nephropathy, ATN	Severe	None	Mod AS, severe AH	15 glomeruli: 28% global GS; 7% FSGS; 40% IFTA	Irregular coarse granular glomerular C3 (3+)	Subepithelial, paramesangial deposits; frequent FPE; GBM thickening and mesangial sclerosis; no TRIs; no viral particles
13	Advanced diabetic nephropathy, ATN	Severe	None	Severe AH	20 glomeruli: 15% global GS; 15% FSGS; mild to mod IFTA	Negative	GBM thickening and mesangial sclerosis; no TRIs; no viral particles
14	ATN ^a	Present	None	Mild AS	14 glomeruli: 14% global GS; 0% FSGS; 10% IFTA	κ light chain staining bias in tubular droplets and casts	Segmental FPE; no deposits or crystals; no TRIs; no viral particles
Allograft AKI							
15	Active AMR	No	None	Mod AS, AH	25 glomeruli: 10% global GS; 0% FSGS; 50% IFTA	C4d diffusely positive	Segmental FPE; no TRIs; no viral particles
16	Chronic active AMR, IgAN, FSGS, TMA	No	Single arterial thrombus	Severe AH	4 glomeruli: 25% global GS; 50% FSGS; 50% IFTA	IgA (1-2+); C4d (positive in 10% of PTCs)	Subendothelial space expansion; segmental FPE; rare mesangial deposits; no TRIs; no viral particles
17	ATN	Mild	None	None	19 glomeruli: 0% global GS; 0% FSGS; 0% IFTA	C4d negative	Not performed

Abbreviations: AH, arteriolar hyaline; AIN, acute interstitial nephritis; AMR, antibody-mediated rejection; AS, arteriosclerosis; ATN, acute tubular necrosis/acute tubular injury; EM, electron microscopy; FPE, podocyte foot-process effacement; FSGS, focal segmental glomerulosclerosis; GBM, glomerular basement membrane; GN, glomerulonephritis; GS, glomerulosclerosis; IF, immunofluorescence; IFTA, interstitial fibrosis and tubular atrophy; IgAN, immunoglobulin A nephropathy; LM, light microscopy; Mod, moderate; PTC, peritubular capillary; SARS-CoV-2, severe acute respiratory syndrome coronavirus 2; TIN, tubulointerstitial nephritis; TMA, thrombotic microangiopathy; TRIs, tubuloreticular inclusions.

^aSARS-CoV-2 positive by polymerase chain reaction at time of kidney biopsy.

(11/17; 65%), and hematuria (4/17; 24%). All patients' kidney manifestations presented concurrently with or within 1 week of RT-PCR-confirmed SARS-CoV-2 infection, and most had only mild COVID-19 symptoms. However, there was often several weeks' delay between the onset of COVID-19 symptoms or confirmed positive RT-PCR test results and the kidney biopsy procedure (Table 3). Therefore, most biopsies were performed after individuals were RT-PCR negative and considered to be of low infection risk.

Histologically, acute tubular injury was seen in the majority (14/17; 82%) of this biopsy series. The most

striking finding is the high incidence of collapsing glomerulopathy (7/17; 41%), which has been reported by multiple groups in association with SARS-CoV-2 infection.¹⁶⁻²⁰ The mechanism driving this acute glomerular injury process is possibly related to interferon production, a known trigger of collapsing glomerulopathy.²¹⁻²³ It is less likely that direct podocyte infection is an etiologic factor because 3 of the 4 patients who were negative for virus by immunohistochemistry and/or in situ hybridization had podocytopathies (1 each with FSGS, collapsing glomerulopathy, and minimal change disease).

Table 3. Timing and Outcomes of Kidney Disease in Patients With COVID-19

Case	Time From COVID-19 Presentation to:		Kidney Biopsy Diagnosis	Treatment and/or Outcome at Time of Writing
	Kidney Manifestations	Kidney Biopsy ^a		
Podocytopathy				
1	Concurrent	2 wk ^b	Collapsing FSGS, ATN	Dialysis
2	No COVID-19 symptoms	4 wk	Collapsing FSGS, ATN	Unknown
3	No COVID-19 symptoms	8 d ^b	Collapsing FSGS, ATN, AIN	Dialysis, with improvement in pre-dialysis Scr
4	Concurrent	11 d	FSGS, ATN, AIN	Unknown
5	Concurrent	7 wk	Minimal change disease	Prednisone; full remission after 4 wk of treatment
Podocytopathy + Renal TMA				
6	1 wk	6 wk	Collapsing FSGS, EM evidence of endothelial injury, ATN, TIN	Dialysis
7	Concurrent	4 d ^b	Collapsing FSGS, TMA, ATN	Dialysis, no other specific treatment; Scr returned to 1.5 mg/dL
Clinically Overt TMA ± Podocyte Injury				
8	No COVID-19 symptoms	25 d	Arteriolar-prominent TMA, Collapsing FSGS, ATN	Dialysis (symptomatically improved with BP control, but discharged to outpatient dialysis)
9	3-5 d	10-14 d ^b	Arteriolar and glomerular-prominent TMA, collapsing FSGS, ATN	Dialysis
10	No COVID-19 symptoms	3 d	Arteriolar-prominent TMA, FSGS, mesangial immune complex deposition, ATN	Dialysis
11	2-3 d	4-5 wk	Arteriolar and glomerular-prominent TMA	PLX, eculizumab, prednisone; remains on dialysis
AKI + Underlying Disease				
12	Unknown	4 wk	Postinfectious GN, advanced diabetic nephropathy, ATN	Dialysis
13	Concurrent	4 d	Advanced diabetic nephropathy, ATN	Stable and asymptomatic at the time of discharge with Scr of 1.1 mg/dL; volume status and rash had improved; never required dialysis
14	Concurrent	5 d ^b	ATN with κ light chain staining bias	Scr returned to 1 mg/dL; eventually diagnosed with Waldenström: FLC ratio of 15.1 (κ = 80.7 mg/dL [ref < 1.9 mg/L], λ = 5.35 mg/L [ref < 2.35 mg/L])
Allograft AKI				
15	6 wk	6 wk	Active AMR	PLX + IVIG ×3, IV methylprednisolone followed by rituximab
16	Concurrent	6 wk	Chronic active AMR, IgAN, FSGS, possible TMA	Held MMF, reduced tacrolimus and initiated low-dose prednisone (10 mg/d); Scr improved to 2.7 mg/dL
17	Concurrent	7 wk	ATN	Scr returned to 1.3 mg/dL

Abbreviations: AIN, acute interstitial nephritis; AKI, acute kidney injury; AMR, antibody-mediated rejection; ATN, acute tubular injury; BP, blood pressure; COVID-19, coronavirus disease 2019; EM, electron microscopy; FLC, free light chain; FSGS, focal segmental glomerulosclerosis; GN, glomerulonephritis; IgAN, immunoglobulin A nephropathy; IVIG, intravenous immunoglobulin; MMF, mycophenolate mofetil; PLX, plasma exchange; ref, reference range; SARS-CoV-2, severe acute respiratory syndrome coronavirus 2; Scr, serum creatinine; TIN, tubulointerstitial nephritis; TMA, thrombotic microangiopathy.

^aIf no COVID-19 symptoms, the interval start is when SARS-CoV-2 positive by reverse transcriptase–polymerase chain reaction.

^bSARS-CoV-2 positive by polymerase chain reaction at time of kidney biopsy.

We were able to perform APOL1 genotyping for 1 Black patient (case 1) who was found to carry the high-risk G1/G1 genotype. Although we did not genotype the other patients in this case series, 6 of 7 patients with collapsing glomerulopathy were of Black race, consistent with other reports demonstrating a strong association between collapsing glomerulopathy in the setting of SARS-CoV-2

infection with high-risk APOL1 genotypes,^{17,19,24} a susceptibility that parallels its incidence in HIV-infected patients.^{24,25} The last patient with collapsing glomerulopathy (case 6) was a Hispanic individual from Mexico who was also found to have a high-risk G2/G2 APOL1 genotype, although the prevalence of homozygous high-risk APOL1 genotypes in mainland Hispanics is 0.1%.²⁶

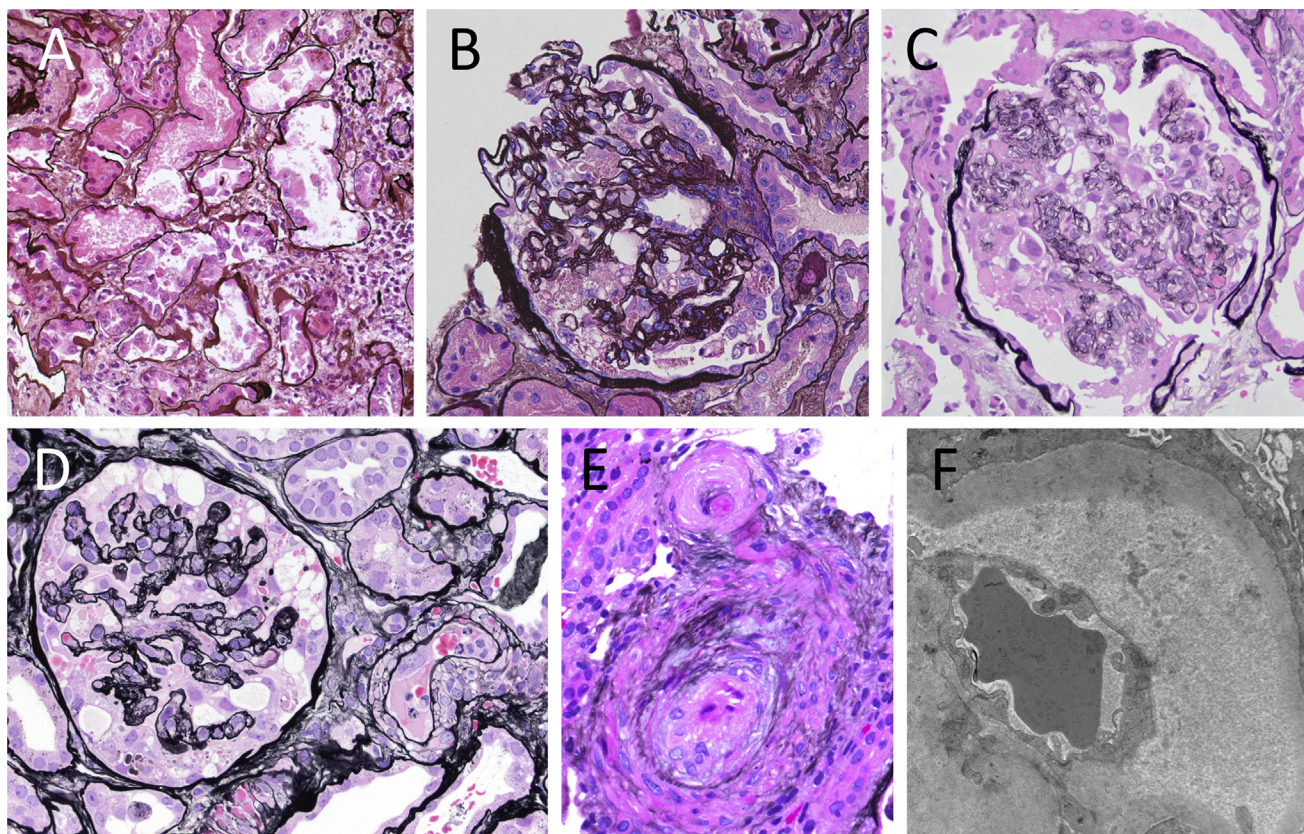


Figure 1. Kidney biopsy findings from representative cases. (A) Case 7, acute tubular necrosis; (B) case 7, collapsing glomerulonephritis (GN); (C) case 6, collapsing GN; (D) case 9, collapsing GN and thrombotic microangiopathy (TMA); (E) case 8, TMA (A-E: Jones methenamine silver; original magnification, $\times 400$); (F) case 8, TMA (electron microscopy; original magnification, $\times 20,900$).

Acute TMA and more subtle ultrastructural evidence of acute endothelial cell injury were also common findings in this case series (6/17; 35%). Four of 6 of these patients had underlying hypertension, and 2 had prior or ongoing treatment with gemcitabine (1 of whom also used cocaine) and thus had potential additional drivers for TMA besides SARS-CoV-2 infection. Four patients' biopsy specimens with TMA/endothelial injury also demonstrated collapsing glomerulopathy, and 2 allograft biopsy specimens showed endothelial cell injury in the setting of antibody-mediated rejection.

Interestingly, TMA has been associated with collapsing glomerulopathy,²⁷⁻³⁰ and endothelial injury is the most common manifestation of antibody-mediated rejection.^{31,32} Thus, the frequent finding of acute TMA and more subtle ultrastructural evidence of acute endothelial cell injury appears to be the manifestation of the underlying disease processes in the patients in this case series. Endothelial injury and dysfunction are emerging mechanisms in severe COVID-19, and other groups have suggested that endothelial injury may be a manifestation of SARS-CoV-2 infection and contribute to kidney injury.^{11,33,34} Our series demonstrates that a broad clinical and pathologic spectrum of acute endothelial injury may exist even in the absence of significant COVID-19-related respiratory symptoms, and some of these changes can be

attributed to co-existing diseases. It is possible that SARS-CoV-2 infection may exacerbate clinical situations predisposing to endothelial injury such as hypertension, antibody-mediated rejection, prothrombotic states, and endothelial toxins. Additional data will be helpful to determine whether this is an important clinical consideration.

To our knowledge, this is the first report of infection-related glomerulonephritis (case 12) in the setting of COVID-19. Infection-related glomerulonephritis is most commonly associated with bacterial infections but has been seen in association with viral infections such as parvovirus B19 and influenza virus H1N1.³⁵⁻³⁷ Our patient manifested kidney symptoms 19 days after testing positive for SARS-CoV-2, indicating that the timing of glomerulonephritis fits with the pathogenesis of postinfectious glomerulonephritis. However, this patient also had nodular diabetic nephropathy and a concurrent urinary tract infection, and it is possible that the urinary tract infection was a cause of or contributor to the infection-related glomerulonephritis. We also report a case of minimal change disease in 1 patient (case 5). In contrast to the Black patient with a high-risk (G1/G1) *APOL1* genotype who presented with minimal change disease in a recent report,²⁰ our patient is of White race. However, it is well

appreciated that minimal change disease may manifest after viral infections or interferon treatment,³⁸⁻⁴¹ therefore representing another pathway by which SARS-CoV-2 infection may trigger a podocytopathy.

Two of the 3 kidney transplant recipients reported here developed new donor-specific antibodies and antibody-mediated rejection weeks after SARS-CoV-2 infection, which raises the possibility of immune stimulation of alloantibody production during viral infection.^{42,43} In 1 of these patients (case 16), immunosuppression was reduced during acute COVID-19 hypoxemia, which may have predisposed to the development of antibody-mediated rejection. However, in the other patient (case 15), treatment for antibody-mediated rejection was initiated only after the diagnostic kidney biopsy was completed and in the setting of new high-titer anti-HLA*DR53 antibodies. Emergence of de novo donor-specific antibodies has also been recently been reported in a pediatric heart transplant recipient who was infected with SARS-CoV-2.⁴⁴ Kidney allograft recipients may therefore be at increased risk for developing de novo donor-specific antibodies and active antibody-mediated rejection after SARS-CoV-2 infection.

Direct viral infection of the kidney by SARS-CoV-2 has been proposed as a possible mechanism of kidney injury and is an attractive concept because both podocytes and proximal tubular epithelial cells express high levels of the angiotensin-converting enzyme type 2 entry receptor.^{11,45-47} We could not establish direct kidney infection by SARS-CoV-2 in our case series, though a caveat is that there was often a several-week delay between diagnosis of COVID-19 and performing the kidney biopsy. We note that the temporal relationship between onset of kidney manifestations, COVID-19 symptoms, and diagnostic biopsy has not been clearly reported in the previous studies to date.^{10,16,17,20,48} Detectable SARS-CoV-2 may wane quickly with time after the onset of infection similar to SARS-CoV.^{49,50} Therefore, these delays meant that most patients in this series may have cleared virus from their kidneys and were therefore RT-PCR negative by nasopharyngeal swab at the time of biopsy. Even with this caveat, most recent biopsy and autopsy case series have concluded that there is no significant SARS-CoV-2 infection of the kidney,^{16,20,24,48,51-53} which is in contrast to the possibility of direct infection that was reported in 2 earlier studies.^{11,45} Therefore, our study adds to the accumulating evidence that direct and persistent infection of the kidney by SARS-CoV-2 does not appear to play a significant role in kidney disease in most patients with COVID-19.

Many studies have relied solely on electron microscopy to establish direct viral infection of tissues. However, without orthogonal validation and rigorous controls, this approach is problematic because there are many ultrastructural mimics of viral particles.^{51,54-56} Even in the lung, using validated immunohistochemistry and RNA in situ hybridization, very few cells appear to contain detectable virus.^{45,52} If direct viral infection of the kidney occurs, the lower viral load compared to lung tissue would

make ultrastructural identification of exceedingly rare SARS-CoV-2 particles in the kidney improbable among the ubiquitous viral mimics.⁴⁵ In contrast to the patients in 2 autopsy series or those in a recent biopsy series,^{11,20,48,53} most patients reported here had only mild COVID-19 symptoms while presenting with AKI, heavy proteinuria, and/or severe hypertension. Some diseases detected in this case series may represent diagnoses coincident with COVID-19. However, the high incidence of typically rare disease processes such as collapsing glomerulopathy and TMA raises the possibility that SARS-CoV-2 infection contributed to these injuries, even in the absence of direct infection of the renal parenchyma. Given that most SARS-CoV-2-infected patients exhibit only mild symptoms such as those in our case series, the incidence of AKI and proteinuria may increase as the pandemic progresses and disproportionately affect more vulnerable populations with pre-existing risk factors for kidney disease or high-risk APOL1 genotypes.

Supplementary Material

Supplementary File (XLSX)

Table S1: Additional information on cases.

Article Information

Authors' Full Names and Academic Degrees: Shreeram Akilesh, MD, PhD, Cynthia C. Nast, MD, Michifumi Yamashita, MD, PhD, Kammi Henriksen, MD, Vivek Charu, MD, PhD, Megan L. Troxell, MD, PhD, Neeraja Kambham, MD, Erika Bracamonte, MD, Donald Houghton, MD, Naila I. Ahmed, MD, Chyi Chyi Chong, MD, Bijin Thajudeen, MD, Shehzad Rehman, MD, Firas Khoury, MD, Jonathan E. Zuckerman, MD, PhD, Jeremy Gitomer, MD, Parthasarathy C. Raguram, MD, Shanza Mujeeb, MD, Ulrike Schwarze, MD, M. Brendan Shannon, MD, Iris De Castro, MD, Charles E. Alpers, MD, Behzad Najafian, MD, Roberto F. Nicosia, MD, PhD, Nicole K. Andeen, MD, and Kelly D. Smith, MD, PhD.

Authors' Affiliations: Department of Laboratory Medicine and Pathology, University of Washington, Seattle, WA (SA, US, CEA, BN, RFN, KDS); Department of Pathology, Cedars-Sinai Medical Center, Los Angeles, CA (CCN, MY); Department of Pathology, University of Chicago, Chicago, IL (KH); Department of Pathology, Stanford University, Stanford, CA (VC, MLT, NK); Department of Pathology, University of Arizona, Tucson, AZ (EB); Department of Pathology, Oregon Health & Science University, Portland, OR (DH, NKA); Northeast Nephrology Consultants, Joliet, IL (NIA); Division of Nephrology, Department of Medicine, University of Arizona, Tucson, AZ (CCC, BT); Division of Nephrology Department of Medicine, Oregon Health & Science University (SR); Oregon Kidney & Hypertension Clinic, Portland, OR (FK); Department of Pathology and Laboratory Medicine, University of California Los Angeles, Los Angeles, CA (JEZ); Providence Alaska Medical Center, Anchorage, AK (JG); CHI Franciscan Nephrology Associates, Tacoma (PCR, SM); and Division of Nephrology, Department of Medicine, University of Washington, Seattle, WA (MDS, IDC).

Address for Correspondence: Shreeram Akilesh, MD, PhD, Department of Laboratory Medicine and Pathology, Box 356100, University of Washington Medical Center, 1959 NE Pacific Street, Seattle, WA 98195 (shreeram@uw.edu) or Nicole K. Andeen, MD, Department of Pathology, Oregon Health & Science University, 3181 SW Sam Jackson Park Road, Mail Code L113, Portland, OR, 97239 (andeen@ohsu.edu) or Kelly D. Smith, MD, PhD,

Department of Laboratory Medicine and Pathology, Box 356100, University of Washington Medical Center, 1959 NE Pacific Street, Seattle, WA 98195 (kelsmith@uw.edu).

Authors' Contributions: Research idea and study design: SA, NKA, KDS; data acquisition: all authors; data analysis/interpretation: all authors; study supervision: SA, NKA, KDS. NKA and KDS contributed equally to this work. Each author contributed important intellectual content during manuscript drafting or revision and agrees to be personally accountable for the individual's own contributions and to ensure that questions pertaining to the accuracy or integrity of any portion of the work, even one in which the author was not directly involved, are appropriately investigated and resolved, including with documentation in the literature if appropriate.

Support: None.

Financial Disclosure: The authors declare that they have no relevant financial interests.

Acknowledgements: We thank Dr Kimberly Muczynski (University of Washington) for contributing clinical information and follow-up for this series.






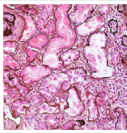
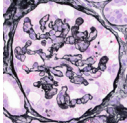
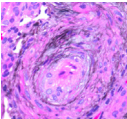
Peer Review: Received July 21, 2020. Evaluated by 2 external peer reviewers, with direct editorial input from the Pathology Editor, an Associate Editor, and the Editor-in-Chief. Accepted in revised form October 4, 2020.

References

- Hou YJ, Okuda K, Edwards CE, et al. SARS-CoV-2 reverse genetics reveals a variable infection gradient in the respiratory tract. *Cell*. 2020;182(2):429-446.
- Williamson EJ, Walker AJ, Bhaskaran K, et al. Factors associated with COVID-19-related death using OpenSAFELY. *Nature*. 2020;584:430-436.
- Hirsch JS, Ng JH, Ross DW, et al. Acute kidney injury in patients hospitalized with COVID-19. *Kidney Int*. 2020;98(1):209-218.
- Cheng Y, Luo R, Wang K, et al. Kidney disease is associated with in-hospital death of patients with COVID-19. *Kidney Int*. 2020;97(5):829-838.
- Wu C, Chen X, Cai Y, et al. Risk factors associated with acute respiratory distress syndrome and death in patients with coronavirus disease 2019 pneumonia in Wuhan, China. *JAMA Intern Med*. 2020;180(7):934-943.
- Chen T, Wu D, Chen H, et al. Clinical characteristics of 113 deceased patients with coronavirus disease 2019: retrospective study. *BMJ*. 2020;368:m1091.
- Zheng Z, Peng F, Xu B, et al. Risk factors of critical & mortal COVID-19 cases: a systematic literature review and meta-analysis. *J Infect*. 2020;81(2):16-25.
- Valeri AM, Robbins-Juarez SY, Stevens JS, et al. Presentation and outcomes of patients with ESKD and COVID-19. *J Am Soc Nephrol*. 2020;31(7):1409-1415.
- Naicker S, Yang CW, Hwang SJ, Liu BC, Chen JH, Jha V. The novel coronavirus 2019 epidemic and kidneys. *Kidney Int*. 2020;97(5):824-828.
- Gavriilaki E, Brodsky RA. Severe COVID-19 infection and thrombotic microangiopathy: success does not come easily. *Br J Haematol*. 2020;189(6):e227-e230.
- Su H, Yang M, Wan C, et al. Renal histopathological analysis of 26 postmortem findings of patients with COVID-19 in China. *Kidney Int*. 2020;98(1):219-227.
- Bradley BT, Maioli H, Johnston R, et al. Histopathology and ultrastructural findings of fatal COVID-19 infections in Washington State: a case series. *Lancet*. 2020;396(10247):320-332.
- Miller SE, Brealey JK. Visualization of putative coronavirus in kidney. *Kidney Int*. 2020;98(1):231-232.
- Miller SE, Goldsmith CS. Caution in identifying coronaviruses by electron microscopy. *J Am Soc Nephrol*. 2020;31(9):2223-2224.
- Goldsmith CS, Tatti KM, Ksiazek TG, et al. Ultrastructural characterization of SARS coronavirus. *Emerg Infect Dis*. 2004;10(2):320-326.
- Larsen CP, Bourne TD, Wilson JD, Saqqa O, Sharshir MA. Collapsing glomerulopathy in a patient with coronavirus disease 2019 (COVID-19). *Kidney Int Rep*. 2020;5(6):935-939.
- Peleg Y, Kudose S, D'Agati V, et al. Acute kidney injury due to collapsing glomerulopathy following COVID-19 infection. *Kidney Int Rep*. 2020;5(6):940-945.
- Gaillard F, Ismael S, Sannier A, et al. Tubuloreticular inclusions in COVID-19-related collapsing glomerulopathy. *Kidney Int*. 2020;98(1):241.
- Sharma Y, Nasr SH, Larsen CP, Kemper A, Ormsby AH, Williamson SR. COVID-19-associated collapsing focal segmental glomerulosclerosis: a report of 2 cases. *Kidney Med*. 2020;2(4):493-497.
- Kudose S, Batal I, Santoriello D, et al. Kidney biopsy findings in patients with COVID-19. *J Am Soc Nephrol*. 2020;31(9):1959-1968.
- Wilk AJ, Rustagi A, Zhao NQ, et al. A single-cell atlas of the peripheral immune response in patients with severe COVID-19. *Nat Med*. 2020;26:1070-1076.
- Kanungo S, Tamirisa S, Gopalakrishnan R, Salinas-Madrigal L, Bastani B. Collapsing glomerulopathy as a complication of interferon therapy for hepatitis C infection. *Int Urol Nephrol*. 2010;42:219-222.
- Abid Q, Best Rocha A, Larsen CP, et al. APOL1-associated collapsing focal segmental glomerulosclerosis in a patient with stimulator of interferon genes (STING)-associated vasculopathy with onset in infancy (SAVI). *Am J Kidney Dis*. 2020;75(2):287-290.
- Wu H, Larsen CP, Hernandez-Arroyo CF, et al. AKI and collapsing glomerulopathy associated with COVID-19 and APOL1 high-risk genotype. *J Am Soc Nephrol*. 2020;31(8):1688-1695.
- Kasembeli AN, Duarte R, Ramsay M, et al. APOL1 risk variants are strongly associated with HIV-associated nephropathy in black South Africans. *J Am Soc Nephrol*. 2015;26(11):2882-2890.
- Kramer HJ, Stilp AM, Laurie CC, et al. African ancestry-specific alleles and kidney disease risk in Hispanics/Latinos. *J Am Soc Nephrol*. 2017;28(3):915-922.
- Mandal AK, Nordquist JA, Rodgers CL. Glomerulopathy and arteriopathy in congenital nephrotic syndrome: light, electron, and fluorescence microscopy studies. *Hum Pathol*. 1977;8(3):344-349.
- Meehan SM, Pascual M, Williams WW, et al. De novo collapsing glomerulopathy in renal allografts. *Transplantation*. 1998;65(9):1192-1197.
- Stokes MB, Davis CL, Alpers CE. Collapsing glomerulopathy in renal allografts: a morphological pattern with diverse clinicopathologic associations. *Am J Kidney Dis*. 1999;33(4):658-666.
- Nadasdy T, Allen C, Zand MS. Zonal distribution of glomerular collapse in renal allografts: possible role of vascular changes. *Hum Pathol*. 2002;33(4):437-441.
- Fogo AB. Talking back: the podocytes and endothelial cells duke it out. *Kidney Int*. 2016;90(6):1157-1159.
- Halloran PF, Venner JM, Madill-Thomsen KS, et al. Review: the transcripts associated with organ allograft rejection. *Am J Transplant*. 2018;18:785-795.

33. Teuwen LA, Geldhof V, Pasut A, Carmeliet P. COVID-19: the vasculature unleashed. *Nat Rev Immunol.* 2020;20:389-391.
34. Jhaveri KD, Meir LR, Flores Chang BS, et al. Thrombotic microangiopathy in a patient with COVID-19. *Kidney Int.* 2020;98(2):509-512.
35. Hara S, Hirata M, Ito K, et al. Post-infectious acute glomerulonephritis with podocytopathy induced by parvovirus B19 infection. *Pathol Int.* 2018;68(3):190-195.
36. Marco H, Guermah I, Matas L, et al. Postinfectious glomerulonephritis secondary to erythrovirus B19 (parvovirus B19): case report and review of the literature. *Clin Nephrol.* 2016;85:238-244.
37. Jain T, Hemington L, Etuwewe B. A case of post-infectious glomerulonephritis following infection with influenza A subtype H1N1. *Pediatr Nephrol.* 2011;26:151-152.
38. Kim SR, Lee SB, Kim IY, et al. Relapse of minimal change disease following infection with the 2009 pandemic influenza (H1N1) virus. *Clin Exp Nephrol.* 2012;16:329-332.
39. Haruki A, Ishikawa E, Katayama K, et al. Spontaneous remission of adult-onset minimal change nephrotic syndrome associated with influenza B infection: a case report. 2018;19:162.
40. Rettmar K, Kienast J, van de Loo J. Minimal change glomerulonephritis with reversible proteinuria during interferon α 2a therapy for chronic myeloid leukemia. *Am J Hematol.* 1995;49(4):355-356.
41. Markowitz GS, Nasr SH, Stokes MB, D'Agati VD. Treatment with IFN- α , - β , or - γ is associated with collapsing focal segmental glomerulosclerosis. *Clin J Am Soc Nephrol.* 2010;5(4):607-615.
42. D'Orsogna L, van den Heuvel H, van Kooten C, Heidt S, Claas FHJ. Infectious pathogens may trigger specific allo-HLA reactivity via multiple mechanisms. *Immunogenetics.* 2017;69:631-641.
43. Amir AL, D'Orsogna LJA, Roelen DL, et al. Allo-HLA reactivity of virus-specific memory T cells is common. *Blood.* 2010;115(15):3146-3157.
44. Russell MR, Halnon NJ, Alejos JC, Salem MM, Reardon LC. COVID-19 in a pediatric heart transplant recipient: emergence of donor-specific antibodies. *J Heart Lung Transplant.* 2020;39(7):732-733.
45. Puelles VG, Lütgehetmann M, Lindenmeyer MT, et al. Multi-organ and renal tropism of SARS-CoV-2. *N Engl J Med.* 2020;383:590-592.
46. Menon R, Otto EA, Sealton R, et al. SARS-CoV-2 receptor networks in diabetic kidney disease, BK-virus nephropathy and COVID-19 associated acute kidney injury [preprint posted online August 24, 2020]. *medRxiv.* <https://doi.org/10.1101/2020.05.09.20096511>.
47. Zou X, Chen K, Zou J, Han P, Hao J, Han Z. Single-cell RNA-seq data analysis on the receptor ACE2 expression reveals the potential risk of different human organs vulnerable to 2019-nCoV infection. *Front Med.* 2020;14:185-192.
48. Sharma P, Uppal NN, Wanchoo R, et al. COVID-19-associated kidney injury: a case series of kidney biopsy findings. *J Am Soc Nephrol.* 2020;31(9):1948-1958.
49. Sauter JL, Baine MK, Butnor KJ, et al. Insights into pathogenesis of fatal COVID-19 pneumonia from histopathology with immunohistochemical and viral RNA studies. *Histopathology.* 2020;77(6):915-925.
50. Nicholls JM, Butany J, Poon LLM, et al. Time course and cellular localization of SARS-CoV nucleoprotein and RNA in lungs from fatal cases of SARS. *PLoS Med.* 2006;3(2):222-229.
51. Cassol CA, Gokden N, Larsen CP, Bourne TD. Appearances can be deceiving - viral-like inclusions in COVID-19 negative renal biopsies by electron microscopy. *Kidney360.* 2020;1(8):824-828.
52. Best Rocha A, Stroberg E, Barton LM, et al. Detection of SARS-CoV-2 in formalin-fixed paraffin-embedded tissue sections using commercially available reagents. *Lab Invest.* 2020;100:1485-1489.
53. Golmai P, Larsen CP, DeVita MV, et al. Histopathologic and ultrastructural findings in postmortem kidney biopsy material in 12 patients with AKI and COVID-19. *J Am Soc Nephrol.* 2020;31(9):1944-1947.
54. Roufousse C, Curtis E, Moran L, et al. Electron microscopic investigations in COVID-19: not all crowns are coronas. *Kidney Int.* 2020;98(2):505-506.
55. Smith KD, Akilesh S, Alpers CE, Nicosia RF. Am I a coronavirus? *Kidney Int.* 2020;98(1):219-227.
56. Goldsmith CS, Miller SE, Martines RB, Bullock HA, Zaki SR. Electron microscopy of SARS-CoV-2: a challenging task. *Lancet.* 2020;395(10238):e99.

Multicenter Clinicopathologic Correlation of Kidney Biopsies Performed in COVID-19 Patients Presenting With AKI or Proteinuria

Setting	Clinical Presentation	Pathologic Findings
 <p>7 large referral centers in US</p> <p>N = 17</p> <p>9 female, 8 male 8 Black, 5 Hispanic</p>  <p>14 native kidney 3 allograft kidney</p>	 <p>N = 14 (82%) with MILD COVID-19 symptoms (eg cough, fatigue)</p>  <p>Kidney disease manifested within 1 week of COVID-19</p>  <p>Indication for biopsy: N = 15 (88%) AKI N = 11 (65%) Proteinuria</p>	 <p>Acute tubular injury N = 15 (88%)</p>  <p>Collapsing glomerulopathy N = 7 (41%)</p>  <p>Thrombotic microangiopathy N = 6 (35%)</p>

CONCLUSION: Even with mild COVID-19 disease, patients can present with AKI and/or proteinuria. Collapsing glomerulopathy and thrombotic microangiopathy are frequently seen and can lead to irreversible injury requiring dialysis.

Shreeram Akilesh, Cynthia C. Nast, Michifumi Yamashita, et al (2020)

@AJKDonline | DOI: 10.1053/j.ajkd.2020.10.001

