

# An anterior segment optical coherence tomography study of the anterior chamber angle after implantable collamer lens-V4c implantation in Asian Indian Eyes

Rashmi Singh, Murugesan Vanathi, Alisha Kishore, Radhika Tandon, Divya Singh

**Purpose:** To quantitatively assess anterior chamber and angle parameters by anterior segment optical coherence tomography (AS-OCT) in myopic eyes undergoing Implantable Collamer Lens (ICL V4c) implantation. **Methods:** Prospective noncomparative observational case series. Pre and postoperative (1<sup>st</sup> and 3<sup>rd</sup> month) AS-OCT angle parameters (anterior chamber depth [ACD], anterior chamber angle [ACA], Angle opening distance [AOD], trabecular iris space area [TISA], scleral spur angle [SSA]) were evaluated in 32 eyes (16 patients). SPSS version 20 with paired *t*-test for intragroup and Mann-Whitney U value test for intergroup comparisons. **Results:** It included 6 (37.5%) males and 10 (62.5%) females. Preoperative ACA of  $34.6 \pm 2.3^\circ$  reduced to  $32.2 \pm 2.4^\circ$ ,  $31.9 \pm 2.5^\circ$  at 1 and 3 months postoperatively ( $P = 0.001$ ). Preoperative mean AOD500, AOD750, TISA500, TISA750, SSA of  $0.34 \pm 0.06$  mm,  $0.52 \pm 0.15$  mm,  $0.09 \pm 0.02$  mm<sup>2</sup>,  $0.20 \pm 0.04$  mm<sup>2</sup>,  $34.27 \pm 4.6^\circ$  decreased to  $0.32 \pm 0.06$  mm,  $0.48 \pm 0.15$  mm,  $0.08 \pm 0.02$  mm<sup>2</sup>,  $0.17 \pm 0.05$  mm<sup>2</sup>,  $32.5 \pm 4.3^\circ$  at 1-month ( $P = 0.001$ );  $0.32 \pm 0.06$  mm,  $0.47 \pm 0.13$  mm,  $0.08 \pm 0.02$  mm<sup>2</sup>,  $0.17 \pm 0.05$  mm<sup>2</sup> and  $32.4 \pm 4.6^\circ$  ( $P = 0.001$ ) at 3-months, respectively. Correlation analysis between preoperative ACD/intraocular pressure (IOP) was  $-0.62$  ( $P = 0.0002$ ) [1<sup>st</sup> month],  $-0.40$  (0.024) [third month]; between IOP/postoperative ACA, AOD500, AOD750, TISA500, TISA750, SSA was  $-0.04$  (0.81),  $-0.03$  (0.85),  $-0.08$  (0.64),  $-0.12$  (0.48),  $-0.10$  (0.57),  $-0.06$  (0.73) at 1 month;  $-0.09$  (0.58),  $0.04$  (0.78),  $0.12$  (0.48),  $-0.02$  (0.9),  $-0.04$  (0.79),  $0.02$  (0.88) at 3 months; between ICL vault/ACA, AOD500, AOD750, TISA500, TISA750, SSA was  $0.38$  (0.02),  $0.24$  (0.17),  $0.21$  (0.25),  $0.05$  (0.75),  $0.15$  (0.41),  $0.27$  (0.13) at 1<sup>st</sup> month;  $0.19$  (0.28),  $0.06$  (0.71),  $-0.03$  (0.85),  $0.005$  (0.97),  $0.05$  (0.78),  $0.07$  (0.68) at 3<sup>rd</sup> month. **Conclusion:** Postoperatively significant angle narrowing was noted. There was a negative correlation between IOP and preoperative ACD. There was no significant correlation between IOP and ICL vault with postoperative AS-OCT angle parameters.

**Key words:** Angle, anterior chamber, anterior segment optical coherence tomography, ICL V4c, myopia, phakic IOL

The use of Visian Implantable Collamer Lenses (ICLs, STAAR Surgical, Monrovia, CA, USA), which are soft, foldable, sulcus-placed posterior chamber phakic intraocular lenses, is a well-accepted surgical treatment for high myopic refractive errors.<sup>[1-3]</sup> ICL implantation for high-myopic correction has resulted in significant changes in anterior chamber angle (ACA), depth and volume.<sup>[4]</sup> The iridocorneal angle was noted to have narrowing in different quadrants after ICL-V4c implantation, which remained stable at 3 months in photopic and scotopic conditions.<sup>[5,6]</sup> In view of the increasing adoption of ICL, this study of the AC parameters measurements in ICL was undertaken.<sup>[7,8]</sup>

## Methods

### Study design

This was a prospective, longitudinal, noncomparative observational, pilot study that was done in accordance with the tenets of the Declaration of Helsinki. Ethical clearance was obtained. Thirty-two eyes of 16 patients with high myopia undergoing ICL V4c implantation, between the

age of 20 and 40 years with a stable refractive error for the previous 2 years who were not amenable to laser refractive surgery correction and willing to participate in the study were included. All patients with pathological myopia, anterior chamber depth (ACD) less than 2.8 mm, previous history of ocular inflammation or glaucoma, and concurrent corneal or retinal disease and specular count less than 2500 cells/mm<sup>2</sup> were excluded from the study. All surgeries were performed by a single surgeon by following a standard protocol.

### Data collection

The preoperative details included uncorrected visual acuity (UCVA), best-corrected visual acuity (BCVA), refractive error, slit-lamp examination, intraocular pressure (IOP), pachymetry, endothelial cell count, anterior segment optical coherence tomography (AS-OCT) imaging (Visante, Carl Zeiss Meditec AG, Germany) for iridocorneal angle dimensions.

This is an open access journal, and articles are distributed under the terms of the Creative Commons Attribution-NonCommercial-ShareAlike 4.0 License, which allows others to remix, tweak, and build upon the work non-commercially, as long as appropriate credit is given and the new creations are licensed under the identical terms.

**For reprints contact:** reprints@medknow.com

**Cite this article as:** Singh R, Vanathi M, Kishore A, Tandon R, Singh D. An anterior segment optical coherence tomography study of the anterior chamber angle after implantable collamer lens-V4c implantation in Asian Indian Eyes. Indian J Ophthalmol 2020;68:1418-23.

### Access this article online

#### Website:

www.ijo.in

#### DOI:

10.4103/ijo.IJO\_1540\_19

### Quick Response Code:



Dr Rajendra Prasad Centre for Ophthalmic Sciences, All India Institute of Medical Sciences, New Delhi, India

**Correspondence to:** Dr Murugesan Vanathi, Cornea, Ocular Surface, Cataract and Refractive Services, Dr Rajendra Prasad Centre for Ophthalmic Sciences, All India Institute of Medical Sciences, New Delhi - 110 029, Ansari Nagar, India. E-mail: mvanathi.rpc@gmail.com

Received: 26-Aug-2019

Revision: 27-Dec-2019

Accepted: 01-Feb-2020

Published: 25-Jun-2020

Postoperative UCVA, BCVA, IOP, lens vault (distance between ICL and the anterior surface of lens), ACD, AS-OCT iridocorneal angle measurements were performed at 1 and 3 months. Angle parameters and ICL vault were obtained from AS-OCT images captured by an expert technician [Fig. 1]. The trabecular iris angle (TIA) was measured by tracing a line of 500  $\mu\text{m}$  from the angle recess towards the Schwalbe line and another line on the surface of the iris to the point perpendicular to the first line. The ICL vault was measured by tracing a line from the center of the anterior pole of the crystalline lens to the posterior pole of the ICL. Three scans were taken, and the best quality image was chosen. Angle opening distance 500  $\mu\text{m}$  from the scleral spur (AOD 500; perpendicular distance from the trabecular meshwork 500  $\mu\text{m}$  anteriorly from the scleral spur to the anterior iris surface), Trabecular iris space area 500  $\mu\text{m}$  (TISA500; area bounded anteriorly by AOD, posteriorly by a line from the scleral spur perpendicular to the line of the inner scleral wall to the opposing iris, superiorly by the corneoscleral wall and inferiorly by the iris surface). Similarly, AOD and TISA were measured at 750  $\mu\text{m}$ .<sup>[9,10]</sup> Scleral spur angle (SSA) was also measured using AS-OCT.

### Surgical technique

All surgeries were done under topical anesthesia using 0.5% proparacaine hydrochloride. Pupillary dilatation was achieved with a combination of eye drops containing 1% tropicamide and 2.5% phenylephrine. With a temporal approach, two 1 mm paracentesis ports were made using angled keratome or 15° micro-vitreoretinal blade at 12 and 6 o'clock positions. Hypromellose 2% (Viscomet PF, Unimed technologies) viscoelastic was then injected into the AC by taking care not to overfill the chamber. A temporal 3.2 mm clear corneal incision was made using keratome. The ICL was loaded into the cartridge and injected into the AC. The two paracentesis incisions were used to position the footplates under the iris using the special manipulating instrument (Vukich's manipulator) to ensure that all haptics were tucked posterior to the iris. In the case of toric ICL (TICL) proper alignment was ensured. At the end of

the surgery, viscoelastic was cleared from the AC. A standard postoperative regime consisting of topical prednisolone acetate 1% four times a day for 5 days tapering over 2 weeks and topical moxifloxacin 0.5% four times a day for 2 weeks was followed. Postoperatively, the patient was examined at day 1 to check for proper ICL positioning and lens vault on slit-lamp and AS-OCT, and IOP was checked. The patient was followed up regularly at 1 week, 1 month, 3 months, and 6 months after the surgery. UCVA, BCVA, IOP, central corneal thickness (CCT), ICL vault, and ACD, angle parameters (ACA, AOD500, AOD750, TISA500, TISA750, SSA) were measured using AS-OCT at 1 month and 3 months postoperative period.

### Outcome measures

The primary outcome measure was to assess the changes in IOP, ACD, ACA, AOD 500 and 750, TISA 500 and 750, and SSA after ICL V4c implantation at postoperative day 1, month 1 and 3, and secondary outcome measure was to assess correlation of IOP and ICL lens vault, with the AS-OCT ACA parameter measurements.

### Statistical analysis

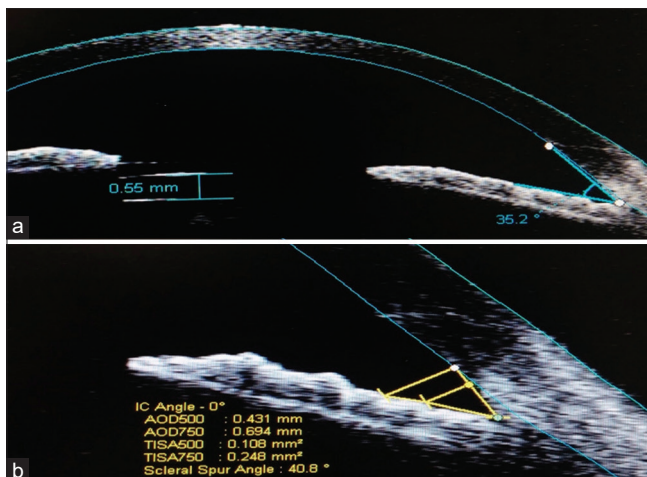The data was analyzed using SPSS version 20 (Statistical Package for Social Sciences) with paired *t*-test for intragroup comparison and Mann-Whitney U value test for intergroup comparison. *P* value of less than 0.05 was considered significant.

## Results

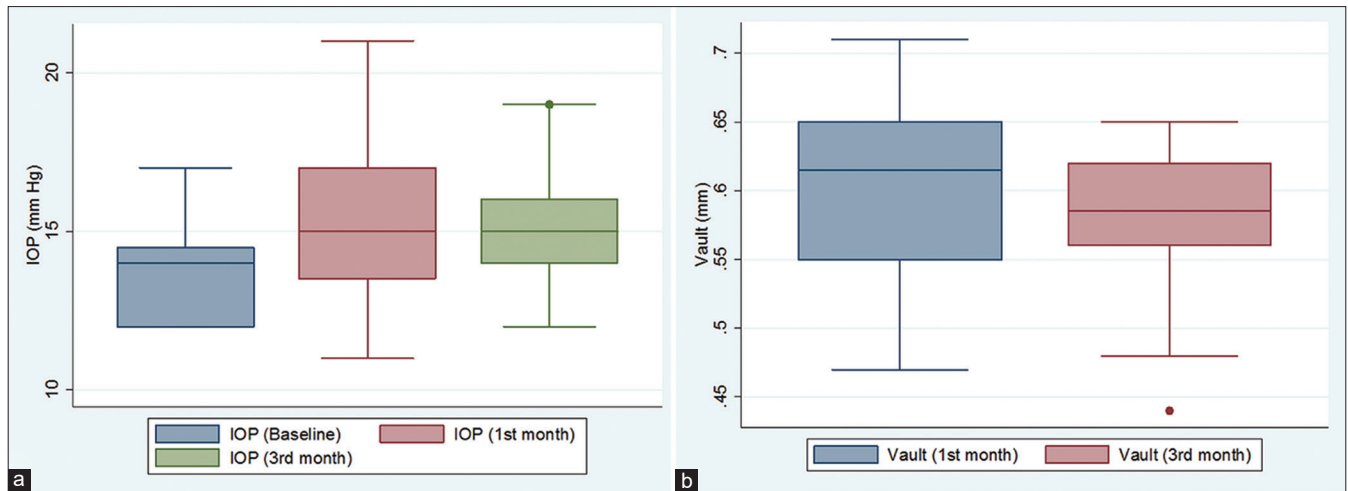Thirty-two eyes of 16 patients were included in this study, of which 10 (62.5%) were females and 6 (37.5%) were males. The mean age of presentation was  $28.7 \pm 3.2$  years. The mean size of the ICL V4c implanted was  $13.2 \pm 0.34$  mm with a mean spherical power of  $-10.43 \pm 3.12$  diopters and mean cylindrical power of  $2.21 \pm 0.21$  dioptres. The mean preoperative ACD was  $3.25 \pm 0.15$  mm (2.95–3.5 mm). The study characteristics are depicted in Table 1; Figs. 2 and 3.

The mean preoperative ACA was  $34.68 \pm 2.34^\circ$  which decreased to  $32.201 \pm 2.453$  at 1 month ( $P=0.001$ ) and  $31.94 \pm 2.52$  at 3 months post-op period ( $P < 0.001$ ). The mean preoperative values of AOD 500 and AOD 750 were  $0.35 \pm 0.06$  mm and  $0.52 \pm 0.15$  mm respectively both of which decreased at 1 month postoperative period to  $0.324 \pm 0.059$  (0.001) and  $0.482 \pm 0.151$  (0.001) and at 3 months postoperative period to  $0.32 \pm 0.06$  (0.001) and  $0.47 \pm 0.13$  (0.001), respectively ( $P < 0.001$ ). The mean preoperative values of TISA 500 and TISA 750 were  $0.09 \pm 0.02$  mm<sup>2</sup> and  $0.2 \pm 0.04$  mm<sup>2</sup>, respectively both of which decreased at one month postoperative period to  $0.08 \pm 0.02$  (0.001) and  $0.17 \pm 0.05$  ( $P=0.001$ ) and 3 months post-op period to  $0.08 \pm 0.02$  and  $0.17 \pm 0.05$  ( $P < 0.001$ ), respectively. The mean value of SSA was  $34.28 \pm 4.6^\circ$  preoperatively which decreased to  $32.5 \pm 4.3^\circ$  ( $P = 0.001$ ) and to  $32.4 \pm 4.6^\circ$  at 1 month and 3 months postoperative period, respectively ( $P < 0.001$ ). It is to be noted that there was no significant difference in any of these parameters between 1 month and 3 months postoperative period.

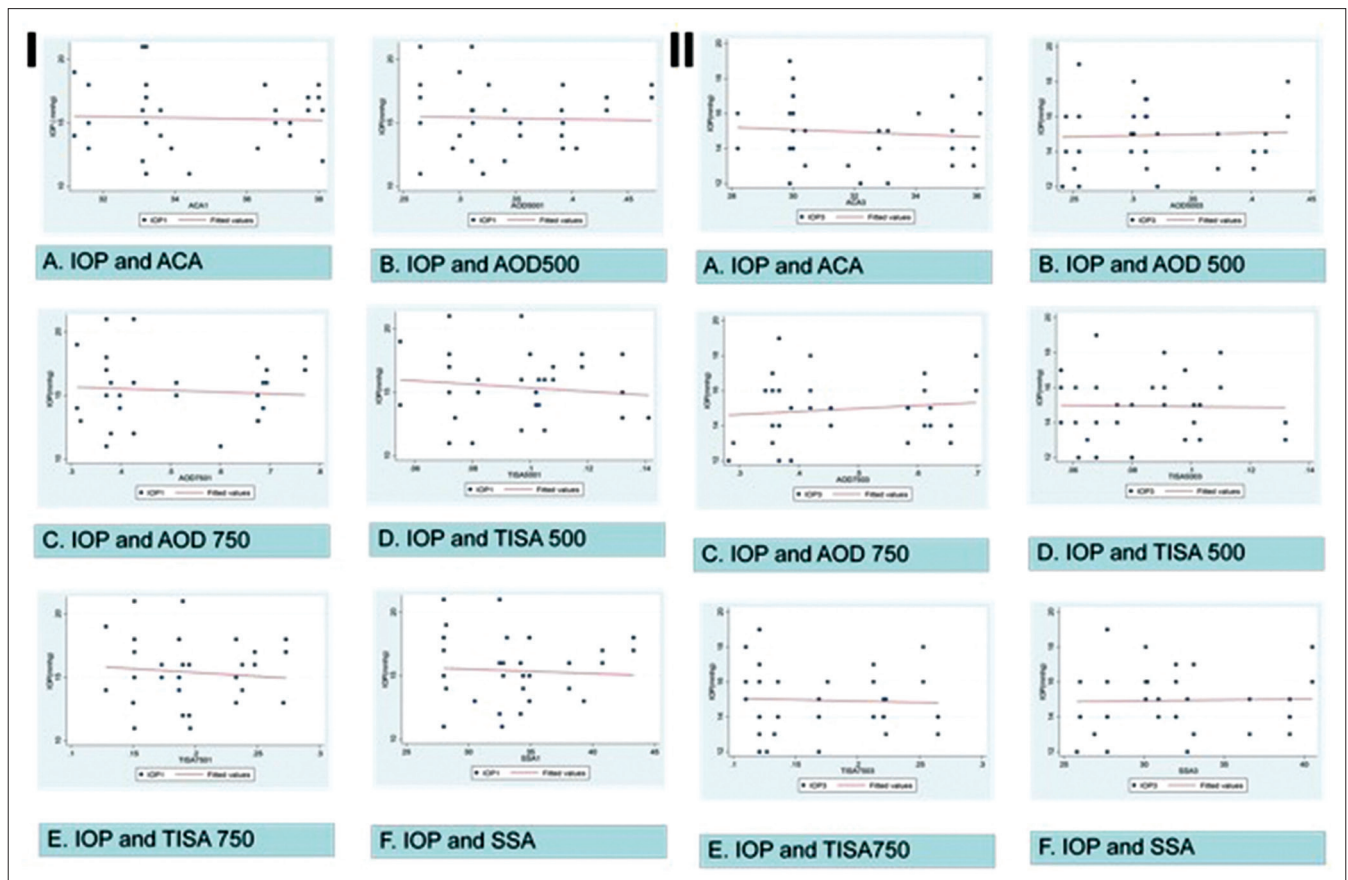
Preoperative IOP of  $13.8 \pm 1.39$  increased to  $15.37 \pm 2.58$  ( $P = 0.021$ ) and to  $14.93 \pm 1.77$  at 3<sup>rd</sup> month ( $P = 0.05$ ). There was no significant difference between IOP at 1<sup>st</sup> month and 3<sup>rd</sup> month ( $P = 0.61$ ). Vault at 1 month was  $0.60 \pm 0.06$  and decreases significantly at 3<sup>rd</sup> month to  $0.58 \pm 0.05$  ( $P = 0.02$ ). There was a significant negative correlation between the preoperative ACD and the IOP at postoperative 1<sup>st</sup> and 3<sup>rd</sup> month. The Pearson correlation coefficient between



**Figure 1:** Postoperative anterior segment optical coherence tomography (AS-OCT) picture depicting ACD and Implantable Collamer Lens (ICL) vault (a) and anterior chamber angle parameters measurement (AOD500, AOD750, TISA500, TISA750, ACA and SSA) (b) AOD500: angle opening distance at 500 $\mu\text{m}$ ; AOD750: angle opening distance at 750 $\mu\text{m}$ ; TISA500: trabecular iris space area at 500 $\mu\text{m}$ ; TISA750: trabecular iris space area at 750 $\mu\text{m}$ ; ACA: anterior chamber angle; SSA: scleral spur angle



**Figure 2:** (a) Box whiskers plot showing the intraocular pressure at baseline, 1<sup>st</sup> month and 3<sup>rd</sup>-month postoperative period. (b) Box whiskers plot showing the ICL vault at 1<sup>st</sup> month and 3<sup>rd</sup>-month postoperative period



**Figure 3:** Correlation between intraocular pressure (IOP) and angle parameters at postoperative 1 month (I) and the correlation between IOP and angle parameters at postoperative 3<sup>rd</sup> month (II)

preoperative ACD and the IOP at 1<sup>st</sup> and 3<sup>rd</sup> month was noted to be  $-0.6185$  ( $P = 0.0002$ ) and  $-0.3976$  ( $0.0242$ ), respectively.

Analysis for correlation of IOP and ICL vault with AC parameters at postoperative months 1 and 3 [Table 2; Figs. 3 and 4] did not reveal any significant correlation. None of the patients needed exchange or explantation of the ICL V4c in our study. No other complications such as postoperative uveitis,

angle-closure attacks, cataract formation, retinal detachment, or endophthalmitis were noted in this study.

### Discussion

ICL is an FDA-approved modality for refractive correction in patient unsuitable for corneal ablation. It is reversible procedure and can correct wide range of refractive errors



including myopia, hypermetropia, and astigmatism.<sup>[11]</sup> The most recently introduced model of ICL is V4c, which has central small opening known as CentraFLOW. It comes with various advantages including no need of peripheral iridotomy (PI) preoperatively, decreased risk of pigment dispersion, intraoperative thorough viscoelastic removal, decreased risk of pupillary block glaucoma, decreasing cataract formation as continuous aqueous current between anterior capsule of lens and posterior surface of ICL is maintained.<sup>[12]</sup> Preoperative ICL planning includes two important parameters that help in choosing appropriate size of lens in particular patient, assessment of ACD, and white-to-white measurement. The ICL sizing has been described in Table 3.

Higuera-Esteban *et al.* compared the V4B and V4C design of ICL to evaluate the safety of V4C ICL without iridotomy.<sup>[13]</sup> They did not find any significant difference between the two designs in terms of IOP and vault in the postoperative period. So, they reached a conclusion that the new ICL with the CentraFLOW provides similar results as its predecessors for correcting moderate to high myopia and maintaining safe IOP levels without the need of iridotomy. Our study also corroborates the above findings. Even though an increase in IOP is seen in the postoperative period, it remains in the physiologic range and there is no record of any acute/

very high increase in IOP in any of our case. Shimizu *et al.* long-term comparison of conventional ICL and ICL with hole evaluated the safety, efficacy, predictability, change in IOP and ACD in the postoperative period and compared the two designs of ICL.<sup>[14]</sup> They did not find any significant change in the IOP in the Hole ICL group or in the conventional ICL group. No significant increase in IOP (>21 mmHg) was noted during the 5-year observation period. Hole ICL group was associated with a significant change in the ACD but not the conventional ICL group. Multiple comparisons demonstrated significant difference between preoperative and postoperative measurements of ACD. We also saw similar findings with the IOP remaining in the normal range in all the cases. Also, the angle parameters as measured by AS-OCT showed a significant decrease as is seen in the above study in terms of ACD.

Eissa *et al.* have done a study to evaluate ACA after ICL implantation.<sup>[15]</sup> They enrolled 54 eyes of 27 patients undergoing V4C phakic posterior chamber Collamer lens implantation for myopic refractive correction. They found a significant increase in IOP which remained the same at 6 and 18 months. ACA measured using Pentacam imaging was found to decrease significantly at 1, 6, and 18 months. They noted a moderate correlation between ICL vault and AC angle. They had concluded that ICL implantation leads to an increase in IOP and a decrease in the

**Table 1: Details of the study characteristics, their comparison in the preoperative and postoperative period**

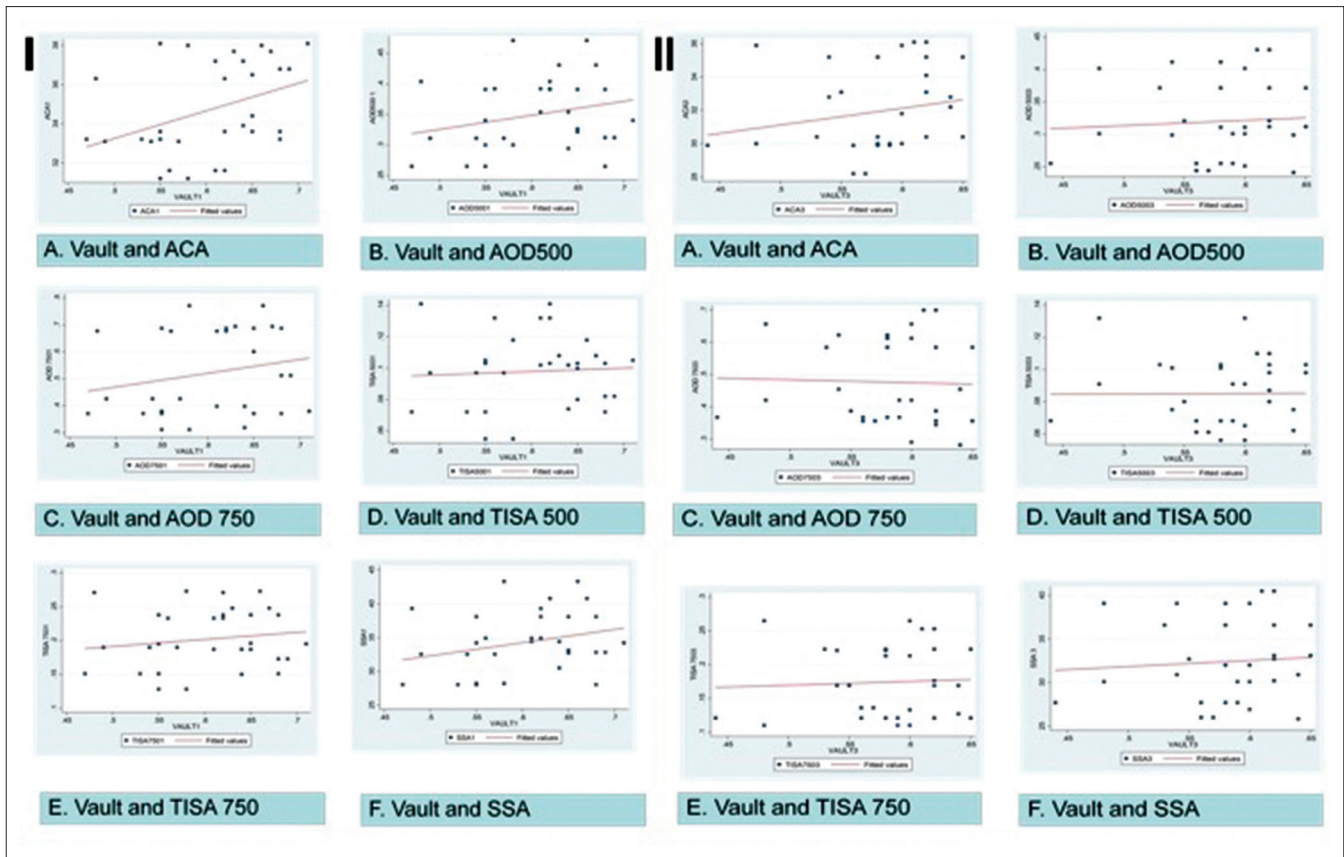
Study parameters	Preoperative	Postoperative	
		1 month	3 months
Mean intraocular pressure (IOP) (mmHg)	13.8±1.39	15.37±2.58 *P=0.021	14.93±1.77 *P=0.05
Mean ICL vault (µm)	-	600±60	580±50
			(**P=0.02)
Trabecular iris angle (TIA) (degrees)	34.684±2.34	32.2±2.4 (*P=0.001)	31.9±2.5 (*P=0.001)
Mean angle opening distance 500 (AOD500) (mm)	0.349±0.61	0.32±0.06 (*P=0.001)	0.32±0.06 (*P=0.001)
Mean AOD 750 (mm)	0.521±0.16	0.48±0.15 (*P=0.001)	0.47±0.13 (*P=0.001)
Mean trabecular iris space area 500 (TISA 500) (mm <sup>2</sup> )	0.098±0.02	0.08±0.02 (*P=0.001)	0.08±0.02 (*P=0.001)
Mean TISA 750 (mm <sup>2</sup> )	0.202±0.04	0.17±0.05 (*P=0.001)	0.17±0.05 (*P=0.001)
Mean scleral spur angle (SSA) (degrees)	34.278±4.62	32.5±4.3 (*P=0.001)	32.4±4.6 (*P=0.001)

\*Paired t-test (in comparison to preoperative value). \*\*Paired t-test (between postoperative months 1 and 3 value) ICL: Implantable Collamer Lens

**Table 2: Correlation analysis of postoperative IOP and ICL vault with anterior chamber angle parameters**

Study variable	ACA	AOD500	AOD750	TISA500	TISA750	SSA
<b>Postoperative month 1 r (P)</b>						
IOP	-0.04 (0.81)	-0.033 (0.85)	-0.083 (0.64)	-0.12 (0.48)	-0.10 (0.57)	-0.06 (0.73)
VAULT	0.38 (0.02)	0.24 (0.17)	0.21 (0.25)	0.05 (0.75)	0.15 (0.41)	0.27 (0.13)
<b>Postoperative month 3 r (P)</b>						
IOP	-0.09 (0.58)	0.04 (0.78)	0.12 (0.48)	-0.02 (0.9)	-0.04 (0.79)	0.02 (0.88)
VAULT	0.19 (0.28)	0.06 (0.71)	-0.03 (0.85)	0.005 (0.97)	0.05 (0.78)	0.07 (0.68)

r (P): Pearson's correlation coefficient, P value; ACA: Anterior chamber angle; AOD500: Angle opening distance at 500µ; AOD750: Angle opening distance at 750µ; TISA500: Trabecular iris space area at 500µ; TISA750: Trabecular iris space area at 750µ; SSA: Scleral spur angle



**Figure 4:** Correlation between ICL vault and angle parameters at postoperative 1 month (i) and the correlation between ICL vault and angle parameters at postoperative 3<sup>rd</sup> month (II)

**Table 3: Pre-operative assessment of ICL sizing based on white to white (WTW) and anterior chamber depth (ACD)**

White to white (mm)	ACD (mm)	ICL size
<10.5	All	Not recommended
10.5-10.6	<=3.5	Not recommended
10.5-10.6	>3.5	12.1
10.7-11.0	All	12.1
11.1	<=3.5	12.1
11.1	>3.5	12.6
11.2-11.4	All	12.6
11.5-11.6	<=3.5	12.6
11.5-11.6	>3.5	13.2
11.7-12.1	All	13.2
12.2	<=3.5	13.2
12.2	>3.5	13.7
12.3-12.9	All	13.7
>=13	All	Not recommended

AC angle with all values maintaining in the physiological range. This study of 32 eyes of 16 patients evaluated the ACA using AS-OCT. We found similar results with the IOP increasing at 1<sup>st</sup> month and remaining the same in the 3<sup>rd</sup>-month postoperative period. The ACA parameters as measured by AS-OCT showed a significant decrease at 1 and 3 months postoperative period. As against the above study, we did not find any significant correlation between IOP, ICL vault, and ACA parameters, but

found a significant negative correlation between the preoperative ACD and the postoperative IOP.

Zhu *et al.* evaluated the AC volume (ACV) (Pentacam imaging) after ICL implantation in 45 eyes of 26 patients with high myopia preoperatively and postoperatively over a mean follow-up period of 4.28 months.<sup>[16]</sup> The mean ACV was found to decrease significantly (a decrease of 40%) from  $198.33 \pm 33.08 \text{ mm}^3$  before surgery to  $118.65 \pm 17.70 \text{ mm}^3$  after surgery. They found a positive correlation between postoperative ACV and ACA and concluded the ACV to be a sensitive parameter that is complementary to vault and ACD in preoperative assessment and postoperative monitoring of ICL patients.

We used AS-OCT imaging to assess the ACA parameters. This study shows similar results with the angle parameters decreasing significantly in the postoperative period. Postoperative IOP shows a negative correlation with the preoperative ACD. The above two findings enhance the importance of measuring ACD as well as angle parameters which can act as a guide while selecting ideal candidates for ICL surgery.

Elmohamady *et al.* evaluated AC changes after ICL implantation in 34 patients with high myopia who underwent ICL implantation using Pentacam imaging and noted that the average ACA decreased significantly from  $36.93^\circ \pm 4.75^\circ$  preoperatively to  $25.17^\circ \pm 5.64^\circ$  and  $25.23^\circ \pm 6.05^\circ$  at 1 and 3 months, postoperatively.<sup>[17]</sup> Mean ACV was  $191.24 \pm 11.18 \text{ mm}^3$  preoperatively which reduced significantly to  $141.53 \pm 16.77$  and  $142.11 \pm 15.89 \text{ mm}^3$  at 1 and 3 months, postoperatively. Mean central AC depth was  $3.59 \pm 0.17 \text{ mm}$  preoperatively

and decreased to  $2.83 \pm 0.24$  mm and  $2.96 \pm 0.25$  mm at 1 and 3 months postoperatively. The ICL vault decreased significantly ( $P$ -value  $<0.001$ ) from  $0.556 \pm 0.033$  mm at 1 month postoperative period to  $0.431 \pm 0.056$  mm at 3 months postoperatively. They concluded that ICL implantation leads to a significant decrease in ACA, volume, and depth. Our results also concur with their findings with the angle parameters in our study decreasing significantly in the postoperative period as well as vault decreasing from postoperative 1<sup>st</sup> month to 3<sup>rd</sup> month.

Yan *et al.* have reported the 2-year outcomes of Visian ICL with a central hole (ICL V4c) implantation for correcting high myopia in 61 eyes of 32 patients using Scheimpflug tomography imaging to measure ACV, ACD, ACA width (ACAW), and vault.<sup>[18]</sup> The ACV, ACD, and ACAW were noted to reduce from preoperative values of  $193.28 \pm 29.15$  mm<sup>3</sup>,  $3.15 \pm 0.23$  mm, and  $36.51 \pm 6.54^\circ$  to  $112.48 \pm 17.01$  mm<sup>3</sup>,  $2.99 \pm 0.23$  mm, and  $22.54 \pm 5.27^\circ$  ( $P = 0.0008$ ,  $0.008$ , and  $0.0003$ , respectively). IOP did not show any increase in comparing preoperative and postoperative values. It was seen to be  $15.39 \pm 2.88$  mmHg before surgery and  $15.86 \pm 4.11$  mmHg at 2 years ( $P = 0.11$ ).

This study shows a significant narrowing of the ACA parameters at postoperative months 1 and 3, in comparison to the preoperative values. We noted that all the AS-OCT ACA parameters TIA, AOD 500, AOD 750, TISA 500, TISA 750, and SSA reduced significantly ( $P=0.001$ ) at 1 month and 3 months ( $P=0.001$ ) postoperatively when compared to the preoperative values. No significant difference was noted between 1 month and 3 months postoperative values ( $P = 0.21$ ). Preoperative IOP of  $13.8 \pm 1.39$  mmHg increased to  $15.37 \pm 2.58$  mmHg ( $P=0.021$ ) and to  $14.93 \pm 1.77$  mmHg at 3<sup>rd</sup> month ( $P=0.05$ ). There was no significant difference between IOP at 1<sup>st</sup> month and 3<sup>rd</sup> month ( $P$ -value =  $0.61$ ). Though considerable angle narrowing was detected at both 1 and 3 months after ICL V4c implantation, there seemed no correlation between the IOP, ICL vault, and the ACA parameters which is suggestive that the CentraFLOW design precludes the affection on the IOP despite ACA narrowing caused by the ICL implantation in the sulcus. There was a significant negative correlation between the preoperative ACD and the IOP at 1<sup>st</sup> month and 3<sup>rd</sup> month postoperatively [ $r = -0.6185$  ( $P = 0.0002$ ) and  $r = -0.3976$  ( $0.024$ ), respectively]. Considering that the ACA parameters narrow significantly in the postoperative period, preoperative AS-OCT measurement of angle parameters may be useful in identifying candidates suitable for ICL implantation. Those candidates with preoperative narrow-angle chamber parameters may be excluded from ICL implantation even with the V4c model with the CentraFLOW design.

## Conclusion

ICLV4C is a safe approach to correcting myopia without the need for iridotomy, thus, avoiding the associated inflammation. An increase in IOP is seen in the postoperative period which remains in the physiologic range. The negative correlation between the preoperative ACD and postoperative IOP as well as the significant decrease seen in the AS-OCT angle parameters, both reinforce the importance of measuring the angle parameters before taking up the patient for an ICL surgery.

## Financial support and sponsorship

Nil.

## Conflicts of interest

There are no conflicts of interest.

## References

- Sanders DR, Doney K, POCO M. United States Food and Drug Administration clinical trial of the Implantable Collamer Lens (ICL) for moderate to high myopia: Three-year follow-up. *Ophthalmology* 2004;111:1683-92.
- Sanders DR, Schneider D, Martin R, Brown D, Dulaney D, Vukich J, *et al.* Toric Implantable Collamer Lens for moderate to high myopic astigmatism. *Ophthalmology* 2007;114:54-61.
- Lovisol CF, Reinstein DZ. Phakic intraocular lenses. *Surv Ophthalmol* 2005;50:549-87.
- Elmohamady MN, Abdelghaffar W. Anterior chamber changes after Implantable Collamer Lens implantation in high myopia using pentacam: A prospective study. *Ophthalmol Ther* 2017;6:343-9.
- Fernández-Vigo JI, Macarro-Merino A, Fernández-Vigo C, Fernández-Vigo JA, Martínez-de-la-Casa JM, Fernández-Pérez C, *et al.* Effects of Implantable Collamer Lens V4c placement on iridocorneal angle measurements by Fourier-domain optical coherence tomography. *Am J Ophthalmol* 2016;162:43-52.e1.
- García-De la Rosa G, Olivo-Payne A, Serna-Ojeda JC, Salazar-Ramos MS, Lichtinger A, Gomez-Bastar A, *et al.* Anterior segment optical coherence tomography angle and vault analysis after toric and non-toric Implantable Collamer Lens V4c implantation in patients with high myopia. *Br J Ophthalmol* 2018;102:544-8.
- Kamiya K, Shimizu K, Igarashi A, Kitazawa Y, Kojima T, Nakamura T, *et al.* Posterior chamber phakic intraocular lens implantation: Comparative, multicentre study in 351 eyes with low-to-moderate or high myopia. *Br J Ophthalmol* 2018;102:177-81.
- Dougherty PJ, Priver T. Refractive outcomes and safety of the Implantable Collamer Lens in young low-to-moderate myopes. *Clin Ophthalmol Auckl NZ* 2017;11:273-77.
- Chen X, Miao H, Naidu RK, Wang X, Zhou X. Comparison of early changes in and factors affecting vault following posterior chamber phakic Implantable Collamer Lens implantation without and with a central hole (ICL V4 and ICL V4c). *BMC Ophthalmol* 2016;16:161.
- Fernández-Vigo JI, García-Feijóo J, Martínez-de-la-Casa JM, García-Bella J, Fernández-Vigo JA. Morphometry of the trabecular meshwork *in vivo* in a healthy population using Fourier-domain optical coherence tomography. *Invest Ophthalmol Vis Sci* 2015;56:1782-8.
- Kamiya K, Shimizu K, Igarashi A, Hikita F, Komatsu M. Four-year follow-up of posterior chamber phakic intraocular lens implantation for moderate to high myopia. *Arch Ophthalmol* 2009;127:845-50.
- Packer M. The Implantable Collamer Lens with a central port: Review of the literature. *Clin Ophthalmol* 2018;12:2427-38.
- Higuera-Esteban A, Ortiz-Gomariz A, Gutiérrez-Ortega R, Villa-Collar C, Abad-Montes JP, Fernandes P, *et al.* Intraocular pressure after implantation of the Visian Implantable Collamer Lens with CentraFLOW without iridotomy. *Am J Ophthalmol* 2013;156:800-5.
- Shimizu K, Kamiya K, Igarashi A, Kobashi H. Long-term comparison of posterior chamber phakic intraocular lens with and without a central hole (Hole ICL and conventional ICL) implantation for moderate to high myopia and myopic astigmatism. *Medicine (Baltimore)* 2016;95:e3270.
- Eissa SA, Sadek SH, El-Deeb MWA. Anterior chamber angle evaluation following phakic posterior chamber Collamer lens with CentraFLOW and its correlation with ICL vault and intraocular pressure. *J Ophthalmol* 2016; 2016:1383-89.
- Zhu Y, Zhu H, Jia Y, Zhou J. Changes in anterior chamber volume after implantation of posterior chamber phakic intraocular lens in high myopia. *BMC Ophthalmol* 2018;18:185.
- Elmohamady MN, Abdelghaffar W. Anterior chamber changes after Implantable Collamer Lens implantation in high myopia using Pentacam: A prospective study. *Ophthalmol Ther* 2017;6:343-9.
- Yan Z, Miao H, Zhao F, Wang X, Chen X, Li M, *et al.* Two-year outcomes of Visian Implantable Collamer Lens with a central hole for correcting high myopia. *J Ophthalmol* 2018; 2018:8678352. doi: 10.1155/2018/8678352.