



Since January 2020 Elsevier has created a COVID-19 resource centre with free information in English and Mandarin on the novel coronavirus COVID-19. The COVID-19 resource centre is hosted on Elsevier Connect, the company's public news and information website.

Elsevier hereby grants permission to make all its COVID-19-related research that is available on the COVID-19 resource centre - including this research content - immediately available in PubMed Central and other publicly funded repositories, such as the WHO COVID database with rights for unrestricted research re-use and analyses in any form or by any means with acknowledgement of the original source. These permissions are granted for free by Elsevier for as long as the COVID-19 resource centre remains active.



Case Report

Bioprosthetic Valve Thrombosis and Obstruction Secondary to COVID-19

Guillem Llopis Gisbert, MD, Verónica Vidal Urrutia, MD, Miguel A. Moruno Benita, MD, Ana Payá Chaume, MD, Alberto Berenguer Jofresa, MD, PhD, Andrés M. Cubillos Arango, MD, José L. Pérez Boscá, MD, PhD, and Rafael Payá Serrano, MD, PhD

Consorci Hospital General Universitari de Valencia, Valencia, Spain

ABSTRACT

Patients with COVID-19 may present a hypercoagulable state, with an important impact on morbidity and mortality. Because of this situation pulmonary embolism is a frequent complication during the course of infection. We present the case of a patient recently discharged, after admission with confirmed COVID-19, who developed a pulmonary embolism and thrombosis of a biological mitral valve prosthesis, producing valve obstruction and stenosis. After 15 days of anticoagulant treatment, resolution of the thrombus and normalisation of prosthetic valve function was observed. This case supports current recommendations of administering full-dose anticoagulation therapy to COVID-19 patients with biological heart valve prosthesis, even after the acute phase of infection.

RÉSUMÉ


Les patients atteints de COVID-19 présentent parfois une hypercoagulabilité, ce qui a un retentissement important sur la morbidité et la mortalité. C'est pour cette raison que l'embolie pulmonaire est une complication fréquemment observée chez les patients infectés. Nous présentons le cas d'un patient ayant récemment obtenu son congé de l'hôpital après avoir contracté la COVID-19, qui a présenté une embolie pulmonaire et une thrombose de prothèse mitrale biologique provoquant l'obstruction et la sténose de la valve. Après 15 jours d'anticoagulation, la thrombose s'est résorbée et la prothèse valvulaire fonctionne de nouveau normalement. Ce cas milite en faveur des recommandations actuelles concernant l'administration d'une anticoagulation à dose complète aux patients atteints de COVID-19 ayant une prothèse valvulaire biologique, même après la phase aiguë de l'infection.

Case

We present the case of a 77-year-old man who was admitted to the hospital during recovery from COVID-19 infection, with the diagnosis of pulmonary embolism and severe prosthetic mitral valve stenosis.

The patient had undergone mitral valve replacement with a biological prosthesis in 2017 during treatment for *Staphylococcus aureus* endocarditis with severe valve regurgitation. Follow-up transthoracic echocardiography (TTE) performed in November 2019 showed normal prosthesis function (transmitral gradient of 4 mm Hg). He had been recently admitted to our centre for COVID-19 pneumonia, without requiring intensive care, and was discharged 3 weeks before the reported clinical episode. During the 12 days of his

admission for COVID-19, he received anticoagulation at prophylactic doses (3500 IU bemparin every 24 h), following the current guidelines used in our centre.

The patient presented 2 weeks later to the emergency department reporting dyspnea on light physical exertion. Physical examination showed a blood pressure of 115/80 mm Hg and oxygen saturation of 86%, crackles in both lung bases, and bilateral lower limb edema. We performed 12-lead electrocardiography, observing the presence of sinus tachycardia at 105 beats per minute. Chest radiography showed signs of pulmonary congestion with bilateral pleural effusion. Blood tests showed normal platelet count and high D-dimer (see [Supplemental Table S1](#) for laboratory findings). We requested a contrast-enhanced thoracic and lungs computed tomography scan, which showed filling defects in segmental arteries suggesting the diagnosis of pulmonary embolism (PE). As part of the work-up, we performed TTE, revealing severe prosthetic mitral stenosis ([Fig. 1](#); [Videos 1](#) and [2](#)  view videos online). The mitral valve area estimated by pressure half-time was 0.5–0.6 cm², and the mean transprosthetic gradient was 20 mm Hg, with pulmonary artery systolic pressure estimated to be 85 mm Hg and a dilated

Received for publication August 6, 2020. Accepted October 14, 2020.

Corresponding author: Dr Guillem Llopis Gisbert, Consorci Hospital General Universitari de Valencia, Avenida Tres Cruces, 2, Valencia, Spain (46014). Tel.: +0034608127917, Cardiology Department ext: 187523; fax: +0034963131800.

E-mail: guillemllopis@gmail.com

See page 938.e6 for disclosure information.

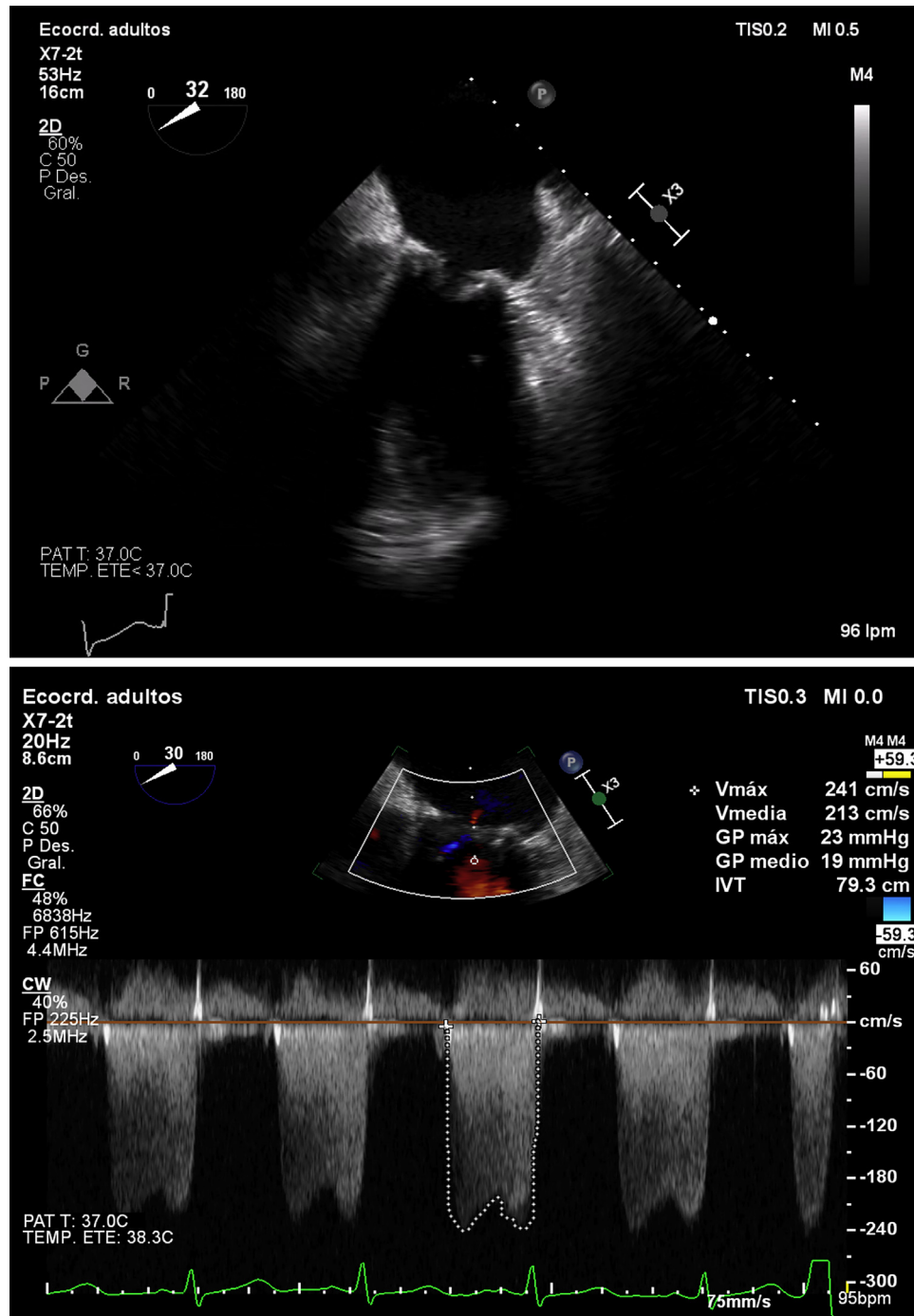


Figure 1. Transesophageal echocardiography (2-dimensional) on admission: mesoesophageal 2-chamber view showing thickened leaflets compatible with laminar thrombus with limited mitral valve opening (transmitral gradient of 19 mm Hg).

right ventricle with systolic dysfunction (TAPSE 11 mm, S' 6.2 cm/s).

Management

On admission, we performed transesophageal echocardiography (TEE), confirming the findings of the TTE, observing thickened leaflets suggesting the presence of a laminar thrombus, with limited opening (valve orifice area of

0.6 cm² as determined by means of 3-dimensional planimetry) and a high mean gradient (19 mm Hg). Blood cultures were negative, and Doppler ultrasound of the lower limbs showed no signs of deep vein thrombosis. We started standard treatment for heart failure with intravenous diuretics and weight-adjusted anticoagulation with low-molecular-weight heparin as part of the treatment for PE. The patient presented a satisfactory clinical response, and follow-up TEE was performed 15 days later, confirming the resolution of the

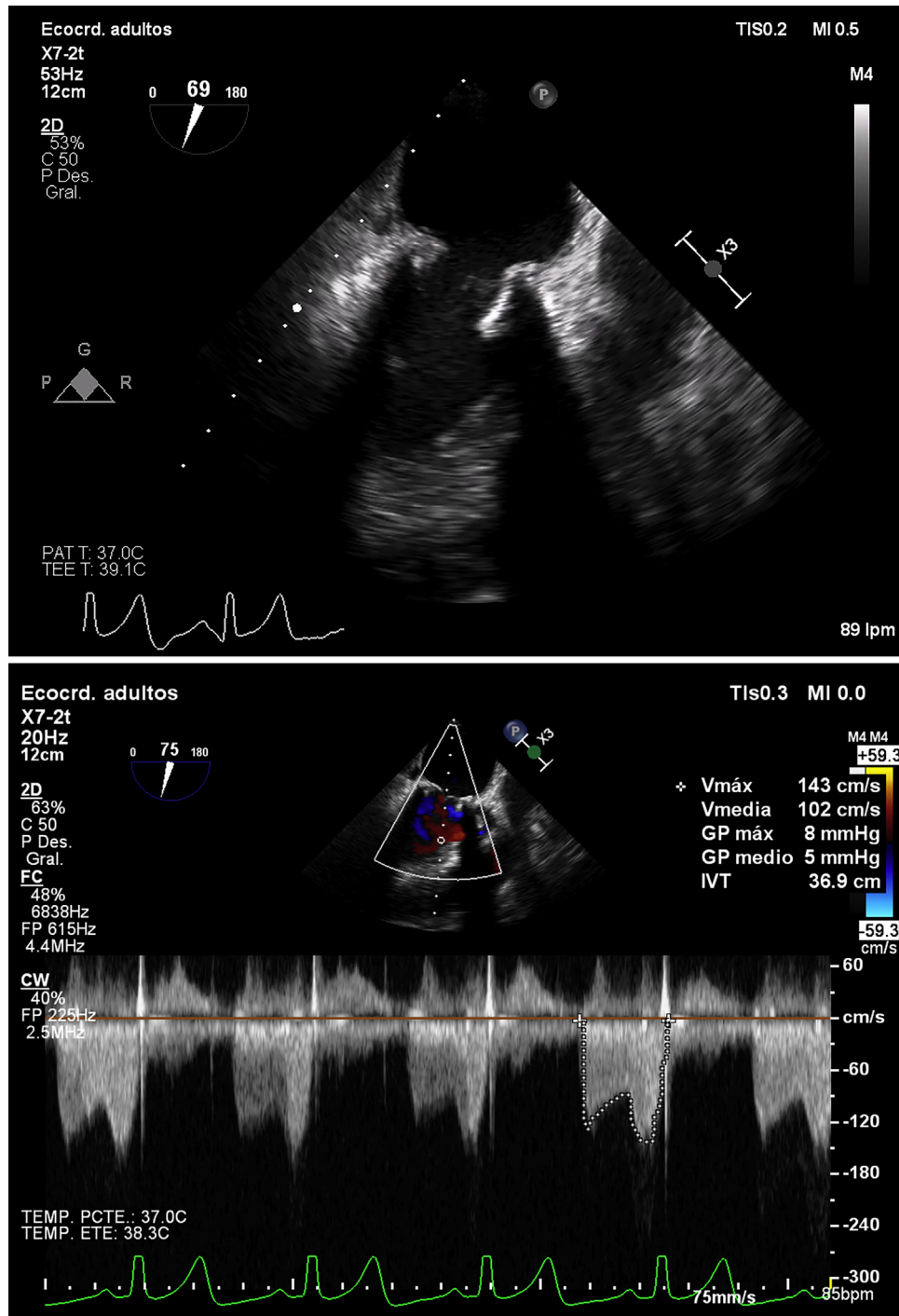


Figure 2. Transesophageal echocardiography (2-dimensional) 15 days later: mesoesophageal 2-chamber view showing resolution of prosthetic stenosis with thin leaflets and normal valve opening, only mild restriction of anterior mitral leaflet persisting with complete telediastolic opening (transmittal gradient of 5 mm Hg).

prosthetic thrombus and stenosis (Fig. 2; Videos 3 and 4) with thin leaflets, normal valve opening (planimetry of 2.1 cm²), and normalisation of the transprosthetic mean gradient (5 mm Hg), and only mild anterior leaflet restriction persisting with complete telediastolic opening.

At hospital discharge, we switched to oral anti-coagulation with vitamin K antagonist (acenocoumarol) for an international normalized ratio goal of 3-3.5, bridging with heparin. We decided on a 3-month duration of anti-coagulation treatment, with further echocardiographic reevaluation.

Discussion

During the pandemic, SARS-CoV-2 infection has been associated with arterial (acute limb ischemia) and venous thromboembolic phenomena (especially at pulmonary level) as well as, less frequently, consumption coagulopathies.¹ This seems to be due to a hypercoagulable state promoted by COVID-19, whose mechanisms have not yet been explained. As far as we know, this may happen as a consequence of endothelial damage secondary to direct viral injury as well as to systemic inflammatory response, where the complement system plays an important role.² Recently, some reported cases have been published, in which PE occurred despite the administration of anticoagulation treatment at prophylactic doses.³ Furthermore, in most cases the thromboembolic event occurred after the acute phase of infection, namely, in the recovery phase.⁴ Therefore, the use of anticoagulation as primary prevention has been proposed despite limited evidence. However, some scientific societies have already made some recommendations about the anticoagulation management,⁵ including the administration of anticoagulant therapy up to 45 days after hospital discharge if there are thrombotic risk factors (eg, reduced mobility, active cancer, elevated D-dimer > 2 times the upper limit of normal) and low risk of bleeding.

We performed a literature review on the topic of COVID-19—associated heart valve prosthesis thrombosis and did not find any cases reporting mechanical or biological prosthesis thrombosis. Typically, bioprosthetic valve thrombosis is a possible but infrequent finding. In this case, the patient had a biological mitral prosthesis thrombosis simultaneously with PE. Making the correct diagnosis was required to provide the patient with the optimal anticoagulation strategy, after which we verified the resolution of the thrombus and consequently of the prosthetic valve stenosis.

We conclude that patients with COVID-19 may present hypercoagulability, causing the occurrence of pulmonary thromboembolism and in some cases also thrombosis of heart valve prostheses, as was the case for this patient 2 weeks after he was discharged from the hospital for COVID-19 pneumonia. With these findings, we support the recommendation of a prolonged anticoagulation strategy at full therapeutic

doses after discharge of selected COVID-19 patients, particularly those with valve prostheses, including biological ones. Further studies are needed to shed light on the role of SARS-CoV-2 in thromboembolic phenomena and to confirm the most appropriate duration of anticoagulation therapy in selected patients.

Funding Sources

The authors have no funding sources to declare.

Disclosures

The authors have no conflicts of interest to disclose.

References

1. Connors JM, Levy JH. COVID-19 and its implications for thrombosis and anticoagulation. *Blood* 2020;135:2033-40.
2. Chauhan AJ, Wiffen LJ, Brown TP. COVID-19: a collision of complement, coagulation and inflammatory pathways. *J Thromb Haemost* 2020;1:2110-7.
3. Mestre-Gómez B, Lorente-Ramos RM, Rogado J, et al. Incidence of pulmonary embolism in noncritically ill COVID-19 patients. Predicting factors for a challenging diagnosis. *J Thromb Thrombolysis* 2021;51:40-6.
4. Langer F, Kluge S, Klamroth R, et al. Coagulopathy in COVID-19 and its implication for safe and efficacious thromboprophylaxis. *Hamostaseologie* 2020;40:264-9.
5. Bikdeli B, Madhavan MV, Jimenez D, et al. COVID-19 and thrombotic or thromboembolic disease: implications for prevention, antithrombotic therapy, and follow-up: JACC state-of-the-art review. *J Am Coll Cardiol* 2020;75:2950-73.

Supplementary Material

To access the supplementary material accompanying this article, visit the online version of the *Canadian Journal of Cardiology* at www.onlinecjc.ca and at <https://doi.org/10.1016/j.cjca.2020.10.008>.