

Review of the pathology underlying benign paroxysmal positional vertigo

Journal of International Medical Research

48(4) 1–12

© The Author(s) 2019

Article reuse guidelines:

sagepub.com/journals-permissions

DOI: 10.1177/0300060519892370

journals.sagepub.com/home/imr**Sertac Yetiser** 

Abstract

The pathophysiological mechanism underlying benign paroxysmal positional vertigo (BPPV) is related to free-floating debris/otoliths in the semicircular canal (canalolithiasis) or debris/otoliths attached to the cupula (cupulolithiasis). These debris/otoliths are considered to originally accumulate after detachment from the neuroepithelium of the utricular macula secondary to a type of degeneration. An idiopathic form, which is assumed to occur spontaneously, is diagnosed when the causative pathology is obscure. However, an association between various other systemic or inner ear conditions and BPPV has been reported, indicating the existence of secondary BPPV. This study was performed to present the first review of the pathology underlying BPPV following a complete PubMed/Medline search. In total, 1932 articles published from 1975 to 2018 were reviewed. The articles were classified according to 17 potentially causative factors (aging; migraine; Meniere's disease; infection; trauma; idiopathic sudden sensorineural hearing loss; sleeping habits; osteoporosis and vitamin D insufficiency; hyperglycemia and diabetes mellitus; chronic head and neck pain; vestibule or semicircular canal pathology; pigmentation disorders; estrogen deficiency; neurological disorders; autoimmune, inflammatory, or rheumatologic disorders; familial or genetic predisposition; and allergy). A discussion of the underlying cause of BPPV for each factor is presented.

Keywords

Benign paroxysmal positional vertigo, aging, trauma, migraine, Meniere's disease, vestibular neuronitis, vitamin D deficiency

Date received: 5 September 2019; accepted: 13 November 2019

Introduction

Benign paroxysmal positional vertigo (BPPV) can be defined as transient, position-induced torsional, vertical, or horizontal nystagmus with vertigo. Symptoms

Department of Otolaryngology–Head and Neck Surgery, Anadolu Medical Center, Gebze, Kocaeli, Turkey

Corresponding author:

Sertac Yetiser, Department of Otolaryngology–Head and Neck Surgery, Anadolu Medical Center, Cumhuriyet Mahallesi, 2255 sokak, No. 3, Gebze, Kocaeli 41400, Turkey.

Email: sertac.yetiser@anadolusaglik.org



Creative Commons Non Commercial CC BY-NC: This article is distributed under the terms of the Creative

Commons Attribution-NonCommercial 4.0 License (<https://creativecommons.org/licenses/by-nc/4.0/>) which permits non-commercial use, reproduction and distribution of the work without further permission provided the original work is attributed as specified on the SAGE and Open Access pages (<https://us.sagepub.com/en-us/nam/open-access-at-sage>).

are provoked in association with a specific head position. The diagnosis is supported by the brief latency, limited duration, fatigability, and reversibility of the nystagmus upon returning to an erect position. The pathology is based on displacement of the cupula due to either free-floating debris/otoliths in the semicircular canal (canalolithiasis) or attachment of debris/otoliths to the cupula (cupulolithiasis).

Any inner ear pathology that detaches the otoconia appears to be capable of causing BPPV. Secondary BPPV is diagnosed when an associated cause is clearly identified. However, the underlying pathology is often obscure; in such cases, idiopathic BPPV is diagnosed.¹ This study was performed to review the pathologies possibly underlying the occurrence of BPPV.

Review of the literature

A review of the literature on the pathology underlying BPPV was conducted. The articles were identified by means of a search of the PubMed database using the keyword "BPPV," which yielded 1932 articles. The search included articles published from 1975 to 2018. In total, 545 articles were reviewed for the study after exclusion of those that were not published in English, those that were technical or guideline reports, those based on the outcomes of a specific treatment method or analysis of quality of life only, experimental studies that focused on a mathematical model of BPPV, and single case reports. Comparative studies were excluded if the discussion of the underlying pathology was not clear. If more than one article by the same author(s) or institution was found, only the most recent article matching the aforementioned criteria and those that were not overlapping were included.

Seventeen factors possibly associated with the pathology underlying BPPV were identified: aging; migraine; Meniere's

disease; trauma; infection and vestibular neuronitis; idiopathic sudden sensorineural hearing loss; sleeping habits; osteoporosis and vitamin D insufficiency; hyperglycemia and diabetes mellitus; chronic head and neck pain; vestibule or semicircular canal pathology; pigmentation disorders; estrogen deficiency; neurological disorders; autoimmune, inflammatory, or rheumatologic disorders; familial or genetic predisposition; and allergy.

Findings

After searching articles regarding BPPV in older people, including reports focused on the aging of the labyrinth, 78 articles were selected. Forty-seven articles were about the association of migraine and BPPV; 56 were about Meniere's disease and BPPV; 37 were about viral infections and vestibular neuronitis, which may have a role in the pathogenesis of BPPV; 63 were about BPPV following trauma; 25 were about idiopathic sudden sensorineural hearing loss accompanying BPPV; 21 were about the role of sleeping habits in BPPV; 41 investigated the relationship among vitamin D levels, osteoporosis, and BPPV; 15 focused on the association among hyperglycemia, diabetes mellitus, and BPPV; 8 were about the relationship among myalgia, fibromyalgia, chronic neck pain, and BPPV; 18 investigated vascular or anatomical abnormalities, including a large vestibular aqueduct, Arnold-Chiari malformation, abnormalities in the vertebral and basilar arteries, hypoplasia of the semicircular canals, and other conditions that may have a role in the pathogenesis of BPPV; 2 were about the relationship between BPPV and pigmentation disorders; 5 were about estrogen deficiency in BPPV; 9 focused on the association of BPPV and neurological disease, including multiple sclerosis and Parkinson disease; 12 were about possible defects associated with autoimmunity in patients with BPPV;

and 4 were about the familial incidence and possible genetic role in the pathogenesis of BPPV. No article addressed the association between BPPV and allergy. The distribution of these articles about the pathogenesis of BPPV is shown in Figure 1.

Discussion

Aging

Aging is a risk factor for utricular dysfunction in idiopathic BPPV.² Animal studies have indicated the occurrence of otoconial degeneration with aging.^{3,4} The incidence of BPPV is higher at advanced ages, and it has been rarely reported to occur in children. Picciotti et al.⁵ reviewed 475 patients with BPPV and found that comorbidities were present in 72.6% of patients with recurrent BPPV, and this incidence was higher in female and older patients. Yetiser and Ince⁶ reviewed the age distribution of 263 patients from 10 to 84 years of age and found that 5 patients were younger than 20 years. Bachor et al.³ reviewed 186

temporal bones from 121 individuals between the ages of newborn and 10 years. They found that the incidence of basophilic cupular deposits, which have been clinically implicated in BPPV, was 12.7%. The lower occurrence in children than adults suggested that the accumulation of deposits could be due to aging of the vestibular labyrinth. The average age at onset of the first episode of BPPV is >50 years. Residual symptoms such as dizziness and balance disorders are more common after otolith repositioning in older patients, and the recurrence rate is high.^{2,4} This is probably because of otoconia fragmentation secondary to aging. Notably, however, this process is multifactorial.

Migraine

Previous studies have shown that patients with migraine seem more likely to develop BPPV than subjects in the control group.⁷⁻⁹ Kim et al.¹⁰ performed a nationwide cohort study and reported a higher incidence of BPPV in patients with migraine (6.0%)

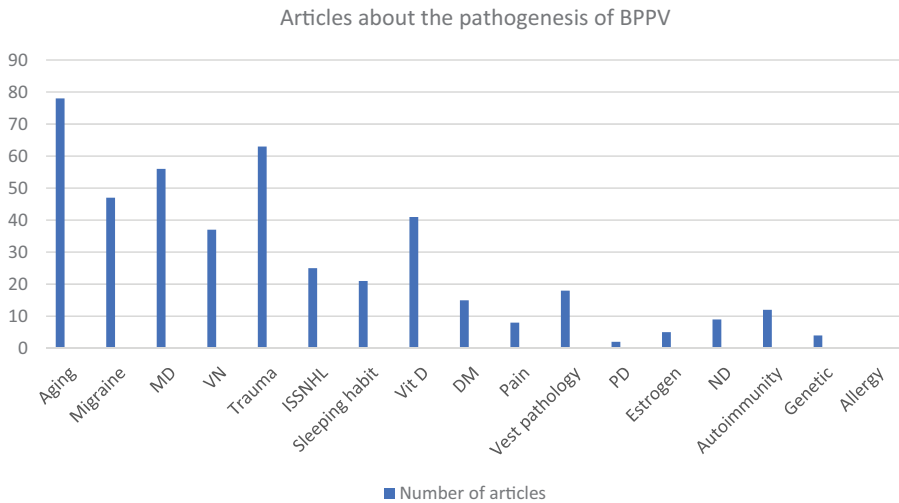


Figure 1. Distribution of articles focusing on the pathogenesis of BPPV. BPPV, benign paroxysmal positional vertigo; MD, Meniere’s disease; VN, vestibular neuronitis; ISSHL, idiopathic sudden sensorineural hearing loss; Vit D, vitamin D deficiency; PD, pigmentation disorder; ND, neurological disorder.

than in control subjects (3.2%). Faralli et al.¹¹ reviewed the recovery time, residual dizziness, and recurrence in patients with BPPV with and without migraine. The authors found no significant difference in the number of maneuvers needed to achieve recovery, and they stated that a direct pathophysiological link between migraine and BPPV is unlikely.¹¹ Yetiser and Gokmen¹² analyzed whether clinical features in patients with BPPV and migraine differ from those in patients with BPPV without migraine. The comparative analysis of the cure rate of the therapeutic maneuvers between the two groups showed no significant differences.

Meniere's disease

Several reports have indicated an association between Meniere's disease and BPPV. The incidence greatly varies from 0.5% to 44.0%.^{1,13-15} Meniere's disease and BPPV may share common pathological ground because of the high incidence of Meniere's disease and BPPV in the same ear.¹⁶⁻¹⁸ Hydropically induced damage to the maculae of the utricle and saccule or partial obstruction of the membranous labyrinth are possible mechanisms underlying the coexistence of Meniere's disease and BPPV.¹⁹⁻²¹ Several studies have shown that when BPPV is associated with Meniere's disease, more therapeutic sessions are needed and the recurrence rate is high.^{16,17,22,23}

Infection and vestibular neuronitis

Viral infections may play a role in the pathogenesis of BPPV. The occurrence of BPPV following vestibular neuronitis is not rare.^{24,25} Hanci et al.²⁶ reported higher serological values for herpesvirus, Epstein-Barr virus, adenovirus, and cytomegalovirus in patients with BPPV than in the control group. BPPV secondary to

vestibular neuronitis is associated with a lower age at onset, more frequent involvement of the posterior canal, greater presence of canal weakness, and higher rate of recurrence.²⁷ Arbusow et al.²⁸ isolated herpes simplex virus in the labyrinth of 48% of studied temporal bones. However, the occurrence of infection-related otoconial detachment needs histopathological confirmation in animal studies.

Trauma

Trauma is a common cause of BPPV. Pisani et al.²⁹ reviewed 3060 patients with a clinical diagnosis of BPPV, and a clear association with a traumatic event was present in 23.4% of patients. Chang et al.³⁰ reviewed 768 patients with BPPV and found that 9.2% of patients with BPPV had undergone previous dental surgery. Gordon et al.³¹ followed the training program of 63 American football players and reported 16 additional cases of BPPV during follow-up. The most common types of trauma were motor vehicle crashes, common falls, temporal bone or stapes surgery, and head trauma.³²⁻³⁵ Acoustic or electrical stimulation, pressure, intense physical activity, and mechanical trauma can lead to otoconial dislodgement.³⁶⁻³⁸ Traumatic BPPV may involve multiple canals and requires repeated maneuvers.^{32,39-41}

Idiopathic sudden sensorineural hearing loss

Idiopathic sudden sensorineural hearing loss may accompany BPPV. The incidence of BPPV among patients with sudden hearing loss ranges from 5.4% to 12.1%.⁴²⁻⁴⁴ Karlberg et al.⁴⁵ reported four cases of sudden hearing loss and ipsilateral posterior canal BPPV, all of which were resolved following a repositioning maneuver. The findings indicated that the pathology was located inside the labyrinth rather than

within the cochleovestibular nerve. Based on these cases, the authors proposed viral labyrinthitis rather than a vascular infarct. Conversely, El-Saied et al.⁴⁶ described five patients with hearing loss and BPPV and proposed a vascular insult as the common pathophysiological mechanism.⁴⁶ It seems that when BPPV is associated with sudden hearing loss, treatment requires several sessions of a repositioning maneuver.^{43,44} Lee and Ban⁴⁷ reviewed 38 patients with sudden hearing loss and BPPV and proposed that the association of these two pathologies represents definite vestibular damage and is closely related to a poor prognosis.

Sleeping habits

Gyo⁴⁸ was one of the first to indicate the occurrence of BPPV in a group of patients following bedrest restrictions after unrelated surgeries. Sleeping habits may be closely associated with the affected side in patients with BPPV. The ear affected by BPPV has been found to be consistent with the head-lying side.^{49,50} Sato et al.⁵¹ and Shim et al.⁵² reported that otoconial debris dislodged from the utricle under the influence of gravity may fall into the lateral or posterior semicircular canals of the undermost ear during sleep. This is seen particularly more often in patients with posterior canal BPPV when the affected ear is down.⁵³ The recurrence rate is high when the patient continues to sleep on the affected side.⁵⁴ Sleeping habits may therefore be associated with hearing loss. Patients with profound unilateral hearing loss often lie on the ear with hearing loss while sleeping to keep the better-hearing ear open to the environment.

Osteoporosis and vitamin D insufficiency

Research on the relationship between vitamin D levels and BPPV is evolving. Otoconia consist of calcium carbonate

crystals, which are connected to saccular and utricular hair cells with protein fibers. Vitamin D receptors regulate transportation of calcium through epithelial channels.⁵⁵ Therefore, vitamin D deficiency may affect the otoconia structure and integrity. The prevalence of a decreased bone mass density among people with BPPV is 81%.⁵⁶ A low serum vitamin D level is a risk factor for BPPV.⁵⁷ Yamanaka et al.⁵⁸ found that the rate of recurrence of BPPV in patients with osteoporosis was significantly higher than that in patients with normal bone mineral density (56.3% vs. 16.1%, respectively). When the symptom severity and recurrence rate were compared between patients with BPPV who had vitamin D deficiency versus a normal serum vitamin level, patients with vitamin D deficiency were found to have more severe symptoms with a longer duration, a lower success rate of repositioning maneuvers, and a higher recurrence rate.^{59,60} The vitamin D level is particularly low in postmenopausal women with BPPV.⁶¹ A low vitamin D level is associated with osteoporosis, and medication to treat osteoporosis can provide protection against BPPV and reduce the incidence of recurrence.^{62,63} Talaat et al.⁶⁴ reported that the rate of recurrence of BPPV in patients with an elevated serum vitamin D level following replacement therapy was quite low during the follow-up period (4%) when compared with that in patients with a low serum vitamin D level (43%).

Hyperglycemia and diabetes mellitus

Disruption of capillary vessels causes microvascular degeneration leading to proximal and distal peripheral sensory and motor neuropathy in patients with chronic hyperglycemia and hyperinsulinemia. Yoda et al.⁶⁵ reviewed 28 temporal bones from 14 patients with type 1 diabetes mellitus and 56 normal temporal bones from 28 age-matched

individuals. The prevalence of cupular and free-floating deposits in the lateral and posterior semicircular canals was significantly higher in the patients with type 1 diabetes mellitus than in the patients with normal temporal bones, and this difference was associated with the duration of disease rather than with aging.⁶⁵ D'Silva et al.⁶⁶ reported that BPPV was seen 46% of patients with type 2 diabetes mellitus compared with 37% of individuals without diabetes mellitus, and the 42% association between type 2 diabetes mellitus and BPPV was mediated by hypertension. Hyperglycemia is also a risk factor for recurrence.⁶⁷

Chronic head and neck pain

Observational studies have indicated a connection between chronic BPPV and headache and neck pain.⁶⁸ Patients with pain benefit from otolith repositioning maneuvers.⁶⁹ Whether myalgia, fibromyalgia, and pain influence detachment of otoconia remains unclear because most such studies are observational and the results are based on self-scoring questionnaires. Whether neck pain is the cause or consequence of BPPV also remains unclear.

Vestibule or semicircular canal pathology

BPPV is usually a self-limiting disease that responds well to repositioning maneuvers. Schratzenstaller et al.⁷⁰ reviewed the magnetic resonance images of patients with atypical and intractable BPPV. They found structural changes such as fractures or filling defects in the semicircular canals. Magnetic resonance imaging is helpful to understand micro-abnormalities of the semicircular canals in patients with persistent symptoms.⁷¹ In contrast, no gross anatomical abnormalities were found in that study.⁷⁰ Recurrent BPPV is reportedly related to volumetric abnormalities of the vestibular aqueduct.⁷² The incidence of

BPPV in patients with a large vestibular aqueduct is approximately 19%.⁷³ However, no evidence-based pathological mechanism was demonstrated.

Pigmentation disorders (vitiligo)

Melanocytes arise from the neural crest and are found in the utricle, saccule, ampulla, and endolymphatic duct and sac. Impaired proliferation of these cells results with white patches of the skin known as vitiligo.⁷⁴ The role and presence of pigment cells in the inner ear are subject to investigation. Melanocytes are particularly present around capillary walls. They seem to have a vasomotor function and play a role in metabolite exchanges.⁷⁵ Vitiligo-associated auditory problems may be related to a degenerative process.⁷⁶ Dawoud et al.⁷⁷ reviewed 30 patients with vitiligo and reported that 17% had BPPV. However, it is difficult to conclude that pigmentation disorders are a cause of BPPV because of the lack of sufficient data.

Estrogen deficiency

The prevalence of BPPV greatly increases with age in both sexes. However, menopausal women are especially susceptible. Decreases in estrogen and progesterone levels can cause inner ear microcirculation disorders in postmenopausal women.⁷⁸ Animal studies have indicated that estrogen receptors are important in otoconia maintenance. Bilateral ovariectomized mice have reduced expression of otoconial components. The density of otoconia decreases but the size of otoconia increases in female ovariectomized rats. Eventually, ectopic debris formation in the ampulla increases under estrogen deficiency.^{79,80}

Neurological disorders

BPPV has been reported in patients with multiple sclerosis and Parkinson's

disease.^{81,82} The association between BPPV and neurological disorders is weak, and data on the pathophysiological mechanism connecting these two clinical disorders are lacking.⁸³ The occurrence of BPPV in patients with neurological disease seems to be coincidental.

Autoimmune, inflammatory, or rheumatologic disorders

Possible defects associated with autoimmunity in patients with BPPV have been a topic of interest. However, conflicting results have been reported. The association of giant cell arteritis and BPPV has been reported in 20% of patients, suggesting an ischemic pattern of otoconia degeneration.⁸⁴ Goto et al.⁸⁵ reviewed reactive oxygen metabolites and circulating soluble vascular cell adhesion molecule to investigate the possible contributory role of angiitis to the onset of BPPV. The results were significant, suggesting alternative pharmacological treatment. Pérez et al.⁸⁶ reported successful intratympanic methylprednisolone treatment in seven of nine patients with persistent posterior canal BPPV. Amor-Dorado et al.⁸⁷ found that the incidence of BPPV among 59 patients with ankylosing spondylitis was low (10%). Modugno et al.⁸⁸ found anti-thyroid antibodies in 27% of patients with BPPV and proposed the existence of immune complex-mediated inner ear disease. However, another study showed no significant difference in the level of thyroid-stimulating hormone, anti-thyroid peroxidase antibody, or anti-thyroglobulin antibody between patients with and without BPPV.⁸⁹

Familial incidence

Gizzi et al.⁹⁰ reviewed the family histories of patients with BPPV, and the results suggested a genetic predisposition to utricular otoconia dislodgement. The authors

compared the familial tendencies between 120 successive patients with BPPV and 120 successive patients with dizziness. Patients with BPPV were five times more likely to have relatives with BPPV than were patients with dizziness (control group). However, no clear hereditary or environmental influence on the development of BPPV was found. Whether BPPV is inherited in an autosomal dominant fashion needs to be confirmed in further studies.⁹¹

Allergy

No research focusing on the association between BPPV and allergy is available.

Conclusion

This review has provided a discussion of some possible underlying causes of BPPV, although the idiopathic form is clearly the most common. Lee et al.⁹² reviewed 718 patients with BPPV. Sixty-nine patients (9.6%) had inner ear disorders associated with BPPV, and the most common pathologies were sudden hearing loss, Meniere's disease, and vestibular neuronitis.⁹² Further studies are required to explore clear links before presenting solid statements. Otoconial degeneration due to aging seems to be important. However, BPPV cannot be solely explained by aging. Secondary problems should be investigated before initiating the clinical decision-making process in patients with BPPV. The gravitational impact of the sleeping position is an interesting factor. Patients should be recommended to sleep on the healthy side following repositioning maneuvers; this is a minor but valuable precaution to reduce recurrence. Additionally, vitamin D and estrogen deficiency should be considered when treating postmenopausal women with BPPV. BPPV following trauma is usually clear in cases of surgery, head trauma, or vehicle accidents. Patients

should also be questioned regarding minor impacts. BPPV occurs in combination with many pathologic conditions. The present review has indicated that aging, trauma, migraine, Meniere's disease, and vestibular neuronitis are the most frequently investigated topics. However, studies of vitamin D deficiency have recently been increasing.

Declaration of conflicting interest

The authors declare that there is no conflict of interest.

Funding

This research received no specific grant from any funding agency in the public, commercial, or not-for-profit sectors.

ORCID iD

Sertac Yetiser  <https://orcid.org/0000-0003-1430-1026>

References

1. Karlberg M, Hall K, Quickert N, et al. What inner ear diseases cause benign paroxysmal positional vertigo? *Acta Otolaryngol* 2000; 120: 380–385.
2. Fujimoto C, Kawahara T, Kinoshita M, et al. Aging is a risk factor for utricular dysfunction in idiopathic benign paroxysmal positional vertigo. *Front Neurol* 2018; 9: 1049. doi: 10.3389/fneur.2018.01049.
3. Bachor E, Wright CG and Karmody CS. The incidence and distribution of cupular deposits in the pediatric vestibular labyrinth. *Laryngoscope* 2002; 112: 147–151.
4. Jang YS, Hwang CH, Shin JY, et al. Age-related changes on the morphology of the otoconia. *Laryngoscope* 2006; 116: 996–1001.
5. Picciotti PM, Lucidi D, De Corso E, et al. Comorbidities and recurrence of benign paroxysmal positional vertigo: personal experience. *Int J Audiol* 2016; 55: 279–284.
6. Yetiser S and Ince D. Demographic analysis of benign paroxysmal positional vertigo as a common public health problem. *Ann Med Health Sci Res* 2015; 5: 50–53.
7. Teixido M, Baker A and Isildak H. Migraine and benign paroxysmal positional vertigo: a single-institution review. *J Laryngol Otol* 2017; 131: 508–513.
8. Uneri A. Migraine and benign paroxysmal positional vertigo: an outcome study of 476 patients. *Ear Nose Throat J* 2004; 83: 814–815.
9. Chu CH, Liu CJ, Lin LY, et al. Migraine is associated with an increased risk for benign paroxysmal positional vertigo: a nationwide population-based study. *J Headache Pain* 2015; 16: 62.
10. Kim SK, Hong SM, Park IS et al. Association between migraine and benign paroxysmal positional vertigo among adults in South Korea. *JAMA Otolaryngol Head Neck Surg* 2019; 145: 307–312.
11. Faralli M, Cipriani L, Del Zompo MR, et al. Benign paroxysmal positional vertigo and migraine: analysis of 186 cases. *B-ENT* 2014; 10: 133–139.
12. Yetiser S and Gokmen MH. Clinical aspects of benign paroxysmal positional vertigo associated with migraine. *Int Tinnitus J* 2015; 19: 64–68.
13. Proctor LR. Results of serial vestibular testing in unilateral Meniere's disease. *Am J Otol* 2000; 21: 552–558.
14. van Esch BF, van Benthem PP, van der Zaag-Loonen HJ, et al. Two common second causes of dizziness in patients with Meniere's disease. *Otol Neurotol* 2016; 37: 1620–1624.
15. Taura A, Funabiki K, Ohgita H, et al. One-third of vertiginous episodes during the follow-up period are caused by benign paroxysmal positional vertigo in patients with Meniere's disease. *Acta Otolaryngol* 2014; 134: 1140–1145.
16. Yetişer S. Co-existence of benign paroxysmal positional vertigo and Meniere's Syndrome. *J Int Adv Otol* 2017; 13: 65–68.
17. Kutlubaev MA, Xu Y and Hornibrook J. Benign paroxysmal positional vertigo in Meniere's disease: systematic review and meta-analysis of frequency and clinical characteristics. *J Neurol*. Epub ahead of print

- 13 August 2019. DOI: 10.1007/s00415-019-09502-x.
18. Luryi AL, Lawrence J, Bojrab D, et al. Patient, disease, and outcome characteristics of benign paroxysmal positional vertigo with and without Meniere's disease. *Acta Otolaryngol* 2018; 138: 893–897.
 19. Jahn AF. Benign positional vertigo and endolymphatic hydrops: what is the connection? *J Laryngol Otol* 2017; 131: 658–660.
 20. Hornibrook J and Bird P. A new theory for Meniere's disease: detached saccular otocornia. *Otolaryngol Head Neck Surg* 2017; 156: 350–352.
 21. Gross EM, Ress BD, Viirre ES, et al. Intractable benign paroxysmal positional vertigo in patients with Meniere's disease. *Laryngoscope* 2000; 110: 655–659.
 22. Balatsouras DG, Ganelis P, Aspris A, et al. Benign paroxysmal positional vertigo associated with Meniere's disease: epidemiological, pathophysiologic, clinical, and therapeutic aspects. *Ann Otol Rhinol Laryngol* 2012; 121: 682–688.
 23. Zhu M, Yu F, Zhou F, et al. Benign paroxysmal positional vertigo associated with Meniere's disease. *J Vestib Res* 2018; 28: 359–364.
 24. Zapala DA, Shapiro SA, Lundy LB, et al. Simultaneous acute superior nerve neurolabyrinthitis and benign paroxysmal positional vertigo. *J Am Acad Audiol* 2006; 17: 481–486.
 25. Mandalà M, Santoro GP, Awrey J, et al. Vestibular neuritis: recurrence and incidence of secondary benign paroxysmal positional vertigo. *Acta Otolaryngol* 2010; 130: 565–567.
 26. Hanci D, Ulusoy S, Muluk NB, et al. Do viral infections have a role in benign paroxysmal positional vertigo? *B-ENT* 2015; 11: 211–218.
 27. Balatsouras DG, Koukoutsis G, Ganelis P, et al. Benign paroxysmal positional vertigo secondary to vestibular neuritis. *Eur Arch Otorhinolaryngol* 2014; 271: 919–924.
 28. Arbusow V, Theil D, Strupp M, et al. HSV-1 not only in human vestibular ganglia but also in the vestibular labyrinth. *Audiol Neurootol* 2001; 6: 259–262.
 29. Pisani V, Mazzone S, Di Mauro R, et al. A survey of the nature of trauma of post-traumatic benign paroxysmal positional vertigo. *Int J Audiol* 2015; 54: 329–333.
 30. Chang TP, Lin YW, Sung PY, et al. Benign paroxysmal positional vertigo after dental procedures: a population-based case-control study. *PLoS One* 2016; 11: e0153092.
 31. Gordon CR, Levite R, Joffe V, et al. Is post-traumatic benign paroxysmal positional vertigo different from the idiopathic form? *Arch Neurol* 2004; 61: 1590–1593.
 32. Park SK, Kim SY, Han KH, et al. Benign paroxysmal positional vertigo after surgical drilling of the temporal bone. *Otol Neurotol* 2013; 34: 1448–1455.
 33. Suarez H, Alonso R, Arocena M, et al. Clinical characteristics of positional vertigo after mild head trauma. *Acta Otolaryngol* 2011; 131: 377–381.
 34. Magliulo G, Gagliardi M, Cuiuli G, et al. Stapedotomy and post-operative benign paroxysmal positional vertigo. *J Vestib Res* 2005; 15: 169–172.
 35. Di Girolamo S, Fetoni AR, Di Nardo W, et al. An unusual complication of cochlear implant: benign paroxysmal positional vertigo. *J Laryngol Otol* 1999; 113: 922–923.
 36. Dan-Goor E, Eden JC, Wilson SJ, et al. Benign paroxysmal positional vertigo after decompression sickness: a first case report and review of the literature. *Am J Otolaryngol* 2010; 31: 476–478.
 37. Giacomini PG, Ferraro S, Di Girolamo S, et al. Benign paroxysmal positional vertigo after intense physical activity: a report of nine cases. *Eur Arch Otorhinolaryngol* 2009; 266: 1831–1835.
 38. Chen G, Li Y, Si J, et al. Treatment and recurrence of traumatic versus idiopathic benign paroxysmal positional vertigo: a meta-analysis. *Acta Otolaryngol* 2019; 139: 727–733.
 39. Aron M, Lea J, Nakku D, et al. Symptom resolution rates of posttraumatic versus non-traumatic Benign paroxysmal positional vertigo: a systematic review. *Otolaryngol Head Neck Surg* 2015; 153: 721–730.
 40. Gökler O, Koçak İ, Aydoğan E, et al. Evaluation of Benign paroxysmal positional

- vertigo in American football players. *J Int Adv Otol* 2018; 14: 295–298.
41. Ahn SK, Jeon SY, Kim JP, et al. Clinical characteristics and treatment of benign paroxysmal positional vertigo after traumatic brain injury. *J Trauma* 2011; 70: 442–446.
 42. Hong SM and Yeo SG. Clinical analysis of patients with idiopathic sudden sensorineural hearing loss and benign paroxysmal positional vertigo. *Acta Otolaryngol* 2013; 133: 439–442.
 43. Kim MB and Ban JH. Benign paroxysmal positional vertigo accompanied by sudden sensorineural hearing loss: a comparative study with idiopathic benign paroxysmal vertigo. *Laryngoscope* 2012; 122: 2832–2836.
 44. Lee JB and Choi SJ. Canal paresis in Benign paroxysmal positional vertigo secondary to sudden sensorineural hearing loss. *Otol Neurotol* 2015; 36: 1708–1713.
 45. Karlberg M, Halmagyi GM, Büttner U, et al. Sudden unilateral hearing loss with simultaneous ipsilateral posterior semicircular canal benign paroxysmal positional vertigo: a variant of vestibulo-cochlear neurolabyrinthitis? *Arch Otolaryngol Head Neck Surg* 2000; 126: 1024–1029.
 46. El-Saied S, Joshua BZ, Segal N, et al. Sudden hearing loss with simultaneous posterior semicircular canal BPPV: possible etiology and clinical implications. *Am J Otolaryngol* 2014; 35: 180–185.
 47. Lee NH and Ban JH. Is BPPV a prognostic factor in idiopathic sudden sensory hearing loss? *Clin Exp Otorhinolaryngol* 2010; 3: 199–202.
 48. Gyo K. Benign paroxysmal positional vertigo as a complication of postoperative bedrest. *Laryngoscope* 1988; 98: 332–333.
 49. Cakir BO, Ercan I, Cakir ZA, et al. Relationship between the affected ear in benign paroxysmal positional vertigo and habitual head-lying side during bedrest. *J Laryngol Otol* 2006; 120: 534–536.
 50. Korres SG, Papadakis CE, Riga MG, et al. Sleep position and laterality of benign paroxysmal positional vertigo. *J Laryngol Otol* 2008; 122: 1295–1298.
 51. Sato G, Sekine K, Matsuda K, et al. Effects of sleep position on time course in remission of positional vertigo in patients with benign paroxysmal positional vertigo. *Acta Otolaryngol* 2012; 132: 614–617.
 52. Shim DB, Kim JH, Park KC, et al. Correlation between the head-lying side during sleep and the affected side by benign paroxysmal positional vertigo involving the posterior or horizontal semicircular canal. *Laryngoscope* 2012; 122: 873–876.
 53. Shigeno K, Ogita H and Funabiki K. Benign paroxysmal positional vertigo and head position during sleep. *J Vestib Res* 2012; 22: 197–203.
 54. Lopez-Escámez JA, Gámiz MJ, Fiñana MG, et al. Position in bed is associated with left or right location in benign paroxysmal positional vertigo of the posterior semicircular canal. *Am J Otolaryngol* 2002; 23: 263–266.
 55. Lundberg YW, Zhao X and Yamoah EN. Assembly of the otoconia complex to the macular sensory epithelium of the vestibule. *Brain Res* 2006; 1091: 47–57.
 56. Parham K, Leonard G, Feinn RS, et al. Prospective clinical investigation of the relationship between idiopathic benign paroxysmal positional vertigo and bone turnover: a pilot study. *Laryngoscope* 2013; 123: 2834–2839.
 57. Jeong SH, Kim JS, Shin JW, et al. Decreased serum vitamin D in idiopathic benign paroxysmal positional vertigo. *J Neurol* 2013; 260: 832–838.
 58. Yamanaka T, Shirota S, Sawai Y, et al. Osteoporosis as a risk factor for the recurrence of benign paroxysmal positional vertigo. *Laryngoscope* 2013; 123: 2813–2816.
 59. Jang YS and Kang MK. Relationship between bone mineral density and clinical features in women with idiopathic benign paroxysmal positional vertigo. *Otol Neurotol* 2009; 30: 95–100.
 60. Kahraman SS, Ozcan O, Arli C, et al. Calcium homeostasis during attack and remission in patients with idiopathic benign paroxysmal positional vertigo. *Otol Neurotol* 2016; 37: 1388–1392.
 61. Han W, Fan Z, Zhou M, et al. Low 25-hydroxyvitamin D levels in postmenopausal female patients with benign paroxysmal positional vertigo. *Acta Otolaryngol* 2018; 138: 443–446.

62. Vibert D, Kompis M and Häusler R. Benign paroxysmal positional vertigo in older women may be related to osteoporosis and osteopenia. *Ann Otol Rhinol Laryngol* 2003; 112: 885–889.
63. Mikulec AA, Kowalczyk KA, Pfitzinger ME, et al. Negative association between treated osteoporosis and benign paroxysmal positional vertigo in women. *J Laryngol Otol* 2010; 124: 374–376.
64. Talaat HS, Kabel AM, Khaliel LH, et al. Reduction of recurrence rate of benign paroxysmal positional vertigo by treatment of severe vitamin D deficiency. *Auris Nasus Larynx* 2016; 43: 237–241.
65. Yoda S, Cureoglu S, Yildirim-Baylan M, et al. Association between type 1 diabetes mellitus and deposits in the semicircular canals. *Otolaryngol Head Neck Surg* 2011; 145: 458–462.
66. D’Silva LJ, Staecker H, Lin J, et al. Retrospective data suggests that the higher prevalence of benign paroxysmal positional vertigo in individuals with type 2 diabetes is mediated by hypertension. *J Vestib Res* 2016; 25: 233–239.
67. Webster G, Sens PM, Salmito MC, et al. Hyperinsulinemia and hyperglycemia: risk factors for recurrence of benign paroxysmal positional vertigo. *Braz J Otorhinolaryngol* 2015; 81: 347–351.
68. Molvaer OI. Chronic Benign paroxysmal positional vertigo (BPPV): A possible cause of chronic, otherwise unexplained neck-pain, headache, and widespread pain and fatigue, which may respond positively to repeated particle repositioning maneuvers (PRM). *Scand J Pain* 2017; 4: 231–232.
69. Iglebakk W, Tjell C and Borenstein P. Treatment of chronic canalithiasis can be beneficial for patients with vertigo/dizziness and chronic musculoskeletal pain, including whiplash related pain. *Scand J Pain* 2017; 8: 1–7.
70. Schratzenstaller B, Wagner-Manslau C, Alexiou C, et al. High-resolution three-dimensional magnetic resonance imaging of the vestibular labyrinth in patients with atypical and intractable benign positional vertigo. *ORL J Otorhinolaryngol Relat Spec* 2001; 63: 165–177.
71. Dallan I, Bruschini L, Neri E, et al. The role of high-resolution magnetic resonance in atypical and intractable benign paroxysmal positional vertigo: our preliminary experience. *ORL J Otorhinolaryngol Relat Spec* 2007; 69: 212–217.
72. Manzari L. Enlarged vestibular aqueduct (EVA) related with recurrent benign paroxysmal positional vertigo (BPPV). *Med Hypotheses* 2008; 70: 61–65.
73. Song JJ, Hong SK, Kim JS, et al. Enlarged vestibular aqueduct may precipitate benign paroxysmal positional vertigo in children. *Acta Otolaryngol* 2012; 132: S109–S117.
74. Moellmann G, Klein-Angerer S, Scollay DA, et al. Extracellular granular material and degeneration of keratinocytes in the normally pigmented epidermis of patients with vitiligo. *J Invest Dermatol* 1982; 79: 321–330.
75. Gill SS and Salt AN. Quantitative differences in endolymphatic calcium and endocochlear potential between pigmented and albino guinea pigs. *Hear Res* 1997; 113: 191–197.
76. Aydogan K, Turan OF and Onart S. Audiological abnormalities in patients with vitiligo. *Clin Exp Dermatol* 2006; 31: 110–113.
77. Dawoud EAE, Ismail EI, Eltoukhy SA, et al. Assessment of auditory and vestibular functions in vitiligo patients. *J Otol* 2017; 12: 143–149.
78. Yang L, Xu Y, Zhang Y, et al. Mechanism underlying the effects of estrogen deficiency on otoconia. *J Assoc Res Otolaryngol* 2018; 19: 353–362.
79. Vibert D, Sans A, Kompis M, et al. Ultrastructural changes in otoconia of osteoporotic rats. *Audiol Neurootol* 2008; 13: 293–301.
80. Yang CJ, Kim Y, Lee HS, et al. Bone mineral density and serum 25-hydroxyvitamin D in patients with idiopathic benign paroxysmal positional vertigo. *J Vestib Res* 2018; 27: 287–294.
81. Frohman EM, Kramer PD, Dewey RB, et al. Benign paroxysmal positioning vertigo in multiple sclerosis: diagnosis, pathophysiology and therapeutic techniques. *Mult Scler* 2003; 9: 250–255.

82. Aranke SV and Sethi KD. Benign paroxysmal positional vertigo in Parkinson's disease. *Neurology* 2003; 61: 1156.
83. van Wensen E, van Leeuwen RB, van der Zaag-Loonen HJ, et al. Benign paroxysmal positional vertigo in Parkinson's disease. *Parkinsonism Relat Disord* 2013; 19: 1110–1112.
84. Amor-Dorado JC, Llorca J, Costa-Ribas C, et al. Giant cell arteritis: a new association with benign paroxysmal positional vertigo. *Laryngoscope* 2004; 114: 1420–1425.
85. Goto F, Hayashi K, Kunihiro T, et al. The possible contribution of angiitis to the onset of benign paroxysmal positional vertigo (BPPV). *Int Tinnitus J* 2010; 16: 25–28.
86. Pérez P, Franco V, Oliva M, et al. A pilot study using intratympanic methylprednisolone for treatment of persistent posterior canal benign paroxysmal positional vertigo. *J Int Adv Otol* 2016; 12: 321–325.
87. Amor-Dorado JC, Barreira-Fernández MP, Vázquez-Rodríguez TR, et al. Benign paroxysmal positional vertigo and clinical test of sensory interaction and balance in ankylosing spondylitis. *Otol Neurotol* 2011; 32: 278–283.
88. Modugno GC, Pirodda A, Ferri GG, et al. A relationship between autoimmune thyroiditis and benign paroxysmal positional vertigo? *Med Hypotheses* 2000; 54: 614–615.
89. Sari K, Yildirim T, Borekci H, et al. The relationship between benign paroxysmal positional vertigo and thyroid autoimmunity. *Acta Otolaryngol* 2015; 135: 754–757.
90. Gizzi M, Ayyagari S and Khattar V. The familial incidence of benign paroxysmal positional vertigo. *Acta Otolaryngol* 1998; 118: 774–777.
91. Gizzi MS, Peddareddygari LR and Grewal RP. A familial form of benign paroxysmal positional vertigo maps to chromosome 15. *Int J Neurosci* 2015; 125: 593–596.
92. Lee NH, Ban JH, Lee KC, et al. Benign paroxysmal positional vertigo secondary to inner ear disease. *Otolaryngol Head Neck Surg* 2010; 143: 413–417.