

# Mandibular Reconstruction with Free Fibula Flap for Medication-related Osteonecrosis of the Jaw in Patients with Multiple Myeloma

Christodoulos Kaoutzanis, MD\*  
 Jason W. Yu, DMD, MD†  
 Z-Hye Lee, MD‡  
 Ashkan Davary, DDS, MD§  
 Kenneth E. Fleisher, DDS, FACSS§  
 Jamie P. Levine, MD†

**Summary:** While bisphosphonates are the cornerstone for management of multiple myeloma, they are associated with medication-related osteonecrosis of the jaw (MRONJ). There are many controversies in the management of MRONJ in this patient population. In this article, we describe a representative case and, along with a literature review, we report the outcomes of our 3 cases with multiple myeloma who underwent mandible reconstruction with vascularized fibula bone grafts after segmental mandible resection for Stage 3 MRONJ over a 3-year period. All patients were male with a mean age of 59 years. All patients had undergone therapy with bisphosphonates and had no other identifiable cause of mandible osteonecrosis. All patients had pathologic mandible fractures associated with intraoral fistulae and exposed bone. Nonsurgical management was attempted in all patients. One patient also underwent debridement of the mandible without resolution of the disease. Mandible reconstruction with an osteocutaneous free fibula flap after segmental mandible resection was performed in all 3 cases without major complications or donor site morbidity. Different bacteria were isolated from the intraoperative tissue cultures in all cases. Computed tomographic imaging revealed bony union without hardware complications in all cases. Mean follow-up was 28 months. In conclusion, we demonstrated that patients with multiple myeloma and advanced MRONJ lesions of the mandible can be managed successfully and safely by segmental resection and reconstruction with vascularized fibula bone graft. (*Plast Reconstr Surg Glob Open* 2020;8:e3186; doi: [10.1097/GOX.0000000000003186](https://doi.org/10.1097/GOX.0000000000003186); Published online 28 October 2020.)

**M**ultiple myeloma is a well-known osteolytic disease that can affect the entire skeleton. While bisphosphonates are the cornerstone for management of multiple myeloma, they are associated with medication-related osteonecrosis of the jaw (MRONJ).<sup>1</sup> Treatment of the necrotic bone remains challenging, especially in

patients with multiple myeloma, as the disease itself is associated with limited bone healing.<sup>2</sup> Given the widespread nature of bony disease, surgical intervention with segmental resection of the mandible and reconstruction with a vascularized bone graft is controversial with a paucity of data. In fact, previous authors advocated against microvascular bone reconstruction in such cases, as there was concern that the transferred bony segment had already been exposed to bisphosphonates and would be affected in a similar manner resulting in osteonecrosis.<sup>3,4</sup> Others expressed concerns related to the effect of antiresorptive drugs on donor site morbidity when using vascularized fibula bone grafts.<sup>5</sup>

We describe a representative case and report the outcomes of 3 patients with multiple myeloma who underwent mandible reconstruction with vascularized fibula bone grafts after segmental mandible resection for medication-related osteonecrosis.

## REPRESENTATIVE CASE

The patient in this case is a 60-year-old white man who was diagnosed with multiple myeloma, primarily affecting

*From the \*Division of Plastic and Reconstructive Surgery, Department of Surgery, UCHHealth University of Colorado Hospital, Aurora, Colo.; †Section of Oral and Maxillofacial Surgery, UCLA School of Dentistry; Division of Plastic and Reconstructive Surgery, David Geffen School of Medicine, University of California Los Angeles, Los Angeles, Calif.; ‡Hansjörg Wyss Department of Plastic Surgery, NYU Langone Health, New York, N.Y.; and §Division of Oral and Maxillofacial Surgery, Department of Surgery, NYU Langone Health, New York, N.Y.*

*Received for publication July 6, 2020; accepted August 22, 2020.*

*Copyright © 2020 The Authors. Published by Wolters Kluwer Health, Inc. on behalf of The American Society of Plastic Surgeons. This is an open-access article distributed under the terms of the [Creative Commons Attribution-Non Commercial-No Derivatives License 4.0 \(CCBY-NC-ND\)](https://creativecommons.org/licenses/by-nc-nd/4.0/), where it is permissible to download and share the work provided it is properly cited. The work cannot be changed in any way or used commercially without permission from the journal.*

**DOI:** [10.1097/GOX.0000000000003186](https://doi.org/10.1097/GOX.0000000000003186)

**Disclosure:** *The authors have no financial interest to declare in relation to the content of this article.*

the vertebral bodies of the lower back approximately 10 years ago. Over the years, he had several courses of chemotherapy. In 2017, he received antiresorptive therapy, specifically Zometa, which caused osteonecrosis of the right mandible with associated osteomyelitis. This was managed for approximately 1 year with multiple courses of antibiotics and oral antiseptic rinses. He presented to our facility with progressive pain in the right mandible and cranial nerve V3 paresthesia. Imaging (magnetic resonance imaging and bone scan) confirmed the diagnosis. Given the refractory nature of the disease, he underwent excisional debridement and marginal resection of the right mandible with local flap for closure, extraction of teeth #27-31, and application of autologous platelet-rich plasma to the right mandible. He initially recovered well, but 2 months later, he developed increasing right mandible pain with associated swelling. Computed tomographic (CT) scan findings revealed a pathologic fracture of the right mandible (Fig. 1). Given the severity of the disease demonstrated through imaging, a decision was made to proceed with segmental resection of the right mandible (parasymphysis to angle) and extraction of tooth #26. Reconstruction of the defect was preplanned with virtual surgical planning and CT angiography was utilized to assess the donor sites. The reconstruction was then completed using a double barrel osteocutaneous free fibula flap that was harvested from the left lower extremity. The peroneal vessels of the flap were anastomosed to the right facial artery and a branch of the right internal jugular vein. In addition, the stump of the right inferior alveolar nerve was coapted to the right mental nerve using an allograft. The postoperative course was unremarkable. Maxillofacial CT scan about 10 months after surgery revealed bony healing without hardware complications (Fig. 2).

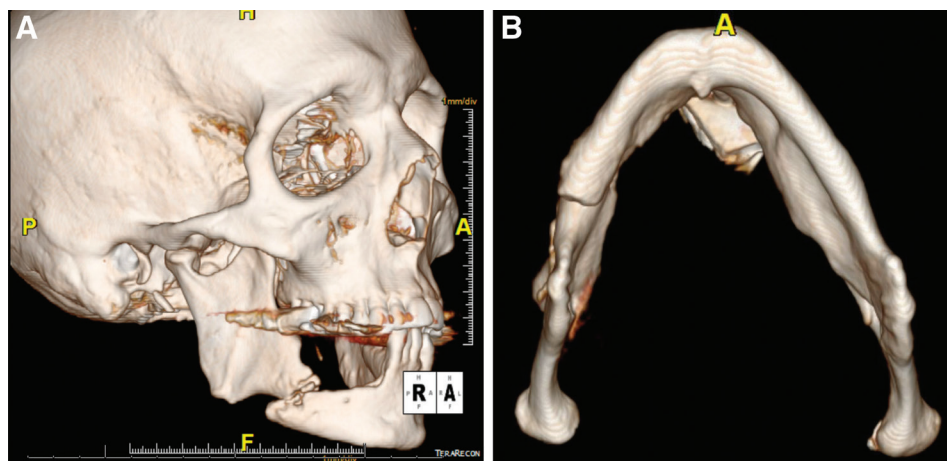
## RESULTS

Between March 2016 and March 2019, 3 male patients with a diagnosis of multiple myeloma underwent mandible reconstruction with vascularized bone graft after segmental mandible resection for MRONJ. Their age

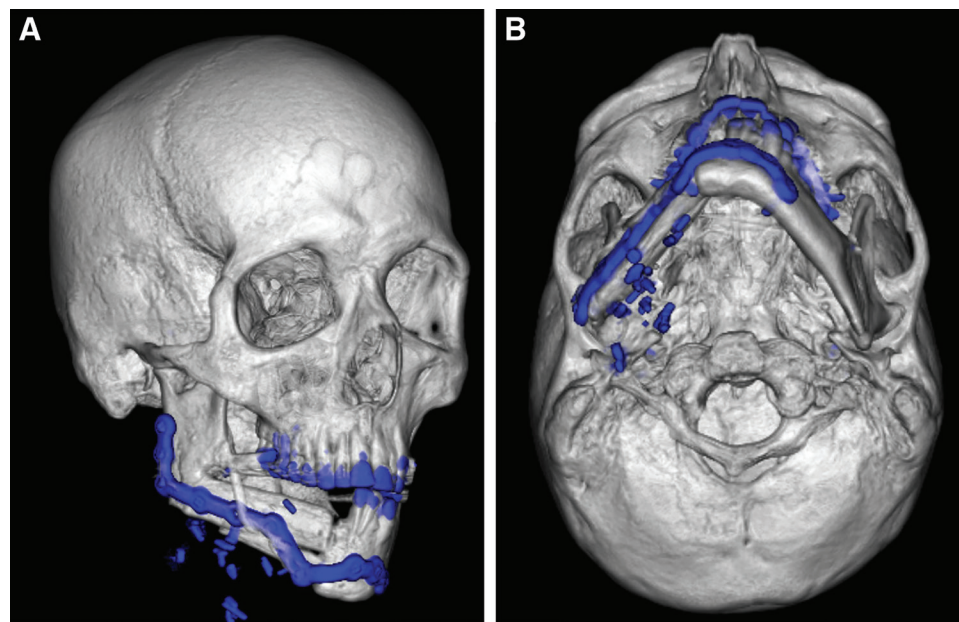
ranged from 55 to 62 years (mean 59 years). All patients had undergone therapy with bisphosphonates and had no other identifiable cause of mandible osteonecrosis (eg, plasmacytoma). All patients presented with symptoms of chronic pain of the mandible and cranial nerve V3 paresthesia. Nonsurgical management with multiple antibiotic courses and oral antiseptic rinses was attempted in all patients. One of the 3 patients also underwent excisional debridement of the mandible without resolution of the disease. Eventually, all 3 patients had pathologic mandible fractures associated with intraoral fistulae and exposed bone. Mandible reconstruction with an osteocutaneous free fibula flap after segmental mandible resection was performed in all three cases. No major complications, free flap failures, emergency room visits, or readmissions were observed within 60 days postoperatively. Pathology of the mandible specimen confirmed osteonecrosis in all 3 cases. Different bacteria were isolated from the intraoperative tissue cultures in all 3 cases; thus, patients completed a 6-week course of antibiotics postoperatively. Length of hospital stay ranged from 7 to 12 days (mean 9 days). Postoperative CT scan was obtained in all cases and revealed bony union without hardware complications. Follow up ranged from 15 to 50 months (mean 28 months). There was no donor site morbidity.

## DISCUSSION

Given the widespread use of bisphosphonates in the management of multiple myeloma, MRONJ continues to be a devastating complication requiring specialized treatment when it occurs. As demonstrated in our case series and multiple previous reports, conservative treatment does not always control the disease, which has a significant impact on the quality of life of these patients.<sup>6-10</sup> Excisional debridement of the mandible has been recommended in advanced cases with promising outcomes.<sup>1,11,12</sup> More recently, the use of autologous leukocyte- and platelet-rich fibrin has also been advocated to promote healing of the mandible.<sup>11,12</sup> Unfortunately, sometimes the disease continues to progress even after implementing conservative surgical measures.



**Fig. 1.** Preoperative maxillofacial CT scan image (3D reconstruction) demonstrating a pathologic fracture of the right mandibular body. A, Oblique lateral view. B, Inferior view.



**Fig. 2.** Postoperative maxillofacial CT scan image (3D reconstruction) at 10 months demonstrating bony healing at the proximal and distal aspects of the double barrel osteocutaneous free fibula flap. A, Oblique lateral view. B, Inferior view.

**Table 1. Literature Review (Including Our Data) of Patients with Multiple Myeloma and MRONJ Who Underwent Segmental Mandible Resection and Reconstruction with Vascularized Free Fibula Graft**

Author	Age	Gender	Bisphosphonate	Initial Treatment	Stage	Fistula	Fracture	Segmental Resection	Free Flap Choice	Complications	Follow-up (mo)
Ferrari et al <sup>7</sup>	66	Male	Pamidronate, Zoledronic acid	1. Curettage 2. Mandibular corticotomy with curettage and PRP treatment	3	Yes	Yes	R ramus to L ramus	Fibula	None	12
Mücke et al <sup>8</sup>	60	Female	Zoledronic acid	Multiple debridements and sequestrectomy	3	Yes	Yes	L mandible	Fibula	None	12
Seth et al <sup>10</sup>	71	Female	Ibandronate	NR	3	No	Yes	NR	Fibula	None	23.7
	51	Female	Zoledronic acid	NR	3	No	Yes	NR	Fibula	None	13.9
Hanasono et al <sup>13</sup>	63	Female	Pamidronate disodium	None	3	Yes	No	R angle to L parasymphysis	Fibula	Recipient site hematoma	13.3
	57	Male	Zoledronic acid	Debridement, mandibulectomy	2	No	No	R parasymphysis to L angle	Fibula	None	20.1
	65	Male	Zoledronic acid	Debridement, HBO	3	Yes	Yes	R angle to L angle	Fibula	None	77
	70	Female	Zoledronic acid	Debridement	3	No	Yes	R angle to L midbody	Fibula	Recipient site infection resulting in free flap loss, small bowel obstruction	8.1
	75	Female	Zoledronic acid	Debridement	2	No	No	R angle to R parasymphysis	Fibula	None	3
Our data	62	Male	Zoledronic acid	None	3	Yes	Yes	L angle to L parasymphysis	Fibula	None	50
	55	Male	Zoledronic acid	None	3	Yes	Yes	L coronoid to L symphysis	Fibula	None	20
	60	Male	Zoledronic acid	Debridement with marginal resection of R mandible, and PRP treatment	3	Yes	Yes	R body to R parasymphysis	Fibula	None	15

HBO, hyperbaric oxygen; L, left; NR, not reported; PRP, platelet-rich plasma; R, right.

Patients present with symptomatic pathologic mandible fractures associated with exposed bone and osteomyelitis. Management of these patients remains challenging given the background of multiple myeloma and concerns for bony healing, limiting further surgical options that can be offered.

Our case series, to the best of our knowledge, is one of the largest in the literature to demonstrate that a more aggressive surgical approach with segmental mandible resection and reconstruction with vascularized free fibula graft can be successfully utilized to address this problem. Literature review revealed only 9 other cases with multiple myeloma and MRONJ undergoing a similar approach with a positive outcome except one patient who had an infection that resulted in the loss of the flap (Table 1).<sup>7,8,10,13</sup> Our results suggest that free vascularized bone graft can be harvested from the lower extremities and used for reconstruction of the mandible as long as the bone from that region is not grossly affected by multiple myeloma, demonstrating osteolytic lesions or severe osteopenia. As a result, careful preoperative planning with imaging of the proposed donor site is a crucial component for the success of this procedure. Preoperative virtual surgical planning has further refined the technique and improved the accuracy of the reconstruction.<sup>14</sup> In addition, aside from the accurate delivery of the mandible resection and reconstruction, intraoperative cultures have to be sent to isolate any specific bacteria. This will guide postoperative antibiotic choice and duration, which has to be done in conjunction with the infectious disease team.

In conclusion, this case series demonstrated that patients with multiple myeloma and advanced MRONJ can be managed successfully and safely by segmental mandible resection and reconstruction with vascularized fibula bone graft. Meticulous preoperative planning along with intraoperative bony cultures and completion of a postoperative antibiotic course are key components for a successful outcome. Although this is a promising approach, further larger studies are necessary to confirm our positive outcomes and evaluate long-term healing in patients undergoing placement of dental implants, or additional chemotherapy, or a stem cell transplant.

**Christodoulos Kaoutzakis, MD**

Division of Plastic & Reconstructive Surgery  
Department of Surgery  
UCHealth University of Colorado Hospital  
Academic Office 1 (AO1), 12631 E. 17th Ave, C309  
Aurora, CO 80045  
E-mail: ckaoutzakis@gmail.com

## REFERENCES

1. Ruggiero SL, Dodson TB, Assael LA, et al; American Association of Oral and Maxillofacial Surgeons. American Association of Oral and Maxillofacial Surgeons position paper on bisphosphonate-related osteonecrosis of the jaws—2009 update. *J Oral Maxillofac Surg.* 2009;67(5 suppl):2–12.
2. Fairfield H, Falank C, Avery L, et al. Multiple myeloma in the marrow: pathogenesis and treatments. *Ann N Y Acad Sci.* 2016;1364:32–51.
3. Marx RE, Sawatari Y, Fortin M, et al. Bisphosphonate-induced exposed bone (osteonecrosis/osteopetrosis) of the jaws: risk factors, recognition, prevention, and treatment. *J Oral Maxillofac Surg.* 2005;63:1567–1575.
4. Ruggiero SL. Bisphosphonate-related osteonecrosis of the jaw: an overview. *Ann N Y Acad Sci.* 2011;1218:38–46.
5. Raguse JD, Trampuz A, Boehm MS, et al. Replacing one evil with another: is the fibula really a dispensable spare part available for transfer in patients with medication-related osteonecrosis of the jaws? *Oral Surg Oral Med Oral Pathol Oral Radiol.* 2020;129:e257–e263.
6. Engroff SL, Kim DD. Treating bisphosphonate osteonecrosis of the jaws: is there a role for resection and vascularized reconstruction? *J Oral Maxillofac Surg.* 2007;65:2374–2385.
7. Ferrari S, Bianchi B, Savi A, et al. Fibula free flap with endosseous implants for reconstructing a resected mandible in bisphosphonate osteonecrosis. *J Oral Maxillofac Surg.* 2008;66:999–1003.
8. Mücke T, Haarmann S, Wolff KD, et al. Bisphosphonate related osteonecrosis of the jaws treated by surgical resection and immediate osseous microvascular reconstruction. *J Craniomaxillofac Surg.* 2009;37:291–297.
9. Nocini PF, Saia G, Bettini G, et al. Vascularized fibula flap reconstruction of the mandible in bisphosphonate-related osteonecrosis. *Eur J Surg Oncol.* 2009;35:373–379.
10. Seth R, Futran ND, Alam DS, et al. Outcomes of vascularized bone graft reconstruction of the mandible in bisphosphonate-related osteonecrosis of the jaws. *Laryngoscope.* 2010;120:2165–2171.
11. Maluf G, Caldas RJ, Silva Santos PS. Use of leukocyte- and platelet-rich fibrin in the treatment of medication-related osteonecrosis of the jaws. *J Oral Maxillofac Surg.* 2018;76:88–96.
12. Nørholt SE, Hartlev J. Surgical treatment of osteonecrosis of the jaw with the use of platelet-rich fibrin: a prospective study of 15 patients. *Int J Oral Maxillofac Surg.* 2016;45:1256–1260.
13. Hanasono MM, Militsakh ON, Richmon JD, et al. Mandibulectomy and free flap reconstruction for bisphosphonate-related osteonecrosis of the jaws. *JAMA Otolaryngol Head Neck Surg.* 2013;139:1135–1142.
14. Chang EI, Jenkins MP, Patel SA, et al. Long-term operative outcomes of preoperative computed tomography-guided virtual surgical planning for osteocutaneous free flap mandible reconstruction. *Plast Reconstr Surg.* 2016;137:619–623.