

Role of TGF- β 1-mediated epithelial-mesenchymal transition in the pathogenesis of tympanosclerosis

JINGJING QIU^{1*}, YANMEI WANG^{2*}, WENTAO GUO^{1*}, LING XU¹,
YAKUI MOU¹, LIMEI CUI¹, FENGCHAN HAN³ and YAN SUN¹

Departments of ¹Otorhinolaryngology Head and Neck Surgery, and ²Blood Purification, The Affiliated Yantai Yuhuangding Hospital of Qingdao University, Yantai, Shandong 264000; ³Key Laboratory for Genetic Hearing Disorders in Shandong, Binzhou Medical University, Yantai, Shandong 264003, P.R. China

Received May 14, 2020; Accepted September 24, 2020

DOI: 10.3892/etm.2020.9438

Abstract. The present study aimed to explore the role of TGF- β 1-mediated epithelial-mesenchymal transition (EMT) in the pathogenesis of tympanosclerosis. Sprague Dawley rats were injected with inactivated *Streptococcus pneumoniae* suspension to establish a rat model of tympanosclerosis. The rats were sacrificed 8 weeks after the model was established. H&E and von Kossa staining was used to observe the morphological changes of middle ear mucosa. Western blotting was used to detect the expression of TGF- β 1 and EMT-associated proteins in the mucosa samples. Middle ear mucosal epithelial cells of rats were collected to establish a primary culture. The cultured cells were stimulated with TGF- β 1 and the expression of EMT-associated proteins was detected by western blotting and immunofluorescence. In addition, the cells were treated with TGF- β receptor type I/II inhibitor and the expression level of EMT-associated proteins was detected by western blotting. Sclerotic lesions appeared on 72.4% of tympanic membranes, and marked inflammation, inflammatory cell infiltration and fibrosis were found in the middle ear mucosa of rat models of tympanosclerosis. In middle ear mucosa of rats with tympanosclerosis, the expression of mesenchymal cell markers increased and that of epithelial cell markers decreased compared with the control group. TGF- β 1

stimulated the activation of the EMT pathway in middle ear mucosal epithelial cells, resulting in an increased expression of fibronectin and N-cadherin. In addition, a decreased expression level of EMT-associated proteins was observed when TGF- β 1 was inhibited. In conclusion, the present study indicated that TGF- β 1-mediated EMT may play an important role in the pathogenesis of tympanosclerosis.

Introduction

Tympanosclerosis is an irreversible pathological change in the tympanic membrane and mucosa of the middle ear due to prolonged chronic inflammation (1). This condition can damage the auditory ossicles and block hearing conduction. Patients may suffer from hearing loss, otorrhea, tinnitus and other adverse symptoms that affect the quality of their lives (2). The etiology of tympanosclerosis merits further study. Chronic inflammation of the middle ear has been widely acknowledged by otologists as the etiology of tympanosclerosis (3). In chronic suppurative otitis media, the incidence of tympanosclerosis is 35.64% (4). In addition, 35.7% of patients develop tympanosclerosis after being treated for secretory otitis media with myringotomy and ventilation tube insertion (5). High incidence and severe clinical symptoms negatively affect the quality of life of patients. Therefore, the pathogenesis of tympanosclerosis must be explored to strengthen the early intervention and develop new treatment methods.

TGF- β is the main regulator of inflammatory responses. It can control the initiation and regression of inflammation by regulating chemotaxis and activity of inflammatory cells, such as macrophages and granulocytes (6). Previous studies have shown that TGF- β can promote not only matrix deposition and tissue repair after tissue injury but also the development of inflammation, and induce abnormal collagen deposition and fibrosis under inflammatory conditions (7,8). As one of the three subtypes of TGF- β , TGF- β 1 is an important cytokine and one of the essential transmitters that induce inflammation and fibrosis (9). Melhus *et al* (10) found that high TGF- β 1 expression in secretory otitis media in rats can increase fibrinogen in the middle ear mucosa and induce fibroid degeneration in the tympanic membrane. Guo *et al* (11) revealed that the expression of TGF- β 1 was increased in middle ear

Correspondence to: Dr Yan Sun, Department of Otorhinolaryngology Head and Neck Surgery, The Affiliated Yantai Yuhuangding Hospital of Qingdao University, 20 East Yuhuangding Road, Yantai, Shandong 264000, P.R. China
E-mail: entsunyan@126.com

Dr Fengchan Han, Key Laboratory for Genetic Hearing Disorders in Shandong, Binzhou Medical University, 346 Guanhai Road, Yantai, Shandong 264003, P.R. China
E-mail: hanfengchan@gmail.com

*Contributed equally

Key words: tympanosclerosis, epithelial-mesenchymal transition, TGF- β 1, fibronectin, N-cadherin

mucosa by tympanosclerosis model, and its expression was positively correlated with the course of tympanosclerosis. The mechanisms and signaling pathways of TGF- β 1 involved in regulating the occurrence and development of otitis media and tympanosclerosis caused by nonhealing require further investigation.

TGF- β 1 is also an important inducer of EMT (12). EMT refers to the process of epithelial cells transforming into mesenchymal cells during normal physiological development or in a pathological state. EMT is divided into three subtypes, among which type II EMT is involved in inflammation, tissue regeneration, wound healing, and organ fibrosis (13,14). Existing literature recognized that TGF- β 1-mediated EMT plays an important role in the development of chronic inflammation to fibrosis (15). A previous study has confirmed that EMT regulates the progression of mastitis to mammary fibrosis through the TGF- β 1 signal pathway (16). Some scholars also revealed that airway inflammation during asthma could induce increased secretion of TGF- β 1 and promote the occurrence of EMT in the airway, eventually leading to airway remodeling (17). Numerous studies have been performed to investigate the signaling pathways of TGF- β 1 that may regulate EMT. Some scholars reported that TGF- β 1 mediates the snail signaling pathway in EMT and snail is a key target of this pathway (18,19). A previous study on liver fibrosis has shown that using corresponding drugs to inhibit the gene expression levels of TGF- β 1 and snail could reduce the expression of fibronectin in hepatocytes and block the process of EMT (20). TGF- β 1 is a key factor in promoting tympanosclerosis; however, to the best of our knowledge, TGF- β 1-mediated EMT in the pathogenesis of tympanosclerosis has not been previously investigated.

The aim of the present study was to detect the expression levels of EMT-associated proteins in an animal model and a primary cell culture, and to explore the mechanism of TGF- β 1-mediated EMT in tympanosclerosis.

Materials and methods

Materials. A total of 40 male Sprague Dawley rats (weight, 200–220 g; age, 8 weeks) were purchased from Jinan Pengyue Experimental Animal Breeding Co., Ltd. All rats had a quality certificate (license no. 1107261911003742) for experimental animals. Animals were housed at a temperature of $23\pm 2^\circ\text{C}$, a humidity of 50% and a 12/12 h light/dark cycle with free access to rat chow and water. Adaptive feeding for 1 week was necessary before modeling, and the absence of abnormalities of the external auditory meatus and the tympanic membrane of the rats was confirmed. A total of 30 rats were used to establish animal models and 10 were used to harvest cells for the primary cell culture. Animal health and behavior were monitored daily and animal welfare was in compliant with requirements of the Animal Welfare Act (21). This study was approved by the Medical Ethics Committee of the Affiliated Yuhuangding Hospital of Qingdao University, [Yantai, China; approval no. 2018 (135)], and experiments were conducted according to the Guidelines for Animal Experimentation of the Qingdao University.

A standard strain of *Streptococcus pneumoniae* (49619TM; American Type Culture Collection) was provided by the

microbiology laboratory of the Affiliated Yuhuangding Hospital of Qingdao University. Recombinant human TGF- β 1 protein (cat. no. ab50036), and rabbit polyclonal β -actin (cat. no. ab8227), rabbit polyclonal TGF- β 1 (cat. no. ab92486), rabbit polyclonal fibronectin (cat. no. ab2413), mouse monoclonal E-cadherin (cat. no. ab1416), rabbit polyclonal N-cadherin (cat. no. ab18203) and goat polyclonal snail (cat. no. ab53519) antibodies were purchased from Abcam. Rabbit anti-mouse (cat. no. ab6728) and goat anti-rabbit (cat. no. ab205718) HRP-conjugated secondary antibodies were obtained from Abcam, and rabbit anti-goat HRP-conjugated secondary antibody (cat. no. bs20005) was obtained from Absin Biotechnology, Inc. H&E (cat. no. G1120-3) and von Kossa (cat. no. G3282-2) staining kits were obtained from Beijing Solarbio Science & Technology Co., Ltd. The BCA protein assay kit (cat. no. PC0020), RIPA lysis buffer (cat. no. R0020) and SDS-PAGE loading buffer (cat. no. P1040) used for western blotting were also from Beijing Solarbio Science & Technology Co., Ltd. Rabbit polyclonal vimentin antibody (cat. no. AF7013), goat anti-rabbit IgG (H+L) Fluor594-conjugated secondary antibody (cat. no. S0006) and enhanced chemiluminescence (ECL) reagent (cat. no. K002) were from Affinity Biosciences. TGF- β receptor type I/II inhibitor (LY2109761) was from MedChemExpress.

Animal experiments. Before modeling, the standard strain of *S. pneumoniae* was selected to 5% sheep blood agar plate (BioMerieux SA) and cultured in a CO₂ incubator at 35°C for 24 h. The concentration of *S. pneumoniae* was adjusted to 1×10^8 CFU/ml using a type 721 spectrophotometer. Thereafter, an Eppendorf tube containing *S. pneumoniae* was heated using a 65°C metal bath (GT120S; Leopard Scientific Instruments (Beijing) Co., Ltd.) for 30 min to deactivate the bacteria. The heated bacterial suspension was inoculated on blood agar medium. When no bacterial growth was found via culture at 37°C for 24 h, the suspension was kept for modeling use.

Under sterile conditions, all rats were anesthetized intraperitoneally with pentobarbital (30 mg/kg; NAF Apotek, Oslo). Subsequently, a syringe needle was inserted into the anterior inferior quadrant of the tympanic membrane of the right ear using an otomicroscope (Haag-Streit; Moller-Wedel Optical GmbH), and 50 μl of the inactivated *S. pneumoniae* suspension was injected. The left ear was not treated. Otomicroscope observation was performed every three days within two weeks after injection of *S. pneumoniae*, and every seven days after two weeks. The duration of the animal experiment was 8 weeks. A total of 8 weeks after modeling, the tympanic membrane of all rats was observed under the otomicroscope. Tympanosclerosis is defined as the formation of obvious turbid or white plaques on the tympanic membrane (22).

After otomicroscopic observation, the rats with sclerotic plaques on the tympanic membrane of the right ear were euthanized and the tympanic bullae in the left and right ears were removed. Rats were euthanized when they survived until 8 weeks after modeling or if they reached a humane endpoint. Euthanasia was performed via an overdose of sodium pentobarbital, as per the recommendations established by the American Veterinary Medical Association Panel on Euthanasia (23). Death was verified by cardiorespiratory arrest and disappearance of various reflexes. The middle ear mucosae of the right

and left ears were used as experimental and control groups, respectively. In total, 4/5 of the middle-ear mucosa of all model rats was collected under the otomicroscope and immediately frozen at -80°C for western blot analysis. The remaining 1/5 was fixed overnight in 5% paraformaldehyde solution at room temperature and decalcified with 10% EDTA solution for histological evaluation. After decalcification, the samples were dehydrated with an ascending alcohol series, embedded in paraffin wax, cut into thin sections ($5\text{-}\mu\text{m}$ thick), and sequentially mounted on glass slides. Finally, the sections were stained in accordance with the manufacturer's instructions for H&E staining kit and von Kossa staining kit, respectively.

Cell culture. Primary culture of middle ear epithelial cells was performed, as previously described (24,25). Cells were maintained in RPMI-1640 media supplemented with 5% fetal bovine serum and 1% penicillin/streptomycin. After counting, the cell concentration was adjusted to $5 \times 10^5/\text{ml}$, seeded into a 12-well plate and cultured at 37°C with 5% CO_2 for 48 h. The culture medium was subsequently replaced with or without 20 ng/ml TGF- β 1, a dose based on previous research (26). After 48 h treatment with or without TGF- β 1 at 37°C , the cells were collected for subsequent experiments.

For inhibition of the TGF- β 1 pathway, primary cells were inoculated on the 12-well plate ($5 \times 10^5/\text{ml}$) again. After culture at 37°C with 5% CO_2 for 48 h, cells were treated with 10 $\mu\text{mol}/\text{ml}$ LY2109761 at 37°C for 6 h. Subsequently, the medium with LY2109761 was removed, and the new medium was replaced and treated with TGF- β 1 at 37°C for 48 h, then the cells were collected for subsequent experiments.

Morphological observation and calcium evaluation. The paraffin-embedded sections were heated at 65°C for 1 h and then deparaffinized in xylene and rehydrated in a descending alcohol series. Subsequently, the sections were stained using the aforementioned H&E and von Kossa staining kits. In the process of H&E staining, the sections were stained with hematoxylin for 1 min, soaked with distilled water for 15 min, and then stained with eosin for 1 min. When von Kossa staining was performed, the sections were incubated with von Kossa silver solution, placed under ultraviolet light for 15 min, washed with distilled water for 1 min, then treated with 5% sodium thiosulfate for 2 min, and then re-stained with 0.1% nuclear fast red solution staining for 1 min. The above staining processes were all carried out at room temperature. The sections stained by H&E and von Kossa were dehydrated and transparent, sealed with neutral gum and observed under fluorescence microscopy (BX53; Olympus Soft Imaging Solutions GmbH). The characteristics of tympanosclerosis, including mucosa thickening, fibrosis and calcium deposition, were recorded.

Western blot analysis. RIPA and PMSF were added to the Eppendorf tubes to lyse the mucosa and primary cells. After sufficient grinding and centrifugation (4°C , $14,000 \times g$, 20 min), the protein was extracted, and the concentration was measured using a BCA kit. SDS-PAGE loading buffer (50 μl) was added to 200 μl protein supernatant, and the mix was heated in a metal bath at 100°C for 5 min to obtain the protein samples required for electrophoresis. Equivalent amounts of

protein (25 $\mu\text{g}/\text{lane}$) were separated by SDS-PAGE (8% gel) and then electrotransferred onto nitrocellulose membranes for 90 min at 260 mA. Subsequently, the membranes were blocked with skimmed milk at a concentration of 5% for 1 h at room temperature. Then, the membranes incubated overnight at 4°C with the aforementioned β -actin (1:2,000) TGF- β 1 (1:1,000), fibronectin (1:1,000), E-cadherin (1:1,000), N-cadherin (1:1,000) and snail (1:500 dilution) antibodies. The membranes were washed three times with TBS with 0.1% Tween-20 (TBST; 10 min each) and incubated with the aforementioned HRP-conjugated goat anti-rabbit (1:10,000 dilution), rabbit anti-mouse (1:5,000 dilution) or rabbit anti-goat (1:5,000 dilution) IgG antibodies at room temperature for 1 h. The membranes were washed three times with TBST again and the ECL reagent was used. The membranes were exposed for development using a fluorescence and chemiluminescence imaging system (ChemiScope 6200 Touch; Clinx Science Instruments Co., Ltd.). The grayscale value of each band was measured using ImageJ software (version 1.8.0; National Institutes of Health).

Immunofluorescence. Primary cells were fixed in 4% paraformaldehyde for 20 min at room temperature and then permeabilized with 0.5% TritonX-100 for 20 min. After blocking with 5% BSA for 2 h at room temperature, the cells were incubated with the aforementioned anti-vimentin antibody (1:100) at 4°C overnight. The next day, the cells were incubated with the aforementioned goat anti-rabbit IgG (H+L) Fluor594-conjugated secondary antibody (1:200) at 37°C for 1 h. The cells were washed with PBS 3 times and then stained with DAPI for 5 min at room temperature. The cells were observed using fluorescence microscopy.

Statistical analysis. Statistical analyses were conducted using SPSS version 22.0 (IBM Corp.) and GraphPad Prism version 7.0 (GraphPad Software, Inc.). For western blotting results, paired samples were compared using a paired samples t-test and multiple comparisons were performed using one-way ANOVA followed by the Least Significant Difference test. Relative vimentin intensity data were compared using an unpaired samples t-test. $P < 0.05$ was considered to indicate a statistically significant difference.

Results

Otomicroscopic observations. Among the 30 rats, one died of digestive system infection 6 days after modeling, while the remaining animals survived until 8 weeks after modeling. Three days after the establishment of the model, yellowish serous exudation could be seen in the middle ear cavity of the rats. Two weeks later, the inflammatory exudation was absorbed, and the tympanic membrane perforation caused by puncture healed. The otomicroscopic results showed that a tympanosclerosis model was successfully established in 21 out of 29 right ears at 8 weeks, and no obvious abnormalities in the tympanic membrane were found among the 29 left ears and 8 right ears (Fig. 1).

Histopathological observations. The H&E staining results are shown in Fig. 2. The mucosal structure of the control group

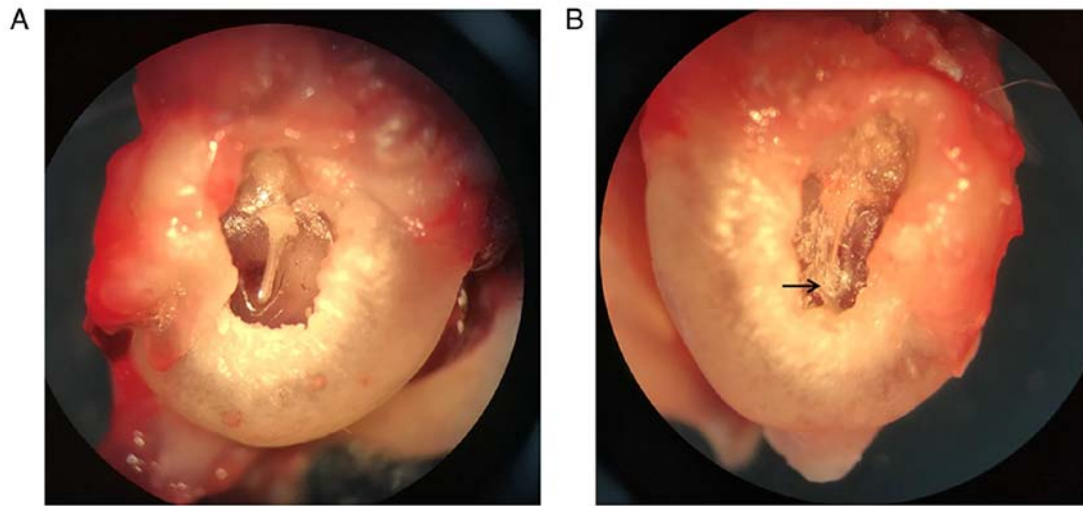


Figure 1. Otomicroscopic observations at week 8. (A) Representative left ear used as the control. The tympanic membrane was intact and transparent without calcification. (B) Representative right ear used as the experimental model. The tympanic membrane showed obvious turbidity and sclerotic plaques (arrow) at the tympanic ring. Original magnification, x20.

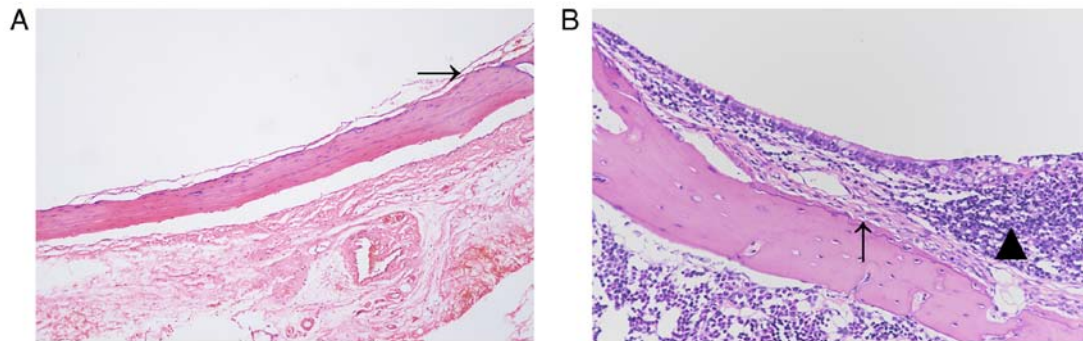


Figure 2. H&E staining observations. (A) Representative control group image. Morphology and structure of mucosa (arrow) were normal and without inflammation. (B) Representative experimental group image. Mucosa was markedly thickened with inflammatory cell infiltration (triangle) and fibrous tissue hyperplasia (arrow). Original magnification, x200.

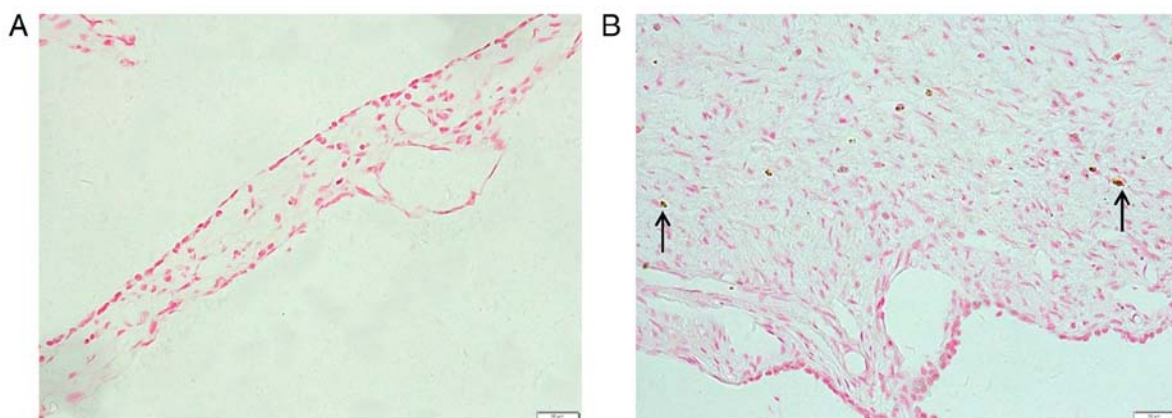


Figure 3. Von Kossa staining observations. (A) Representative control group image. No calcium deposition was found. (B) Representative experimental group image. Mucosa was markedly thickened with scattered calcium deposits (arrows). Original magnification, x400.

was intact, and no inflammation or fibroplasia was observed (Fig. 2A). The mucosa in the experimental group was markedly thicker than that in the control group. In addition, inflammatory cell infiltration was observed, and the fibrous tissue was hyperplastic (Fig. 2B).

The von Kossa staining results are shown in Fig. 3. The mucosal structure of the control group was normal with no calcium deposition (Fig. 3A). The mucosa of the experimental group was markedly thickened and scattered calcium deposits were found in the tissue (Fig. 3B).

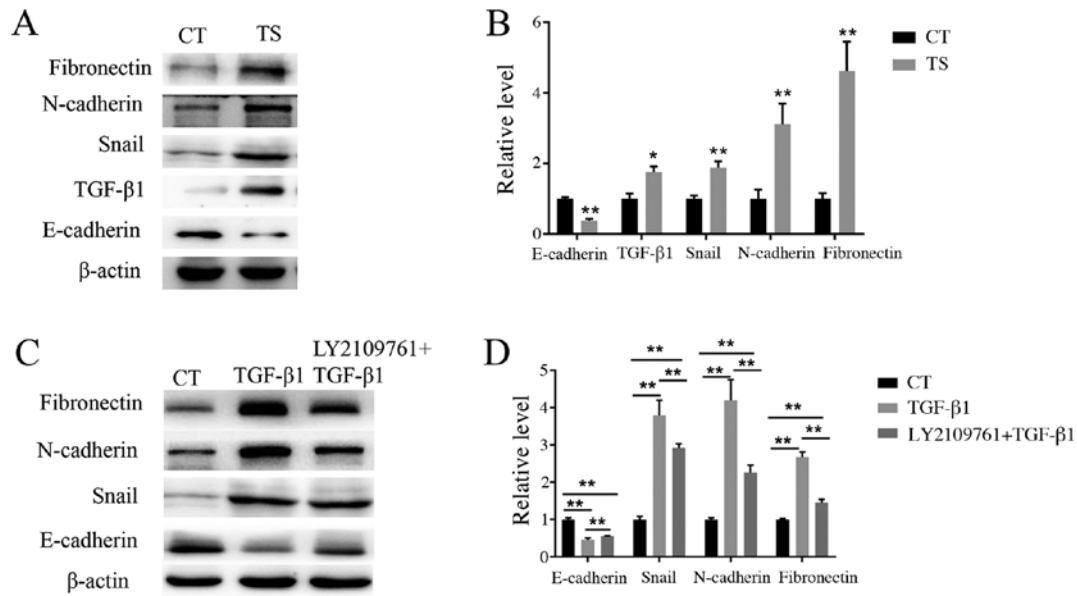


Figure 4. Detection of protein expression by western blotting. (A) Western blotting results for E-cadherin, TGF- β 1, snail, N-cadherin and fibronectin in the TS and CT groups. (B) Semi-quantitative analysis of the expression levels of E-cadherin, TGF- β 1, snail, N-cadherin and fibronectin in the TS and CT groups. * $P < 0.05$ and ** $P < 0.01$ vs. CT. (C) Western blotting results for EMT-associated proteins after treatment with TGF- β 1 or co-treatment with TGF- β 1 and LY2109761. (D) Semi-quantitative analysis of the expression levels of EMT-associated proteins after TGF- β 1 stimulation or co-treatment with TGF- β 1 and LY2109761. ** $P < 0.01$ as indicated. CT, control; TS, tympanosclerosis.

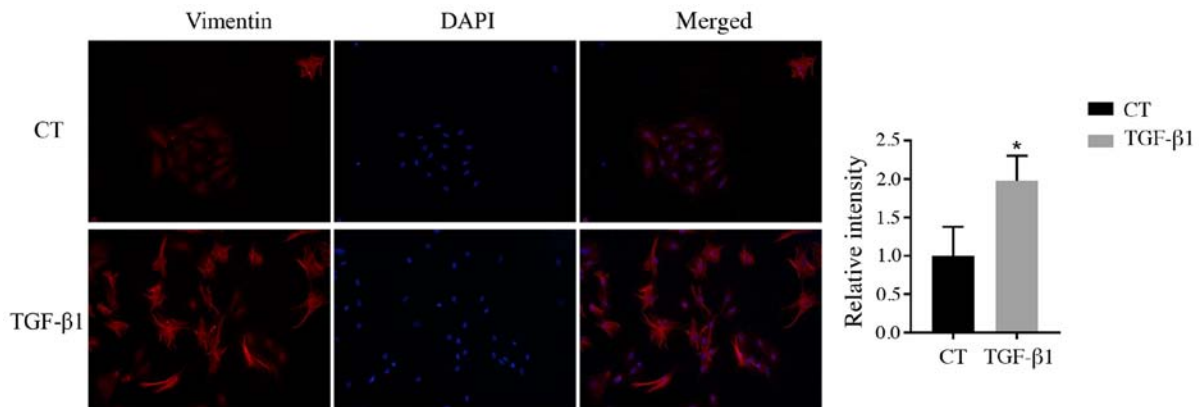


Figure 5. Immunofluorescence staining for vimentin. Nuclei were stained blue using DAPI. The expression levels of vimentin were upregulated following TGF- β 1 stimulation. * $P < 0.05$ vs. CT. Original magnification, x200.

Western blot analysis. To confirm whether EMT was associated with tympanosclerosis, western blotting was used to detect the expression levels of E-cadherin, TGF- β 1, snail, N-cadherin and fibronectin in tympanosclerotic middle ear and normal middle ear mucosa. As shown in Fig. 4A and B, the expression levels of TGF- β 1, snail, N-cadherin and fibronectin in the experimental group were increased, whereas E-cadherin expression level decreased, compared with that in the control group. In order to further determine the role of the EMT-associated pathway in the pathogenesis of tympanosclerosis, middle ear mucosal cells were treated with TGF- β 1. Western blotting results showed that when stimulated with TGF- β 1, the expression of E-cadherin decreased, while the expression of snail, N-cadherin and fibronectin increased (Fig. 4C and D). These results suggested that TGF- β 1 can activate the EMT, of middle ear mucosa cells, resulting in a decrease in the

expression of epithelial markers and an increase in the expression of mesenchymal markers. A total of 6 h before TGF- β 1 stimulation, LY2109761 was used to treat cells. It was found that compared with the TGF- β 1 treatment group, the expression of E-cadherin increased but the expression levels of snail, N-cadherin and fibronectin decreased in the group co-treated with LY2109761 (Fig. 4C and D), and the differences were statistically significant ($P < 0.01$), which indicated that LY210976 could inhibit the occurrence of EMT in middle ear mucosa.

Immunofluorescence analysis. Vimentin is a hallmark of EMT (27). Vimentin was visualized in middle ear epithelial cells at 48 h after TGF- β 1 treatment using immunofluorescence. The results showed that the relative intensities of vimentin in the group treated with TGF- β 1 were significantly higher than those in the control group (Fig. 5).

Discussion

A tympanosclerosis model in rats can be established in a number of ways, including tympanotomy and *S. pneumoniae* injection. The latter was chosen for the present study because the course of tympanosclerosis induced by *S. pneumoniae* injection is closer to that of humans than that in tympanotomy (28). Tympanosclerosis is one of the main reactions of the tympanic membrane and middle-ear mucosa to long-term aseptic secretory otitis media, and the course of tympanosclerosis is progressive (29). The main pathogenic substance of inactivated *S. pneumoniae* is endotoxin, which can cause connective tissue and goblet cell proliferation in the middle-ear mucosa, and induce the accumulation of glandular secretions leading to secretory otitis media. Three days after injection of inactivated *S. pneumoniae*, yellowish serous fluid was found in the middle ear cavity of most rats, but there was generally no purulent fluid. Long-term exudation of inflammatory substances stimulates tympanosclerosis in the middle ear mucosa; meanwhile, perforation of the tympanic membrane during injection promotes the formation of a high-oxygen environment in the tympanum, which in turn induces accumulation of oxygen free radicals and promotes tympanosclerosis (30). Perforation of the tympanic membrane caused by puncture usually heals within 2 weeks. In the present study, the middle ear mucosa was obtained 8 weeks after modeling, as most studies revealed that the typical histological changes in tympanosclerosis could be observed 8 weeks after modeling (1,11,31).

The modeling method used in the present study was simple, safe and reliable. One rat died on the sixth day after *S. pneumoniae* injection due to digestive tract infection, this was considered to be due to the poor resistance of the individual, while the remaining 29 survived for 8 weeks. The otomicroscopic observations showed that the tympanic membrane of the left ear was transparent in all rats, and 21 rats (72.4% of the total) had turbid or obvious sclerotic plaques in the tympanic membrane of the right ears. It is possible that the inflammation in the middle ear of some rats was self-cured before the development of tympanosclerosis due to anti-infection ability. Thus, the success rate of modeling did not reach 100%. In future studies, changing some modeling conditions, such as increasing the frequency of *S. pneumoniae* injections and combining two modeling methods, could be explored to increase the rate of success for the model and obtain a sufficient number of experimental specimens. In the present study, H&E staining showed that the morphology of the middle ear mucosa in the control group was normal, whereas that in the experimental group was thickened. In addition, extensive inflammatory cell infiltration was observed in certain fibroblast-rich areas. This finding was consistent with the histological changes in tympanosclerosis shown in a previous study (1). Therefore, the results of the present study indicated that intratympanic injection of inactivated *S. pneumoniae* is an effective way to establish a model of tympanosclerosis.

The progression of middle-ear inflammation to tympanosclerosis mainly occurs in five stages: Inflammatory exudation, granulation, fibrosis, hyalinization and calcification, among which fibrosis is the last reversible stage (31). Thus, exploring the progression from middle ear inflammation to fibrosis is important in preventing and treating tympanosclerosis. To the

best of our knowledge, the present study is the first to suggest that TGF- β 1-mediated EMT is involved in the pathogenesis of tympanosclerosis. The current findings provide a new theoretical basis for the prevention and treatment of tympanosclerosis caused by otitis media.

TGF- β 1 is a multifunctional cytokine involved in the regulation of various biological processes, among which pro-inflammatory and pro-fibrotic effects have been widely studied. Numerous hypotheses have been proposed on the specific mechanism of TGF- β 1 in promoting the progression of chronic inflammation into fibrosis (32,33). Most studies suggested that TGF- β 1 is associated with EMT, which is considered as an important process in the progression of inflammation to degenerative fibrous disease (34,35). TGF- β 1 is a core factor that regulates the progression of fibrosis (36). TGF- β 1 promotes the synthesis of extracellular matrix protein fibronectin by regulating the transformation of epithelial cells associated with type II EMT into fibroblasts, thereby resulting in the contraction of extracellular matrix (37). A previous study has confirmed that high expression of TGF- β 1 is observed in secretory otitis media (38). The present study used western blotting to detect the expression levels of TGF- β 1 in the tympanosclerotic and normal middle ear mucosae of rats. TGF- β 1 expression was significantly increased in the experimental group. Therefore, secretory otitis media induced by *S. pneumoniae* could stimulate the secretion of TGF- β 1, which might subsequently promote fibrosis in the transition from otitis media to tympanosclerosis.

Fibronectin and N-cadherin proteins are mesenchymal markers of EMT (39). Fibronectin is also the most abundant extracellular matrix protein in various tissues. Its overexpression promotes the accumulation of extracellular matrix and eventually leads to organ fibrosis by changing the cell structure and behavioral characteristics. such as promoting the recruitment and stimulation of inflammatory cells (40,41). Kriegel *et al* (42) reported that the accumulation of extracellular matrix proteins and the occurrence of interstitial fibrosis are the main results of TGF- β 1-induced EMT in renal epithelial cells. N-cadherin is not only a typical EMT marker but also an important intercellular adhesion molecule. A previous study has shown that the process of fibronectin promoting the deposition of extracellular matrix is associated with the increase in cytoskeleton tension resulting from N-cadherin adhesion (43). In the present study, western blot analysis confirmed that the expression levels of fibronectin and N-cadherin, two main EMT markers, were significantly increased in the experimental group compared with the control. Histological analysis showed obvious fibrous adhesion and fibrous hyperplasia in the middle-ear mucosa of the experimental group, which may be associated with the deposition of the extracellular matrix caused by the overexpression of fibronectin and N-cadherin. The aforementioned results further demonstrated the role of TGF- β 1-induced EMT in tympanosclerosis, suggesting that may promote the development of otitis media and participate in middle-ear mucosal fibrosis.

Snail is a zinc finger transcription factor located in the nucleus that promotes EMT by inhibiting the expression of E-cadherin, a typical epithelial marker (44). TGF- β 1 is the upstream pathway that induces snail activation. Park *et al* (45) reported that EMT induced by the TGF- β 1/snail signal

pathway was involved in the formation of pulmonary fibrosis. The results of the present study suggested that the expression level of snail in the experimental group was significantly higher than that in the normal control group. At the same time, the expression level of E-cadherin in the tympanosclerosis mucosa was significantly decreased compared with control. Thus, the results suggest that TGF- β 1 may regulate EMT in tympanosclerosis through the snail signal pathway.

TGF- β 1 is an extracellular signaling molecule that transmits the extracellular signal to the nucleus by binding to its receptor on the cell membrane (46). In the case of EMT, TGF- β 1 activates snail, which inhibits the expression of epithelial genes and promotes the transcription of mesenchymal genes (47). The present study showed that the expression levels of snail, N-cadherin and fibronectin were upregulated and E-cadherin was downregulated following TGF- β 1 stimulation in middle ear epithelial cells. In addition, when compared with TGF- β 1 treatment group, the current study also found that the expression levels of mesenchymal markers such as snail, N-cadherin and fibronectin decreased, while the expression level of epithelial marker E-cadherin increased in epithelial cells treated with LY2109761. Notably, immunofluorescence results revealed that the expression of vimentin, a hallmark of EMT, was significantly increased after middle ear epithelial cells were stimulated by TGF- β 1. The current results provide evidence for the involvement of EMT in tympanosclerosis formation.

The present study represents an advancement in the research on the pathogenesis of tympanosclerosis; however, it has certain limitations. Although the pathogenesis of tympanosclerosis regulated by TGF- β 1-mediated EMT was studied in animal models, the mechanism in humans remains unclear. In the future, human tympanosclerosis specimens will be collected to further explore the pathogenic factors associated with tympanosclerosis.

In conclusion, high expression of TGF- β 1 is a key factor in promoting the formation of tympanosclerosis via the EMT process. The present study provides strong evidence for the involvement of TGF- β 1-induced EMT in the formation of tympanosclerosis and provides a new direction for the treatment and prevention of tympanosclerosis. The pathogenesis of tympanosclerosis is complex and, to the best of our knowledge, has not been fully elucidated. The majority of patients report to the clinic for consultation only when they have reached the irreversible stage of this condition. Thus, exploring the pathogenesis of tympanosclerosis is necessary for prevention and further treatment.

Acknowledgements

Not applicable.

Funding

The present study was supported by the Science and Technology Plan Project of Yantai (grant no. 2018SFGY107).

Availability of data and materials

The datasets used and/or analyzed during the current study are available from the corresponding author on reasonable request.

Authors' contributions

WG, LC, YM, YS and FH were responsible for the conception of this study and designed the experiments. JQ, YW and LX performed the experiments and analyzed the data. YS and FH contributed to reviewing and proofreading the manuscript. All authors contributed to the interpretation of data and writing of the manuscript. All authors read and approved the final manuscript.

Ethics approval and consent to participate

The present study was approved by the Medical Ethics Committee of the Affiliated Yuhuangding Hospital of Qingdao University (Yantai, China) and experiments were conducted according to the Guidelines for Animal Experimentation of the Qingdao University (Qingdao, China).

Patient consent for publication

Not applicable.

Competing interests

The authors declare that they have no competing interests.

References

- Zhang Y, Wang S, Zheng Y and Liu A: Possible role of dickkopf-1 protein in the pathogenesis of tympanosclerosis in a rat model. *J Laryngol Otol* 131: 860-865, 2017.
- Qiu JJ, Wang JX and Sun Y: Advances in research on etiology of tympanosclerosis and related factors. *Chin J Otol* 18: 792-796, 2020.
- Asiri S, Hasham A, Al Anazy F, Zakzouk S and Banjar A: Tympanosclerosis: Review of literature and incidence among patients with middle-ear infection. *J Laryngol Otol* 113: 1076-1080, 1999.
- Wu Y, Yin S, Zhu H and Zhang S: Tympanosclerosis incidence among patients with chronic suppurative otitis media. *Lin Chuang Er Bi Yan Hou Ke Za Zhi* 20: 1016-1017, 2006 (In Chinese).
- Branco C, Monteiro D and Paco J: Predictive factors for the appearance of myringosclerosis after myringotomy with ventilation tube placement: Randomized study. *Eur Arch Otorhinolaryngol* 274: 79-84, 2017.
- Wrzesinski SH, Wan YY and Flavell RA: Transforming growth factor-beta and the immune response: Implications for anticancer therapy. *Clin Cancer Res* 13: 5262-5270, 2007.
- Fabregat I, Moreno-Caceres J, Sanchez A, Dooley S, Dewidar B, Giannelli G and Ten Dijke P; IT-LIVER Consortium: TGF- β signalling and liver disease. *FEBS J* 283: 2219-2232, 2016.
- Berksoy Hayta S, Durmus K, Altuntas EE, Yildiz E, Hisarciklio M and Akyol M: The reduction in inflammation and impairment in wound healing by using strontium chloride hexahydrate. *Cutan Ocul Toxicol* 37: 24-28, 2018.
- Zhang X, Zhang MC and Wang CT: Loss of LRRCC25 accelerates pathological cardiac hypertrophy through promoting fibrosis and inflammation regulated by TGF- β 1. *Biochem Biophys Res Commun* 506: 137-144, 2018.
- Melhus A and Ryan AF: Expression of cytokine genes during pneumococcal and nontypeable haemophilus influenzae acute otitis media in the rat. *Infect Immun* 68: 4024-4031, 2000.
- Guo W, Bai X, Han Y, Xu L, Liu W, Zhang G, Li J, Fan Z and Wang H: Expressions of TGF- β 1 and MMP-9 in a guinea pig model of tympanosclerosis: Possible role in the pathogenesis of this disorder. *Laryngoscope* 122: 2037-2042, 2012.

12. Wang X, Gao JL, Zhao MM, Zhu HX, Tian YX, Li R, Jiang XH, Yu L, Tian JR and Cui JZ: Therapeutic effects of conditioned medium from bone marrow-derived mesenchymal stem cells on epithelial-mesenchymal transition in A549 cells. *Int J Mol Med* 41: 659-668, 2018.
13. Stone RC, Pastar I, Ojeh N, Chen V, Liu S, Garzon KI and Tomic-Canic M: Epithelial-mesenchymal transition in tissue repair and fibrosis. *Cell Tissue Res* 365: 495-506, 2016.
14. Guarino M, Tosoni A and Nebuloni M: Direct contribution of epithelium to organ fibrosis: Epithelial-mesenchymal transition. *Hum Pathol* 40: 1365-1376, 2009.
15. Sisto M, Lorusso L, Ingravallo G, Tamma R, Ribatti D and Lisi S: The TGF- β 1 signaling pathway as an attractive target in the fibrosis pathogenesis of sjogren's syndrome. *Mediators Inflamm* 2018: 1965935, 2018.
16. Chen Q, Yang W, Wang X, Li X, Qi S, Zhang Y and Gao MQ: TGF- β 1 induces EMT in bovine mammary epithelial cells through the TGF β 1/smud signaling pathway. *Cell Physiol Biochem* 43: 82-93, 2017.
17. Zhu X, Li Q, Hu G, Wang J, Hu Q, Liu Z, Wu G and Zhong Y: BMS345541 inhibits airway inflammation and epithelialmesenchymal transition in airway remodeling of asthmatic mice. *Int J Mol Med* 42: 1998-2008, 2018.
18. Yang HW, Lee SA, Shin JM, Park IH and Lee HM: Glucocorticoids ameliorate TGF- β 1-mediated epithelial-to-mesenchymal transition of airway epithelium through MAPK and Snail/Slug signaling pathways. *Sci Rep* 7: 3486, 2017.
19. Peinado H, Quintanilla M and Cano A: Transforming growth factor beta-1 induces snail transcription factor in epithelial cell lines: Mechanisms for epithelial mesenchymal transitions. *J Biol Chem* 278: 21113-21123, 2003.
20. Wu T, Liu T, Xing L and Ji G: Baicalin and puerarin reverse epithelial-mesenchymal transition via the TGF-beta1/Smad3 pathway *in vitro*. *Exp Ther Med* 16: 1968-1974, 2018.
21. U.S. Department of Agriculture 2001. Code of Federal Regulations, Animal Welfare Act and Regulation chapter 1, subchapter A: Animals and animal products. U.S. Department of Agriculture, Beltsville, MD.
22. Emir H, Kaptan ZK, Samim E, Sungu N, Ceylan K and Ustun H: The preventive effect of ginkgo biloba extract in myringosclerosis: Study in rats. *Otolaryngol Head Neck Surg* 140: 171-176, 2009.
23. Anonymous AVMA Guidelines for the Euthanasia of Animals. 2013 edition. American Veterinary Medical Association, Schaumburg, IL, 2013.
24. Chen L, Huang YL, Wang J and You JM: Effect of platelet activating factor on mucous glycoprotein secretion in culture middle ear epithelium cells. *Guangdong Med J* 698-700, 2003.
25. Nakamura A, DeMaria TF, Lim DJ and van Blitterswijk CA: Primary culture of chinchilla middle ear epithelium. *Ann Otol Rhinol Laryngol* 100: 774-782, 1991.
26. Han F, Shu J, Wang S, Tang CE and Luo F: Metformin inhibits the expression of biomarkers of fibrosis of EPCs *in vitro*. *Stem Cells Int* 2019: 9019648, 2019.
27. Li J, Peng W, Yang P, Chen R, Gu Q, Qian W, Ji D, Wang Q, Zhang Z, Tang J and Sun Y: MicroRNA-1224-5p inhibits metastasis and epithelial-mesenchymal transition in colorectal cancer by targeting SP1-mediated NF- κ B signaling pathways. *Front Oncol* 10: 294, 2020.
28. Zhang YF, Zheng YX, Wang SJ, Peng LY, He C and Liu AG: Comparison of two methods for the modeling of tympanosclerosis in rat. *J Audiol Speech Pathol* 25: 284-287, 2017.
29. Russell JD and Giles JJ: Tympanosclerosis in the rat tympanic membrane: An experimental study. *Laryngoscope* 112: 1663-1666, 2002.
30. Koc S, Kiyici H, Tokar A, Soyaliç H, Aslan H, Kesici H and Karaca ZI: The effect of melatonin and vitamin C treatment on the experimentally induced tympanosclerosis: Study in rats. *Braz J Otorhinolaryngol* 83: 541-545, 2017.
31. Santos PF, Leal MC, Peixoto C, Caldas Neto S and Rosas ST: Otomicroscopic and histologic findings of induced myringosclerosis in rats: A critical study of an experimental model. *Braz J Otorhinolaryngol* 71: 668-674, 2005.
32. Mahmoud AM, Hozayen WG, Hasan IH, Shaban E and Bin-Jumah M: Umbelliferone ameliorates CCl₄-induced liver fibrosis in rats by upregulating PPAR γ and attenuating oxidative stress, inflammation, and TGF- β 1/Smad3 signaling. *Inflammation* 42: 1103-1116, 2019.
33. Kania G, Blyszczuk P and Eriksson U: Mechanisms of cardiac fibrosis in inflammatory heart disease. *Trends Cardiovasc Med* 19: 247-252, 2009.
34. Lopez-Novoa JM and Nieto MA: Inflammation and EMT: An alliance towards organ fibrosis and cancer progression. *EMBO Mol Med* 1: 303-314, 2009.
35. Sato M, Muragaki Y, Saika S, Roberts AB and Ooshima A: Targeted disruption of TGF-beta1/Smad3 signaling protects against renal tubulointerstitial fibrosis induced by unilateral ureteral obstruction. *J Clin Invest* 112: 1486-1494, 2003.
36. Loboda A, Sobczak M, Jozkowicz A and Dulak J: TGF- β 1/Smads and miR-21 in renal fibrosis and inflammation. *Mediators Inflamm* 2016: 8319283, 2016.
37. Yang YC, Zhang N, Van Crombruggen K, Hu GH, Hong SL and Bachert C: Transforming growth factor-beta1 in inflammatory airway disease: A key for understanding inflammation and remodeling. *Allergy* 67: 1193-1202, 2012.
38. Cooter MS, Eisma RJ, Burleson JA, Leonard G, Lafreniere D and Kreutzer DL: Transforming growth factor-beta expression in otitis media with effusion. *Laryngoscope* 108: 1066-1070, 1998.
39. Rout-Pitt N, Farrow N, Parsons D and Donnelley M: Epithelial mesenchymal transition (EMT): A universal process in lung diseases with implications for cystic fibrosis pathophysiology. *Respir Res* 19: 136, 2018.
40. Altrock E, Sens C, Wuerfel C, Vasel M, Kawelke N, Dooley S, Sottile J and Nakchbandi IA: Inhibition of fibronectin deposition improves experimental liver fibrosis. *J Hepatol* 62: 625-633, 2015.
41. Iredale JP: Models of liver fibrosis: Exploring the dynamic nature of inflammation and repair in a solid organ. *J Clin Invest* 117: 539-548, 2007.
42. Kriegel AJ, Fang Y, Liu Y, Tian Z, Mladinov D, Matus IR, Ding X, Greene AS and Liang M: MicroRNA-target pairs in human renal epithelial cells treated with transforming growth factor beta 1: A novel role of miR-382. *Nucleic Acids Res* 38: 8338-8347, 2010.
43. Dzamba BJ, Jakab KR, Marsden M, Schwartz MA and DeSimone DW: Cadherin adhesion, tissue tension, and noncanonical Wnt signaling regulate fibronectin matrix organization. *Dev Cell* 16: 421-432, 2009.
44. Chaffer CL, San Juan BP, Lim E and Weinberg RA: EMT, cell plasticity and metastasis. *Cancer Metastasis Rev* 35: 645-654, 2016.
45. Park YJ, Bang IJ, Jeong MH, Kim HR, Lee DE, Kwak JH and Chung KH: Effects of β -sitosterol from corn silk on TGF- β 1-induced epithelial-mesenchymal transition in lung alveolar epithelial cells. *J Agric Food Chem* 67: 9789-9795, 2019.
46. Lee HY, Kim IK, Yoon HK, Kwon SS, Rhee CK and Lee SY: Inhibitory effects of resveratrol on airway remodeling by transforming growth factor- β /smad signaling pathway in chronic asthma model. *Allergy Asthma Immunol Res* 9: 25-34, 2017.
47. Kee JY, Han YH, Mun JG, Park SH, Jeon HD and Hong SH: Effect of Korean red ginseng extract on colorectal lung metastasis through inhibiting the epithelial-mesenchymal transition via transforming growth factor- β 1/Smad-signaling-mediated Snail/E-cadherin expression. *J Ginseng Res* 43: 68-76, 2019.



This work is licensed under a Creative Commons Attribution-NonCommercial-NoDerivatives 4.0 International (CC BY-NC-ND 4.0) License.