

Liver Cancer–Specific Serine Protease Inhibitor Kazal Is a Potentially Novel Biomarker for the Early Detection of Hepatocellular Carcinoma

Felix Lu, BS¹, Pir Ahmad Shah, MD², Abhishek Rao, MS¹, Cynthia Gifford-Hollingsworth, MD³, Anne Chen, MS¹, Gary Trey, MD², Mina Soryal, MS¹, Arslan Talat, MD², Aysha Aslam, MD², Bilal Nasir, MD², Saad Choudhry, MD², Rizwan Ishtiaq, MD², Hanna Sanoff, MD⁴, Lanla F. Conteh, MD⁵, Anne Noonan, MD⁵, Ke-Qin Hu, MD⁶, Carl Schmidt, MD⁷, Min Fu, PhD⁸, Jesse Civan, MD⁹, Gary Xiao, MD³, Daryl T.-Y. Lau, MD² and Xuanyong Lu, PhD¹

INTRODUCTION: Liver cancer–secreted serine protease inhibitor Kazal (LC-SPIK) is a protein that is specifically elevated in cases of hepatocellular carcinoma (HCC). We assessed the performance of LC-SPIK in detecting HCC, including its early stages, in patients with cirrhosis, hepatitis B virus (HBV), and hepatitis C virus (HCV).

METHODS: We enrolled 488 patients, including 164 HCC patients (81 early HCC) and 324 controls in a blinded, prospective, case–control study. Serum LC-SPIK levels were determined by an enzyme-linked immunosorbent assay-based assay. The performance of serum LC-SPIK and α -fetoprotein (AFP), including area under the curve (AUC), sensitivity, and specificity, are compared. The performance of LC-SPIK was evaluated in an independent validation cohort with 102 patients.

RESULTS: In distinguishing all HCC patients from those with cirrhosis and chronic HBV/HCV, LC-SPIK had an AUC of 0.87, with 80% sensitivity and 90% specificity using a cutoff of 21.5 ng/mL. This is significantly higher than AFP, which had an AUC of 0.70 and 52% sensitivity and 86% specificity using a standard cutoff value of 20.0 ng/mL. For early-stage HCC (Barcelona Clinic Liver Cancer stage 0 and A), LC-SPIK had an AUC of 0.85, with 72% sensitivity and 90% specificity, compared with AFP, which had an AUC of 0.61, with 42% sensitivity and 86% specificity. In addition, LC-SPIK accurately detected the presence of HCC in more than 70% of HCC patients with false-negative AFP results.

DISCUSSION: The study provided strong evidence that LC-SPIK detects HCC, including early-stage HCC, with high sensitivity and specificity, and might be useful for surveillance in cirrhotic and chronic HBV/HCV patients, who are at an elevated risk of developing HCC.

SUPPLEMENTARY MATERIAL accompanies this paper at <http://links.lww.com/CTG/A434>

Clinical and Translational Gastroenterology 2020;11:e00271. <https://doi.org/10.14309/ctg.0000000000000271>

INTRODUCTION

Primary hepatocellular carcinoma (HCC) is the most common form of liver cancer, with an estimated 854,000 cases in 2015, and is associated with high mortality (1–5). It is often undiagnosed until its later stages where curative treatment options are more limited than those in earlier stages, and 5-year survival rate drops to less than 15%. By contrast, the survival rate is more than 50%

with detection of HCC at earlier stages (1,2,6,7). The poor prognosis of HCC can be overcome with sensitive and accurate diagnostic assays, which can detect the cancer in its earliest and most treatable stages.

Existing tools for HCC surveillance include liver ultrasound and α -fetoprotein (AFP). Ultrasound is the primary surveillance tool, whereas AFP is only optionally recommended per American

¹ImCare Biotech LLC, Doylestown, Pennsylvania, USA; ²Liver Center, Department of Medicine, Beth Israel Deaconess Medical Center, Harvard Medical School, Boston, Massachusetts, USA; ³Department of Surgery, College of Medicine, Drexel University, Philadelphia, Pennsylvania, USA; ⁴University of North Carolina, Chapel Hill, North Carolina, USA; ⁵James Cancer Hospital and Solove Research Institute, Ohio State University, Columbus, Ohio, USA; ⁶University of California Irvine, School of Medicine, Orange, California, USA; ⁷West Virginia University Medicine, Morgantown, West Virginia; ⁸Janssen Research & Development, Spring House, Pennsylvania, USA; ⁹Liver Tumor Center, Thomas Jefferson University, Philadelphia, Pennsylvania, USA. **Correspondence:** Xuanyong Lu, PhD. E-mail: xl@imcarebiotech.com.

Received July 28, 2020; accepted October 12, 2020; published online November 23, 2020

© 2020 The Author(s). Published by Wolters Kluwer Health, Inc. on behalf of The American College of Gastroenterology

Association for the Study of Liver Diseases guidelines and the European Association for the Study of the Liver makes no recommendation for AFP due to its poor performance (4,8). Although ultrasound is noninvasive, it is operator and equipment dependent and not sensitive enough to detect HCC in its critical early stages, with an estimated sensitivity below 50% (6,9). For tumor sizes less than 2 cm, the sensitivity of ultrasound is only 21% (9,10). In addition, ultrasound is suboptimal in certain subpopulations such as obese patients with high body mass index and those with a coarse liver echotexture (4,8,11). AFP, which is still the most commonly tested biomarker for HCC, suffers from poor performance, with an estimated 41%–65% sensitivity and 80%–90% specificity, using a cutoff value of 20.0 ng/mL (12,13). AFP is worse in detecting early-stage HCC, with sensitivity rate less than 40% (12,14). In addition, nearly 40% of patients with HCC have undetectable AFP levels in their sera (13,15–17), and patients with chronic liver diseases might have falsely elevated AFP levels during active inflammation (18). These factors highlight the limited application of AFP in HCC surveillance programs and weaknesses with ultrasound. Other potential biomarkers, such as AFP-L3 and des- γ (4) prothrombin, are only approved for risk stratification, not surveillance, and suffer from low sensitivities in early-stage HCC (4). Biopsies or other radiological methods such as CT scans and MRIs are expensive and burdensome screening modalities and not appropriate for regular surveillance. An accurate and cost-effective solution for HCC surveillance remains a significant unmet need.

To address this, we investigated the performance of a protein called liver cancer–secreted serine protease inhibitor Kazal (LC-SPIK). LC-SPIK is a liver cancer–specific isoform of serine protease inhibitor Kazal (SPIK), which also called pancreas secretory trypsin inhibitor and tumor-associated trypsin inhibitor (19,20). Normally, SPIK has no or limited activity in liver tissues or in any tissues besides the pancreas. However, recent studies have reported that the expression of SPIK is elevated in HCC (21–23). The use of SPIK as a cancer biomarker before has been impeded by the fact that serum SPIK levels are also elevated in other conditions such as acute pancreatitis (24–26). We have demonstrated that the SPIK protein secreted by liver cancer cells is unique as it retains an additional N-terminal fragment during secretion (27). We call this HCC-specific SPIK isoform “liver cancer SPIK” or LC-SPIK. To determine whether this isoform is cancer specific and differentiable from normal or pancreatic SPIK (pan-SPIK), we developed a monoclonal antibody immobilized with a monoclonal anti-LC-SPIK antibody (IM-MCA), which solely recognizes LC-SPIK, and then an enzyme-linked immunosorbent assay (ELISA)-based diagnostic kit. Using this kit, we evaluated LC-SPIK performance in distinguishing HCC from cirrhosis and chronic hepatitis B virus (HBV)/hepatitis C virus (HCV) in a prospective, blinded clinical study and the potential as a novel HCC biomarker.

MATERIALS AND METHODS

Determining serum levels of LC-SPIK and AFP

Serum levels of LC-SPIK were quantified using the ELISA test kit we developed and validated, following a standardized protocol described in the kit’s instructions for use. In brief, the 96-well plate was IM-MCA; 10 μ L of each specimen was diluted with dilution buffer to 100 μ L and incubated with the plate at 37° C for 1 hour. To ensure accuracy of the test results, each sample was tested in triplicate. A standard calibrator set consisting of six 100- μ L samples of HPLC-purified LC-SPIK at various concentrations

(100, 50, 20, 4, 1, and 0 ng/mL) and positive and negative controls were incubated with the plate. After washing, 100 μ L of conjugate (polyclonal anti-SPIK antibody labeled with horse peroxidase) was added and incubated at 37° C for 45 minutes. The color was developed after incubation with tetramethylbenzidine at room temperature for 20 minutes, and the OD450 nm was determined. The mean and SD of the OD450-nm values for each sample was calculated after the test, and the concentration of LC-SPIK levels was determined using the standard curve generated with the calibrator set. The analytical performance of the test kit is described in the Supplementary Material (Supplementary Digital Content 1, <http://links.lww.com/CTG/A434>). Serum levels of AFP was determined by partner institutions in their clinical laboratories using US Food and Drug Administration (FDA)-approved AFP tests, including the Beckman Coulter UniCel DxI, Siemens Immulite XPI, and Ortho Clinical Diagnostics AFP test.

Western blot

Patient sera and controls (purified LC-SPIK from stable cell line S2-3 and pan-SPIK from PanC1 cells) (27) were separated by sodium dodecyl sulphate-polyacrylamide gel electrophoresis (SDS PAGE) and transferred to polyvinylidene difluoride (PVDF) membrane. SPIK protein was visualized by staining with a polyclonal anti-SPIK antibody and then with a standard anti-mouse secondary antibody conjugated with horseradish peroxidase. An ECL Advance Western Blotting Detection Kit (GE Healthcare, Piscataway, NJ) was used to visualize the image.

Sample population

Serum samples for the primary study were collected prospectively from a total of 488 unique study subjects enrolled in 6 separate clinical sites. These institutions include Beth Israel Deaconess Medical Center, Teaching Hospital of Harvard Medical School, Drexel University College of Medicine, Thomas Jefferson University, Ohio State University, University of California, Irvine, and University of North Carolina. Of those 488 patients, there were 164 HCC patients including 81 patients with early-stage HCC (Barcelona Clinic Liver Cancer [BCLC] stage 0-A). There were 324 controls, including 245 with liver diseases (125 liver cirrhosis and 120 chronic HBV/HCV) and 79 healthy patients. For the independent validation study, additional 102 sera were obtained from a well-characterized biorepository at Beth Israel Deaconess Medical Center. Of these, 45 samples were collected from HCC patients, including 30 patients with early-stage HCC, and 57 samples were collected from patients with cirrhosis as controls. Clinical samples were collected under a study protocol set by ImCare Biotech and approved by each clinical site’s Institutional Review Board.

HCC and control group criteria

HCC was diagnosed through biopsy or computed tomography/MRI using Liver Imaging Reporting and Data System (LI-RADS) classifications of LR4 and LR5 (28). The stage of HCC was determined based on the BCLC staging system as set by American Association for the Study of Liver Diseases guidelines (4). In the control groups, healthy subjects had normal liver biochemistry with no history of underlying liver and alcohol abuse. Determination of liver cirrhosis was based on histological criteria, FibroScan (score >12 kPa), or clinical and radiological evidence of portal hypertension. Follow-up imaging for cirrhotic patients at least 6 months after the blood draw did not show that any had

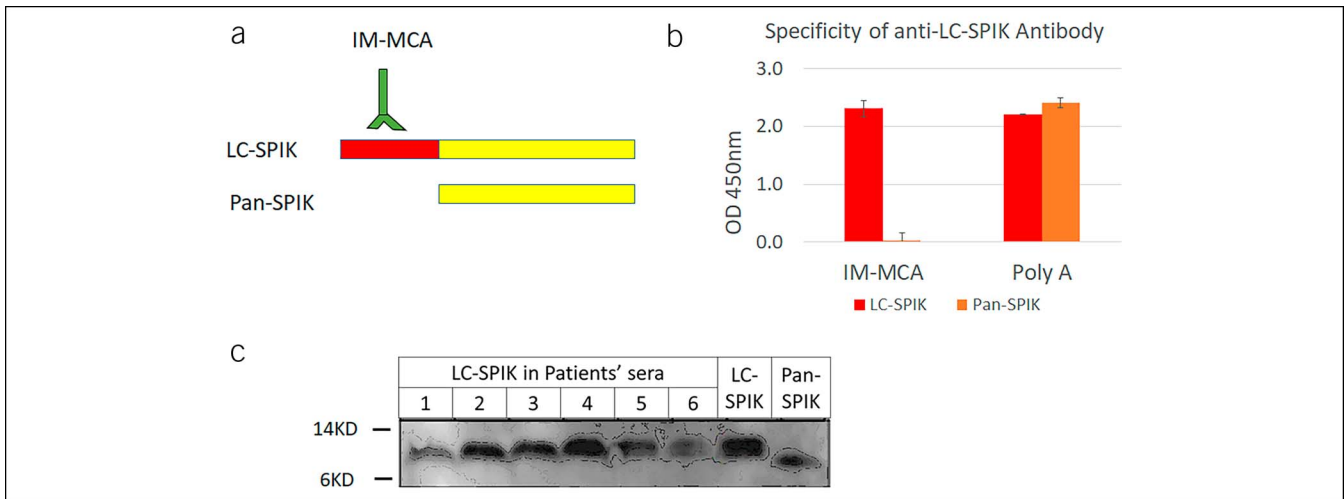


Figure 1. (a) Structural difference between LC-SPIK and pan-SPIK. (b) 96-well plates were immobilized using polyclonal anti-SPIK antibody “poly A” and then incubated with either LC-SPIK from S2-3 cells or pan-SPIK from PanC1 cells (27). The binding activity was quantified by incubation with horse peroxidase–labeled immobilized with a monoclonal anti-LC-SPIK antibody or poly A. (c) Western blot was used to confirm the difference between LC-SPIK and pan-SPIK and the presence of LC-SPIK in HCC patient sera. HCC, hepatocellular carcinoma; LC-SPIK, liver cancer–secreted serine protease inhibitor Kazal; pan-SPIK, pancreatic SPIK.

developed HCC. Noncirrhotic hepatitis B subjects were defined as being surface protein positive with detectable HBV DNA, whereas noncirrhotic hepatitis C patients were defined as having detectable anti-HCV antibody and HCV RNA.

Statistical analysis

Statistical analyses were conducted on all the data collected, together with the relevant clinical information using IBM software SPSS 24 (IBM, Armonk, NY). The serum level of LC-SPIK and the resulting distribution were analyzed for the HCC group and each of our control groups. Values of LC-SPIK and 95% confidence intervals were calculated and visualized by boxplot. Comparisons of LC-SPIK levels in the HCC group and each control group were performed using nonparametric 1-way ANOVA (*post-hoc* multiple) comparisons (Tukey HSD), with P values <0.05 being considered statistically significant. Similar analysis was performed for

patients by age, sex, ethnicity, BCLC stage, and LI-RADS classification.

Receiver operating characteristic (ROC) curves were constructed using HCC patients and controls with liver disease (chronic HBV/HCV and cirrhosis, excluding healthy patients). For LC-SPIK, an optimal cutoff value of 21.5 ng/mL was determined by analyzing the ROC curve and choosing a cutoff value that maximizes sensitivity and specificity for the detection of HCC. This was then used to calculate test sensitivity and specificity. ROC analysis of AFP was also performed, and its sensitivity and specificity were then compared with LC-SPIK.

Similar analysis was performed for the validation study, and details are provided in the Supplementary Material (Supplementary Digital Content 1, <http://links.lww.com/CTG/A434>). The same cutoff value of LC-SPIK (21.5 ng/mL) was confirmed as optimal in the validation study.

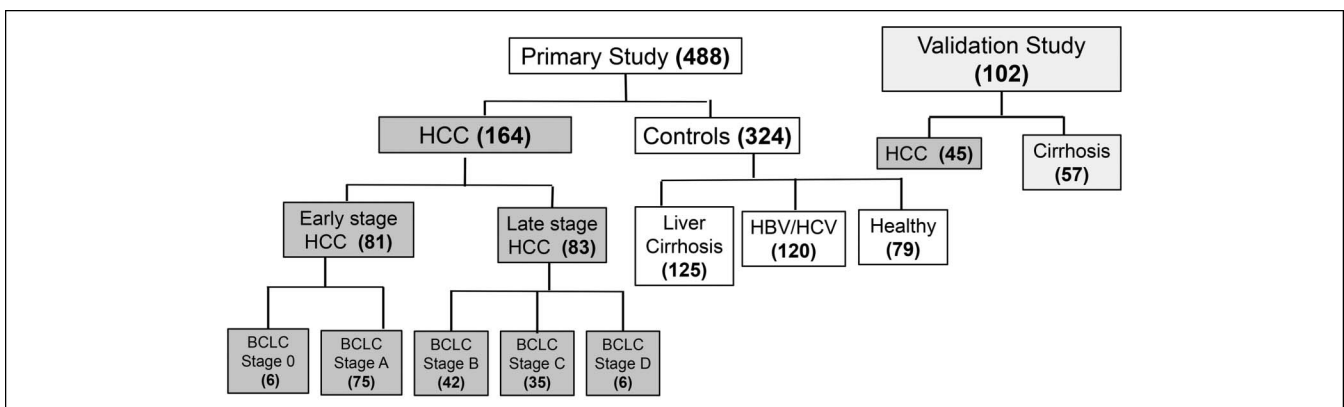


Figure 2. The cohorts of HCC patients and controls in primary and validation studies. The cohorts of HCC patients and controls in both the primary and validation studies are shown. HCC patients in the primary study were further divided into different cohorts in this study according to BCLC stages, per American Association for the Study of Liver Diseases recommendations. HCC, hepatocellular carcinoma.

Table 1. Patient cohorts and their distributions by age, sex, and race

Cohort	Case	Disease association				Age (yr)				Sex		Race			
		HBV	HCV	Nonviral	ND	<36	36–50	51–60	>60	Men	Women	White	Black	Asian	^c Other minority
HCC ^a	164	16	77	39	32	1	14	58	91	130	34	68	71	19	6
		14.0%	62.2%	23.8%	20%	0.6%	8.5%	35.4%	55.5%	79.3%	20.7%	41.5%	43.3%	11.6%	3.7%
Cirrhosis ^b	125	31	34	26	34	3	24	48	50	76	49	70	25	23	7
		24.8%	27.2%	20.8%	27.2%	2.4%	19.2%	38.4%	40.0%	60.8%	39.2%	56.0%	20.0%	18.4%	5.6%
HBV/HCV	120	81	39	NA	0	38	40	22	20	65	55	23	18	68	11
		67.5%	32.5%			31.7%	33.3%	18.3%	16.7%	54.2%	45.8%	19.2%	15.0%	56.7%	9.2%
Healthy	79	NA	NA	NA	NA	14	18	23	24	47	32	49	6	15	9
						17.7%	22.8%	29.1%	30.4%	59.5%	40.5%	62.0%	7.6%	19.0%	11.4%
Total	488					62	103	155	192	334	178	228	123	128	33
						12.1%	20.1%	30.3%	37.5%	65.2%	34.8%	44.5%	24.0%	25.0%	6.4%

HBC, hepatitis B virus; HCC, hepatocellular carcinoma; HCV, hepatitis C virus; NA, not applicable; ND, not determined.

^aNonviral HCC includes alcoholic and other kind of liver cancer.

^bNonviral cirrhosis includes NASH cirrhosis, autoimmune, alcoholic cirrhosis, etc.

^cOther minority includes Hispanic, American Indian, or Alaska Native

RESULTS

LC-SPIK is present in HCC patient's sera but not pan-SPIK

Using our ELISA-based test, we demonstrated that the monoclonal antibody IM-MCA only recognized LC-SPIK but not pan-SPIK, whereas a polyclonal anti-SPIK antibody recognized both forms of SPIK (Figure 1b). Furthermore, we confirmed that LC-SPIK was structurally different from pan-SPIK because of the retention of an extra N-terminal fragment (Figure 1a). Finally, using western blot, we showed that LC-SPIK was the only form present in the sera of HCC patients (Figure 1c).

Patient characteristics

A total of 488 patients were enrolled in the primary study, including 164 with HCC and 324 without HCC. Patient cohorts are detailed in Figure 2, whereas all patient demographics and disease etiology are given in Table 1. Most study participants (65.2%) were men, whereas 34.8% were women; 44.5% of participants self-identified as White, 25.0% as Asian, 24.0% as African American, and 6.4% as other minority, which includes non-White Hispanic, Alaskan Native, and Native American.

Regarding disease etiology, for the liver cirrhosis cohort, 27% of patients had HCV, 25% had HBV, and 21% had nonviral

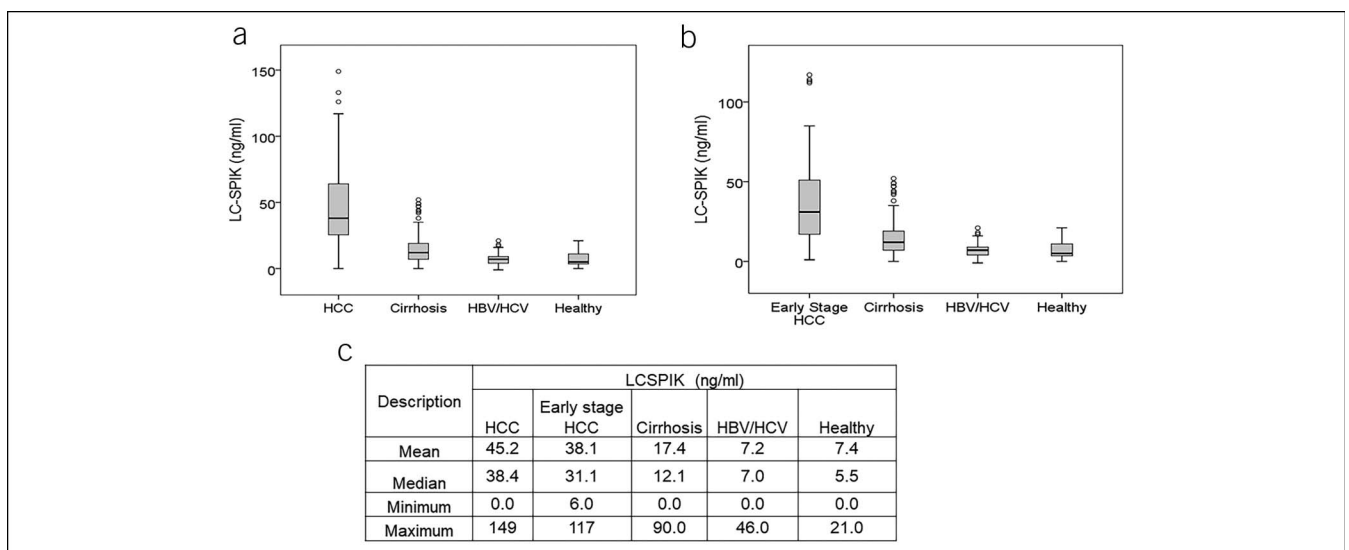


Figure 3. Serum LC-SPIK levels in HCC patients and controls; 10 μ L serum from HCC patients and controls were evaluated using an ELISA test kit. (a) Distribution of serum LC-SPIK levels are compared and visualized for 164 HCC patients and each control group (125 cirrhosis, 120 hepatitis B/C, and 79 healthy subjects). (b) LC-SPIK levels in 81 patients with early-stage HCC are compared with control groups. (c) The mean, median, minimum, and maximum LC-SPIK values for each patient group are listed. HCC, hepatocellular carcinoma; LC-SPIK, liver cancer–secreted serine protease inhibitor Kazal.

Table 2. Liver cancer–secreted serine protease inhibitor Kazal levels in patients, early- vs late-stage HCC

Cohort	No. of cases	Mean (ng/mL)	95% confidence interval for mean		P value for comparisons between each group ^a
			Lower bound	Upper bound	
Early-stage HCC	81	38.1	32.1	44.2	0.003
Late-stage HCC	83	52.2	45.3	59.1	

HCC, hepatocellular carcinoma.
^aDifferences are considered significant at $P < 0.05$.

conditions. In the HCC group, more than 60% of the patients were infected with HCV, whereas 14.0% had HBV and 23.8% had nonviral conditions (Table 1).

Of the 164 HCC patients, 81 were considered early-stage HCC (6 BCLC stage 0 and 75 BCLC stage A), and 83 were considered late-stage HCC (42 BCLC stage B, 35 BCLC Stage C, and 6 BCLC stage D) (Figure 2). In this study, 110 HCC patients had a LI-RADS score of 5, whereas 43 had a LI-RADS score of 4 (see Table, Supplemental Digital Content 2, <http://links.lww.com/CTG/A434>).

Of these 153 patients, 10 patients with LI-RADS (LR)-5 scores and 5 patients with LR-4 scores were further confirmed by biopsy. The remaining 11 patients who did not have LR-4/LR-5 scores were confirmed using biopsy alone, for a total of 26 biopsy-confirmed patients.

Serum LC-SPIK is significantly elevated in HCC patients, including early-stage HCC

The mean serum level of LC-SPIK in all HCC patients was 45.2 ng/mL (95% confidence interval [CI]: 40.5–49.9), which was significantly higher than that in all control groups ($P < 0.001$) (Figure 3a,c). There was no statistically significant difference in serum LC-SPIK levels among subgroups of HCC patients based on age, sex, race, or LI-RADS classification (all $P > 0.3$) (see Table, Supplemental Digital Content 2, <http://links.lww.com/CTG/A434>). The existing pan-SPIK did not interfere in the detection of LC-SPIK in blood (see Figure, Supplemental Digital Content 3, <http://links.lww.com/CTG/A434>).

For the 81 patients with early-stage HCC (BCLC stage 0 and A), the mean concentration of serum LC-SPIK was 38.1 ng/mL (95% CI: 32.1–44.2) and was significantly different from the serum LC-SPIK levels in all control groups ($P < 0.001$) (Figure 3b,c). Late-stage HCC (BCLC stages B, C, and D) had a significantly higher mean LC-SPIK level of 52.2 ng/mL (95% CI:

45.3–59.1) compared with early-stage HCC (38.1 ng/mL, 95% CI: 32.1–44.2) ($P = 0.009$) (Table 2). No statistically significant difference was found in LC-SPIK levels characterized by individual BCLC stages (all $P > 0.250$) (Table 3).

LC-SPIK performance in detecting HCC of any stage

The AUC for LC-SPIK in detecting HCC using patients with liver disease as controls was 0.87 (95% CI: 0.83–0.91), compared with 0.70 (95% CI: 0.64–0.76) for AFP. Using 21.5 ng/mL as a cutoff value for serum LC-SPIK, the sensitivity and specificity of LC-SPIK were 80% and 90%, respectively. Comparatively, using 20.0 ng/mL as a cutoff value of serum AFP, the sensitivity and specificity were only 52% and 86%, respectively, which is significantly lower than that of LC-SPIK ($P < 0.05$) (Figure 4a,c). When using cirrhotic patients alone as the control, LC-SPIK had an AUC of 0.82 (95% CI: 0.77–0.87), with 80% sensitivity and 82% specificity, whereas AFP had an AUC of 0.67 (95% CI: 0.61–0.74), with 52% sensitivity and 78% specificity (Figure 4b,d).

LC-SPIK performance in detecting early-stage HCC

The area under the curve (AUC) for LC-SPIK in detecting early-stage HCC using patients with liver disease as controls was 0.85 (95% CI: 0.79–0.90), compared with only 0.61 (95% CI: 0.52–0.69) for AFP. Using 21.5 ng/mL as cutoff value, sensitivity of LC-SPIK in detecting HCC in its early stages was 72% with 90% specificity, which is significantly higher than the 42% sensitivity and 86% specificity for AFP (Figure 4a,e). When using cirrhotic patients alone as the control, LC-SPIK had an AUC of 0.77 (95% CI: 0.71–0.84), with 72% sensitivity and 82% specificity, whereas AFP had an AUC of 0.59 (95% CI: 0.50–0.67), with 42% sensitivity and 78% specificity (Figure 4b,f).

Table 3. Liver cancer–secreted serine protease inhibitor Kazal levels in patients by Barcelona Clinic Liver Cancer stage

Cohort	No. of cases	Mean (ng/mL)	95% confidence interval for mean		P value for comparisons between each group ^a
			Lower bound	Upper bound	
Stage 0	6	33.7	17.1	50.2	0.250–0.998
Stage A	75	39.6	32.9	46.4	
Stage B	42	48.9	39.3	58.5	
Stage C	35	51.1	40.9	61.4	
Stage D	6	65.6	22.7	108.6	

^aDifferences are considered significant at $P < 0.05$.

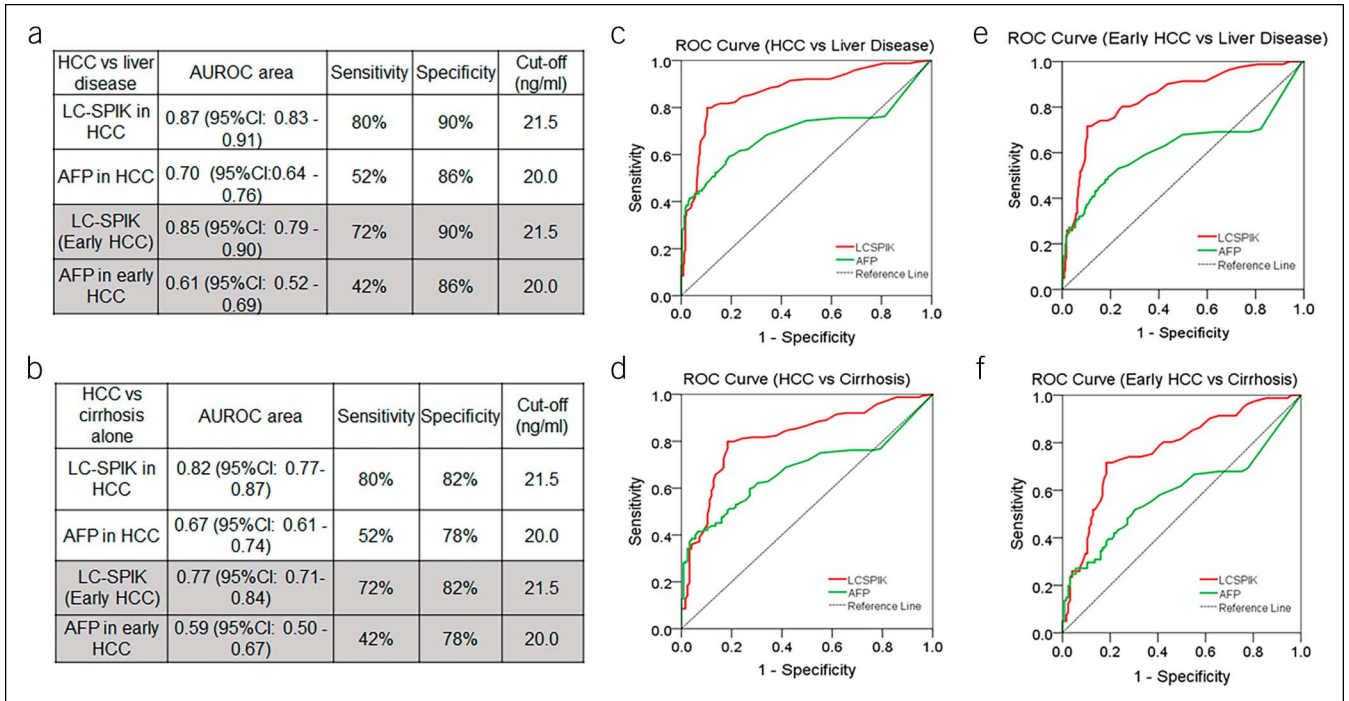


Figure 4. ROC curves of LC-SPIK and AFP in distinguishing HCC with liver disease (cirrhosis and chronic hepatitis B/hepatitis C viruses) as control or cirrhosis alone as the control. The ROC curves of LC-SPIK and AFP in HCC/early-stage HCC patients were constructed using patients with liver disease as the control or cirrhotic patients alone as the control and then compared. (a) The AUC, sensitivity, and specificity of LC-SPIK and AFP in distinguishing HCC/early-stage HCC from liver disease are listed. (b) The AUC, sensitivity, and specificity of LC-SPIK and AFP in distinguishing HCC/early-stage HCC from cirrhosis are listed. (c) ROC curve of LC-SPIK and AFP in distinguishing all HCC from liver disease. (d) ROC curve of LC-SPIK and AFP in distinguishing all HCC from cirrhosis. (e) ROC curve of LC-SPIK and AFP in distinguishing early-stage HCC from liver disease. (f) ROC curve of LC-SPIK and AFP in distinguishing early-stage HCC from cirrhosis. ALP, α -fetoprotein; HCC, hepatocellular carcinoma; LC-SPIK, liver cancer–secreted serine protease inhibitor Kazal; ROC, receiver operating curve.

LC-SPIK performance in HCC patients with false-negative AFP results

Of 164 HCC patients, serum of 77 patients (47%) showed false-negative AFP test results. LC-SPIK correctly detected HCC in 55

of these 77 patients (71%) (Figure 5a,c). For early-stage HCC, AFP gave a false-negative result in 46 of 81 patients (57%). LC-SPIK correctly detected early-stage HCC in 30 of these 46 patients (65%) (Figure 5b,c).

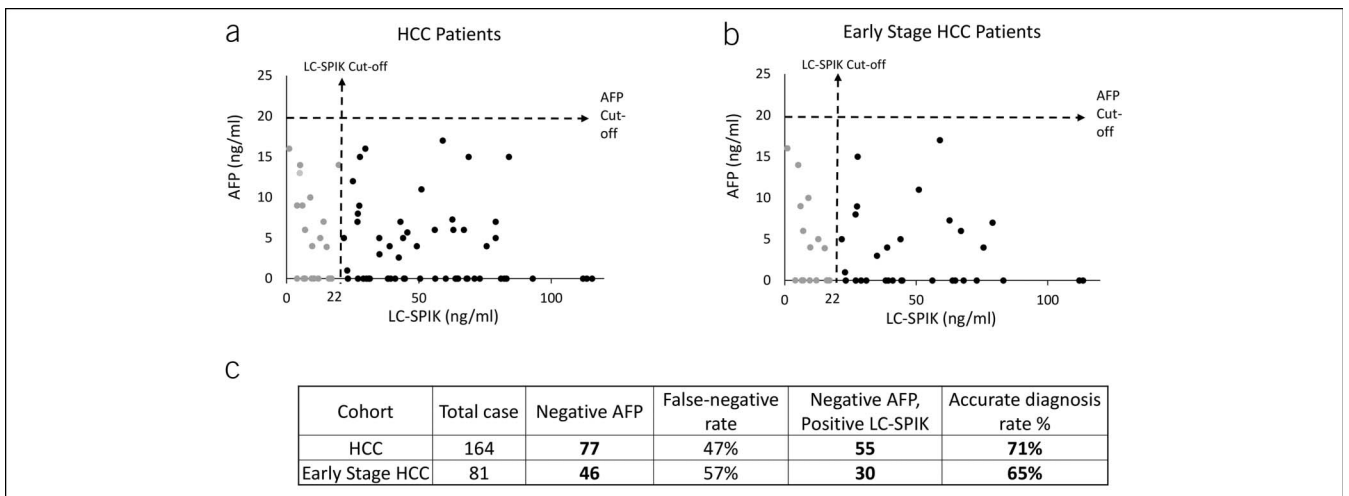


Figure 5. Positive LC-SPIK results in HCC patients with false-negative AFP results. (a) For all patients with positive LC-SPIK test results but false-negative AFP results, their measured serum LC-SPIK and AFP levels are plotted against each other. The position along the x axis indicates serum LC-SPIK level, whereas position along the y axis represents serum AFP level. Each dot represents 1 patient. The cutoff value is 21.5 ng/mL for LC-SPIK and 20.0 ng/mL for AFP. (b) Similar data for patients with early-stage HCC is shown. (c) The number of HCC patients, whose LC-SPIK is true positive but AFP is false negative. ALP, α -fetoprotein; HCC, hepatocellular carcinoma; LC-SPIK, liver cancer–secreted serine protease inhibitor Kazal.

Validation study

To validate the discriminative power of LC-SPIK, a blinded validation study was performed using an independent cohort of 45 HCC patients, which included 30 with early-stage HCC and 57 cirrhotic controls (Figure 1). In this study, the mean serum LC-SPIK level in HCC was 34.2 ng/mL (95% CI: 27.4–41.1), which was significantly higher compared with cirrhotic controls at 19.3 ng/mL (95% CI: 16.9–21.6, $P < 0.001$) (see Table, Supplemental Digital Content 4, <http://links.lww.com/CTG/A434>). The optimal cutoff value of LC-SPIK for HCC was evaluated and remained at 21.5 ng/mL, the same as previously determined in our primary study population. The sensitivity of LC-SPIK was 80%, which is exactly the same as in the primary study and was significantly higher than AFP, which had only 51% sensitivity. The specificity of LC-SPIK in the validation study was 72%, which is lower than that in the primary study (82%) but still within the range of noninferiority (see Table, Supplemental Digital Content 5, <http://links.lww.com/CTG/A434>). Similar results were found in patients with early-stage HCC, where LC-SPIK had 70% sensitivity and was much higher than that of AFP (41%) (see Table, Supplemental Digital Content 5, <http://links.lww.com/CTG/A434>). The validation study did not show a statistically significant difference for specificity between AFP and LC-SPIK.

DISCUSSION

Early HCC detection with an accurate biomarker remains an unmet need. Our study demonstrated that serum LC-SPIK can reliably detect HCC and differentiate between HCC from other liver disease states. Using a cutoff value of 21.5 ng/mL, LC-SPIK was 80% sensitive and 90% specific in detecting HCC at any stage and was 72% sensitive in detecting early stage. In addition, LC-SPIK correctly detected HCC in 5 of 6 patients (83.3%) with very early-stage HCC (BCLC stage 0). Compared with AFP, the biomarker that is most frequently used for HCC detection, LC-SPIK demonstrated higher sensitivity and specificity for all stages of HCC. In addition, LC-SPIK correctly identified HCC in most cases where AFP provides a false-negative result, even for early HCC. These results provide evidence that LC-SPIK is a robust diagnostic biomarker that is superior to AFP, particularly for early-stage HCC.

We also evaluated whether the level of LC-SPIK correlated with the stage of cancer progression. First, we examined the mean levels of LC-SPIK in sera from different stages of HCC, as defined by the BCLC guidelines. This resulted in 5 different stages (shown in Table 3). The mean values of LC-SPIK were consistently higher for late and more advanced stages. Patients in the very early-stage group (BCLC stage 0) had the lowest mean LC-SPIK value of only 33.7 ng/mL, whereas terminal stage D patients had the highest mean LC-SPIK value of 65.6 ng/mL. Analysis based strictly on BCLC classification, however, led to overstratification and uneven sample sizes, especially for hard to recruit groups such as the BCLC stage 0 (very early) and stage D (terminal) groups. Thus, the results were not statistically significant ($P > 0.05$) (Table 3).

We subsequently performed similar analysis focusing on early- and late-stage HCC as defined previously. The mean level of LC-SPIK for patients in the early-stage group was 38.1 ng/mL (95% CI: 32.1–44.2), whereas the mean level of LC-SPIK in the

late-stage group was 52.2 ng/mL (95% CI: 45.3–59.1). Comparing these values, we do see a statistically significant difference between the 2 groups ($P < 0.05$), showing that there is a correlation between progression of HCC by stage and increased levels of LC-SPIK. Although further study is required, these results suggest that LC-SPIK might have potential as a tool to monitor HCC progression.

In this study, we also observed that serum LC-SPIK tested above the 21.5 ng/mL cutoff value in a total of 25 of 324 controls (7.7%). Of these, there were 23 of 125 cirrhotic patients (18.4%) and 2 of 37 HCV-infected patients (5.4%). No false-positive results for LC-SPIK were found in any of the 83 HBV-infected patients or 79 healthy subjects (see Table, Supplemental Digital Content 6, <http://links.lww.com/CTG/A434>). Cirrhotic patients had the highest rate of LC-SPIK positive test results, which might be related to the fact that they also have the highest risk of developing HCC.

The encouraging performance of LC-SPIK as a single biomarker makes it attractive to combine with other novel or existing HCC diagnostic tests. Studies show that there is potential for improvement when combining biomarkers into a panel, such as with the GALAD score, which showed improved sensitivity and specificity over AFP, AFP-L3, and des- γ -(4) prothrombin alone in some cases (29). The performance of LC-SPIK might be further improved when combined with other biomarkers, clinical information, and/or even imaging technologies, such as MRI with hepatobiliary contrast agent (gadoteric acid), which has been shown to greatly improve early stage HCC detection (30). The potential for improved sensitivity and specificity could enhance the efficacy of surveillance programs of high-risk patients and ability to detect early-stage HCC.

In summary, we were able to generate strong evidence that serum LC-SPIK might be applied as a novel diagnostic biomarker for detection of HCC, especially in its early and most treatable stages. It showed much higher sensitivity and specificity than AFP and compared, especially, favorably for patients with early-stage HCC and those with non-AFP-secreting HCC. Further prospective, longitudinal studies with LC-SPIK, either alone or in combination with other HCC diagnostic tests, might be needed to fully evaluate its clinical utility as a tool for HCC surveillance in diverse patient populations and clinical settings.

CONFLICTS OF INTEREST

Guarantor of the article: Xuanyong Lu, PhD.

Specific author contributions: Study conception and design: X.L., F.L., D.T.-Y., G.X., H.S., L.F.C., A.N., C.S., J.C., M.F., and K.-Q.H. Methodology and technology development: F.L., A.R., A.C., and X.L. Source: M.S., C.G.-H., P.A.S., H.S., L.F.C., A.N., C.S., J.C., K.-Q.H., and D.T.-Y.L. Statistical analysis: F.M. Drafting of manuscript: F.L., X.L., and D.T.-Y.L. All authors approved the final version of the article, including the authorship list.

Financial support: This project is funded by National Cancer Institute (NCI, NIH) SBIR phase I and Phase II grant: R43CA165314 and R44 CA165314.

Potential competing interests: X.L. is funded by NCI and financially supported by ImCare Biotech LLC. M.S. and F.L. are currently employed by ImCare Biotech LLC. The other authors have disclosed that they have no conflicts of interest.

Study Highlights

WHAT IS KNOWN

- ✓ HCC is deadly, but survival significantly improves with early detection.
- ✓ There is an unmet need for effective HCC surveillance tools.

WHAT IS NEW HERE

- ✓ Liver cancer–secreted serine protease inhibitor Kazal (LC-SPIK) is a new biomarker for HCC.
- ✓ LC-SPIK detects HCC with high sensitivity and specificity and significantly outperforms AFP.

TRANSLATIONAL IMPACT

- ✓ LC-SPIK can be used as an excellent biomarker for HCC surveillance and discovering HCC in its early and treatable stage.

ACKNOWLEDGEMENTS

We thank Gloria McCarthy and Carol Lam, College of Medicine, Drexel University; Patrick Casey and Cynthia Miller, Thomas Jefferson University; Vijayram Malladi and Karen Joanie Cam-poverde Reyes, Harvard Medical School; Janhvi Rabadey, University of North Carolina; Laura DeGroff, Aladdin Alqais, and Barbara Kleiber, Ohio State University for their support for this study. We thank Aaron Y. Lu for his critical reading of manuscript and comments.

REFERENCES

1. Ricke J, Malfertheiner P. Hepatocellular cancer (HCC) contributes in a significant way to the worldwide burden of neoplastic diseases.. Preface *Dig Dis* 2009;27:79.
2. Brozzetti S, Bezzi M, De Sanctis GM, et al. Elderly and very elderly patients with hepatocellular carcinoma. Strategy for a first line treatment. *Ann Ital Chir* 2013;84:120–8.
3. El-Serag HB, Kanwal F. Epidemiology of hepatocellular carcinoma in the United States: Where are we? Where do we go? *Hepatology* 2014;60:1767–75.
4. Marrero JA, Kulik LM, Sirlin CB, et al. Diagnosis, staging, and management of hepatocellular carcinoma: 2018 practice guidance by the American association for the study of liver diseases. *Hepatology* 2018;68:723–50.
5. Global Burden of Disease Liver Cancer Collaboration; Akinyemiju T, Abera S, Ahmed M, et al. The burden of primary liver cancer and underlying etiologies from 1990 to 2015 at the global, regional, and national level: Results from the global burden of disease study 2015. *JAMA Oncol* 2017;3:1683–91.
6. Bruix J, Sherman M. Management of hepatocellular carcinoma. *Hepatology* 2005;42:1208–36.
7. Kim KM, Sinn DH, Jung SH, et al. The recommended treatment algorithms of the BCLC and HKLC staging systems: Does following these always improve survival rates for HCC patients? *Liver Int* 2016;36:1490–7.
8. European Association for the Study of the Liver. Electronic address eee, European association for the study of the L. EASL clinical practice guidelines: Management of hepatocellular carcinoma. *J Hepatol* 2018;69:182–236.
9. Yu NC, Chaudhari V, Raman SS, et al. CT and MRI improve detection of hepatocellular carcinoma, compared with ultrasound alone, in patients with cirrhosis. *Clin Gastroenterol Hepatol* 2011;9:161–7.
10. Tzartzeva K, Obi J, Rich NE, et al. Surveillance imaging and alpha fetoprotein for early detection of hepatocellular carcinoma in patients with cirrhosis: A meta-analysis. *Gastroenterology* 2018;154:1706–18 e1701.
11. Simmons O, Fetzter DT, Yokoo T, et al. Predictors of adequate ultrasound quality for hepatocellular carcinoma surveillance in patients with cirrhosis. *Aliment Pharmacol Ther* 2017;45:169–77.
12. Song P, Tang Q, Feng X, et al. Biomarkers: Evaluation of clinical utility in surveillance and early diagnosis for hepatocellular carcinoma. *Scand J Clin Lab Invest Suppl* 2016;245:S70–76.
13. Witjes CD, van Aalten SM, Steyerberg EW, et al. Recently introduced biomarkers for screening of hepatocellular carcinoma: A systematic review and meta-analysis. *Hepatol Int* 2013;7:59–64.
14. Giannini EG, Marengo S, Borgonovo G, et al. Alpha-fetoprotein has no prognostic role in small hepatocellular carcinoma identified during surveillance in compensated cirrhosis. *Hepatology* 2012;56:1371–9.
15. Aoyagi Y, Suzuki Y, Isemura M, et al. The fucosylation index of alpha-fetoprotein and its usefulness in the early diagnosis of hepatocellular carcinoma. *Cancer* 1988;61:769–74.
16. Malaguarnera G, Giordano M, Paladina I, et al. Serum markers of hepatocellular carcinoma. *Dig Dis Sci* 2010;55:2744–55.
17. Sherman M. Hepatocellular carcinoma: Epidemiology, risk factors, and screening. *Semin Liver Dis* 2005;25:143–54.
18. El-Serag HB, Kanwal F. alpha-Fetoprotein in hepatocellular carcinoma surveillance: mend it but do not end it. *Clin Gastroenterol Hepatol* 2013;11:441–3.
19. Bartelt DC, Shapanka R, Greene LJ. The primary structure of the human pancreatic secretory trypsin inhibitor. Amino acid sequence of the reduced S-aminoethylated protein. *Arch Biochem Biophys* 1977;179:189–99.
20. Greene LJ, Pubols MH, Bartelt DC. Human pancreatic secretory trypsin inhibitor. *Methods Enzymol* 1976;45:813–25.
21. Lee YC, Pan HW, Peng SY, et al. Overexpression of tumour-associated trypsin inhibitor (TATI) enhances tumour growth and is associated with portal vein invasion, early recurrence and a stage-independent prognostic factor of hepatocellular carcinoma. *Eur J Cancer* 2007;43:736–44.
22. Lu X, Lee M, Tran T, et al. High level expression of apoptosis inhibitor in hepatoma cell line expressing Hepatitis B virus. *Int J Med Sci* 2005;2:30–5.
23. Ohmachi Y, Murata A, Matsuura N, et al. Specific expression of the pancreatic-secretory-trypsin-inhibitor (PSTI) gene in hepatocellular carcinoma. *Int J Cancer* 1993;55:728–34.
24. Hirota M, Ohmuraya M, Baba H. The role of trypsin, trypsin inhibitor, and trypsin receptor in the onset and aggravation of pancreatitis. *J Gastroenterol* 2006;41:832–6.
25. Playford RJ, Hanby AM, Quinn C, et al. Influence of inflammation and atrophy on pancreatic secretory trypsin inhibitor levels within the gastric mucosa. *Gastroenterology* 1994;106:735–41.
26. Kobayashi K, Horiuchi M, Saheki T. Pancreatic secretory trypsin inhibitor as a diagnostic marker for adult-onset type II citrullinemia. *Hepatology* 1997;25:1160–5.
27. Lu F, Lamontagne J, Sun A, et al. Role of the inflammatory protein serine protease inhibitor Kazal in preventing cytolytic granule granzyme A-mediated apoptosis. *Immunology* 2011;134:398–408.
28. Kielar AZ, Elsayes KM, Chernyak V, et al. LI-RADS version 2018: What is new and what does this mean to my radiology reports? *Abdom Radiol (NY)* 2019;44:41–2.
29. Berhane S, Toyoda H, Tada T, et al. Role of the GALAD and BALAD-2 serologic models in diagnosis of hepatocellular carcinoma and prediction of survival in patients. *Clin Gastroenterol Hepatol* 2016;14:875–86 e876.
30. Granito A, Galassi M, Piscaglia F, et al. Impact of gadoxetic acid (Gd-EOB-DTPA)-enhanced magnetic resonance on the non-invasive diagnosis of small hepatocellular carcinoma: A prospective study. *Aliment Pharmacol Ther* 2013;37:355–63.

Open Access This is an open-access article distributed under the terms of the Creative Commons Attribution-Non Commercial-No Derivatives License 4.0 (CCBY-NC-ND), where it is permissible to download and share the work provided it is properly cited. The work cannot be changed in any way or used commercially without permission from the journal.