



## RESEARCH ARTICLE

# REVISED Effect of vitamin E supplementation on orthodontic tooth movement in Wistar rats: a preliminary study [version 3; peer review: 2 approved]

Previously titled: Effect of vitamin E supplementation on orthodontic tooth movement in Wistar rats

Erliera Sufarnap<sup>1</sup> , Darmayanti Siregar<sup>2</sup>, Yumi Lindawati<sup>3</sup>

<sup>1</sup>Department of Orthodontics, Universitas Sumatera Utara, Medan, North Sumatera, 20155, Indonesia

<sup>2</sup>Department of Dental Public Health, Universitas Sumatera Utara, Medan, North Sumatera, 20155, Indonesia

<sup>3</sup>Department of Oral Biology, Universitas Sumatera Utara, Medan, North Sumatera, 20155, Indonesia

**V3** First published: 04 Sep 2020, 9:1093  
<https://doi.org/10.12688/f1000research.25709.1>  
 Second version: 15 Oct 2020, 9:1093  
<https://doi.org/10.12688/f1000research.25709.2>  
 Latest published: 07 Dec 2020, 9:1093  
<https://doi.org/10.12688/f1000research.25709.3>

## Abstract

**Background:** Tooth movement induced by the application of orthodontic force was initiated by inflammatory process. Studies have shown that vitamin E has an anti-inflammatory and antioxidant properties which perhaps could inhibit the tooth to move. This study aimed to evaluate the effect of vitamin E supplementation on orthodontic tooth movement in Wistar rats.

**Methods:** Wistar rats (n=56) were divided into two groups. Group 1 served as the control groups, while group 2 was given vitamin E for 14 days before application of orthodontic force. Each group was divided into four subgroups (n=7), corresponding to the number of days orthodontic force lasted, i.e. 0, 1, 3, 7 days. At each of these four time points, distance measurements and quantity of osteoblasts-osteoclasts were measured in each rat.

**Results:** Tooth movement distance was increased for group 2 than group 1 for all time intervals, but this difference was only statistically different on day 3 ( $p=0.001$ ). For both groups, tooth movement was significantly different between each time interval in each group ( $p=0.041$ ). The mean number of osteoblast cells was increased for group 2 compared to group 1 for all time intervals ( $p<0.05$ ), but was not significant different between time intervals ( $p=0.897$ ). The number of osteoclasts was not significantly different between groups, but it was statistically different between time intervals ( $p=0.004$ ).

**Conclusion:** The outcome of this study demonstrated that group 2 resulted a better tooth movement compared to group 1 and significantly found on day 3, based on the distance measurement. The osteoclast cell numbers were the same within both control groups, whilst the number of osteoblast cells in group 2 was significantly

## Open Peer Review

Reviewer Status  

Invited Reviewers

1 2

### version 3

(revision)  
07 Dec 2020

### version 2

(revision)  
15 Oct 2020



report



### version 1



04 Sep 2020



report



report

1. **Ananto Ali Alhasyimi** , Gadjah Mada University (UGM), Yogyakarta, Indonesia
2. **Hiroyuki Kanzaki** , Tohoku University Hospital, Sendai, Japan  
Tsurumi University, Yokohama, Japan

Any reports and responses or comments on the article can be found at the end of the article.

higher than those in group 1.

### Keywords

Orthodontic tooth movement, vitamin E, tooth movement distance, osteoblast, osteoclast.

**Corresponding author:** Erliera Sufarnap ([erliera@usu.ac.id](mailto:erliera@usu.ac.id))

**Author roles:** **Sufarnap E:** Conceptualization, Data Curation, Formal Analysis, Funding Acquisition, Investigation, Project Administration, Resources, Supervision, Validation; **Siregar D:** Formal Analysis, Methodology, Software; **Lindawati Y:** Visualization, Writing – Review & Editing

**Competing interests:** No competing interests were disclosed.

**Grant information:** This study project is financed by Research Institution of Universitas Sumatera Utara (263/UN5.2.3.1/PPM/KP-TALENTA-USU/2019).

*The funders had no role in study design, data collection and analysis, decision to publish, or preparation of the manuscript.*

**Copyright:** © 2020 Sufarnap E *et al.* This is an open access article distributed under the terms of the [Creative Commons Attribution License](#), which permits unrestricted use, distribution, and reproduction in any medium, provided the original work is properly cited.

**How to cite this article:** Sufarnap E, Siregar D and Lindawati Y. **Effect of vitamin E supplementation on orthodontic tooth movement in Wistar rats: a preliminary study [version 3; peer review: 2 approved]** F1000Research 2020, 9:1093 <https://doi.org/10.12688/f1000research.25709.3>

**First published:** 04 Sep 2020, 9:1093 <https://doi.org/10.12688/f1000research.25709.1>

**REVISED Amendments from Version 2**

Minor revisions at:

## 1. Abstract

Section Conclusion: Words added in a sentence to strengthen the meaning.

## 2. Method

Section Experiment: Revisions at the authorship's name of reference number 17 which we found a mistake.

**Any further responses from the reviewers can be found at the end of the article**

## Introduction

Tooth movement is induced by the application of orthodontic force characterized by bone and periodontal tissue remodeling. Orthodontic force also alters periodontal tissue vascularity and blood flow, resulting in the local synthesis and release of various molecules such as neurotransmitters, cytokines, growth factors, colony-stimulating factors and arachidonic acid metabolites<sup>1</sup>.

Bone remodelling is a process that enables tooth movement. It involves bone-reabsorption by osteoclasts on the pressure site and bone-formation by osteoblasts on the tension site<sup>2,3</sup>. Osteoclasts are multinucleated cells, irregular in shape with a process originating from Howship's lacunae<sup>4</sup>. They stimulate bone resorption by creating cavities in the bone known as lacunae that will be filled by osteoblast cells<sup>3</sup>. According to Mavragani *et al.*, the cellular process of osteoclast proliferation has been used as important indicators in evaluating the level of tooth movement<sup>5</sup>. Osteoblasts are mononuclear cells that originate from mesenchymal stem cells in bone marrow. Mature osteoblasts form the osteoid by synthesizing collagen and non-collagen proteins<sup>6</sup>.

According to Burstone in Asiry's citation, there are three phases of orthodontic tooth movement, which consists the initial, lag and postlag phases<sup>7</sup>. The initial stage of orthodontic tooth movement stimulates an inflammatory response involving cells and blood vessels in periodontal ligaments as well as chemical mediators. In response to mechanical stress caused by the application of orthodontic force, substances such as cytokines and enzymes are released<sup>2,8</sup>. Interleukin-1 $\beta$  is a pro-inflammatory cytokine that facilitates fusion and activation of osteoclasts, and encourages early bone resorption<sup>9</sup>.

Studies have shown that vitamin E has anti-inflammatory properties, which helps suppress damaging effects of oxygen free radicals in cells during bone formation<sup>10</sup>. Previous studies carried out by Esenlik *et al.* and Xu *et al.* suggest that vitamin E supplementation may alter cytokine production; vitamin E supplement maintains normal bone remodelling in young animals and increases bone mass by decreasing the concentration of free radicals which suppress bone formation<sup>11,12</sup>.

Since orthodontic tooth movement is mediated by inflammation process (bone remodelling of cells and chemical mediators, cytokines and growth factors), it is possible to hypothesize

that vitamin E will reduce the tooth movement with its anti-inflammatory effects but it also has a positive effect on bone formation process. The purpose of this study was to evaluate the effect of vitamin E supplementation on tooth movement distance and osteoblast and osteoclast cells in Wistar rats. Mice and rats are mammals that have a reasonably comparable metabolism to humans, which can be used for biological-cellular mechanism analysis in orthodontic tooth movement<sup>13</sup>.

## Methods

### Animals

This article was reported in line with the ARRIVE guidelines. The study was an *in-vivo* quasi experiment, which was approved by the Animal Research Ethics Committee, Department of Biology - Faculty of Mathematics and Science, Universitas Sumatera Utara (No. 0128/KEPH-FMIPA/2019).

A total of 56 healthy male, four to five-months old, Wistar rats, weighing 150–250 grams, were used in this study. The Wistar Rats came from the same breeding farm (Deli Serdang, North Sumatera, Indonesia) in two cycles.

The rats were adapted to their environment for 7 days before the experiment start. They were nurtured at the Animal House at Faculty of Mathematics and Science, Universitas Sumatera Utara in polycarbonate cage, which measured 480 mm  $\times$  265 mm  $\times$  210 mm. Each cage had wood shavings on the floor, and contained 3 or 4 animals, which were marked for each subgroup. Rats were chosen for each group by simple random sampling.

Low light to dark cycle was maintained for a minimum 12 hours at 25–30°C for room temperature within the experiment period. The rats were given a standard pellet diet. All conditions served to produce the optimum condition of the rats' habitat<sup>14</sup>. A rubber separator was inserted between maxillae's incisors to produce non-invasive experiments. Anaesthetic was used to euthanize the rats at the end of the experimental procedure.

### Experiment

Wistar rats (n=56) were divided into two groups. Each group was then divided into four subgroups (n=7), corresponding to the number of the days orthodontic force lasted, i.e. 0, 1, 3, 7 days. Vitamin E or tocopherols (VE) were reportedly able to modulate the estrogen receptor- $\beta$  (ER $\beta$ ) therefore male rats were chosen as subjects for this study<sup>15</sup>. The sample size of each subgroup was decided by Sastroasmoro and Ismael's formula for hypothetical analysis between independent variables<sup>16</sup>.

Subgroups were chosen based on the rats' social behaviours. Hyperactive rats were chosen to be in the same cage, separately to rats with a more passive behaviour. These conditions avoided any anxiety social-related behaviour between rats in the cage within the experiment. For each experiment, a researcher who was blind to the experiment chose a sample randomly from each cage.

Group 1 were the control group and were given water orally as a placebo. The rats' tail was marked with black pen. Group 2 were the experimental group and were given VE (dl- $\alpha$ -Tocopheryl Acetate; Sanbe, Indonesia) at a dosage of 60 mg/kg, orally using gavage needle. The dose chosen was based on a research that had been done by Norazlina *et al.*<sup>17</sup>. The group 2 rats' tail marked with red pen.

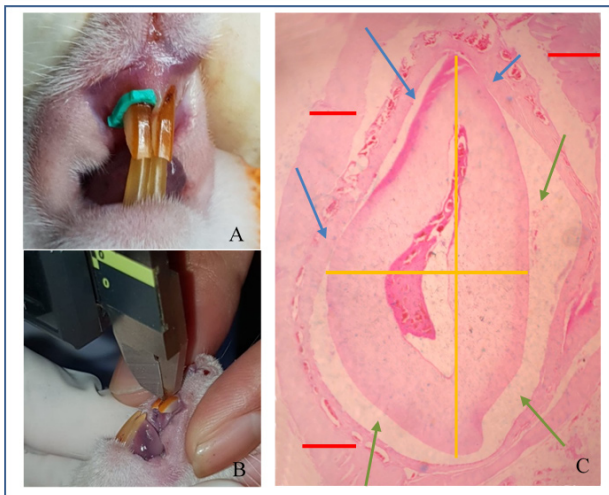
Water and VE were given every day at 8am, for 14 days before and continued after application of orthodontic force. After 14 days, orthodontic force was applied to each rat in both groups by addition of a rubber separator to one of the maxilla incisors (Figure 1A). This administration of orthodontic force applied were carried out before daily water and VE feeding. This procedure counted as the baseline time of the experiment. At each of these four time points distance measurements and quantity of osteoblasts-osteoclasts were measured (see section below).

At end of each experiment period, the dosage of ketamine® at 80mg/kg of body weight and xyla® (Interchemie, Holland) at 10mg/kg of body weight was used to euthanised each rat by cardiac puncture methods for further research with blood analysis.

## Outcomes

Tooth movement was measured using a digital calliper (Mitutoyo, Japan) was used to measure the distance between maxilla incisors at mesial cervical (Moorrees method) immediately after removal of the rubber separator (Figure 1B)<sup>18</sup>.

The pre-maxillae were dissected and fixated in 10% formalin for 24h, and decalcified with rapid-decalcifier, Nitric acid 10% (Aurona Scientific, Singapore) for 10–14 days. The embedded blocks were trimmed using a Leica microtome (Leica, Germany)



**Figure 1.** (A) Rat separator; (B) Distance measurement; (C) Microscopic of whole teeth at 40x magnification. Lines, Yellow=teeth; Green=periodontal ligament; Red=alveolar bone. Arrows, Blue=pressure side; Green=tension side.

into 5 $\mu$ m sections. Histological sections were stained with haematoxylin-eosin and were examined using Olympus CX21 light microscope at 400x magnification to analyse the number of cells within five fields of view for each measurement.

A pressured site on the distal of the tooth exhibited the region of interest (ROI) for a quantitative measured for osteoclast analysis which were described as a narrow area between teeth and alveolar bone where the tooth tended to move, and this site was used for osteoclast analysis. A tension site on the mesial of the tooth exhibited the ROI for a quantitative measured for the osteoblast analysis which were described as a wide area between teeth and alveolar bone where the tooth was left out, and this site was used for osteoblast analysis (Figure 1C).

The histological methods to identify the osteoclasts-osteoblasts include visualization of the cell characteristics and location. Osteoblast describes as a basophilic cuboidal or polygonal mononuclear cells which located on bone surfaces<sup>19</sup>. Osteoclast describes as a giant, multinucleated cell which has an average of 3–20 nucleus, the shape tends to be oval. Osteoclasts are very motile at various sites along the bone surface, it describes the varied appearance of these cells<sup>20</sup>.

## Statistical analysis

IBM-SPSS (Statistical Package for Social Sciences), version 26.0, was used for statistical analysis. Independent t-test and Mann-Whitney test were used to analyse the difference between the two main groups and the inter-rater reliability (IRR) determination were analysed with Cronbach's alpha level. General Linear Model-Repeated Measures (ANOVA GLM-RM) and Friedman analysis were used to analyse the difference between time intervals. Significant differences were determined at  $p < 0.05$ .

## Results

Throughout the feeding of VE supplementation, all rats were habituated to reduce their stress-related disturbances and they seemed to be in a good condition during administration of VE, and no rat had undergone for toxicity and neither had been death within the experimental period.

Determination of osteoblast's and osteoclast's quantity were done by 2 examiners, a senior anatomical pathologists and an orthodontist. Cronbach's alpha interpretation to inter rater reliability (IRR) were 4 samples from group 1 for each time's period, osteoblast's level for alpha was -0,181 (ANOVA,  $p$ -value=0,521) and osteoclast's level for alpha was 0,7 (Friedman,  $p$ -value=0,001). Mean value from both rater were decided to be the amount numbers for this data analysis.

Tooth movement distances were greater in group 2 compared to group 1 at each time point (Table 1). This difference was only statistically significant on day 3 ( $p=0.001$ ). For both groups, tooth movement was significantly different between each time interval in each group ( $p=0.041$ ). After day 3, movement for group 1 reduced, while for group 2, this continued to increase until day 7.

**Table 1. Comparison of tooth movement distance between Group 1 (control) and group 2 (vitamin E treatment (n=7/subgroup (day))).** Data are presented as mean±SD.

Day	Tooth movement (mm)		P value <sup>a</sup>	P value <sup>b</sup>
	Group 1	Group 2		
0	0.00±0.00	0.00±0.00	Baseline	0.041
1	0.25±0.05	0.31±0.13	0.486	
3	0.22±0.12	0.50±0.11	0.001	
7	0.37±0.20	0.55±0.22	0.1373	

p<0.05 – statistically significant. <sup>a</sup>Independent t-test; <sup>b</sup>ANOVA GLM-RM

The number of osteoblasts in group 2 were higher compared with group 1 at each time point (Figure 2A and B; Table 2). These differences were statistically significant (p<0.05). Group 2 showed increased osteoblasts starting from day 0 to day 3, while group 1 had decreased osteoblast after day 3.

The number of osteoclasts in group 2 were higher than group 1 except on day 1, but the differences were not significant statistically (Figure 2C and D; Table 3).

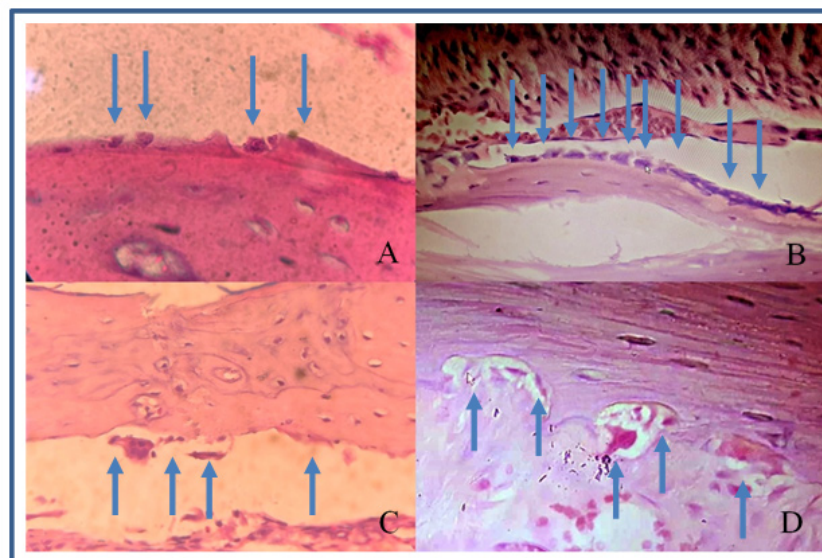
**Discussion**

Orthodontic force causes gradual compression on the periodontal ligament, which leads to circulatory disorders, such as ischemia and hypoxia in the early stage of orthodontic tooth movement<sup>21</sup>. Hypoxia and compression caused by orthodontic

force stimulate the production of reactive oxygen species and free radicals, which contribute to cellular and tissue damage, especially damaging lipid peroxidation chains<sup>22</sup>. Vitamin E is a strong biological antioxidant that has several functions: scavenges free radicals, which inhibit lipid peroxidation and inflammation; protects ischemic tissue and hypoxia; provides immunostimulation<sup>11,23</sup>. Norazlina *et al.* observed the effect of vitamin E supplementation on bone metabolism in mice treated with nicotine. Their study results suggested that vitamin E can increase trabecular bone formation and prevent bone calcium loss by reducing pro-inflammatory cytokines<sup>17</sup>. McGavin *et al.* concluded that vitamin E will have an effect to the plasma alpha tocopherol levels minimum at weeks 4 until 6 from the dietary intake of vitamin E resources whilst from the supplement of 220 IU/day, the levels significantly increased within 2 weeks and remained until weeks 8<sup>24</sup>.

In the present study, it can be seen that both groups showed increased tooth movement distance as well as increase in the number of osteoclast and osteoblast cells on day 1. This is due to the initial phase of tooth movement after application of orthodontic force<sup>25</sup>. This phase occurs 24 hours to 48 hours after application of orthodontic force on teeth<sup>3</sup>.

Our results showed that the number of osteoclasts is higher in group 2 compared to group 1 although the difference was not statistically significant. Miresmaeili *et al.*, in their study on the effect of vitamin C to orthodontic tooth movement, found that osteoclast numbers were significantly higher in the vitamin C group, which hence accelerates tooth movement<sup>26</sup>. Kale *et al.*, in their research on vitamin D injection, observed a significant amount of Howship’s lacunae in resorption cavity as a result of osteoclast’s activity<sup>27</sup>. Future research is required to observe



**Figure 2. Osteoblasts and osteoclasts in rat alveolar bone at 400x magnification. (A)** osteoblasts in group 1 (control); **(B)** osteoblasts in group 2 (vitamin E treatment); **(C)** osteoclasts in group 1; **(D)** osteoclasts in a Howship’s lacuna in group 2.

**Table 2. Comparison of number of osteoblasts between Group 1 (control) and group 2 (VE) (n=7/subgroup (day)).** Data are presented as mean±SD.

Day	Number of osteoblasts (n)		P value <sup>a</sup>	P value <sup>b</sup>
	Group 1	Group 2		
0	5.14±1.34	9.21±3.21	0.012	0.001
1	5.29±1.71	9.36±2.38	0.003	
3	3.86±1.94	10.14±3.53	0.004	
7	5.04±0.95	8.43±1.02	0.002	

p<0.05 – statistically significant. <sup>a</sup>Mann-Whitney test; <sup>b</sup>Friedman analysis

**Table 3. Comparison of number of osteoclasts between Group 1 (control) and group 2 (VE) (n=7/subgroup (day)).** Data are presented as mean±SD.

Day	Number of osteoclasts (n)		P value <sup>a</sup>	P value <sup>b</sup>
	Group 1	Group 2		
0	0.89±0.48	1.18±0.47	0.393	0.016
1	1.86±0.93	1.79±0.77	0.797	
3	1.07±0.91	1.68±0.67	0.109	
7	1.82±1.01	2.18±0.93	0.172	

p<0.05 – statistically significant. <sup>a</sup>Mann-Whitney test; <sup>b</sup>Friedman analysis

the comparison between Howship's lacunae and osteoclasts numbers.

In our study, there were statistically significant differences in the mean number of osteoblast cells between both groups at each time observed. The osteoblast cell numbers significantly higher from the baseline period since the rats already intervened with vitamin E 14 days prior the experiment time. McGavin mentioned that vitamin E supplementation would increased the plasma alpha tocopherol levels minimum of 2 weeks<sup>24</sup>. Kawakami and Takano-Yamamoto demonstrated an increased osteoclast and osteoblast number with local injection of 1,25-dihydroxyvitamin D3 in the submucosal palatal area of rats subjected to tooth movement on day 7. Increased osteoblast counts were observed on day 14<sup>23,28</sup>. In another study, Feresin *et al.* reported that the formation rate and bone volume increased significantly by 65% in rat bone, who were given a vitamin E diet compared to the control group. Their result indicated that a vitamin E diet was able to increase the process of mineralization and

bone formation mediated by osteoblast cells<sup>29</sup>. Diravidamani *et al.* stated that many drugs that are used to reduce pain had effects on orthodontic tooth movement. Further research should be done to observe vitamin E on pain regulation, because it has anti-inflammatory effect, which is assumed to reduce pain in orthodontic treatment<sup>10,30-33</sup>.

The force mechanism from the separator used in our study was static and the elasticity from the separator is easily lost due to saliva acidity (pH), food and chewing process; a the force of a rubber separator will be reduced by 50–55% within 24 hours<sup>33</sup>. This is a limitation of our study, as we wanted to analyse for a longer time and with a larger force. The aim of our study was to see the orthodontic tooth movement and not stabilization, so we decided to observe the orthodontic movement within the initial phase, and not all phases until the lag phase.

The Cronbach's alpha test for the inter-rater reliability (IRR) analysis showed a weak result correlation of osteoblast's level which had a reverse and a "poor" correlation between both agreement. Whilst the the osteoclast's level had an acceptable agreement between IRR. This is also the limitation of this study, further analysis supposed to be complete with specific biomarker for osteoblast and also for osteoclast immunohistochemistry staining which is an important tool to determine the bone resorption and bone remodelling for scientific research which are not determinable by haematoxylin-eosin staining alone<sup>34</sup>. These limitations of the study made this study was designed as a preliminary study.

## Conclusions

Our findings demonstrated that which could be seen in the distance measurement. The osteoclast cell numbers have the same within control groups, whilst the number of osteoblast cells in the VE supplementation group was significantly higher than those in control group. Our hypothesis on the effect of VE supplementation on tooth movement were accept the null hypothesis in osteoclast count which meant that it didn't show inhibited effect in the tooth to move.

## Data availability

### Underlying data

Open Science Framework: Methods, Figures, and Results from "Effect of Vitamin E Supplementation on Orthodontic Tooth Movement in Wistar Rats", <https://doi.org/10.17605/OSF.IO/3S4QB><sup>35</sup>.

### Reporting guidelines

Open Science Framework: ARRIVE checklist for 'Effect of vitamin E supplementation on orthodontic tooth movement in Wistar rats', <https://doi.org/10.17605/OSF.IO/3S4QB><sup>35</sup>.

Data are available under the terms of the [Creative Commons Attribution 4.0 International license](https://creativecommons.org/licenses/by/4.0/) (CC-BY 4.0).

## References

1. Krisnan V, Davidovitch Z: **Cellular, Molecular, and Tissue-Level Reactions to Orthodontic Force.** *Am J Orthod Dentofacial Orthop.* 2006; **129**(4): 469.e1–32. [PubMed Abstract](#) | [Publisher Full Text](#)
2. Nimeri G, Kau CH, Abou-Kheir NS, et al.: **Acceleration of Tooth Movement During Orthodontic Treatment-A Frontier in Orthodontics.** *Prog Orthod.* 2013; **14**: 42. [PubMed Abstract](#) | [Publisher Full Text](#) | [Free Full Text](#)
3. Ariffin SHZ, Yamamoto Z, Abidin IZZ, et al.: **Cellular and Molecular Changes in Orthodontic Tooth Movement.** *ScientificWorldJournal.* 2011; **11**: 1788–803. [PubMed Abstract](#) | [Publisher Full Text](#) | [Free Full Text](#)
4. Bhalaji SI: **Orthodontics: The Art and Science.** New Delhi: Arya (MEDI) Publishing House, 4<sup>th</sup>ed, 2009; 400–2. [Reference Source](#)
5. Mavragani M, Brudvik P, Selvig KA: **Orthodontically Induced Root and Alveolar Bone Resorption: Inhibitory Effect of Systemic Doxycycline Administration In rats.** *Eur J Orthod.* 2005; **27**(3): 215–25. [PubMed Abstract](#) | [Publisher Full Text](#)
6. Alansari S, Sangsuwon C, Vongthongleur T, et al.: **Biological Principles Behind Accelerated Tooth Movement.** *Seminars in Ort.* 2015; **21**(3): 161–61. [Publisher Full Text](#)
7. Asiry MA: **Biological Aspects of Orthodontic Tooth Movement: A Review of Literature.** *Saudi J Biol Sci.* 2018; **25**(6): 1027–1032. [PubMed Abstract](#) | [Publisher Full Text](#) | [Free Full Text](#)
8. Isola G, Matarese G, Cordasco G, et al.: **Mechanobiology of The Tooth Movement During The Orthodontic Treatment: A Literature Review.** *Minerva Stomatol.* 2016; **65**(5): 299–304. [PubMed Abstract](#)
9. Basaran G, Ozer T, Kaya FA, et al.: **Interleukine-1beta and tumor necrosis factor-alpha levels in the human gingival sulcus during orthodontic treatment.** *Angle orthod.* 2006; **76**(5): 830–36. [PubMed Abstract](#)
10. Uysal T, Amasyali M, Olmez H, et al.: **Stimulation of Bone Formation in The Expanding Inter-premaxillary Suture by Vitamin E, In Rat.** *Korean J Orthod.* 2009; **39**(5): 337–48. [Publisher Full Text](#)
11. Esenlik E, Naziroglu M, Acikalin C, et al.: **Vitamin E Supplementation Modulates Gingival Circulatory Fluid Lipid Peroxidation and Antioxidant Levels in Patients With Orthodontic Tooth Movement.** *Cell Biochem Funct.* 2012; **30**(5): 376–81. [PubMed Abstract](#) | [Publisher Full Text](#)
12. Xu H, Watkins BA, Seifer MF: **Vitamin E Stimulates Trabecular Bone Formation and Alters Epiphyseal Cartilage Morphometry.** *Calcif Tissue Int.* 1995; **57**(4): 293–300. [PubMed Abstract](#) | [Publisher Full Text](#)
13. Kirschnack C, Bauer M, Gubernator J, et al.: **Comparative Assessment of Mouse Models for Experimental Orthodontic Tooth Movement.** *Sci Rep.* 2020; **10**(1): 12154. [PubMed Abstract](#) | [Publisher Full Text](#) | [Free Full Text](#)
14. ARR: **Guideline 20: Guidelines for Housing of Rats in Scientific Institutions.** Animal Welfare Branch. ([www.animaletics.org.au](http://www.animaletics.org.au)): 16–55. [Reference Source](#)
15. Khallouki F, de Medina P, Caze-Subra S, et al.: **Molecular and Biochemical Analysis of the Estrogenic and Proliferative Properties of Vitamin E Compounds.** *Front Oncol.* 2016; **5**: 287. [PubMed Abstract](#) | [Publisher Full Text](#) | [Free Full Text](#)
16. Sastroasmoro S, Ismael S: **Dasar-Dasar Metodologi Penelitian Klinis.** 5<sup>th</sup> ed. Sagung Seto. 2014; 352–368. [Reference Source](#)
17. Norazlina M, Lee PL, Lukman HI, et al.: **Effects Of Vitamin E Supplementation On Bone Metabolism In Nicotine-Treated Rats.** *Singapore Med J.* 2007; **48**(3): 195–9. [PubMed Abstract](#)
18. Vanjari K, Nuvvula S, Kamatham R: **Prediction of Canine and Premolar Size Using the Widths of Various Permanent Teeth Combinations: A Cross-Sectional Study.** *Contemp Clin Dent.* 2015; **6**(Suppl 1): S210–20. [PubMed Abstract](#) | [Publisher Full Text](#) | [Free Full Text](#)
19. Henry JP, Bordoni B: **Histology, Osteoblasts.** In: *StatPearls.* Treasure Island (FL): StatPearls Publishing; [Updated 2020 May 21]. 2020. [Reference Source](#)
20. Downey PA, Siegel MI: **Bone biology and the clinical implications for osteoporosis.** *Phys Ther.* 2006; **86**(1): 77–91. [PubMed Abstract](#) | [Publisher Full Text](#)
21. Arai C, Nomura Y, Ishikawa M, et al.: **HSPA1A is upregulated in periodontal ligament at early stage of tooth movement in rats.** *Histochem Cell Biol.* 2010; **134**(4): 337–43. [PubMed Abstract](#) | [Publisher Full Text](#)
22. Zhang L, Wei W, Xu J: **Inhibitory Effect of Melatonin on Diquat-Induced Lipid Peroxidation in Vivo as Assessed by the Measurement of F<sub>2</sub>-Isoprostanes.** *J Pineal Res.* 2006; **40**(4): 326–31. [PubMed Abstract](#) | [Publisher Full Text](#)
23. Arjmandi BH, Juma S, Beharka A, et al.: **Vitamin E Improves Bone Quality in the Aged but Not in Young Adult Male Mice.** *J Nutr Biochem.* 2002; **13**(9): 543. [PubMed Abstract](#) | [Publisher Full Text](#)
24. McGavin JK, Mann JJ, Skeaff CM, et al.: **Comparison of a vitamin E-rich diet and supplemental vitamin E on measures of vitamin E status and lipoprotein profile.** *Eur J Clin Nutr.* 2001; **55**(7): 555–61. [PubMed Abstract](#) | [Publisher Full Text](#)
25. Noda K, Nakamura Y, Kogure K, et al.: **Morphological Changes in the Rat Periodontal Ligament and Its Vascularity After Experimental Tooth Movement Using Superelastic Forces.** *Eur J Orthod.* 2009; **31**(1): 37–45. [PubMed Abstract](#) | [Publisher Full Text](#)
26. Miresmaeili A, Mollaei N, Azar R, et al.: **Effect of Dietary Vitamin C on Orthodontic Tooth Movement in Rats.** *J Dent (Tehran).* 2015; **12**(6): 409–13. [PubMed Abstract](#) | [Free Full Text](#)
27. Kale S, Kocadereli I, Atilla P, et al.: **Comparison of the effects of 1,25 dihydroxycholecalciferol and prostaglandin E<sub>2</sub> on orthodontic tooth movement.** *Am J Orthod Dentofacial Orthop.* 2004; **125**(5): 607–614. [PubMed Abstract](#) | [Publisher Full Text](#)
28. Kawakami M, Takano-Yamamoto T: **Local Injection of 1,25-Dihydroxyvitamin D<sub>3</sub> Enhanced Bone Formation for Tooth Stabilization After Experimental Tooth Movement in Rats.** *J Bone Miner Metab.* 2004; **22**(6): 541–6. [PubMed Abstract](#) | [Publisher Full Text](#)
29. Feresin RG, Johnson SA, Elam ML, et al.: **Effects of Vitamin E on Bone Biomechanical and Histomorphometric Parameters in Ovariectomized Rats.** *J Osteoporos.* 2013; **2013**: 825985. [PubMed Abstract](#) | [Publisher Full Text](#) | [Free Full Text](#)
30. Diravidamani K, Sivalingam SK, Agarwal V: **Drugs Influencing Orthodontic Tooth Movement: An Overall Review.** *J Pharm Bioall Sci.* 2012; **4**(Suppl 2): S299–303. [PubMed Abstract](#) | [Publisher Full Text](#) | [Free Full Text](#)
31. Jiang Q: **Natural forms of vitamin E: metabolism, antioxidant and anti-inflammatory activities and the role in disease prevention and therapy.** *Free Radic Biol Med.* 2014; **72**: 76–90. [PubMed Abstract](#) | [Publisher Full Text](#) | [Free Full Text](#)
32. Long SJ, Benton D: **Effects of vitamin and mineral supplementation on stress, mild psychiatric symptoms, and mood in nonclinical samples: a meta-analysis.** *Psychosom Med.* 2015; **75**(2): 144–153. [PubMed Abstract](#) | [Publisher Full Text](#)
33. Weissheimer A, Locks A, de Menezes LM, et al.: **In Vitro Evaluation of Force Degradation of Elastomeric Chains Used in Orthodontics.** *Dental Press J Orthod.* 2013; **18**(1): 55–62. [PubMed Abstract](#) | [Publisher Full Text](#)
34. Matos LL, Truffelli DC, de Matos MG, et al.: **Immunohistochemistry as an important tool in biomarkers detection and clinical practice.** *Biomark Insights.* 2010; **5**: 9–20. [PubMed Abstract](#) | [Publisher Full Text](#) | [Free Full Text](#)
35. Sufarnap E: **Methods, Figures, and Results from "Effect of Vitamin E Supplementation on Orthodontic Tooth Movement in Wistar Rats.** 2020. <http://www.doi.org/10.17605/OSF.IO/3S4QB>

# Open Peer Review

Current Peer Review Status:  

Version 2

Reviewer Report 24 November 2020

<https://doi.org/10.5256/f1000research.30027.r73171>

© 2020 Kanzaki H. This is an open access peer review report distributed under the terms of the [Creative Commons Attribution License](#), which permits unrestricted use, distribution, and reproduction in any medium, provided the original work is properly cited.



**Hiroyuki Kanzaki** 

<sup>1</sup> Maxillo-oral Disorders, Tohoku University Hospital, Sendai, Japan

<sup>2</sup> Department of Orthodontics, School of Dental Medicine, Tsurumi University, Yokohama, Japan

Thank you for an excellent revision of the manuscript. The reviewer felt that this revised manuscript is appropriate for next step, except for one issue. It is no scale bar at figure 2. If your lab is performing in vitro assay and has hemotocytometer, you can calibrate the microscope scale by using the hemotocytometer. If your lab has no hemotocytometer, microscope calibration slide would help the calibration. Microscope calibration slide is around \$10.00, and not so expensive. I recommend you to set the scale in figure 2 by using microscope calibration slide...

**Competing Interests:** No competing interests were disclosed.

**Reviewer Expertise:** bone biology

**I confirm that I have read this submission and believe that I have an appropriate level of expertise to confirm that it is of an acceptable scientific standard.**

Author Response 28 Nov 2020

**Erliera Sufarnap**, Universitas Sumatera Utara, Medan, Indonesia

**Dear Prof. Hiroyuki Kanzaki;**

Maxillo-oral Disorders, Tohoku University Hospital, Sendai, Japan; Department of Orthodontics, School of Dental Medicine, Tsurumi University, Yokohama, Japan

We send a thousand thanks, gratitudes and appreciations of your knowledge and advices. We currently order the microscope calibration scale and the eyepiece graticule for the Olympus microscope. Unfortunately within this pandemic, the university's laboratorium were closed and some of them switched to 'other' function for the pandemic purposes. We were terribly ask for the forgiveness. Soon after we receive the calibration sets or the



condition of the lab's will clear and clean, we try our best to complete it regardless to the unknown of time prediction.

Once again, I apologize for this matter and thanking you so much for the valuable knowledge for our research.

**Competing Interests:** No competing interest were disclosed

---

## Version 1

Reviewer Report 25 September 2020

<https://doi.org/10.5256/f1000research.28373.r71955>

© 2020 Kanzaki H. This is an open access peer review report distributed under the terms of the [Creative Commons Attribution License](#), which permits unrestricted use, distribution, and reproduction in any medium, provided the original work is properly cited.



**Hiroyuki Kanzaki** 

<sup>1</sup> Maxillo-oral Disorders, Tohoku University Hospital, Sendai, Japan

<sup>2</sup> Department of Orthodontics, School of Dental Medicine, Tsurumi University, Yokohama, Japan

In this manuscript, the authors examined the effect of vitamin E (VE) supplementation on orthodontic tooth movement (OTM). They found that VE augmented OTM only at day-3. The number of osteoblasts was increased by VE at any time point, though the number of osteoclasts was stable irrespective of VE. This manuscript seems at the development stage, and there are some concerns and they are discussed below.

### Major:

1. Increased osteoblast at day 0 in group-2.

Why was there a statistically significant difference on day-0?

2. Model of OTM

The reviewer felt that the model the authors used is not suitable for the model of OTM, due to excessive heavy force by elastic separation band. Other models such as the use of super-elastic coil spring between molar and incisor would be suitable.

### Minor:

1. Please add the scale in figure 2.

2. Vitamin E dosage

Please describe how the authors decided the dose of vitamin E in this experiment.

**Is the work clearly and accurately presented and does it cite the current literature?**

No

**Is the study design appropriate and is the work technically sound?**

No

**Are sufficient details of methods and analysis provided to allow replication by others?**

No

**If applicable, is the statistical analysis and its interpretation appropriate?**

Partly

**Are all the source data underlying the results available to ensure full reproducibility?**

Partly

**Are the conclusions drawn adequately supported by the results?**

Partly

**Competing Interests:** No competing interests were disclosed.

**Reviewer Expertise:** bone biology

**I confirm that I have read this submission and believe that I have an appropriate level of expertise to state that I do not consider it to be of an acceptable scientific standard, for reasons outlined above.**

Author Response 01 Oct 2020

**Erliera Sufarnap**, Universitas Sumatera Utara, Medan, Indonesia

Dear, Assoc. Prof. Hiroyuki Kanzaki, Maxillo-oral Disorders, Yohoku University Hospital, Sendai, Japan

Thank you for your kind attention and assistance in reviewing our manuscript with the precious advices for the manuscript and our further research. We have revised the manuscript according to some inquiries you have been suggested. The following are our comprehensive comments to the review after revised.

**Major :**

1. "In this manuscript, the authors examined the effect of VE supplementation on OTM. They found that VE augmented OTM only at day 3".

**Comment :** The distance measurement showed that the distance of the group 2 (VE) seemed wider for all time point of observation, but unfortunately we found significantly difference only on day 3 since the initial phase was happened within this period of time.

2. "The number of osteoblasts was increased by VE at any time point since the baseline time (day-0)"

**Comment** : VE already intervened 14 days prior the orthodontic separator insertion based on McGavin et al. study<sup>24</sup>. The authors wanted to observe the OTM after the VE circulated to the rats body since VE is one of the regular vitamin to be intake daily.

3. "This manuscript seems at the development stage and there are some concerns suppose to be discussed below"

**Comment** : Yes Indeed, we discuss this is as our limitation of the study on the discussion chapter, moreover we added the Title of this manuscript become "A preliminary study".

4. Model of OTM: "The reviewer felt that the model the authors used is not suitable for the model of OTM, due to excessive heavy force by elastic separation band. Other models such as the use of super-elastic coil spring between molar and incisor would be suitable".

**Comment** : Yes Indeed. For further research we should effort ourself to have more controllable and continuously force of the mechanic. We thank you again for this valuable insight and definitely we will be consider in our future works.

**Minor:**

1. Please add the scale in figure 2

**Comment** : The Olympus CX21 light microscope we used did not have any scale bar and so that the slide we used. We were sorry for our laboratory limitation. I have tried so hard to put in to ImageJ and converted it, but still it could not be processed properly. So, still I couldn't give the answer your inquiry.

2. VE dosage

**Comment** : We have edited and added to the experiment chapter

We thank you again for your kindness for the established and valuable insight of the reviews.

**Competing Interests:** No competing interest were disclosed

Reviewer Report 09 September 2020

<https://doi.org/10.5256/f1000research.28373.r70989>

© 2020 Ali Alhasyimi A. This is an open access peer review report distributed under the terms of the [Creative Commons Attribution License](#), which permits unrestricted use, distribution, and reproduction in any medium, provided the original work is properly cited.



**Ananto Ali Alhasyimi** 

Department of Orthodontics, Faculty of Dentistry, Gadjah Mada University (UGM), Yogyakarta, Indonesia

It's been an honor for us to review the manuscripts. First of all, please allow me to congratulate the authors for endeavoring to undertake this study which I found very interesting and valuable as

a recommendation for further study in the orthodontics field especially in the acceleration of orthodontic tooth movement area. We have been reviewing throughout the manuscript. The following are our comments related to the manuscript.

**General Comment:**

- The title and topic are quite interesting for journal scope and discover a novelty especially for developing natural materials to accelerate orthodontic tooth movement.
- Paper is well-organized and easy to follow.
- To improve the readability, It is recommended that the text is given an English language edit as many of the sentences might be misunderstood and some of typos were found. I suggest a revision of the English grammar structures by an expert editor in revising manuscripts.

**Abstract:**

- The author mentioned: "Tooth movement induced by the application of orthodontic force is facilitated by bone remodeling cells and chemical mediators. Vitamin E has anti-inflammatory properties, which helps in suppressing the damaging effects of oxygen free radicals in cells during bone formation". As we know that inflammation is a part of the orthodontic tooth movement, so it is better to find another logic to connect the reason for using Vitamin E in this study.
- It stated: "Conclusion: Present outcomes demonstrate that vitamin E contributes to faster tooth movement compared to control group. It also stimulates more bone formation without reducing the bone resorption". The author only evaluates the osteoclast and osteoblast number and did not analyze bone formation nor bone resorption indicator. It is better to write a conclusion based on what the author did.

**Introduction:**

- At the end of the introduction part please add some of the hypotheses.

**Methods:**

1. Author used healthy male Wistar ratsà what is the rationale? Please explain shortly in the manuscript.
2. A dosage of 60 mg/kg Vitamin E was used in this study, what is the rationale? Please explain shortly in the manuscript.
3. Authors have chosen HE staining for labeling osteoclast and osteoblast number but did not use any specific marker for osteoblasts (e.g. Von-kossa or Alkaline phosphatase.) and osteoclast (TRAP), rather relied on visual analyses and counting of cells. This method of counting cells is somewhat arbitrary. There are a number of markers available for osteoblasts - osteoclasts using these biomarkers will strengthen this study.
4. Author should add the special characteristic of osteoclast-osteoblast (e.g. osteoblast was demonstrated as a cuboidal shape cell, characterized by a single, large, deep blue-purple nuclei, and found on the edge surfaces of alveolar bone) to minimize the bias and add the

region of interest (ROI) since ROI is the key element in both number counts and distribution. Therefore, it is of utmost importance to show where were these ROIs.

5. A blinded evaluator was responsible for determination of the score and had undergone a training exercise involving the calculation of the Kappa coefficient for the determination of intra-examiner agreement, what about the result? Please write it whether it is satisfactory or not.

### Results

- General results were not reported. What happens with the general health of the animal during the administration of Vitamin E (e.g. general toxicity, edema, deaths affect the body weight of animals?)

### Discussion

- Fairly well written with minor typographical errors.

### Conclusion

- The author only evaluates the osteoclast and osteoblast number and did not analyze bone formation nor bone resorption indicator. It is better to write a conclusion based on what the author did.

**Is the work clearly and accurately presented and does it cite the current literature?**

Yes

**Is the study design appropriate and is the work technically sound?**

Yes

**Are sufficient details of methods and analysis provided to allow replication by others?**

Yes

**If applicable, is the statistical analysis and its interpretation appropriate?**

Yes

**Are all the source data underlying the results available to ensure full reproducibility?**

Yes

**Are the conclusions drawn adequately supported by the results?**

Partly

**Competing Interests:** No competing interests were disclosed.

**Reviewer Expertise:** orthodontic biomaterials

**I confirm that I have read this submission and believe that I have an appropriate level of expertise to confirm that it is of an acceptable scientific standard.**

Author Response 01 Oct 2020

**Erliera Sufarnap**, Universitas Sumatera Utara, Medan, Indonesia

Dear Dr Ananto Ali Alhasyimi, Universitas Gadjah Mada, Sleman, Indonesia

Thank you for your kind assistance in reviewing our manuscript becoming very marvelous manuscript with your advices at many chapters. We have revised the manuscript according to some inquiries you have been suggested. Finally we add the title become 'A preliminary study' which suppose to be our limitation of this research and would be continue to further research which we mentioned on discussion part. Several additional references already provided to consolidated theories which were needed. The following are our comprehensive comments to the review after revised.

1. Abstract
  1. "As we know that inflammation is a part of the orthodontic tooth movement, so it is better to find another logic to connect the reason for using Vitamin E in this study".
    - o : We have edited the reason of using VE in this study
  2. The author only evaluates the osteoclast and osteoblast number and did not analyze bone formation nor bone resorption indicator. It is better to write a conclusion based on what the author did.
    - o : We have edited the conclusion based on the variables we observed without any other conclusion.
2. Introduction : " At the end of the introduction part please add some of the hypotheses".  
**Comment** : We have edited our hypothesize more pointedly.
3. Methods :
  - a. "Author used healthy male Wistar rats what is the rationale? Please explain shortly in the manuscript."  
**Comment** : We were sorry, we've missed the detail to explain why. We edited and gave a reason that VE able to modulate the estrogen (hormone) and a reference had been added to strengthen this reason.
  - b. "A dosage of 60 mg/kg Vitamin E was used in this study, what is the rationale? Please explain shortly in the manuscript."  
**Comment** : The dose chosen was based on a research that had been done by Nur Azlina et al. <sup>17</sup>.
  - c. "There are a number of markers available for osteoblasts – osteoclasts using these biomarkers will strengthen this study".  
**Comment** : We mentioned changes in the title and discussion chapter as our limitations of the study
  - d. Author should add the special characteristic of osteoclast-osteoblast to minimize the bias and add the region of interest (ROI) since ROI is the key element in both number counts and distribution. Therefore, it is of utmost importance to show where were these ROIs.  
**Comment** : Thank you Doctor, We completed and added additional references to mention about the characteristic of osteoblast and osteoclast and explained about the specific ROI.
  - e. A blinded evaluator was responsible for determination of the score and had undergone a training exercise involving the calculation of the Kappa coefficient for the determination of

intra-examiner agreement, what about the result? Please write it whether it is satisfactory or not.

**Comment** : To be honest, the level for IRR results have not very satisfactory result. The observer decided to use the "main value" from both raters as the datas to be analysed. And we also edited and added this results as our limitation of the study at the discussion chapter.

4. Results : General results were not reported. What happens with the general health of the animal during the administration of Vitamin E (e.g.general toxicity, edema, deaths affect the body weight of animals?)

**Comment** : We have edited this inquiry to the result's chapter.

5. Discussion : "Fairly well written with minor typographical errors".

**Comment** : Thank you for the review and we already rechecked and changed.

6. Conclusion : "The author only evaluates the osteoclast and osteoblast number and did not analyze bone formation nor bone resorption indicator. It is better to write a conclusion based on what the author did".

**Comment** : We have edited the conclusion based on the variables we observed without any other conclusion.

Thank you for the established reviews and the valuable insight for our manuscript.

**Competing Interests:** No competing interest were disclosed

The benefits of publishing with F1000Research:

- Your article is published within days, with no editorial bias
- You can publish traditional articles, null/negative results, case reports, data notes and more
- The peer review process is transparent and collaborative
- Your article is indexed in PubMed after passing peer review
- Dedicated customer support at every stage

For pre-submission enquiries, contact [research@f1000.com](mailto:research@f1000.com)

**F1000Research**