

Images of the month: A painful nodule arising within chronic necrobiosis lipoidica

Authors: David McBriar,^A Matthew Costley,^B Joseph Houghton^C and Donal O’Kane^D

KEYWORDS: Necrobiosis lipoidica, squamous cell carcinoma

DOI: 10.7861/clinmed.2020-0618

Case presentation

A 77-year-old woman attended clinic for review of longstanding necrobiosis lipoidica. She reported a tender lesion on the left lower leg that had developed over 2 months. This had not responded to treatment with topical steroids, unlike all previous necrobiosis lipoidica-related ulcerations. On examination, a 15×15 mm tender ulcerating nodule was evident within an area of clinical chronic quiescent necrobiosis lipoidica (Fig 1).

This patient originally presented to our department 9 years previously, with a 3×4 cm well-circumscribed pink-brown plaque with central atrophy and telangiectasia on the left shin. Histology demonstrated a palisading and interstitial granulomatous dermatitis and was supportive of the clinical diagnosis of necrobiosis lipoidica. Past medical history included hypertension and hypothyroidism but not diabetes. Over subsequent years, the plaque on the left shin enlarged and two smaller plaques developed on the right shin. Intermittent areas of ulceration were successfully managed with potent topical steroids (± occlusion). Topical tacrolimus 0.1% had also been beneficial at reducing inflammation in non-ulcerated areas.

A 4 mm incisional punch biopsy was performed on the new nodular lesion. This demonstrated well differentiated squamous cell carcinoma (Fig 2). The nodule was subsequently excised with 4 mm clinical margins and repaired with a split skin graft.

Discussion

Necrobiosis lipoidica is a rare, chronic granulomatous skin disorder. Onset is often in middle age, and there is a female preponderance.¹ It is associated with diabetes in 11–65% of cases.² The pathogenesis is unclear. Typically, necrobiosis lipoidica involves the pre-tibial area; but may involve the scalp, face or upper limbs. Over time, the plaques flatten to form broad, yellow/

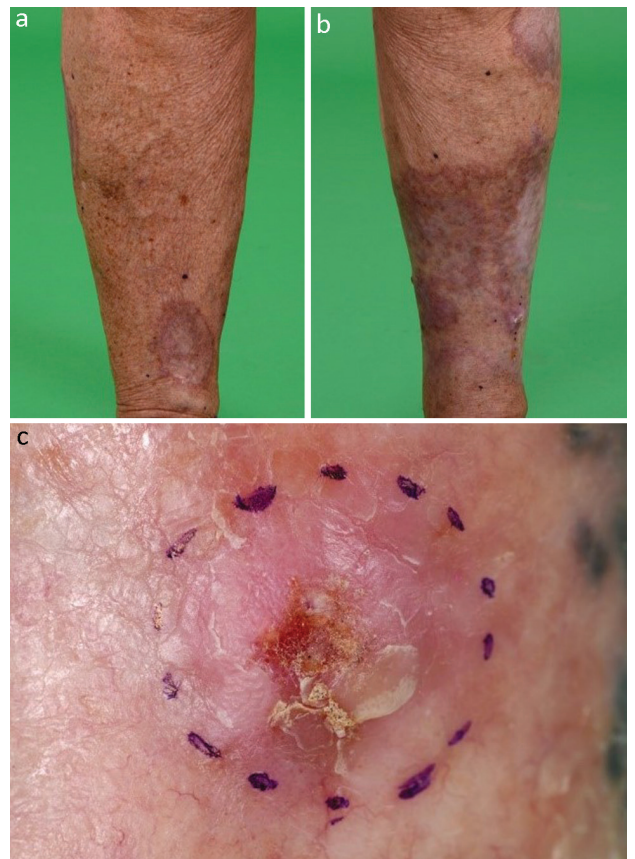

Fig 1. Clinical photographs showing chronic necrobiosis lipoidica. a) Chronic necrobiosis lipoidica in right leg. b) Chronic necrobiosis lipoidica changes more marked on the left leg. c) Area of chronic necrobiosis on the left lateral shin containing a 15 mm tender ulcerating nodule.

orange patches, often with ulceration.³ There is no cure, and the mainstay of treatment is topical corticosteroids.

Marjolin’s ulcer is a term used to describe tumours, classically squamous cell carcinoma, which arise in the setting of chronic skin disease. They are more aggressive than primary skin cancer and have a higher rate of metastatic spread. They may present as an ulcer which fails to heal, as rapid change or as a tender nodule in an area of chronic disease.

The development of squamous cell carcinoma in an area of necrobiosis lipoidica is rare but documented, a review of

Authors: ^Ainternal medicine training-3, Belfast City Hospital, Belfast, UK; ^Bdermatology registrar, Royal Victoria Hospital, Belfast, UK; ^Cconsultant histopathologist, Royal Victoria Hospital, Belfast, UK; ^Dconsultant dermatologist, Royal Victoria Hospital, Belfast, UK

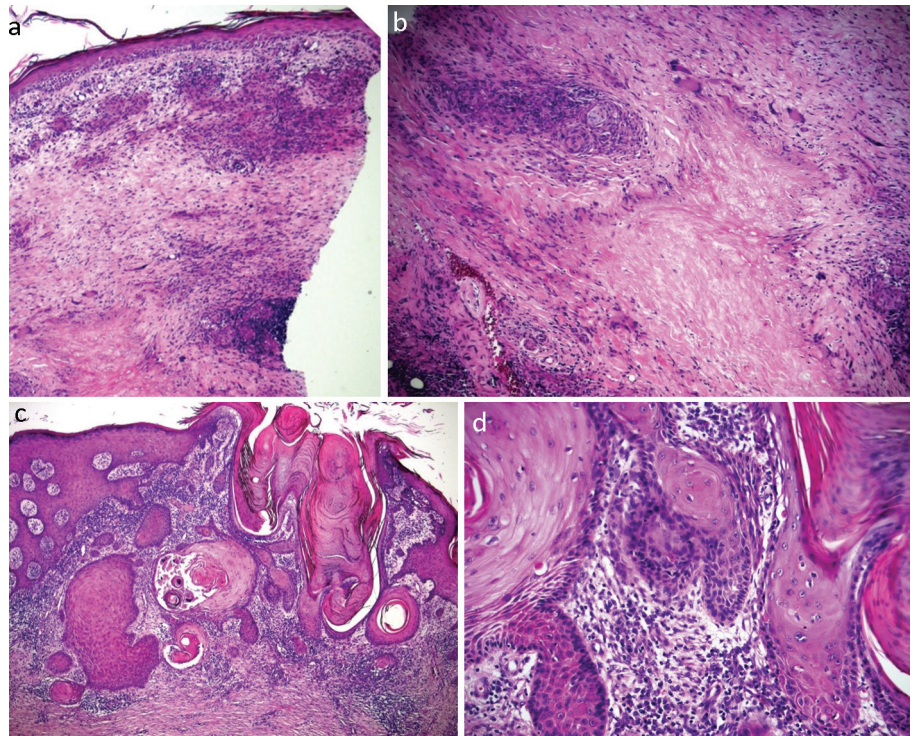


Fig 2. Haematoxylin and eosin stains showing an abnormal squamous proliferation composed of small islands with irregular edges infiltrating a chronically inflamed and fibrotic dermis in keeping with invasive well differentiated squamous cell carcinoma. a) At $\times 10$ magnification. b) At $\times 20$ magnification. c) At $\times 10$ magnification. d) At $\times 40$ magnification.

the literature has demonstrated 16 previous cases.⁴ This case highlights the need to be vigilant to the development of squamous cell carcinoma in the setting of chronic, benign skin disease. In necrobiosis lipoidica, there should be a low threshold for incisional biopsy of a new nodule, evolving ulcer or area not responding to recognised treatment. There is currently no specific guidance on screening or follow-up for non-healing ulceration in patients with necrobiosis lipoidica.⁵

Our case displayed a 9-year history of necrobiosis lipoidica prior to presentation with a squamous cell carcinoma. This is significantly lower than the average time of necrobiosis lipoidica prior to presentation with a primary cancer described in the literature.⁴ This displays the variety of this rare presentation in patients with necrobiosis lipoidica; and they should therefore be counselled in when to seek re-referral and how to self-monitor. ■

References

- 1 Erfurt-Berge C, Dissemond J, Schwede K *et al*. Updated results of 100 patients on clinical features and therapeutic options in

necrobiosis lipoidica in a retrospective multicentre study. *European Journal of Dermatology* 2015;25:595–601.

- 2 Hammer E, Lilienthal E, Hofer SE *et al*. Risk factors for necrobiosis lipoidica in Type 1 diabetes mellitus. *Diabetic Medicine* 2017;34: 86–92.
- 3 Kerr-Valentic MA, Samimi K, Rohlen BH, Agarwal JP, Rockwell WB. Marjolin’s ulcer: modern analysis of an ancient problem. *Plast Reconstr Surg* 2009;123:184–91.
- 4 Lefkovits Y, Adler A. Fatal squamous cell carcinoma from necrobiosis lipoidica diabetorum in a diabetic patient. *Endocrinol Diabetes Metab Case Rep* 2019;2019:19–0007.
- 5 Uva L, Freitas J, Soares de Almeida L *et al*. Squamous cell carcinoma arising in ulcerated necrobiosis lipoidica diabetorum. *International Wound Journal* 2015;12:741–3.

Address for correspondence: Dr David McBriar, Belfast City Hospital, Lisburn Road, Belfast BT9 7AB, UK.

Email: david.mcbriar@outlook.com