




Contents lists available at ScienceDirect

Journal of Clinical Orthopaedics and Trauma

journal homepage: www.elsevier.com/locate/jcot

Review article

SARS-CoV-2 and limb ischemia: A systematic review

Robert M. Putko^{a,*}, Michael D. Bedrin^a, DesRaj M. Clark^a, Andres S. Piscoya^a, John C. Dunn^b, Leon J. Nesti^a^a Department of Orthopaedic Surgery, Uniformed Services University - Walter Reed National Military Medical Center Surgery, Bethesda, MD, 20889, USA^b Department of Orthopaedic Surgery and Rehabilitation, William Beaumont Army Medical Center, El Paso, TX, 79920, USA

ARTICLE INFO

Article history:

Received 2 November 2020

Received in revised form

25 November 2020

Accepted 26 November 2020

Available online 29 November 2020

ABSTRACT

Background: Recent spread of severe acute respiratory coronavirus syndrome-2 (SARS-CoV-2) has led to the coronavirus disease (COVID-19) pandemic, resulting in new challenges across all medical specialties. Limb and digit ischemia have been associated with COVID-19 infection. This systematic review includes primary studies of COVID-19 limb ischemia to identify risk factors, comorbidities, case characteristics, and treatment strategies to better understand the nature of this disease and its effects on the extremities. **Methods:** A literature search for studies detailing COVID-19 infected patients with limb or digit ischemia was performed, identifying 157 articles, 12 of which met inclusion criteria, accounting for 47 patients. Inclusion criteria were (1) primary studies, (2) positive disease diagnosis (3) limb ischemia, (4) reported treatment. Demographic data, case characteristics, treatments, outcomes and mortality were collected and pooled.

Results: The average patient age was 67.6 years, predominantly male (79.6%). Of the 44 cases discussing treatment, 13 (30%) patients underwent medical treatment alone, while 23 (52.3%) patients underwent medical plus surgical treatment. Four patients (9.1%) were treated with observation. In 10 of the 12 studies, lab findings, thrombosis, or conclusions supporting a hypercoagulable state as a cause of limb/digit ischemia were cited. Five patients (10.6%) were on vasopressors and 8 patients (17.0%) were on a ventilator. Of those treated with observation alone, there was 100% resolution of symptoms. Of those treated medically without surgical intervention (17 patients), 6 patients (35.3%) were reported to have revascularization, 6 patients (35.3%) died, and the remaining outcomes were not reported. Medical and surgical treatment resulted in one limb amputation (4.4%) and altogether 74% of patients achieved revascularization of the affected limb/digit. Mortality rate was 45%.

Conclusions: COVID-19 infection may be associated with increased risk of limb or digital ischemia, although the quality of evidence supporting this theory is limited. Evidence of inflammatory-mediated thrombosis and endothelial injury are possible explanations which would support the use of immunotherapy in addition to anticoagulation for treatment or prevention of thromboembolic events. Current outcomes and treatment strategies are variable.

Level of evidence: IV.

© 2020 Delhi Orthopedic Association. All rights reserved.

1. Introduction

Coronavirus disease 2019 (COVID-19) is a respiratory illness caused by severe acute respiratory coronavirus syndrome-2 (SARS-CoV-2). Though known to primarily affect the respiratory system, it

has also been associated with widespread systemic effects to include complications in the cardiovascular, hematologic, neurologic, immunologic and renal systems.¹ Through its rapid transmission world-wide and potentially life and limb threatening complications, COVID-19 has become a global pandemic that has implications through a wide range of medical and surgical specialties due to its association with multi-organ failure. This illness is of particular interest to orthopaedic surgeons due to studies suggesting COVID-19's association with a hypercoagulable state and injury to endothelium through the ACE2 receptor^{2,3} which is thought to play a major role in acute limb ischemia.

* Corresponding author. Department of Orthopaedic Surgery, Uniformed Services University - Walter Reed National Military Medical Center Surgery, 8901 Wisconsin Ave, America Building (19), 2nd Floor, Bethesda, MD, 20889, USA.

E-mail address: robert.putko@gmail.com (R.M. Putko).

With the rise of clinical cases of patients infected with the novel coronavirus pneumonia since December 2019, there has been a plethora of studies describing the wide-ranging impacts of the disease including several reports of acute limb ischemia that involve orthopaedic or vascular surgery consultation.^{4–10} Through systemic inflammation and a hypercoagulable state, there seems to be a spectrum of clinical manifestations of limb injury ranging from chilblains and bullae to acute limb-threatening ischemia. Other clinical findings include acral cyanosis, bruising, blood blisters, and dry gangrene.⁶ Symptoms can be cutaneous, subcutaneous, or involve the entirety of a digit or a distal limb. Outcomes suggest that some patients are able to achieve revascularization of the affected limb or digit with observation or medical and/or surgical intervention, but other patients succumb to either amputation or death due to the disease.

The aim of this review is to analyze the extent of published acute limb ischemia cases in COVID-19 patients as well as established treatment options, outcomes, and mortality. By calculating overall mortality and reviewing severity of illness with respect to treatment modalities and outcomes, this review may better inform healthcare providers in COVID-19 positive patients with limb ischemia. As the pandemic continues to spread and cases rise worldwide, this review may better inform orthopaedic surgeons who are requested in consultation with such cases as well as other treating providers so they may gain a deeper understanding of the effects of SARS-CoV-2 and better counsel and treat patients entrusted to their care.

2. Materials and methods

2.1. Literature review

This study was performed following the PRISMA guidelines without external funding or a previously registered protocol. A literature search of the PubMed, Clinical Key, and Cochrane Library was performed with the following search terms and Boolean operators: “COVID” OR “SARS-CoV-2” AND “Ischemia” with filters for English Language, full length articles, and human subjects resulting in 157 unique results. Two independent reviewers (RP, MB) assessed the titles and abstracts separately for relevancy. In the event of a disagreement, author DC was the arbiter. Abstracts that suggested inclusion in this review were saved for full manuscript review. Articles meeting inclusion criteria were included for full analysis. The GRADE (Grading of Recommendations Assessment, Development and Evaluation Working Group) criteria are a quality assessment template used to evaluate the quality of methods in study analysis.¹¹ Using this template, the quality of the selected studies was then reviewed.

2.2. Eligibility

Inclusion criteria were (1) primary studies, (2) patients diagnosed with SARS-CoV-2, (3) patients with limb ischemia, and (4) reported treatment. Exclusion criteria were (1) review articles, (2) lack of SARS-CoV-2 positivity. Primary outcomes were treatment strategy (i.e. medical management) and outcome of extremity (i.e. revascularization/resolution of ischemia, amputation). Secondary outcome was mortality.

2.3. Data extraction and analysis

Qualified studies that met criteria were examined, and the 2 reviewers extracted all relevant data including study sample size, sex, mean age, average follow up, intervention, and outcomes.

Demographic data, primary outcome measures, and secondary

outcome measures from comparable studies were pooled for all patients. Rates and ratios were converted to percentages when applicable for comparison. Demographic variables, significant laboratory values, treatment modality, outcomes and duration of follow up were pooled and weighted averages were obtained when possible. Mortality and overall study conclusions were similarly recorded.

3. Results

3.1. Included literature and patient demographics

Our literature search identified 12 articles containing 47 patients that met both inclusion and exclusion criteria (Fig. 1, Table 1). Eleven out of 12 studies were either case reports or case series. The remaining article was a prospective cohort study.⁴ Regarding country of origin, four studies were published in Italy, two studies in the United States, and one each in China, France, Portugal, Singapore, Greece, and Spain. Of the 47 patients, 44 were identified as either male or female, with most patients being male (80%). Patient age was reported in 43 patients, with mean age 67.6 years. Treatments were categorized as either medical, medical and surgical, or observation. Given the broad array of treatments rendered, any further subcategorization was deferred. In three cases out of the observational cohort study by Bellosta et al., no treatment was discussed as their conditions were too moribund to undergo operative intervention, although no mention was given to alternative medical treatment modalities.⁴ Of the remaining 44 cases, 13 (30%) cases underwent medical treatment alone, while 23 (52%) underwent medical plus surgical treatment. Four patients (9%) were treated with observation.^{4–10,12–16} Medical treatment for limb ischemia included anticoagulation, thrombolytics, supplemental oxygen, topical nitrates, thermal warming, and immunotherapy, in addition to systemic treatment for additional COVID-19 symptoms. Surgical treatment for limb ischemia included endoscopic versus open thrombectomy, arterial bypass, stenting, angioplasty, endarterectomy, and amputation.

3.2. Outcomes

In 10 out of the 12 studies, lab findings, thrombosis, or conclusions supporting a hypercoagulable state as a cause of limb/digit ischemia were cited. Five patients (10.6%) were noted to be on vasopressors of the 47 diagnosed with acute limb ischemia, while 8 patients (17%) were noted to be on a ventilator (Table 2). Of those treated with observation alone, there was 100% resolution of symptoms (Table 3). Of those treated medically without surgical intervention (17 patients), 6 patients were reported to have revascularization. Another 6 patients died, and the remaining 5 patients' outcomes were not reported. Medical and surgical treatment resulted in one amputation (4%) of the affected limb, 74% of patients achieved revascularization of the affected limb/digit, and the remaining 2 patients in the category had outcomes not reported. In those patients too moribund to undergo surgical treatment (3), all died. In 8 studies that reported patient comorbidities, 11 out of 27 patients (41%) died. In total, mortality was discussed in 40 of the 47 patients, with a rate of 45%. Of note, immunotherapy was discussed in 10 patients included in this systematic review. In one case series of 7 patients, 5 died, and of the remaining 2, one patient's ischemic symptoms improved while in the other ischemic symptoms worsened.⁶ In another series of 2 patients, in one patient limb ischemia symptoms were noted to be completely resolved 14 h after treatment with thrombolysis and administration of tocilizumab. The other patient whose treatment included immunotherapy had digital ischemia noted to be stable, although he

Systematic Review of the Literature PRISMA Flow Diagram

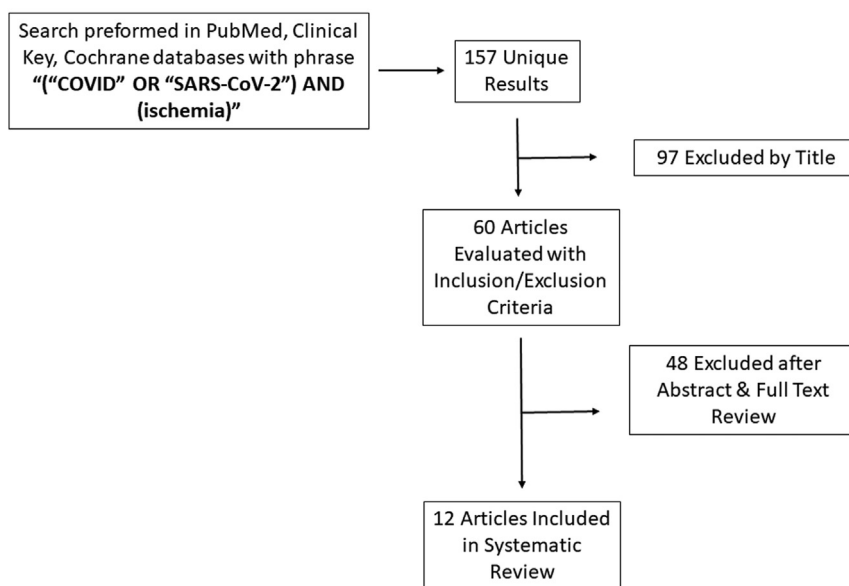


Fig. 1. PRISMA flow diagram indicating search method and article attrition during systematic review process.

Table 1
Demographics.

Author, Year	Journal	Study Design (Level of Evidence)	Sample Size (n)	Gender (M/F)	Mean Age (y)	Treatment	Mean Follow Up (days)	Country
Zhang 2020 ⁵	<i>Chinese J Hematol</i>	Case series (IV)	7	4 M/3 F	59	7 - Medical	26	China
Andrea 2020 ⁶	<i>Int J Infect Dis</i>	Case report (IV)	1	M	58	Medical, surgical	2	Italy
Balestri 2020 ¹¹	<i>J Eur Acad Dermatol Venereol</i>	Case report (IV)	1	F	74	Observation	6	Italy
Bellosta 2020 ³	<i>J Vasc Surg</i>	Prospective cohort study (II)	20	18 M/2 F	75	Surgical -17; NR - 3 (moribund)	NR	Italy
Kashi 2020 ¹²	<i>Thrombosis Res</i>	Case series (IV)	7	5 M/2F	67	2- Medical, surgical; 5 medical	NR	France
Calvao 2020 ¹³	<i>J Eur Acad Dermatol Venereol</i>	Case report (IV)	1	M	81	Medical	died	Portugal
Fan 2020 ⁸	<i>J Thrombo Thromboly</i>	Case report (IV)	1	M	39	Medical, Surgical	NR	Singapore
Suarez-Valle 2020 ¹⁴	<i>J Eur Acad Dermatol Venereol</i>	Case series (IV)	3	NR	NR	Observation	14	Spain
Schultz 2020 ⁴	<i>J Hand Surgery</i>	Case series (IV)	2	1F, 1 M	70, 43	Medical	A-5; B-14	USA
Perini 2020 ⁹	<i>Lancet</i>	Case series (IV)	2	2 M	53, 37	Medical-1; Medical + Surgical- 1	2	Italy
Papamichalis 2020 ⁷	<i>Int J Infect Dis</i>	Case report (IV)	1	M	68	Medical	45	Greece
Kaur 2020 ¹⁵	<i>Hematol Oncol Stem Cell Ther</i>	Case report (IV)	1	M	71	Medical, Surgical	NR	USA

NR = Not reported.

ultimately died following a prolonged hospital course including septic shock and severe acute respiratory distress syndrome.⁸ Lastly, one patient in a case report showed improvement of digital ischemia with treatment including immunotherapy, high-dose heparin, antivirals, and antibiotics.⁵

4. Discussion

Limb ischemia in SARS-CoV-2 positive patients presents a novel challenge to practitioners involved in the care of extremity injuries. This review supports the concept that infection with the SARS-CoV-2 virus may lead to a hyper-inflammatory and hypercoagulable states that may result in varying types of ischemic events involving the digits and limbs. Additionally, most cases of limb ischemia in

SARS-CoV-2 positive patients presented along with elevated inflammatory markers and predominantly in older patients. Presenting symptoms were heterogeneous, as were treatment and outcomes. The level of evidence remains “very low” when considering the GRADE method at this time, which is likely largely in part to the novelty of this disease and the unfolding research being done during this pandemic. As a result, we cannot draw conclusions of causation regarding ischemic events at this time.

Our primary outcomes demonstrated that treatment strategies and outcomes of the affected extremity varied widely across the reported cases, ranging from observation with resolution to open thrombectomy with recurrence and/or amputation. This is likely attributable to presenting location/etiology of ischemia and the degree to which symptoms developed. The most common medical

Table 2
Case details.

Author, Year	Involved limb/digit	Ventilator or pressor treatment	Comorbidities	Pertinent lab findings	Treatment	Outcome, extremity	Mortality	Key Points
Zhang 2020 ⁵	Upper and lower extremity digits	NR	NR	Elevated d-dimer- 7; fibrinogen - 6; FDP - 6; PT prolongation - 4	7 - Medical	5 - Death; 2- NR	5 patients died out of 7. Median time from acro-ischemia to death 12 days	Hypercoagulation status should be monitored closely. In all patients, D-dimer increased to more than 20x normal.
Andrea 2020 ⁶	Right lower limb	Ventilator	HTN	Elevated d-dimer, fibrinogen, and Il-6	Medical, surgical	Return of pulses of R foot	Recovered	Central thrombus in aorta that peripherally embolized
Balestri 2020 ¹¹	Left upper extremity digit	No	Chronic venous leg ulcers, atrial fibrillation, congestive heart failure	NR	Observation	Resolution	Recovered	Asymptomatic COVID-19 patient with ischemia suggests delayed immune response to virus. Onset of symptoms greater than 20 days after follow on negative testing
Bellosta 2020 ³	Bilateral upper and lower extremity limbs	No ventilator, NR pressors	Atrial fibrillation - 5; previous vascular surgery - 4; hypertension -11; diabetes mellitus - 3; chronic obstructive pulmonary disease - 2; coronary artery disease - 2	Mean PO2 66%	17- Medical, surgical; 3- NR (moribund)	Revascularization successful in 12/17 surgical patients; 2/15 required reintervention due to recurrent thrombotic occlusion; major amputation in one patient.	8 died (mean age 81)	Use of post-operative heparin infusion associated with survival (p 0.042). Revascularization success rate lower than expected, possibly due to virus-related hypercoagulable state
Kashi 2020 ¹²	Bilateral lower extremity and limbs	3 on pressor and ventilator	Diabetes mellitus -2; hypertension -6; stroke -1	NR	2- Medical, surgical; 5- medical	NR	NR	Severe thrombosis associated with COVID-19
Calvao 2020 ¹³	Bilateral upper and lower extremity limbs and digits	NR	NR	Elevated CRP, procalcitonin, leukocytosis, d-dimer; biopsy consistent with small vessel vasculitis, partial thickness dermal necrosis	Medical	Death	Died 17 days after developing cutaneous lesions	Ischemic acral lesions may predict poor prognosis as opposed to chilblain lesions mostly seen in young and asymptomatic/ mild patients.
Fan 2020 ⁸	Right lower extremity limb	No	None	Prolonged PT and aPTT; elevated CRP, D-dimer, fibrinogen, factors II, V, VIII, IX, and von Willebrand Antigen	Medical, Surgical	Revascularization of foot	No	Acute ischemic limb due to hypercoagulable state
Suarez-Valle 2020 ¹⁴	Bilateral lower extremity digits	No	NR	Elevated D-dimer - 3 and fibrinogen - 2	Observation	Full recovery of all lesions	No	Spectrum of ischemic lesions ranging from mild, self-limiting to severe and limb threatening
Schultz 2020 ⁴	A - Right upper extremity digit; B -Right upper extremity digits	A- ventilator, pressor; B ventilator, pressor	A- Chronic hepatitis C; B- obesity, hypertension, hyperlipidemia	A- elevated CRP, PT, INR, PTT, D-dimer, fibrinogen; B- elevated D-dimer and fibrinogen	Medical	A- Stable ischemia; B- eschar formation of thumb and index finger, recovery of flow to long finger and small finger	A-yes; B-no	Anticoagulation can be effective; supports hypothesis that COVID-19 can cause hypercoagulable state
Perini 2020 ⁹	A - Bilateral lower extremity limbs; B- left upper extremity limb	1 on ventilator, no pressors	None	Elevated D-dimer	1- Medical; 1- Medical, Surgical	A-Pedal pulse recovery, then recurrence at 2 h postoperatively, followed by continued ischemia until death; B- resolution at 2 days	A-yes; B-no	Supports COVID-19 induced hypercoagulable state
Papamichalis 2020 ⁷	Bilateral upper and lower extremity limbs and digits	Ventilator	Hypertension, diabetes mellitus	Elevated D-dimer, ferritin, CRP	Medical	Resolution of ischemia at 12 h after thrombolysis initiated	Died (sepsis from candidemia/ pseudomonas bacteremia)	Suggests "immunothrombosis" process, antithrombotic treatment plus immunotherapy may be beneficial
Kaur 2020 ¹⁵	Right upper extremity limb	No	Diabetes mellitus	Elevated D-Dimer, ferritin, CRP, LDH, CK	Medical, Surgical	Recovery of palpable radial and ulnar pulses, normal sensation and motor function	Died (cardiac arrest secondary to hypoxemia)	Supports COVID-19 hypercoagulable state and role for anticoagulation

Table 3
Pooled outcomes.

Sample Size	Treatment	Mean Follow Up (days)	Outcome (resolution, amputation, death, NR)
17	Medical	22.1	6 - resolution, 6 - death, 5 - NR
23	Medical + Surgical	2	17 - resolution, 1 - amputation, 3-death, 2-NR
4	Observation	10	4 - resolution
3	NR	NR	3 - death

NR = Not reported.

management strategy either as primary therapy or as an adjunct to open revascularization was anticoagulation with therapeutic-dose heparin or enoxaparin. Tissue plasminogen activator (tPA) was used successfully in one case as well with adjunctive tocilizumab (IL-6 inhibitor),⁸ while in two other cases tocilizumab was used in addition to antibiotics and antivirals with and without anticoagulation respectively.⁵ Other immunotherapy medications such as glucocorticoids and IgG were described as well with some success.⁶ No optimal treatment strategy could be discerned from this data given the heterogeneity in treatments and outcomes. Furthermore, given the high mortality rate across included studies, limb ischemia may be a poor prognostic indicator, which has also been demonstrated elsewhere,¹⁷ although mild cases without associated symptoms did well with observation alone.^{12,15} This would suggest that in patients with COVID-19 symptoms and clinical findings of limb ischemia warranting treatment, actual mortality for this group may be even greater than 45%. Lastly, many patients went on to death despite successful treatment of their limb/digit ischemia as these clinical findings may represent a degree of severity of illness.

Based on these findings, should an orthopaedic surgeon on call be consulted on a COVID-19 positive patient with suspected limb ischemia, a thorough physical exam, laboratory, and radiological work up should be performed. Physical exam should focus on perfusion status of all extremities. Clinical findings suggestive of limb ischemia in COVID-19 patients include chilblains, bullae, blood blisters, acral cyanosis, bruising, and dry gangrene. Laboratory evaluation assessing coagulation function including D-dimer, fibrin/fibrinogen degradation products, fibrinogen (found to be higher in SARS-Cov-2 infected patients)³ should be reviewed. An expert panel from the American Society of Hematology recommends serial monitoring of D-dimer, platelet count, prothrombin time, aPTT, and fibrinogen, with worsening parameters associated with worsening illness.³ Imaging studies including diagnostic ultrasonography and computed tomography angiography may be employed to assess thrombus formation. If suspected limb ischemia is present, use of thrombolytic therapy such as tissue plasminogen activator may be appropriate, in addition to the use of therapeutic-dose heparin products.³ An assessment of vasopressor use should be performed and discontinued if management of concurrent pathology can tolerate removal of vasopressors. Additional medical treatment options may include the addition immunotherapeutic agents, antivirals, antibiotics, topical nitrates and thermal warming. Should medical treatment measures fail, surgical revascularization efforts and lastly amputation should be considered.

Several authors have described an inflammatory mediated mechanism for thrombosis in SARS-CoV-2 patients.^{18,19} This pro-inflammatory state is caused not only by inflammatory cytokines inducing pro-thrombotic state, but it is also believed that SARS-CoV-2 can directly infect endothelial cells through the ACE2 receptor of alveoli, which leads to both endothelial cell activation and dysfunction.³ In the vast majority of cases reviewed here, there was laboratory evidence of elevated inflammatory markers and/or altered clotting parameters. This was the case even in several patients without any significant baseline comorbidities. SARS-CoV-2

has been shown to increase the risk of VTE as well as stroke,²⁰ and the American Society of Hematology recommends therapeutic dose low molecular weight heparin (LMWH) or fondaparinux for all hospitalized patients unless bleeding risk exists.^{9,10} As the clinical manifestations of COVID-19 patients vary, so too do their degrees of ischemia. In very mild cases, patients were treated with observation alone without the need for anticoagulation therapy who noted complete resolution of symptoms. SARS-CoV-2 has also been shown to be a direct cause of endotheliitis, supporting the use of endothelial stabilizing medications such as anti-inflammatory, anti-cytokine drugs, ACE inhibitors, and statins as possible therapeutic or preventative strategies.²¹

This study has several limitations largely due to the novel and rapidly expanding nature of this disease process. Short term, heterogeneous follow-up data exists at this time which limits any pooled measurement of outcomes. Heterogeneity also exists among presenting symptoms as well as reported labs, diagnostic tests, and treatment, making any attempted meta-analysis difficult. The vast majority of literature consists of descriptive case series lacking any comparison groups. It is therefore possible that SARS-CoV-2 infection could be an incidental finding and that SARS-CoV-2 infection does not increase the risk of thrombosis. However, Rey et al. reported a series of cases of acute arterial thrombosis in March 2020 and found that the cohort of patients who were SARS-CoV-2 positive had significantly higher inflammatory markers, higher mortality, and higher proportion of multiple thrombosis events.²² Also of note, approximately 10% of the patients in this review were reportedly on vasopressors, making this a less likely confounding variable. Additionally, one study found an increase in limb ischemia cases when comparing the number of vascular surgery consults from January–March in 2020 vs 2019,⁴ but this finding was not uniform.⁷ This suggests that there may indeed be an association between SARS-CoV-2 and risk of thrombotic/ischemic event, but no definitive causal relationship exists.

Our findings, albeit weakly based on the quality of available evidence, support the theory that SARS-CoV-2 infection may be associated with an increased risk of limb or digital ischemia. While the exact pathophysiology remains unknown, evidence for inflammatory-mediated thrombosis is a possible explanation which would support the use of immunotherapy in addition to anticoagulation for treatment and/or prevention of thromboembolic events. Further understanding of the pathogenesis and optimal treatment strategies of limb ischemia in relation to SARS-CoV-2 viral infection will be important for the vascular, orthopaedic, and microvascular surgeons while new cases continue to accumulate across the world.

Disclaimer

All of the authors are employees of the US Government and this work was prepared as part of their official duties. The views expressed in this article are those of the authors and do not necessarily reflect the official policy or position of the Department of the Navy, Department of the Army, Department of Defense, nor the US Government. Nothing in this article implies any Federal/

DOD/DON/DOA endorsement. Furthermore, each author attests that all individuals who qualify as authors have been listed; each has participated in the conception and design of this work, the analysis of data, the writing of the article, and the approval of the submission of this version; that the article represents valid work; that any information obtained from another source was appropriately acknowledged in this article; and that each author takes public responsibility for the contents of this article.

Conflicts of interest and source of funding

Each author certifies that he has no commercial associations (e.g., consultancies, stock ownership, equity interest, patent/licensing arrangements, etc.) that might pose a conflict of interest in connection with the submitted article. None of the authors received financial support for this study.

References

- Huang C, Wang Y, Li X, et al. Clinical features of patients infected with 2019 novel coronavirus in Wuhan, China. *Lancet*. 2020 02;395(10223):497–506. Epub 2020/01/24.
- Violi F, Pastori D, Cangemi R, Pignatelli P, Loffredo L. Hypercoagulation and antithrombotic treatment in coronavirus 2019: a new challenge. *Thromb Haemostasis*. 2020 Jun;120(6):949–956. <https://doi.org/10.1055/s-0040-1710317>. Epub 2020 Apr 29. PMID: 32349133.
- Abou-Ismaïl MY, Diamond A, Kapoor S, Arafah Y, Nayak L. The hypercoagulable state in COVID-19: incidence, pathophysiology, and management. *Thromb Res*. 2020;194:101–115.
- Bellosta R, Luzzani L, Natalini G, et al. Acute limb ischemia in patients with COVID-19 pneumonia. *J Vasc Surg*. 2020;72(6):1864–1872. <https://doi.org/10.1016/j.jvs.2020.04.483>.
- Schultz K, Wolf JM. Digital ischemia in COVID-19 patients: case report. *J Hand Surg Am*. 2020 Jun;45(6):518–522. Epub 2020/05/11.
- Zhang Y, Cao W, Xiao M, et al. [Clinical and coagulation characteristics of 7 patients with critical COVID-2019 pneumonia and acro-ischemia], *0 Zhonghua Xue Ye Xue Za Zhi*. 2020 Mar 28;41. E006. Epub 2020/03/30.
- Andrea V, Gianluca F, Rodolfo P, Paolo T, Alessandro P, Mauro G. Unheralded lower limb threatening ischemia in a COVID-19 patient. *Int J Infect Dis*. 2020 May 21;96:590–592. Epub 2020/05/25.
- Papamichalis P, Papadogoulas A, Katsiayfylloudis P, et al. Combination of thrombolytic and immunosuppressive therapy for coronavirus disease 2019: a case report. *Int J Infect Dis*. 2020 Jun 1;97:90–93. Epub 2020/06/05.
- Fan BE, Chia YW, Sum CLL, et al. Global haemostatic tests in rapid diagnosis and management of COVID-19 associated coagulopathy in acute limb ischaemia. *J Thromb Thrombolysis*. 2020:1–6.
- Perini P, Nabulsi B, Massoni CB, Azzarone M, Freyrie A. Acute limb ischaemia in two young, non-atherosclerotic patients with COVID-19. *Lancet*. 2020 May 16;395(10236):1546. Epub 2020/05/20.
- Atkins D, Eccles M, Flottorp S, et al. Systems for grading the quality of evidence and the strength of recommendations I: critical appraisal of existing approaches the GRADE Working Group. *BMC Health Serv Res*. 2004 22;4(1):38. <https://doi.org/10.1186/1472-6963-4-38>.
- Balestri R, Termine S, Rech G, Girardelli CR. Late onset of acral necrosis after SARS-CoV-2 infection resolution [published online ahead of print, 2020 May 26] *J Eur Acad Dermatol Venereol*. 2020. <https://doi.org/10.1111/jdv.16668>.
- Kashi M, Jacquin A, Dakhil B, et al. Severe arterial thrombosis associated with Covid-19 infection. *Thromb Res*. 2020 Aug;192:75–77. Epub 2020/05/20.
- Calvão J, Relvas M, Pinho A, Brinca A, Cardoso JC. Acro-ischaemia and COVID-19 infection: clinical and histopathological features [published online ahead of print, 2020 Jun 2] *J Eur Acad Dermatol Venereol*. 2020. <https://doi.org/10.1111/jdv.16687>.
- Suarez-Valle A, Fernandez-Nieto D, Diaz-Guimaraens B, Dominguez-Santas M, Carretero I, Perez-Garcia B. Acro-ischaemia in hospitalized COVID-19 patients. *J Eur Acad Dermatol Venereol*. 2020. <https://doi.org/10.1111/jdv.16592> [Epub ahead of print]; PMID: 32378743; PMCID: PMC7267280.
- Kaur P, Qaqa F, Ramahi A, et al. Acute upper limb ischemia in a patient with COVID-19 [published online ahead of print, 2020 May 13] *Hematol Oncol Stem Cell Ther*. 2020. <https://doi.org/10.1016/j.hemonc.2020.05.001>. S1658-3876(20)30096-0.
- Zhou F, Yu T, Du R, et al. Clinical course and risk factors for mortality of adult inpatients with COVID-19 in Wuhan, China: a retrospective cohort study. *Lancet*. 2020 Mar 28;395(10229):1054–1062. Epub 2020/03/15.
- Han H, Yang L, Liu R, et al. Prominent changes in blood coagulation of patients with SARS-CoV-2 infection. *Clin Chem Lab Med*. 2020 Jun 25;58(7):1116–1120. Epub 2020/03/17.
- Frohman EM, Villemarette-Pittman NR, Melamed E, et al. Part I. SARS-CoV-2 triggered 'PANIC' attack in severe COVID-19. *J Neurol Sci*. 2020 May 21:116936. Epub 2020/06/14.
- Klok FA, Kruip M, van der Meer NJM, et al. Incidence of thrombotic complications in critically ill ICU patients with COVID-19. *Thromb Res*. 2020 Jul;191:145–147. Epub 2020/04/16.
- Varga Z, Flammer AJ, Steiger P, et al. Endothelial cell infection and endotheliitis in COVID-19. *Lancet*. 2020 May 2;395(10234):1417–1418. Epub 2020/04/24.
- Rey JR, Caro-Codón J, Poveda Pineda D, Merino JL, Iniesta Á M, López-Sendón JL. Arterial thrombotic complications in hospitalized patients with COVID-19. *Rev Esp Cardiol (Engl Ed)*. 2020;73(9):769–771. <https://doi.org/10.1016/j.rec.2020.05.008>.