



Since January 2020 Elsevier has created a COVID-19 resource centre with free information in English and Mandarin on the novel coronavirus COVID-19. The COVID-19 resource centre is hosted on Elsevier Connect, the company's public news and information website.

Elsevier hereby grants permission to make all its COVID-19-related research that is available on the COVID-19 resource centre - including this research content - immediately available in PubMed Central and other publicly funded repositories, such as the WHO COVID database with rights for unrestricted research re-use and analyses in any form or by any means with acknowledgement of the original source. These permissions are granted for free by Elsevier for as long as the COVID-19 resource centre remains active.

actuación. Diferentes autores han descrito que la existencia de adherencias pleuropulmonares puede facilitar la perforación al no permitir el colapso pulmonar<sup>1–3</sup>. Algunas publicaciones recientes, basadas en observaciones realizadas a través de autopsias o series quirúrgicas en pacientes con neumonía por Covid-19<sup>4,5</sup>, han demostrado la presencia de áreas de consolidación difusas, densas, de consistencia sólida o cicatricial con abundante exudado inflamatorio alveolar e intersticial, así como la formación de membranas hialinas, que de forma global dificultan el reclutamiento pulmonar y aportan una importante rigidez al parénquima pulmonar.

De acuerdo con estos hallazgos, en caso de perforación del parénquima pulmonar durante la inserción del drenaje torácico, como en nuestro caso, puede no ocurrir un colapso pulmonar inmediato y, por lo tanto, la introducción sencilla del drenaje a través del parénquima pulmonar periférico pudiendo llegar a alcanzar las estructuras hiliares.

Ante un sangrado masivo a través del drenaje torácico tras su colocación debe sospecharse una lesión de grandes vasos, especialmente si se asocia inestabilidad hemodinámica, y el manejo inicial debe consistir en el pinzamiento inmediato del drenaje, así como medidas de estabilización hemodinámica. El tratamiento definitivo es quirúrgico y no debe demorarse, dado que un retraso en la resolución quirúrgica puede conllevar complicaciones como trombosis arterial pulmonar y la propagación de coágulos, un aumento de la poscarga del ventrículo derecho e infarto pulmonar<sup>6</sup>. El objetivo quirúrgico debe ser la retirada controlada del drenaje y la reparación de la arteria pulmonar dañada, que en ocasiones puede llegar a requerir la realización de una neumonectomía para controlar el sangrado<sup>7,8</sup>.

Se ha descrito el manejo conservador en pacientes hemodinámicamente estables mediante la retirada progresiva del drenaje a lo largo de varios días<sup>1</sup>, o embolización selectiva en caso de que la lesión afecte a una rama distal de la arteria pulmonar<sup>3</sup>.

Hay pocos casos en la literatura médica de perforación de arteria pulmonar, no existiendo ningún caso con salida del drenaje a través de la arteria contralateral, por lo que el manejo recomendado al igual que en el resto de los pacientes debe ser individualizado.

Los autores decidimos la realización de un abordaje bilateral secuencial para control proximal de la arteria pulmonar y reparación de los daños ocasionados por la perforación del drenaje, evitando la utilización de bypass cardiopulmonar, y por ende, de anticoagulación sistémica, evitando complicaciones asociadas al uso de circulación extracorpórea secundarias a la respuesta inflamatoria generalizada, lesiones por isquemia-reperusión y por la liberación radicales de oxígeno, especialmente en el caso que presentamos de una paciente con una neumonía bilateral por Covid-19 con mala evolución clínica con ventilación mecánica por insuficiencia respiratoria.

En conclusión, la perforación iatrogénica de la arteria pulmonar es una complicación muy grave asociada a la colocación de un drenaje torácico que requiere de un manejo precoz para control del sangrado y reparación de la arteria pulmonar. De acuerdo con algunas series publicadas, la neumonía por Covid-19 puede conllevar una fibrosis pulmonar que facilite lesiones iatrogénicas con maniobras simples como puede ser la colocación de un drenaje torácico.

### Conflicto de intereses

Los autores declaran no tener conflicto de intereses.

### Bibliografía

1. Biswas M, Boruah PK, von Koch L. A conservative surgical approach for management of iatrogenic pulmonary artery perforation. *Indian J Crit Care Med.* 2012;16:157–9. <http://dx.doi.org/10.4103/0972-5229.102091>.
2. Jauregui A, Deu M, Persiva O. Pulmonary artery perforation after chest tube insertion. *Arch Bronconeumol.* 2016;52:568–9. <http://dx.doi.org/10.1016/j.arbres.2016.03.007>.
3. Shigefuku S, Kudo Y, Saguchi T, Maeda J. Coil embolization for pulmonary artery injury caused by chest tube drainage. *Interact Cardiovasc Thorac Surg.* 2017;24:811–2. <http://dx.doi.org/10.1093/icvts/ivx008>.
4. Déniz-Armengol C, Ramos-Izquierdo R, Ureña-Lliveras A. Paciente con neumonía COVID-19: hallazgos quirúrgicos y correlación radiológica de las lesiones pulmonares. *Arch Bronconeumol.* 2020;56 Suppl 2:33. <http://dx.doi.org/10.1016/j.arbres.2020.04.002>.
5. Wichmann D, Sperhake J-P, Lütgehetmann M, Steurer S, Edler C, Heinemann A, et al. Autopsy findings and venous thromboembolism in patients with COVID-19. *Ann Intern Med.* 2020;173:268–77. <http://dx.doi.org/10.7326/M20-2003>.
6. Edwin F. eComment: Management options of tube thoracostomy-induced pulmonary artery injury. *Interact Cardiovasc Thorac Surg.* 2009;9:760–1. <http://dx.doi.org/10.1510/icvts.2009.209262A>.
7. Rombolá CA, Tomatis SB, Honguero Martínez AF, Atance PL. Parapneumonic pleural effusion. Accidental insertion of a chest tube into right pulmonary artery. *Eur J Cardiothorac Surg.* 2008;34:903. <http://dx.doi.org/10.1016/j.ejcts.2008.06.043>.
8. Bozzani A, Arici V, Bellinzona G, Pirrelli S, Forni E, Odero A. Iatrogenic pulmonary artery rupture due to chest-tube insertion. *Tex Heart Inst J.* 2010;37:732–3.

José Soro-García\*, Mauricio A. Loucel-Bellino, Álvaro Fuentes-Martín, Ángel Cilleruelo-Ramos, José María Matilla-González, Cristina B. García-Rico, Begoña Gregorio-Crespo y Manuel Castanedo-Allende

Servicio de Cirugía Torácica, Hospital Clínico Universitario de Valladolid, Valladolid, España

\* Autor para correspondencia.

Correo electrónico: [josesorogarcia@gmail.com](mailto:josesorogarcia@gmail.com) (J. Soro-García).

<https://doi.org/10.1016/j.arbres.2020.11.005>

0300-2896/ © 2020 SEPAR. Publicado por Elsevier España, S.L.U. Todos los derechos reservados.

### **Trichosporon asahii as Cause of Nosocomial Pneumonia in Patient With COVID-19: A Triple Co-infection**

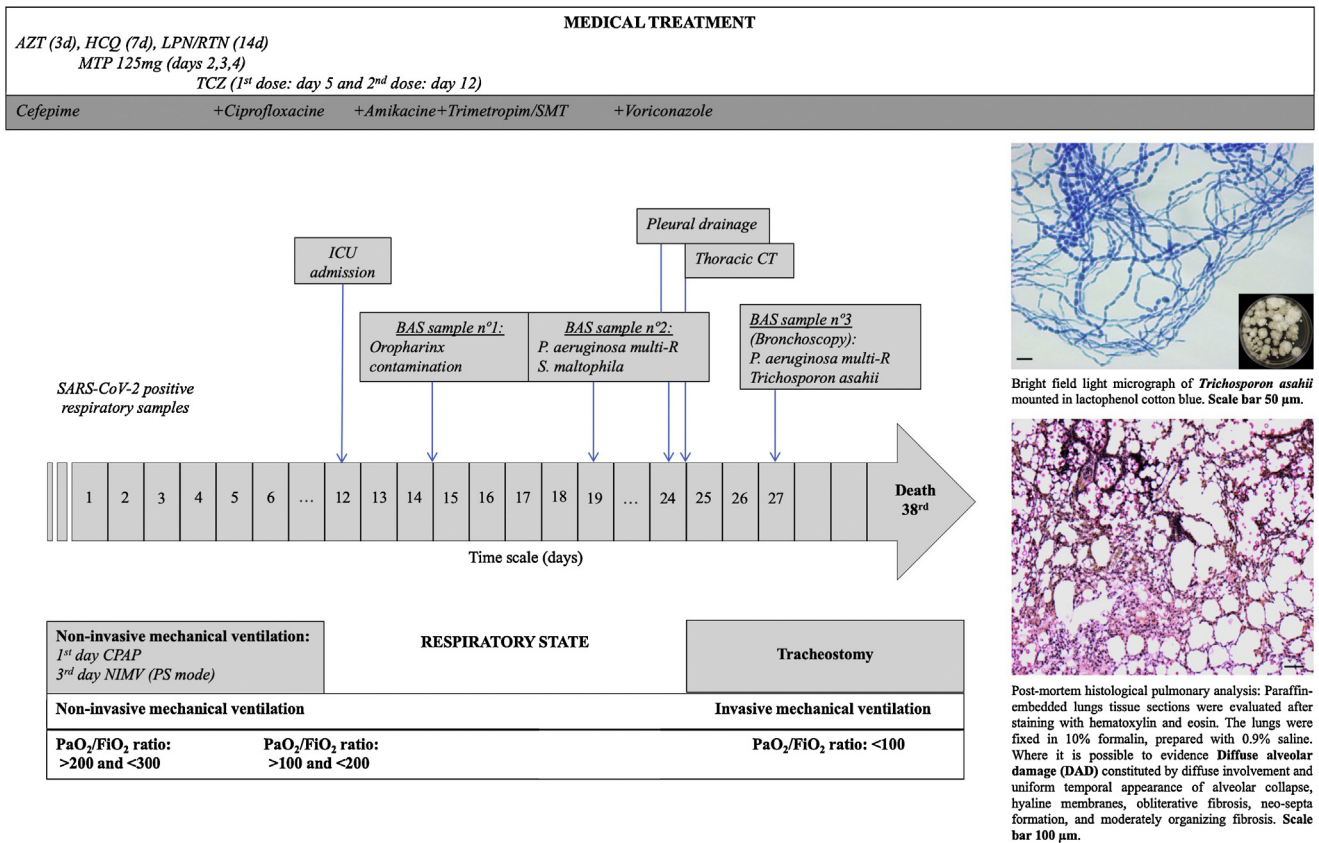


#### **Neumonía nosocomial por Trichosporon asahii**

Dear Editor,

COVID-19, a viral disease caused by the SARS-CoV-2, is a lethal infection in a significant number of cases with several clinical manifestations and symptoms, such as lung damage, exacerbated inflammatory response and, in many cases, generalized organ failure.<sup>1</sup> To combat these symptoms, one or more immunosuppres-

sive drugs can be used individually or in combination<sup>2</sup>; therefore, the treatment itself can impose an additional risk for the development of fungal infections. It is important to emphasize that there are other associated risk factors, such as malnutrition, prolonged intubation, central and/or arterial venous access, and the need for a nasogastric tube that can increase the chances of mycosis infections in patients suffering from severe cases of COVID-19.<sup>3</sup> In the past few decades, the world has experienced an increase in the incidence and spread of emerging fungal infections. This scenario has caused a fundamental change in the epidemiology of invasive fungal diseases, especially in immunocompromised individuals, such as those affected by human immunodeficiency virus (HIV), cancer, or undergoing transplants.<sup>4</sup> Among these emerging pathogens, fungal infections caused by *Trichosporon asahii* have been identified



**Fig. 1.** Timeline for an immunocompetent COVID-19 patient who developed an invasive pulmonary trichosporonosis by *Trichosporon asahii*. The patient was admitted to the intensive care unit on the 12th day after a positive diagnosis by SARS-CoV-2 and died after 24 days. Abbreviations: AZT: Azithromycin HCQ: Hydroxychloroquine sulfate LPN/RTN: Lopinavir/Ritonavir MTP: Methylprednisolone TCZ: Tocilizumab BAS: Bronchial Aspiration CT: Computer Tomography Multi-R: Multi-resistant ICU: Intensive Care Unit CPAP: Continuous Pressure in Upper Airway NIMV: Non-Invasive Mechanical Ventilation.

in neutropenic cancer patients, which significantly increased the severity of their cases leading to a high mortality rate. Recently, the infection has also been identified in other groups of immunocompromised patients.<sup>5</sup>

Here, we report a case of an immunocompetent patient suffering from a severe case of COVID-19 infection who also developed a triple pulmonary coinfection with *Pseudomonas* sp., *Stenotrophomonas* sp. and *Trichosporon* sp.

The patient reported in this study was a 58-year-old male patient that, in 2000, presented a mild chronic kidney disease and had a tuberculosis infection treated with isoniazid chemoprophylaxis. In 2004, he was diagnosed with a bladder neoplasm and was submitted to a radical cystoprostatectomy and a left nephrectomy due to a renal metastasis. The patient had been free of malignant disease for the past ten years and had a competent immune status.

The patient went to the emergency room (Fig. 1 – Day 1) after presenting, for twelve days, high fever, unproductive cough, and general affection. Twenty-four hours before going to the hospital, the patient presented dyspnea with moderate efforts (~90% SpO<sub>2</sub> at rest). A blood test confirmed lymphopenia (900/mm<sup>3</sup>), high C-Reactive Protein (CRP = 35 mg/dL), and altered transaminases (Glutamic Oxaloacetic Transaminase (GOT) 160 IU/L; Glutamate Pyruvic Transaminase (GPT) IU/L; Gamma Glutamyl Transpeptidase (GGT) 75 IU/L, and Phosphatase Alkaline (PAL) 60 IU/L). Chest X-ray images revealed an infiltration in the left base of the lung and the COVID-19 test was positive. With the diagnosis of pneumonia secondary to SARS-CoV-2, the patient was admitted to the Intensive Care Unit (ICU). A treatment off-label with Hydroxychloroquine sulfate 400 mg (equivalent to 310 mg base) Q12H for 2 doses, followed by 200 mg (=155 base) Q12H for 5 days), Lopi-

navir/Ritonavir (400 mg/100 mg), Azithromycin (500 mg daily for three days), Methylprednisolone (bolus of 125 mg daily for three days), and Tocilizumab (two doses of 8 mg/kg IV – 8 h apart) was prescribed and initiated.

During hospitalization (Fig. 1), the respiratory function of the patient aggravated and a high oxygen flow [50 LPM and 90% Fraction of Inspired Oxygen (FiO<sub>2</sub>)] was needed. Finally, an orotracheal intubation and an invasive ventilation was needed on the 12th day of hospitalization in the ICU. On the 19th day (Fig. 1), multiresistant *Pseudomonas aeruginosa* and *Stenotrophomonas maltophilia* strains were isolated from the respiratory secretions of the patient. Despite the treatment with antibiotics, the clinical course of the infection had a poor outcome, and the patient presented persistent fever and hypoxemic respiratory failure. In a chest radiographic exam, left pneumothorax was detected and a chest drainage was performed. A chest CT scan was performed and a suspected pleuropulmonary fistula in the lingular zone, a moderate pleural effusion, and bilateral infiltrates were visualized. Following these results, a fiber bronchoscopy was performed in which abundant purulent secretions, mainly in the right bronchial tree, were visualized and aspirated. Endobronchial lesions were not identified. In the collected respiratory secretions, *Trichosporon asahii* was isolated and a treatment with antifungal drugs (voriconazole) started in day 28th (Fig. 1). The clinical response was weak and the patient developed a septic shock and died on the 38th day after his transfer to the ICU (Fig. 1). The family of the patient authorized the autopsy. The pulmonary autopsy study confirmed the existence of a pattern of acute alveolar damage.

Every day, a discovery regarding the pathophysiological behavior of SARS-CoV-2 emerges. The SARS-CoV-2 causes a lower

respiratory infection which in turn can lead to Acute Respiratory Discomfort Syndromes (ARDS). In addition to a diffuse alveolar damage with severe inflammatory exudation, patients with COVID-19 can present immunosuppression with decreased CD4+T and CD8+ T cells.<sup>6</sup> This clinical scenario opens the door for the development of coinfections by opportunistic microorganisms. Within this context, different published reports have shown the importance of assistant doctors and laboratory specialists in verifying the occurrence of potential coinfections, such as aspergillosis, candidiasis, mucormycosis, or cryptococcosis that could lead to co-morbidities in patients with COVID-19.<sup>7</sup>

The incidence of invasive infections caused by opportunistic fungal species has increased in recent decades. These fungi are normally difficult to diagnose, resistant to many antifungals, and are associated with high mortality rates.<sup>8</sup> In the 1980s, the invasive *Trichosporon* infection was considered the second most common cause of fungemia among immunosuppressed patients who also suffered from hematological diseases, hemochromatosis, end-stage renal disease, or who were on a long-term corticosteroid treatment. Depending on the age, underlying conditions, presence of neutropenia, and clinical treatments, the mortality rates of patients suffering from an invasive trichosporonosis infection can range from 30% to 90%.<sup>9–11</sup> Until now, our case is the first report that shows a *Trichosporon* infection in a COVID-19 patient.

In conclusion, we report a case of a triple pulmonary coinfection in an immunocompetent patient with severe SARS-CoV-2 pneumonia. As the pandemic continues to spread around the world, other reports to assess the frequency of emergent and reemerging highly resistant bacterial and fungal coinfections in individuals suffering from COVID-19 are needed. These coinfections impose severe complications in COVID-19 patients that might lead to death due to the aggravation in the primary viral condition.

#### Ethics declarations

The present study was approved by the Ethics Committee of the Fundación Jiménez Díaz Health Research Institute (EO102-20-HRJC). Due to the pandemic situation, informed consent was not requested from the patients. Personal information and data obtained from the subjects were kept confidential.

#### Conflict of interest

The authors declare that they have no known competing financial interests or personal relationships that could have appeared to influence the work reported in this paper.

#### Acknowledgements

We acknowledge Dr. Barbara Hissa for critical reading and scientific editing of the manuscript. This work was supported by the

Brazilian agencies Conselho Nacional de Desenvolvimento Científico e Tecnológico (CNPq), Coordenação de Aperfeiçoamento de Pessoal de Nível Superior (CAPES) – Finance Code 001 and Fundação Carlos Chagas Filho de Amparo à Pesquisa do Estado do Rio de Janeiro (FAPERJ).

#### Bibliografía

1. Calabrese F, Pezzuto F, Fortarezza F, Hofman P, Kern I, Panizo A, et al. Pulmonary pathology and COVID-19: lessons from autopsy. The experience of European Pulmonary Pathologists. *Virchows Arch*. 2020.
2. Lai CC, Shih TP, Ko WC, Tang HJ, Hsueh PR. Severe acute respiratory syndrome coronavirus 2 (SARS-CoV-2) and coronavirus disease-2019 (COVID-19): the epidemic and the challenges. *Elsevier B.V.*; 2020.
3. Chen N, Zhou M, Dong X, Qu J, Gong F, Han Y, et al. Epidemiological and clinical characteristics of 99 cases of 2019 novel coronavirus pneumonia in Wuhan, China: a descriptive study. *Lancet*. 2020;395:507–13.
4. Rodriguez-Tudela JL, Alastruey-Izquierdo A, Gago S, Cuenca-Estrella M, León C, Miro JM, et al. Burden of serious fungal infections in Spain. *Clin Microbiol Infect*. 2015;21:183–9.
5. de Almeida JN, Hennequin C. Invasive trichosporon infection: a systematic review on a re-emerging fungal pathogen. *Frontiers Media S.A.*; 2016.
6. Lu Q-B, Jiang W-L, Zhang X, Li H-J, Zhang X-A, Zeng H-L, et al. Comorbidities for fatal outcome among the COVID-19 patients: a hospital-based case-control study. *J Infect*. 2020:1–4.
7. Song G, Liang G, Liu W. Fungal co-infections associated with global COVID-19 pandemic: a clinical and diagnostic perspective from china. *Mycopathologia*. 2020;185:599–606.
8. Chagas-Neto TC, Chaves GM, Colombo AL. Update on the genus trichosporon. *Mycopathologia*. 2008;166:121–32.
9. Walsh TJ, Groll A, Hiemenz J, Fleming R, Roilides E, Anaissie E. Infections due to emerging and uncommon medically important fungal pathogens. *Clin Microbiol Infect*. 2004;10:48–66.
10. Kontoyiannis DP, Torres HA, Chagua M, Hachem R, Tarrand JJ, Bodey GP, et al. Trichosporonosis in a tertiary care cancer center: risk factors, changing spectrum and determinants of outcome. *Scand J Infect Dis*. 2004;36:564–9.
11. Liao Y, Lu X, Yang S, Luo Y, Chen Q, Yang R. Epidemiology and outcome of Trichosporon Fungemia: a review of 185 reported cases from 1975 to 2014. *Open Forum Infect Dis*. 2015;2:10.

Gonzalo Segrelles-Calvo<sup>a,b</sup>, Glauber R. De S. Araújo<sup>c</sup>, Estefanía Llopis-Pastor<sup>a</sup>, Susana Frases<sup>c,\*</sup>

<sup>a</sup> Servicio de Neumología, Hospital Universitario Rey Juan Carlos, Madrid, Spain

<sup>b</sup> Instituto de Investigación Biomédica, Fundación Jiménez Díaz, Madrid, Spain

<sup>c</sup> Laboratório de Biofísica de Fungos, Instituto de Biofísica Carlos Chagas Filho, Universidade Federal do Rio de Janeiro, Rio de Janeiro, RJ, Brazil

Corresponding author.

E-mail address: [susanafrases@biof.ufrj.br](mailto:susanafrases@biof.ufrj.br) (S. Frases).

<https://doi.org/10.1016/j.arbres.2020.11.007>

0300-2896/ © 2020 SEPAR. Published by Elsevier España, S.L.U. All rights reserved.

### Costocondritis y espondilitis diferidas por *Candida* en paciente post-COVID-19 tratado previamente con corticoides, antibióticos y tocilizumab



### Delayed Candida Costochondritis and Spondylitis in a Post-COVID-19 Patient Previously Treated With Corticosteroids, Antibiotics, and Tocilizumab

Estimado Director:

Una proporción significativa de los pacientes con formas moderadas o graves de la infección por SARS-CoV-2 requieren ingreso

en Unidades de Cuidados Intensivos (UCI)<sup>1,2</sup>. Los ingresos prolongados en las UCI son un factor de riesgo conocido para el desarrollo de infecciones nosocomiales por *Candida* spp.<sup>3,4</sup> Aunque no está del todo demostrado si los pacientes con COVID-19 tienen una incidencia de infecciones por *Candida* spp. mayor que otros pacientes, algunos trabajos recientes sugieren que presentan un riesgo mayor de candidemia que otras cohortes retrospectivas no-COVID-19<sup>5</sup>. Además de los factores de riesgo conocidos para el desarrollo de una candidemia en pacientes ingresados en una UCI, debe tenerse en cuenta que la frecuente combinación de fármacos inmunosupresores (corticoides), antibióticos de amplio espectro y de inhibidores del receptor de la interleucina-6 (IL-6), en pacientes