

# Scruples over Speckles

Benjamin Persons, Eugene Y. Kissin\*

Division of Rheumatology, Boston University Medical Center, Boston, MA, USA

## Abstract

The “snowstorm” sign refers to the ultrasound appearance of motile hyperechoic specks within synovial fluid and has been reported to have a high specificity for gout. We describe three additional etiologies commonly encountered in the rheumatology clinic that can produce a snowstorm: calcium pyrophosphate deposition disease, fibrin collections/rice bodies, and gas bubbles in viscous synovial fluid.

**Keywords:** Calcium pyrophosphate, gout, rice body, snowstorm

Monosodium urate (MSU) crystals deposited in the joints and soft tissues elicit the inflammatory reaction of gout, the most prevalent form of inflammatory arthritis. In addition to detecting MSU crystals on synovial aspiration, evidence for gouty arthritis can frequently be seen on radiographs and on ultrasound (US) joint imaging. US findings of gouty arthritis include the “double-contour” sign, which corresponds to the deposition of MSU crystals on the surface of hyaline cartilage, subclinical tophaceous deposits, and the “snowstorm” sign, where hyperechoic aggregates are seen as free-floating specks in synovial fluid.<sup>[1]</sup> Both recent meta-analyses and a large observational study find the snowstorm sign to have a specificity of 90% for gout.<sup>[2-4]</sup>

In the observational study done by Ogdie *et al.*, however, note is made that the snowstorm sign can be seen in calcium pyrophosphate deposition (CPPD) disease as well.<sup>[4]</sup> This in mind, we would like to report an expanded list of conditions that can produce free-floating hyperechoic specks in synovial fluid. The figure below displays US images and resultant aspirates from four patients seen in clinic over a 1-month period whose joints had a snowstorm appearance on US. Images have been obtained using a GE Logiq e device with 12 L probe set at 12 MHz. Four different etiologies as confirmed by microscopy are identified: fibrin aggregates [Figure 1a], gas bubbles [Figure 1b], calcium pyrophosphate crystals [Figure 1c], and MSU crystals [Figure 1d].

“Rice bodies” are collections of fibrin and leukocytes that are most commonly seen in rheumatoid arthritis but that have been linked to a variety of inflammatory joint conditions.<sup>[5]</sup> Befitting the name, the classic description has been of smooth, white granules that resemble rice, but intra-articular aggregates of fibrin come in a range of morphologies, some of which have previously been described as producing hyperechoic specks on US in a pattern similar to what we report.<sup>[6,7]</sup>

The development of free-floating specks has also been reported under US after joint traction, commonly referred to as “knuckle cracking,” suggesting that manipulation is one process by which the development of intra-articular gas bubbles regularly occurs.<sup>[8,9]</sup> Our experience suggests that bubbles can be seen in patients with osteoarthritis resulting in chronic effusions with very high viscosity as well.

As mentioned, CPPD is additionally known to manifest as synovial specks on ultrasound. In a meta-analysis of US findings in CPPD, 12% of descriptive terms reviewed are of intra-articular hyperechoic bodies or “spots without acoustic posterior shadowing,” which is similar to the 10% incidence of the snowstorm pattern for CPPD patients reported by Ogdie *et al.*<sup>[4,10]</sup> These relatively common causes of mobile hyperechoic specks in synovial fluid should be considered before assuming that the snowstorm sign confirms a diagnosis of gout.

**Address for correspondence:** Dr. Eugene Kissin,  
Boston University, 72 E Concord St., Evans 501, Boston, MA 02118, USA.  
E-mail: eukissin@bu.edu

Received: 19-12-2019 Revised: 11-02-2020 Accepted: 14-02-2020 Available Online: 25-05-2020

### Access this article online

#### Quick Response Code:



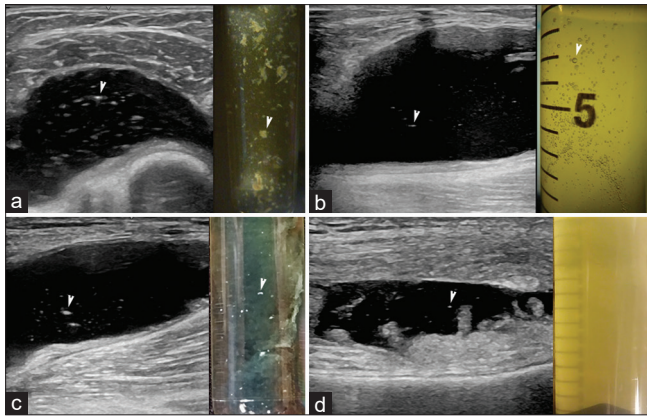
**Website:**  
www.jmuonline.org

**DOI:**  
10.4103/JMU.JMU\_122\_19

This is an open access journal, and articles are distributed under the terms of the Creative Commons Attribution-NonCommercial-ShareAlike 4.0 License, which allows others to remix, tweak, and build upon the work non-commercially, as long as appropriate credit is given and the new creations are licensed under the identical terms.

**For reprints contact:** WKHLRPMedknow\_reprints@wolterskluwer.com

**How to cite this article:** Persons B, Kissin EY. Scruples over speckles. J Med Ultrasound 2020;28:179-80.



**Figure 1:** In each panel are displayed ultrasound image and corresponding joint aspirate with arrowheads indicating representative lesions. (a) Knee effusion, lateral transverse view, containing fibrin aggregates in a rheumatoid arthritis patient. (b) Posterior longitudinal view of popliteal cyst with hyperechoic specks due to gas bubbles suspended in viscous synovial fluid. (c) Posterior longitudinal view of popliteal cyst with calcium pyrophosphate aggregates. (d) Anterior longitudinal view of knee effusion from a patient with gout and hyperechoic specks due to monosodium urate crystals

#### Financial support and sponsorship

Nil.

#### Conflicts of interest

There are no conflicts of interest.

#### REFERENCES

1. Filippucci E, Di Geso L, Grassi W. Tips and tricks to recognize microcrystalline arthritis. *Rheumatology (Oxford)* 2012;51 Suppl 7:vii18-21.
2. Lee YH, Song GG. Diagnostic accuracy of ultrasound in patients with gout: A meta-analysis. *Semin Arthritis Rheum* 2018;47:703-9.
3. Zhang Q, Gao F, Sun W, Ma J, Cheng L, Li Z. The diagnostic performance of musculoskeletal ultrasound in gout: A systematic review and meta-analysis. *PLoS One* 2018;13:e0199672.
4. Ogdie A, Taylor WJ, Neogi T, Fransen J, Jansen TL, Schumacher HR, *et al.* Performance of ultrasound in the diagnosis of gout in a multicenter study: Comparison with monosodium urate monohydrate crystal analysis as the gold standard. *Arthritis Rheumatol* 2017;69:429-38.
5. Forse CL, Mucha BL, Santos ML, Ongcapin EH. Rice body formation without rheumatic disease or tuberculosis infection: A case report and literature review. *Clin Rheumatol* 2012;31:1753-6.
6. Popert AJ, Scott DL, Wainwright AC, Walton KW, Williamson N, Chapman JH. Frequency of occurrence, mode of development, and significance of rice bodies in rheumatoid joints. *Ann Rheum Dis* 1982;41:109-17.
7. Spence LD, Adams J, Gibbons D, Mason MD, Eustace S. Rice body formation in bicipital-radial bursitis: Ultrasound, CT, and MRI findings. *Skeletal Radiol* 1998;27:30-2.
8. Jones AR, Yelverton CJ, Bester C. Ultrasound imaging of the trapeziometacarpal articular cavity to investigate the presence of intraarticular gas bubbles after chiropractic manipulation. *J Manipulative Physiol Ther* 2014;37:476-84.
9. Malghem J, Omoumi P, Lecouvet FE, Vande Berg BC. Presumed intraarticular gas microbubbles resulting from a vacuum phenomenon: Visualization with ultrasonography as hyperechoic microfoci. *Skeletal Radiol* 2011;40:1287-93.
10. Filippou G, Adinolfi A, Iagnocco A, Filippucci E, Cimmino MA, Bertoldi I, *et al.* Ultrasound in the diagnosis of calcium pyrophosphate dihydrate deposition disease. A systematic literature review and a meta-analysis. *Osteoarthritis Cartilage* 2016;24:973-81.