

# Serratus anterior plane block versus intercostal nerve block for postoperative analgesic effect after video-assisted thoracoscopic lobectomy

## A randomized prospective study

Jungwon Lee, MD<sup>a</sup> , Deok Heon Lee, MD, PhD<sup>b</sup> , Saeyoung Kim, MD, PhD<sup>b,\*</sup> 

### Abstract

**Background:** Serratus anterior plane block (SAPB) and intercostal nerve block (ICNB) are attractive options for multimodal analgesia in patients undergoing thoracoscopic surgery, but which block is superior remains unclear.

**Objective:** The present study aimed to assess the effect of SAPB versus ICNB on reducing postoperative pain after video-assisted thoracoscopic surgery (VATS) for lobectomy.

**Methods:** This prospective, randomized, active-intervention-controlled, subject-assessor-blinded, single-center, parallel-group trial allocated 18- to 80-year-old patients with American Society of Anesthesiologists status I to III to receive either SAPB or ICNB in a 1:1 ratio. The primary outcome was numerical pain rating scale (NRS) scores during the first 24 hours postoperatively. The secondary outcomes were postoperative cumulative doses of ketorolac and fentanyl, and the occurrence of postoperative adverse effects.

**Results:** Among the 57 patients assessed for eligibility, 50 were randomly assigned in a 1:1 ratio. Due to conversion to open thoracotomy and patient-controlled analgesia pump failure, 4 patients were excluded and 46 were analyzed. The intergroup differences in NRS scores were not statistically significant at any time point. Cumulative consumptions of fentanyl and ketorolac were also not significantly different. No perioperative adverse events occurred. Postoperative complications were also absent, except for nausea (2/23 patients [8.7% in both groups]).

**Conclusion:** Results of the present study do not clarify whether SAPB or ICNB has a superior effect on reducing pain after VATS, thereby suggesting they may exert similar analgesic effects.

**Abbreviations:** ASA = American Society of Anesthesiologists, ICNB = intercostal nerve block, ICS = intercostal space, IQR = interquartile range, NRS = numeric pain rating scale, PACU = postanesthesia care unit, PCA = patient-controlled analgesia, POD = postoperative day, SAPB = serratus anterior plane block, SD = standard deviation, VATS = video-assisted thoracoscopic surgery.

**Keywords:** intercostal nerves, nerve block, postoperative pain, regional anesthesia, video-assisted thoracoscopic surgery

Editor: Somchai Amornyoitin.

The authors have no funding and conflicts of interest to disclose.

The datasets generated during and/or analyzed during the current study are available from the corresponding author on reasonable request.

<sup>a</sup> Department of Anesthesiology and Pain Medicine, Yeungnam University College of Medicine, <sup>b</sup> Department of Anesthesiology and Pain Medicine, School of Medicine, Kyungpook National University, Daegu, Republic of Korea.

\* Correspondence: Saeyoung Kim, Department of Anaesthesiology and Pain Medicine, School of Medicine, Kyungpook National University, 130, Dongdeok-ro, Jung-gu, Daegu 41944, Republic of Korea (e-mail: saeyoungkim7@gmail.com).

Copyright © 2020 the Author(s). Published by Wolters Kluwer Health, Inc. This is an open access article distributed under the terms of the Creative Commons Attribution-Non Commercial License 4.0 (CCBY-NC), where it is permissible to download, share, remix, transform, and buildup the work provided it is properly cited. The work cannot be used commercially without permission from the journal.

How to cite this article: Lee J, Lee DH, Kim S. Serratus anterior plane block versus intercostal nerve block for postoperative analgesic effect after video-assisted thoracoscopic lobectomy: A randomized prospective study. *Medicine* 2020;99:49(e22102).

Received: 3 March 2020 / Received in final form: 6 July 2020 / Accepted: 6 August 2020

<http://dx.doi.org/10.1097/MD.00000000000022102>

## 1. Introduction

Thoracoscopic surgery can reduce postoperative pain associated with thoracic surgeries. However, pain remains a major concern for patients undergoing video-assisted thoracoscopic surgery (VATS).<sup>[1–3]</sup> Regional analgesic techniques are considered an important part of multimodal analgesia. They can alleviate pain more effectively than systemic opioids alone and can decrease opioid consumption, which contributes to reducing opioid-related adverse effects.<sup>[4,5]</sup>

Serratus anterior plane block (SAPB) and intercostal nerve block (ICNB) are used in multimodal analgesia after VATS. Compared with epidural or paravertebral block, these blocks have the common advantages of being safe and easy to perform. Several studies have reported the effectiveness of SAPB and ICNB in pain management after VATS.<sup>[6–10]</sup>

However, to our knowledge, no study has compared the analgesic effect of SAPB and ICNB. Accordingly, we aimed to compare the efficacy of SAPB and ICNB in reducing postoperative pain as well as the differences in analgesic consumption between the 2 procedures in patients undergoing VATS lobectomy.

## 2. Methods

This prospective, randomized, active-intervention-controlled, subject-assessor-blinded, single-center, parallel-group trial allocated patients at a ratio of 1:1. The study was approved by the Hospital Ethics Committee (2019-07-008-002) and was registered in ClinicalTrials.gov (NCT04250272). This study was performed at Kyungpook National University Hospital, a tertiary referral center in Daegu, Korea, and written informed consent was obtained from all patients. Patients 18 to 80 years of age with lung cancer categorized as American Society of Anesthesiologists class I to III and scheduled to undergo VATS lobectomy were included. Individuals with a history of allergy to local anesthetics, psychological disorders, chronic analgesic or sedative use, coagulopathy, presence of systemic infection or local infection at the injection site, and pregnancy were excluded.

Patients were allocated to receive either SAPB or ICNB in a 1:1 ratio via computer-generated block randomization using block sizes of 2, 4, and 6. Sequentially numbered, opaque, sealed envelopes were used to conceal the allocation sequence, and were prepared by an assistant not otherwise involved in this study. A sequential envelope was opened after anesthesia induction by a nurse who was not involved in the study.

Standard monitoring (electrocardiography, noninvasive blood pressure measurement, pulse oximetry, and bispectral index) was applied to all patients on arrival to the operating room. Preoxygenation with 100% oxygen was performed. After administering propofol (2 mg/kg), remifentanyl (0.3–1.0  $\mu\text{g}/\text{kg}/\text{min}$ ), and rocuronium (0.8 mg/kg) for induction, patients were intubated using a double-lumen tube and a radial artery was cannulated. During surgery, anesthesia was maintained by adjusting propofol infusion to maintain a bispectral index of 40 to 60 and by adjusting remifentanyl infusion to maintain blood pressure and heart rate within 80% to 120% of the preoperative baseline values. Rocuronium (0.2 mg/kg) was administered every 30 minutes.

All VATS lobectomies were performed using a conventional 3-port technique by a single surgeon. Two incisions approximately 1 to 1.5 cm in length were made at the seventh intercostal space (ICS) on the anterior axillary line and the eighth ICS on the posterior axillary line. A 4 to 5 cm incision was made at the fourth ICS on the midaxillary line without rib spreading. At the end of surgery, a 28 Fr chest tube was placed in the lowest access.

Ultrasound-guided superficial SAPBs were performed with the patients in the lateral decubitus position after anesthesia induction before the start of surgery by a single anesthesiologist. A high-frequency linear transducer (6–15 MHz; HFL50x, Sonosite M-Turbo, Sonosite, Bothell, WA, USA) was used. Before skin disinfection, an ultrasound prescan was performed to localize the injection site, which was the plane between the serratus anterior muscle and the latissimus dorsi muscle at the fifth rib level on the midaxillary line. The fifth rib was identified using ultrasound by counting the ribs in a row from the twelfth rib onward. After sterilizing the injection site, a 22-gauge Tuohy needle was placed in the prescanned plane using an in-plane technique. The needle tip position was confirmed using the hydrodissection technique by separating the serratus anterior fascia from the latissimus dorsi fascia. Thereafter, 20 mL of 0.375% ropivacaine was injected to spread along the plane.

Thoracoscopic-assisted ICNBs were performed at all port sites at the end of the surgery and before inserting the chest tube and suturing the surgical wound. Under direct observation of the

affected inside the chest wall with thoracoscopic assistance, a 22-gauge needle was introduced beneath the intercostal muscle and above the parietal pleura in the vicinity of the intercostal bundle. Successful injection was confirmed via a resultant bulge in the parietal pleura. A total of 20 mL of 0.375% ropivacaine was delivered evenly at the anterior and posterior ICSs from all port sites.

After the completion of the surgery, patients in both groups received intravenous patient-controlled analgesia (PCA) devices (Accumate 1100, WooYoung Medical, Seoul, Korea) on arrival at the post-anesthesia care unit (PACU). The PCA regimen consisted of fentanyl 20  $\mu\text{g}/\text{mL}$  mixed with normal saline to a total volume of 100 mL. The device was set to a bolus dose of 20  $\mu\text{g}$  at a basal infusion rate of 0.2  $\mu\text{g}/\text{kg}/\text{h}$  with a lockout time of 15 minutes. If a patient required additional analgesics postoperatively, ketorolac 30 mg was administered intravenously for those with a numerical pain rating scale (NRS) score of 4 or 5 (0 indicating no pain and 10 signifying the worst pain imaginable) and fentanyl 50  $\mu\text{g}$  was administered intravenously for those with an NRS score  $\geq 6$ .

The primary outcome was NRS score at each time point during the first 24 hours postoperatively. NRS scores were recorded at 2, 6, 12, and 24 hours postoperatively. The secondary outcomes were the cumulative doses of ketorolac and fentanyl at 2, 4, 6, 12, 24, 36, and 48 hours postoperatively. The fentanyl dose was calculated as the sum of the basal infusion and bolus doses administered via PCA and the rescue dose. The occurrence of postoperative adverse effects, including nausea, vomiting, dizziness, and respiratory depression, during the 48 hours as well as the number of postoperative days until chest tube removal, were also recorded.

Both blocks were performed when the patients were under general anesthesia. At the end of surgery, needle wounds in patients receiving SAPB were covered with port site dressings because needle insertion points were very close to the port insertion sites (fourth ICS on the midaxillary line). Dressing sizes were identical between the groups. Therefore, the patients, ward medical staff who provided postoperative care, and a research nurse who recorded the evaluation parameters were blinded to the allocation of the block technique.

The sample size for the present investigation was calculated based on findings from a pilot study performed on 5 patients. The mean and standard deviation (SD) of the NRS score at 6 hours after VATS lobectomy in patients receiving thoracoscopic-assisted ICNB was 4.0 and 2.0, respectively. We considered a reduction of the NRS score by 2 as a clinically significant change. The estimated sample size required in each group was 22 patients, with an alpha of 0.05 and power of 0.9. Projecting a 10% dropout rate, 25 patients were included in each group.

Statistical analysis was performed using SPSS version 20.0 (IBM Corporation, Armonk, NY, USA) for Windows (Microsoft Corporation, Redmond, WA, USA). Normality of continuous variables was assessed using the Shapiro-Wilk test. Normally distributed continuous data were analyzed using the independent *t*-test; these data are expressed as mean  $\pm$  SD. Non-normally distributed continuous data were analyzed using the Mann-Whitney *U* test and are expressed as median (interquartile range [IQR]). Mean or median differences for the primary and secondary outcomes are reported with corresponding 95% confidence intervals. The median differences were calculated using the Hodges-Lehmann estimator. Categorical variables were analyzed using Fisher's exact test. Differences with a two-tailed  $P < .05$  were considered statistically significant.

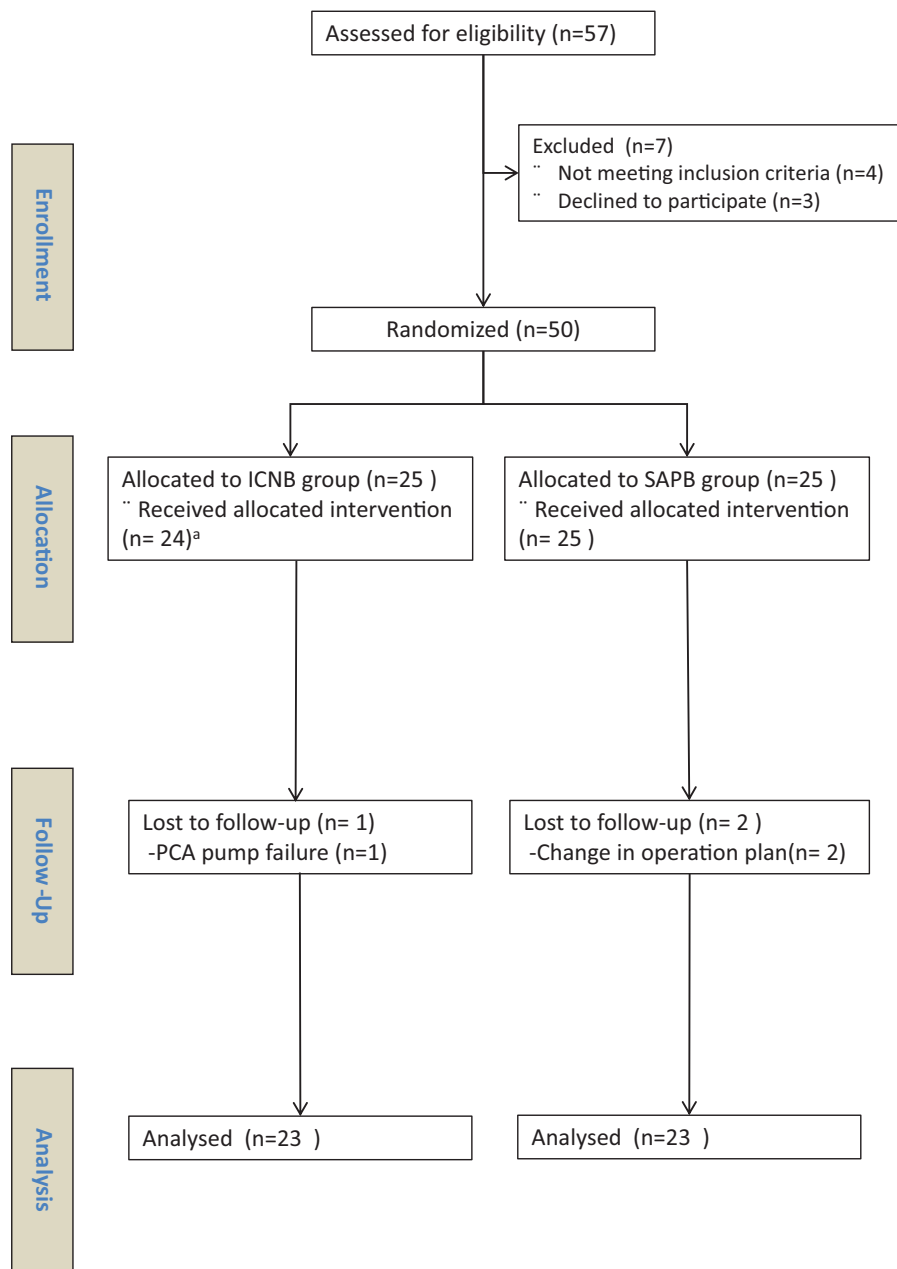
### 3. Results

Patients were prospectively enrolled between August 2019 and January 2020. Of the 57 patients assessed for eligibility, 7 were excluded: 4 had a history of chronic analgesic use; and 3 refused to participate. The remaining 50 patients were randomized in a 1:1 allocation ratio. After allocation, 1 patient in the ICNB group did not receive the block because the operation was converted to open thoracotomy. During both procedures, no adverse events occurred. In addition, 2 patients in the SAPB group (conversion to open thoracotomy) and 1 in the ICNB group (PCA pump failure) were excluded from the analyses. Thus, 46 patients were ultimately analyzed at an allocation ratio of 1:1 (Fig. 1).

The patients exhibited no significant differences in baseline features except for intraoperative remifentanyl consumption (Table 1). Intraoperative remifentanyl consumption was significantly lower in the SAPB group (median 500 [IQR 314–734]) than in the ICNB group (median 910 [IQR 761–1293]) ( $P < .001$ ).

Differences in NRS scores between the ICNB and SAPB groups were not statistically significant at any time point during the first 24 hours postoperatively (Table 2).

Cumulative consumptions of fentanyl and ketorolac were also not significantly different between the groups at 2, 4, 6, 12, 24, 36, and 48 hours postoperatively (Tables 3 and 4). The incidence of postoperative nausea was identical in both groups (2/23 patients [8.7% in each group]), and vomiting, dizziness, and



**Figure 1.** Flow diagram of the study design. ICNB = intercostal nerve block, SAPB = serratus anterior plane block. <sup>a</sup>One patient in the ICNB group did not receive the intervention because the surgery was converted to open thoracotomy.

**Table 1****Demographics of the study patients and perioperative data.**

	ICNB group (N=23)	SAPB group (N=23)	P value
ASA class (I/II/III)	2/19/2	1/21/1	.70
Sex (male/female)	16/7	12/11	.37
Age (yr, median, IQR)	67 (58–74)	68 (57–75)	.78
Height (cm, mean, SD)	163.6 (8.5)	159.3 (10.2)	.12
Weight (kg, median, IQR)	65.0 (57.9–69.4)	63.0 (53.0–72.0)	.82
Intraoperative propofol (mg, median, IQR)	1394 (1080–1668)	1264 (985–1412)	.33
Intraoperative remifentanyl ( $\mu$ g, median, IQR)	910 (761–1293)	500.0 (314–734)	<.001
Anesthesia time (min, median, IQR)	176 (160–207)	167 (144–206)	.53
Operation time (min, median, IQR)	135 (115–173)	123 (100–150)	.22
Use of rescue drugs for hypotension (number, %)	9 (39.1%)	12 (52.2%)	.55

ASA=American Society of Anesthesiologists, ICNB=intercostal nerve block, IQR=interquartile range, SAPB=serratus anterior plane block, SD=standard deviation.

**Table 2****Postoperative pain scores (numeric rating scale score).**

Time after surgery	ICNB group (N=23)	SAPB group (N=23)	P value	Median difference (95% CI)
At 2 h	4 (3–5)	4 (4–6)	.71	0 (–1 to 1)
At 6 h	3 (2–4)	3 (2–4)	.70	0 (–1 to 0)
At 12 h	2 (2–3)	2 (2–3)	.70	0 (0–0)
At 24 h	2 (2–2)	2 (2–2)	.72	0 (0–0)

Data are presented as median (interquartile range).

CI=confidence interval, ICNB=intercostal nerve block, SAPB=serratus anterior plane block.

respiratory depression did not occur postoperatively. The median number of postoperative days until chest tube removal was identical in both groups (1 [IQR 1–1]) ( $P=.77$ ).

**4. Discussion**

The present study compared the efficacy of SAPB with ICNB in patients undergoing VATS lobectomy. No significant differences

were observed between the 2 groups in postoperative NRS scores at each time point during the first 24 hours. Similarly, no clinically significant differences were observed between the groups in the secondary outcome measures of the cumulative consumptions of fentanyl and ketorolac during the 48 hours postoperative period.

Although VATS is less invasive than thoracotomy approach, postoperative pain after VATS is still considered to be moderate to severe.<sup>[11,12]</sup> Inadequate analgesia in VATS may lead to

**Table 3****Postoperative cumulative doses of fentanyl consumption.**

Time after surgery	ICNB group (N=23)	SAPB group (N=23)	P value	Mean difference (95% CI)
At 2 h	117.39 $\pm$ 48.10	143.30 $\pm$ 60.06	.11	–25.91 (–58.25 to 6.42)
At 4 h	168.52 $\pm$ 65.04	197.04 $\pm$ 72.40	.17	–28.52 (–69.42 to 12.37)
At 6 h	213.09 $\pm$ 81.59	241.22 $\pm$ 87.25	.26	–28.13 (–78.33 to 22.07)
At 12 h	322.39 $\pm$ 114.91	347.22 $\pm$ 100.60	.44	–24.83 (–89.01 to 39.35)
At 24 h	548.91 $\pm$ 154.29	564.39 $\pm$ 149.60	.73	–15.48 (–105.79 to 74.83)
At 36 h	710.13 $\pm$ 217.89	693.04 $\pm$ 201.15	.78	17.09 (–107.53 to 141.70)
At 48 h	830.87 $\pm$ 314.56	793.74 $\pm$ 275.71	.67	37.13 (–138.65 to 212.91)

Data are presented as mean $\pm$ standard deviation ( $\mu$ g).

CI=confidence interval, ICNB=intercostal nerve block, SAPB=serratus anterior plane block.

**Table 4****Postoperative cumulative doses of ketorolac consumption.**

Time after surgery	ICNB group (N=23)	SAPB group (N=23)	P value	Median difference (95% CI)
At 2 h	0 (0–30)	30 (0–30)	.17	0 (–30 to 0)
At 4 h	0 (0–30)	30 (0–30)	.21	0 (–30 to 0)
At 6 h	30 (0–30)	30 (0–30)	.78	0 (0–0)
At 12 h	30 (0–30)	30 (0–30)	.84	0 (–30 to 0)
At 24 h	30 (0–60)	30 (0–60)	.79	0 (–30 to 30)
At 36 h	30 (0–60)	30 (0–60)	.73	0 (–30 to 30)
At 48 h	30 (0–60)	30 (30–90)	.48	0 (–30 to 0)

Data are presented as median (interquartile range).

CI=confidence interval, ICNB=intercostal nerve block, SAPB=serratus anterior plane block.

respiratory and cardiovascular complications secondary to ineffective cough, poor removal of secretions, hypercarbia, hypoxemia, and increased myocardial work, as well as patient discomfort.<sup>[13]</sup> Uncontrolled pain also has the potential to develop into post-thoracotomy pain syndrome.<sup>[14]</sup> Therefore, appropriate multimodal analgesia should be provided to patients undergoing VATS for reducing pain-related complications and accelerating recovery.<sup>[15]</sup>

Ultrasound-guided SAPB is a relatively novel technique of regional analgesia for thoracic pain.<sup>[16]</sup> SAPB is safe and easy to perform because the fifth rib acts as a barrier to the lung and the target injection site is superficial and well visualized on ultrasound. SAPB is performed at the fascial plane either superficial or deep to the serratus anterior muscle. Several studies have reported the effectiveness of SAPB in reducing postoperative pain after VATS.<sup>[6,7,17,18]</sup> In 2018, a randomized trial reported that SAPB can reduce opioid consumption after VATS segmentectomy or lobectomy.<sup>[6]</sup> In 2019, a retrospective study reported that SAPB was noninferior to paravertebral block in terms of pain score and opioid consumption.<sup>[18]</sup> Another randomized study demonstrated that SAPB had advantages over local infiltration techniques in terms of pain scores after thoracoscopic surgery.<sup>[17]</sup> As such, SAPB is becoming an attractive choice for regional analgesic intervention for post-VATS pain.

ICNB is a well-known technique for pain management after thoracic surgery.<sup>[3,9,15,19-21]</sup> In a randomized trial, ICNB reduced postoperative pain scores in patients undergoing VATS.<sup>[10]</sup> A review article described ICNB as superior to systemic analgesia and placebo in terms of pain severity.<sup>[22]</sup> Various approaches of ICNB for postoperative pain management in thoracic surgery are available, including transcutaneous injection, transparietal pleural injection from within the pleural cavity,<sup>[21]</sup> and direct injection through the ICS through the port incision.<sup>[8]</sup> The latter 2 approaches are performed by thoracic surgeons during the surgery. Before the introduction of SAPB, our center routinely used ICNB for the management of post-VATS pain via direct injection through the port incision.

Both SAPB and ICNB are alternative options to more invasive blocks such as epidural and paravertebral blocks because they are safe, easy to perform, and easy to learn, and do not affect patient hemodynamics. Hence, we aimed to evaluate which block was superior at reducing postoperative pain scores.

Multimodal analgesia, which is a key component of enhanced recovery after surgery, can be achieved using a combination of nonopioid agents, opioids, and regional analgesic techniques.<sup>[23]</sup> In this study, we designed a multimodal analgesic regimen with SAPB or ICNB, fentanyl, and ketorolac. A PCA system was used for fentanyl administration, which contributes to decreased opioid-related complications and patient convenience through individualization of opioid consumption.<sup>[24]</sup> Cumulative doses of total fentanyl through a PCA device and rescue administration and ketorolac demonstrated no significant differences. Because NRS scores were not significantly different based on similar consumption of systemic analgesics, the 2 blocks may have similar analgesic efficacy after VATS lobectomy.

Although the present study did not demonstrate significant differences between the 2 blocks, the result is plausible. The major factors that affect postoperative pain after VATS include skin incision, muscle splitting, parietal pleural injury, and chest tube stimulation.<sup>[3,17]</sup> ICNB and SAPB have different coverages against these components. The intercostal muscles and costal parietal pleura are innervated by the intercostal nerves, and the

skin is innervated by the lateral cutaneous branches of the intercostal nerves.<sup>[3]</sup> ICNB covers these pain components. Chest tubes irritate not only the pleura, but also the serratus anterior muscle. Stimulation of this muscle causes contractions and spasms, which contribute to post-VATS pain.<sup>[17]</sup> Direct injury to the serratus anterior muscle during surgery also causes postoperative pain. Long thoracic nerve block has been reported to reduce post-VATS pain by relaxing the serratus anterior muscle.<sup>[25]</sup> Superficial SAPB, which we performed in this study, blocks the long thoracic nerve that lies on the superficial plane of the serratus anterior muscle as well as the lateral cutaneous branches of the intercostal nerves.<sup>[26]</sup> However, SAPB has no effect on pleural pain. Therefore, the sum of the effects of each of these blocks on pain components may not be clinically different from one another.

During the surgery, intraoperative remifentanyl consumption was significantly lower in the SAPB group than in the ICNB group (median 500 [IQR 314–734] vs 910 [IQR 761–1293];  $P < .01$ ). This was consistent with the result of our previous study investigating the effect of SAPB on intraoperative opioid consumption.<sup>[27]</sup> Pre-incisional regional analgesia in the SAPB group blocked the nociceptive afferent transmission of surgical stimulation and reduced opioid requirement, while ICNB was performed at the end of surgery.

This study, however, had several limitations, the first of which was that we did not assess the success of the blocks by using sensory checks. However, we performed the procedures under ultrasound or thoracoscopic guidance and visually confirmed appropriate spread of the injectates. Second, the timing of procedure application was different between the 2 groups. SAPB was performed before incision, while ICNB was performed at the end of surgery. Preventive analgesic effect or difference in intraoperative remifentanyl consumption may have a potential to affect postoperative pain. Finally, this study was conducted at a single institution and both blocks were performed by a single operator. These factors contributed to consistency in the procedure and assessment of the data. However, a multicenter study including a different population to assess the generalizability of these results is warranted.

In conclusion, we cannot conclude whether SAPB or ICNB has a superior effect in reducing pain after VATS. The degree of analgesic effect may be similar between the 2 blocks. Further studies using equivalence tests are needed based on our results.

## Author contributions

**Conceptualization:** Saeyoung Kim, Jungwon Lee.

**Data curation:** Deok Heon Lee, Jungwon Lee.

**Formal analysis:** Jungwon Lee.

**Investigation:** Saeyoung Kim, Deok Heon Lee, Jungwon Lee.

**Methodology:** Saeyoung Kim, Deok Heon Lee.

**Supervision:** Saeyoung Kim.

**Writing – original draft:** Jungwon Lee.

**Writing – review & editing:** Saeyoung Kim.

## References

- [1] Bendixen M, Jørgensen OD, Kronborg C, et al. Postoperative pain and quality of life after lobectomy via video-assisted thoracoscopic surgery or anterolateral thoracotomy for early stage lung cancer: a randomised controlled trial. *Lancet Oncol* 2016;17:836–44.
- [2] Kaplowitz J, Papadakos PJ. Acute pain management for video-assisted thoracoscopic surgery: an update. *J Cardiothorac Vasc Anesth* 2012;26:312–21.



- [3] Elmore B, Nguyen V, Blank R, et al. Pain management following thoracic surgery. *Thorac Surg Clin* 2015;25:393–409.
- [4] Crumley S, Schraag S. The role of local anaesthetic techniques in ERAS protocols for thoracic surgery. *J Thorac Dis* 2018;10:1998–2004.
- [5] Kumar K, Kirksey MA, Duong S, et al. A review of opioid-sparing modalities in perioperative pain management: methods to decrease opioid use postoperatively. *Anesth Analg* 2017;125:1749–60.
- [6] Park MH, Kim JA, Ahn HJ, et al. A randomised trial of serratus anterior plane block for analgesia after thoracoscopic surgery. *Anaesthesia* 2018;73:1260–4.
- [7] Ökmen K, Metin Ökmen B. Evaluation of the effect of serratus anterior plane block for pain treatment after video-assisted thoracoscopic surgery. *Anaesth Crit Care Pain Med* 2018;37:349–53.
- [8] Temes RT, Won RS, Kessler RM, et al. Thoracoscopic intercostal nerve blocks. *Ann Thorac Surg* 1995;59:787–8.
- [9] Wurnig PN, Lackner H, Teiner C, et al. Is intercostal block for pain management in thoracic surgery more successful than epidural anaesthesia? *Eur J Cardio-Thorac Surg* 2002;21:1115–9.
- [10] Bolotin G, Lazarovici H, Uretzky G, et al. The efficacy of intraoperative internal intercostal nerve block during video-assisted thoracic surgery on postoperative pain. *Ann Thorac Surg* 2000;70:1872–5.
- [11] Steinhorsdottir KJ, Wildgaard L, Hansen HJ, et al. Regional analgesia for video-assisted thoracic surgery: a systematic review. *Eur J Cardiothorac Surg* 2014;45:959–66.
- [12] Khoshbin E, Al-Jilaihawi AN, Scott NB, et al. An audit of pain control pathways following video-assisted thoracoscopic surgery. *Innovations* 2011;6:248–52.
- [13] Batchelor TJP, Rasburn NJ, Abdelnour-Berchtold E, et al. Guidelines for enhanced recovery after lung surgery: recommendations of the Enhanced Recovery After Surgery (ERAS) Society and the European Society of Thoracic Surgeons (ESTS). *Eur J Cardio-Thorac Surg* 2019;55:91–115.
- [14] Bong CL, Samuel M, Ng JM, et al. Effects of preemptive epidural analgesia on post-thoracotomy pain. *J Cardiothorac Vasc Anesth* 2005;19:786–93.
- [15] Piccioni F, Segat M, Falini S, et al. Enhanced recovery pathways in thoracic surgery from Italian VATS Group: perioperative analgesia protocols. *J Thorac Dis* 2018;10(Suppl 4):S555–63.
- [16] Blanco R, Parras T, McDonnell JG, et al. Serratus plane block: a novel ultrasound-guided thoracic wall nerve block. *Anaesthesia* 2013;68:1107–13.
- [17] Chen G, Li Y, Zhang Y, et al. Effects of serratus anterior plane block for postoperative analgesia after thoracoscopic surgery compared with local anesthetic infiltration: a randomized clinical trial. *J Pain Res* 2019;12:2411–7.
- [18] Wang L, Wang Y, Zhang X, et al. Serratus anterior plane block or thoracic paravertebral block for postoperative pain treatment after uniportal video-assisted thoracoscopic surgery: a retrospective propensity-matched study. *J Pain Res* 2019;12:2231–8.
- [19] Detterbeck FC. Efficacy of methods of intercostal nerve blockade for pain relief after thoracotomy. *Ann Thorac Surg* 2005;80:1550–9.
- [20] Khalil KG, Boutrous ML, Irani AD, et al. Operative intercostal nerve blocks with long-acting bupivacaine liposome for pain control after thoracotomy. *Ann Thorac Surg* 2015;100:2013–8.
- [21] Alzahrani T. Pain relief following thoracic surgical procedures: a literature review of the uncommon techniques. *Saudi J Anaesth* 2017;11:327–31.
- [22] Joshi GP, Bonnet F, Shah R, et al. A systematic review of randomized trials evaluating regional techniques for postthoracotomy analgesia. *Anesth Analg* 2008;107:1026–40.
- [23] Wick EC, Grant MC, Wu CL. Postoperative multimodal analgesia pain management with nonopioid analgesics and techniques: a review. *JAMA Surg* 2017;152:691–7.
- [24] Macintyre PE. Safety and efficacy of patient-controlled analgesia. *Br J Anaesth* 2001;87:36–46.
- [25] Kwon WK, Choi JW, Kang JE, et al. Long thoracic nerve block in video-assisted thoracoscopic wedge resection for pneumothorax. *Anaesth Intensive Care* 2012;40:773–9.
- [26] Mayes J, Davison E, Panahi P, et al. An anatomical evaluation of the serratus anterior plane block. *Anaesthesia* 2016;71:1064–9.
- [27] Lee J, Kim S. The effects of ultrasound-guided serratus plane block, in combination with general anesthesia, on intraoperative opioid consumption, emergence time, and hemodynamic stability during video-assisted thoracoscopic lobectomy: a randomized prospective study. *Medicine (Baltimore)* 2019;98:e15385.