

[ CASE REPORT ]

## Pneumothorax in a COVID-19 Pneumonia Patient without Underlying Risk Factors

Takafumi Yamaya, Tomohisa Baba, Eri Hagiwara, Satoshi Ikeda, Takashi Niwa, Takaaki Kitayama, Kota Murohashi, Katsuyuki Higa, Yozo Sato and Takashi Ogura

### Abstract:

Coronavirus disease 2019 (COVID-19) has been recognized as a worldwide pandemic. However, the clinical course of COVID-19 remains poorly characterized. Although some cases of pneumothorax have been reported, they all had pulmonary complications or were managed with mechanical ventilation. We herein report a case of pneumothorax that developed even though the patient had no pulmonary underlying diseases and had never been managed with mechanical ventilation. In the present case, a lung bulla was found on chest computed tomography during treatment for COVID-19. We concluded that COVID-19 affected the formation of the lung bulla and induced the complication of pneumothorax.

**Key words:** bulla, corticosteroids, COVID-19 pneumonia, organizing pneumonia, pneumothorax, severe acute respiratory syndrome coronavirus 2

(Intern Med 59: 2921-2925, 2020)

(DOI: 10.2169/internalmedicine.5731-20)

### Introduction

Coronavirus disease 2019 (COVID-19) has been identified as a worldwide pandemic. Severe acute respiratory dysfunction often occurs in patients with COVID-19. However, the clinical course in COVID-19 patients has not been fully documented, most notably in the later stages of the disease.

Several complications have been reported among COVID-19 patients. For example, one report showed that pneumothorax developed in 1% of COVID-19 patients (1). Another report suggested that two cases of pneumothorax may have developed due to mechanical ventilation with high positive end-expiratory pressure (PEEP) causing the rupture of pre-existing blebs (2). Another report described a case of pneumothorax in a 62-year-old patient diagnosed with COVID-19 who had no smoking history or any associated underlying medical conditions, including chronic obstructive pulmonary disease (3). However, whether or not pneumothorax can occur in COVID-19 patients who have no underlying risk factors, such as the presence of pulmonary diseases or treatment using mechanical ventilation, has been unclear.

We herein report a case of pneumothorax that developed

in association with COVID-19 pneumonia. The patient had no smoking history and no underlying pulmonary disease before the development of COVID-19 pneumonia and had not received mechanical ventilation during the treatment of the pneumonia.

### Case Report

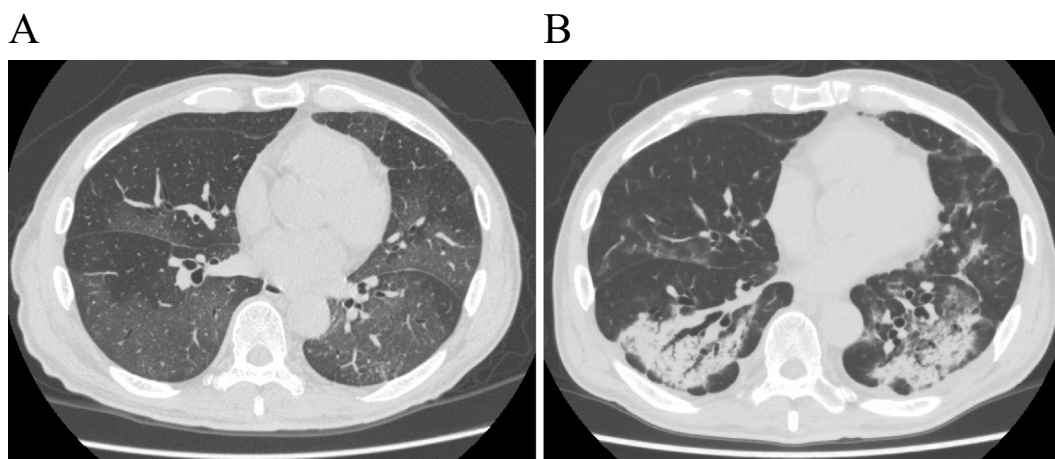
A 77-year-old man presented with a chief complaint of a fever lasting 4 days and was admitted to our hospital for the evaluation and treatment. He was confirmed positive for severe acute respiratory syndrome coronavirus 2 (SARS-CoV-2) by reverse transcription-polymerase chain reaction prior to admission and was diagnosed with COVID-19 pneumonia. The patient had no smoking history and no pulmonary comorbidities, including chronic obstructive pulmonary disease or interstitial pneumonia.

His height was 171.4 cm, and his body weight was 60.3 kg. At admission, his vital signs included a body temperature of 38.8 °C, blood pressure of 93/61 mmHg, heart rate of 88 beats per minute, respiratory rate of 22 breaths per minute (bpm), and percutaneous oxygen saturation (SpO<sub>2</sub>) of 97% while receiving supplemental oxygen (3 L/min). Pe-

**Table. Laboratory Examination Findings on Admission.**

Hematology		Blood chemistry		Serological test	
WBC	8,470 (/μL)	TP	6.7 (g/dL)	CRP	5.93 (mg/dL)
Seg	91.7 (%)	T-bil	1.4 (mg/dL)	KL-6	380 (U/mL)
Eos	0 (%)	AST	73 (IU/L)	Hb-A1c (NGSP)	7.6 (%)
Baso	0.2 (%)	ALT	35 (IU/L)	GLU	208 (mg/dL)
Mono	2.8 (%)	LDH	682 (IU/L)	BNP	29.3 (pg/mL)
Lymph	5.3 (%)	CK	638 (IU/L)	Arterial blood gas analysis	
RBC	543×10 <sup>5</sup> (/μL)	BUN	46.1 (mg/dL)	pH	7.485 (%)
Hb	16.0 (g/dL)	Cre	1.05 (mg/dL)	pCO <sub>2</sub>	30.5 (mmHg)
Hct	46.7 (%)	Na	138 (mEq/L)	pO <sub>2</sub>	70.6 (mmHg)
Plt	14.3×10 <sup>5</sup> (/μL)	K	4.1 (mEq/L)	Lac	2.0 (mmol/L)
		Cl	101(mEq/L)	HCO <sub>3</sub> <sup>-</sup>	22.7 (mmol/L)

WBC: white blood cell, Seg: segmented leukocyte, Eos: eosinophil, Baso: basophil, Mono: monocyte, Lymph: lymphocyte, RBC: red blood cell, Hb: hemoglobin, Hct: hematocrit, Plt: platelet, TP: total protein, T-bil: total bilirubin, AST: aspartate aminotransferase, ALT: alanine aminotransferase, LDH: lactate dehydrogenase, CK: creatine kinase, BUN: blood urea nitrogen, Cre: creatinin, CRP: C-reactive protein, KL-6: Krebs von den Lungen-6, Hb-A1c: hemoglobin A1c, NGSP: Glycohemoglobin Standardization Program, GLU: glucose, BNP: brain natriuretic peptide, pH: potential of hydrogen, Lac: lactate

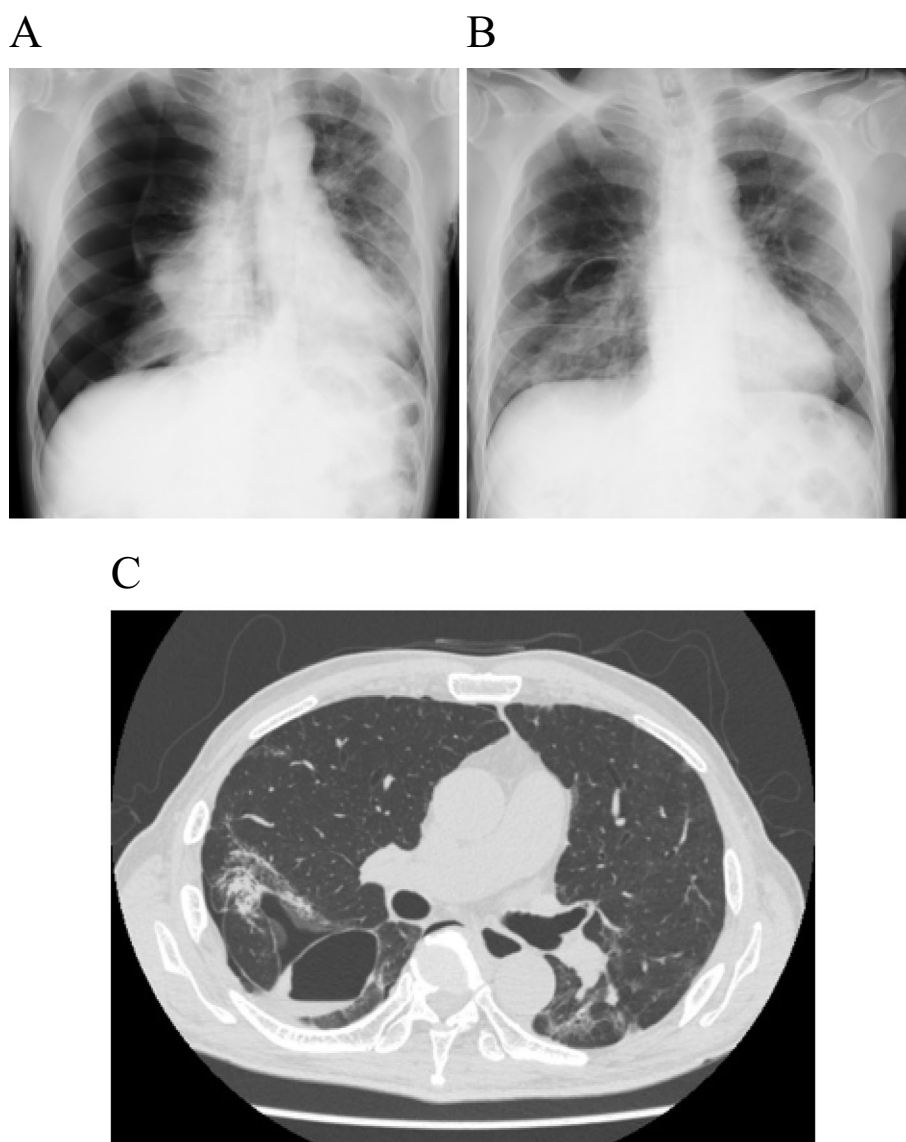


**Figure 1.** Chest computed tomography (CT) performed at the time of admission revealing diffuse, bilateral ground-glass opacities (A). Chest CT performed on day 19 was notable for the expansion of the consolidation and bilateral bronchiectasis in the lower lobes (B).

ripheral blood and serum tests revealed elevated levels of C-reactive protein and lactate dehydrogenase (Table). Overall, his condition included mild to severe inflammation and respiratory failure. Chest computed tomography (CT) was notable for diffuse bilateral ground-glass opacity shadows (Fig. 1A). He was treated with favipiravir (1,800 mg twice daily on day 1, followed by 800 mg twice daily on days 2-12), azithromycin (500 mg once daily), and intravenous immunoglobulin (5,000 mg once daily). Treatment with immunoglobulin and azithromycin was continued for 3 days after admission. Furthermore, methylprednisolone (500 mg once daily, for 3 days from admission) was also intravenously administered. After treatment using these drugs and oxygen inhalation, the patient's body temperature and hypoxia improved. In addition, his inflammation improved, and reverse transcription-polymerase chain reaction tests for SARS-CoV-

2 were negative by day 16.

On day 16, bilateral lung consolidation appeared on chest X-ray. Chest CT performed on day 19 was notable for the expansion of the consolidation and bilateral bronchiectasis in the lower lobes (Fig. 1B). We recognized these features as being similar to those in cases of organizing pneumonia (OP), and corticosteroid treatment was reinitiated. One hour after the first dose of prednisolone (30 mg), the patient reported new-onset chest pain, and his respiratory rate increased to 28 bpm. Chest X-ray revealed right-sided pneumothorax (Fig. 2A). This finding was associated with decreased SpO<sub>2</sub> levels (84%), and a chest tube was inserted immediately. On day 21, chest X-ray clearly showed a bulla in the right lung (Fig. 2B). Continuous air-leak through a chest tube was observed during the following 12 days, and treatment with prednisolone continued. Chest CT performed



**Figure 2.** A and B: Chest X-ray at the onset of pneumothorax (A) and after the insertion of a chest tube that revealed re-expansion of the lung and a right-sided small bulla (B). C: Repeat chest CT performed after 12 days of air drainage showing notable improvement of the pneumothorax and bulla formation in right S6.

at this time revealed improvement in the pneumothorax and bulla formation in the superior basal segment (segment 6; S 6) of the right lung (Fig. 2C). Tests for SARS-CoV-2 remained negative. The respiratory rate improved to 20 bpm, and the patient was discharged from the hospital after removal of the chest tube (Fig. 3).

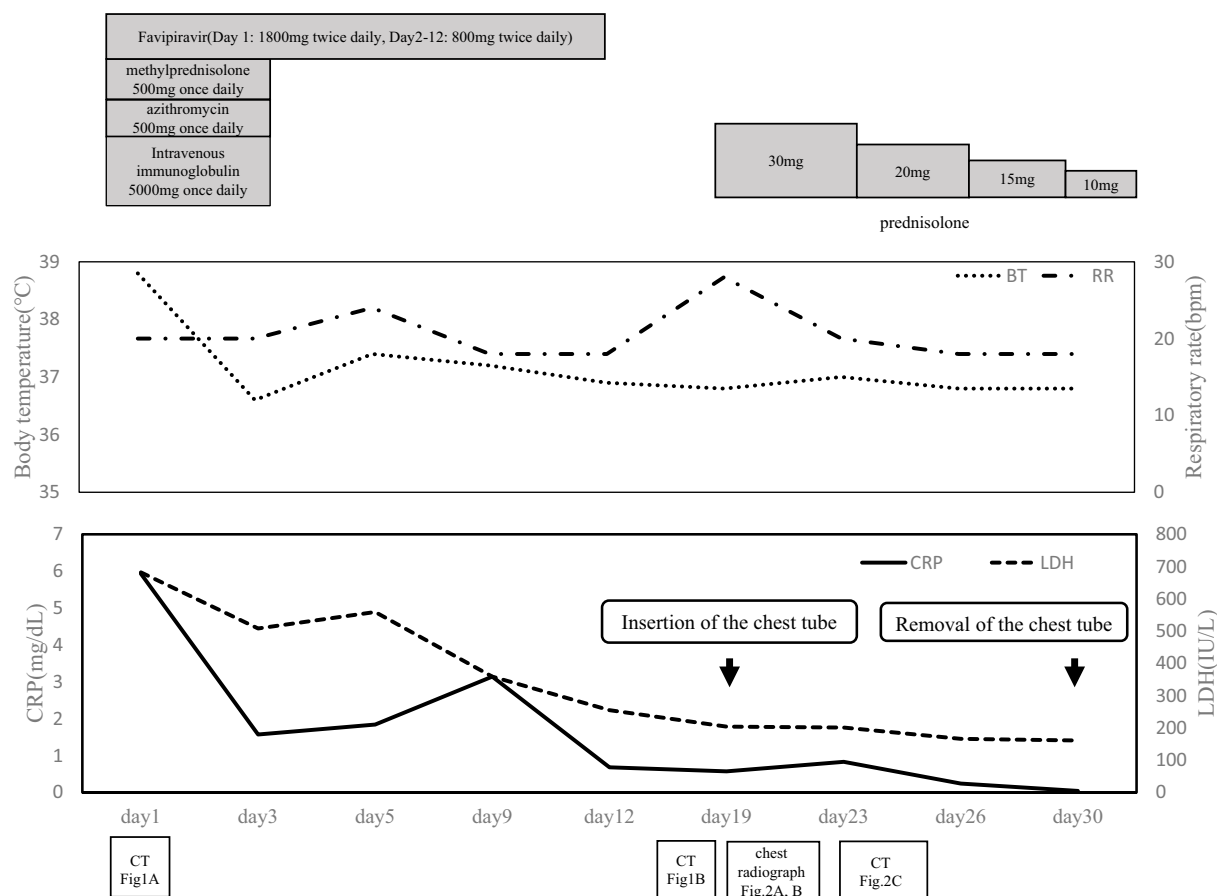
## Discussion

This case is remarkable for several reasons. First, pneumothorax developed in this patient who did not have any risk factors for pneumothorax, including mechanical ventilation, a smoking history, and pulmonary comorbidities. Second, a lung bulla was detected on chest X-ray and CT after the development of pneumothorax despite not being observed on either at the start of COVID-19 treatment.

There have been several reports of pneumothorax devel-

oping in patients undergoing treatment for COVID-19. Among them, one report described two cases of pneumothorax during treatment for COVID-19 (2). Both patients in this report had been intubated and received mechanical ventilation. In addition, a previous study reported that pneumothorax developed in 8% of patients with COVID-19 after treatment with mechanical ventilation (4). Another report showed the development of pneumothorax in a patient in whom a giant bulla had been observed on chest CT after receiving mechanical ventilation using PEEP (5). Therefore, these findings suggest that mechanical ventilation using PEEP may cause the development of pneumothorax, partly through the development and rupture of existing bullae or cysts.

In contrast, the present case had no smoking history and no pulmonary comorbidities. The patient did not receive mechanical ventilation, and no lung bullae or cysts had been observed on chest CT at admission. However, a lung bulla



**Figure 3.** Clinical course of the patient described in the present case report.

was detected after the development of pneumothorax. These findings suggest that, in this case, a lung bulla might have developed via lung injury caused by COVID-19 pneumonia and might be associated with the development of pneumothorax.

Pathological characteristics of postmortem biopsies of patients who died from SARS-CoV-2 have been reported (6, 7), including pronounced desquamation of pneumocytes and hyaline membrane formation, which are consistent with a diagnosis of acute respiratory distress syndrome, acute fibrinous pneumonia, and OP. In the present case, chest CT performed on day 19 was notable for the expansion of the consolidation and bilateral bronchiectasis in the lower lobes, and we recognized these features as being similar to those in a case of OP (8). However, we did not perform bronchoscopy due to concerns over the medical staff's safety and welfare. Future evaluations of this nature may reveal pathological changes associated with COVID-19 pneumonia.

There is currently no proven effective therapy for COVID-19. Clinical trials of several antiviral and antiretroviral drugs are currently ongoing. Several studies have reported that treatment with remdesivir might be effective in the early stages of COVID-19 pneumonia (9, 10). However, the impact of corticosteroid therapy in this setting has been controversial. In patients who were diagnosed with SARS-CoV or Middle East Respiratory Syndrome, corticosteroids

were found to delay the clearance of viral RNA (11, 12). Furthermore, corticosteroid treatment was associated with increased mortality among patients diagnosed with pneumonia secondary to influenza infection (13). However, in our case, we treated a patient with methylprednisolone and prednisolone in addition to favipiravir, azithromycin, and immunoglobulin. This is because treatment with systemic steroids from the beginning of treatment has been suggested to improve SpO<sub>2</sub> in COVID-19 patients (14, 15). A recent study also reported that the use of dexamethasone in patients with COVID-19 resulted in reduced rates of 28-day mortality among those who were receiving either invasive mechanical ventilation or oxygen alone (16).

Although the mechanism underlying the development of a bulla and pneumothorax in the present case was unclear, the check-valve mechanism-associated formation of bullae and the subsequent development of pneumothorax has been suggested in a previous patient with OP treated with corticosteroids (8). Corticosteroid therapy may also cause a delay in the wound-healing process of fragile lung tissue, and these histological changes may induce the formation of bullae through the check-valve mechanism. A previous report described a COVID-19 patient with pneumothorax who was also treated with corticosteroid for six days from the beginning of hospitalization (3). In the present case, corticosteroid therapy started at the beginning of hospitalization might have been associated with the development of the bulla and

thus caused pneumothorax. More attention needs to be focused on the clinical efficacy and adverse effects of corticosteroids in the treatment of COVID-19.

### Conclusion

This is the first case of COVID-19 pneumonia complicated with acute pneumothorax in a patient who did not have any risk factors for pneumothorax, including mechanical ventilation, a smoking history, and the presence of lung bullae and other pulmonary comorbidities.

**The authors state that they have no Conflict of Interest (COI).**

### Acknowledgement

We thank the patient who consented to participate in our study.

### References

- Chen N, Zhou M, Dong X, et al. Epidemiological and clinical characteristics of 99 cases of 2019 novel coronavirus pneumonia in Wuhan, China: a descriptive study. *Lancet* **395**: 507-513, 2020.
- Aiolfi A, Biraghi T, Montisci A, et al. Management of persistent pneumothorax with thoracoscopy and blebs resection in COVID-19 patients. *Ann Thorac Surg*. Forthcoming.
- Wang W, Gao R, Zheng Y, Jiang L. COVID-19 with spontaneous pneumothorax, pneumomediastinum and subcutaneous emphysema. *J Travel Med* **27**: taaa062, 2020.
- Yao W, Wang T, Jiang B, et al. Emergency tracheal intubation in 202 patients with COVID-19 in Wuhan, China: lessons learnt and international expert recommendations. *Br J Anesth* **125**: e28-e37, 2020.
- Sun R, Liu H, Wang X. Mediastinal emphysema, giant bulla, and pneumothorax developed during the course of COVID-19 pneumonia. *Korean J Radiol* **21**: 541-544, 2020.
- Xu Z, Shi L, Wang Y, et al. Pathological findings of COVID-19 associated with acute respiratory distress syndrome. *Lancet Respir Med* **8**: 420-422, 2020.
- Copin MC, Parmentie E, Duburcq T, et al.; Lille COVID-19 ICU and Anatomopathology Group. Time to consider histologic pattern of lung injury to treat critically ill patients with COVID-19 infection. *Intensive Care Med* **23**: 1-3, 2020.
- Kadota T, Shimizu K, Tsurushige C, et al. Organizing pneumonia complicated by cyst and pneumothorax formation. *Intern Med* **51**: 3155-3158, 2012.
- Grein J, Ohmagari N, Shin D, et al. Compassionate use of remdesivir for patients with severe Covid-19. *N Engl J Med* **382**: 2327-2336, 2020.
- Wang Y, Zhang D, Du G, et al. Remdesivir in adults with severe COVID-19: a randomized, double-blind, placebo-controlled, multi-centre trial. *Lancet* **395**: 1569-1578, 2020.
- Lee N, Allen Chan KC, Hui DS, et al. Effects of early corticosteroid treatment on plasma SARS-associated coronavirus RNA concentrations in adult patients. *J Clin Virol* **31**: 304-309, 2004.
- Arabi YM, Mandourah Y, Al-Hameed F, et al. Corticosteroid therapy for critically ill patients with middle east respiratory syndrome. *Am J Respir Crit Care Med* **197**: 757-767, 2018.
- Ni YN, Chen G, Sun J, et al. The effect of corticosteroids on mortality of patients with influenza pneumonia: a systematic review and meta-analysis. *Crit Care* **23**: 99, 2019.
- Zhou W, Liu Y, Tian D, et al. Potential benefits of precise corticosteroids therapy for severe 2019-nCoV pneumonia. *Signal Transduct Target Ther* **5**: 18, 2020.
- Wang Y, Jiang W, He Q, et al. A retrospective cohort study of methylprednisolone therapy in severe patients with COVID-19 pneumonia. *Signal Transduct Target Ther* **5**: 57, 2020.
- Horby P, Lim WS, Emberson JR, et al. Dexamethasone in hospitalized patients with Covid-19 - Preliminary report. *N Engl J Med*. Forthcoming.

The Internal Medicine is an Open Access journal distributed under the Creative Commons Attribution-NonCommercial-NoDerivatives 4.0 International License. To view the details of this license, please visit (<https://creativecommons.org/licenses/by-nc-nd/4.0/>).