

# Use of 'U-shaped tool for follow up of corneal ulcer cases in the COVID-19 pandemic

Rahul K Bafna, Abhijeet Beniwal, Nidhi Kalra, Suman Lata, Mohamed Ibrahime Asif, Namrata Sharma

To describe a smartphone-based telemedicine tool for monitoring of corneal ulcer size during the corona pandemic, a simple "U"-shaped tool was constructed using three Schirmer's strips that were provided to the patients with small to medium-sized corneal ulcers. The patient and the attendant were trained to use this simple U-shaped tool at home and send digital images to the treating ophthalmologist, to monitor the course of the ulcer. The tool was used in five eyes of five patients with active microbial keratitis. Patients were followed up regularly with the use of telemedicine facility every 48 h for an average duration of 7.6 days (range 6–9 days). In all the five eyes, assessment of the serial images with U-shaped tool showed decrease in size of corneal ulcer, which corroborated with subjective improvement in symptoms. Hence, the novel "U"-shaped tool may provide an effective measure in following-up of corneal ulcer patients in times of the COVID-19 pandemic, obviating frequent hospital visits and risk of contracting COVID.

**Key words:** Bacterial keratitis, corneal ulcer, COVID-19, follow-up, pandemic

Corneal ulcers are a common, vision threatening condition that often necessitates frequent follow-up. The size of the ulcer is an important predictive factor in the management of corneal ulcers.<sup>[1]</sup> Objective measurement of the ulcer size on every follow-up is a key to analyze the response to the treatment and need of change in the therapy. Digital photography has been routinely used as a method to objectively monitor the size and progression of the ulcer. Several other computer-based programs have also been designed for the same.<sup>[2-4]</sup>

The WHO declared corona virus pandemic in March 2020, following which social distancing was recommended and movement of all individuals were restricted across the country.<sup>[5]</sup> This posed a major challenge in the follow-up of the patients especially, if elderly, as multiple hospital visits would increase their risk of exposure to Corona virus.

With this concern in mind, a unique "U"-shaped tool was devised to enable monitoring of the ulcer progression and course of disease by the ophthalmologist without the requirement of frequent visits of patients to the hospital.

## Technique

A pilot study was done in five eyes of five patients having small to medium-sized corneal ulcers. A detailed slit lamp examination of the ulcer was performed, and corneal scraping

was done at first visit. Patients were started empirically on topical fortified antibiotics as indicated.

Three Schirmer's strips (Madhu Instruments, New Delhi) were taken [Fig. 1a] and glued in the form of a "U"-shaped tool [Fig. 1b]. This could be done by apposing two of them perpendicularly to the ends of the horizontally placed Schirmer's strip. Ensure that the 5 mm width of vertical Schirmer's strip corresponds to the 5 mm marking on the horizontal strip. These markings were used as a guide to ensure a right angle between the two limbs of the "U"-shaped tool. This could also be confirmed using the grid lines on the smartphone camera.

The patient was made to lie down supine and was asked to look at the ceiling. Then, both eyelids were retracted gently, and the "U"-shaped tool was placed parallel to the eye and aligned with the superior orbital margin, and the smartphone was used to take digital photograph [Fig. 1c]. To avoid parallax error the affected eye, "U"-shaped tool and the smartphone should be placed parallel to each other and aligned in a line. The similar procedure was again repeated with fluorescein staining of the corneal ulcer. The entire procedure was done in the presence of the patient attendant, and he/she was trained in doing this procedure at home. The attendant was then encouraged to perform the same at the clinic to verify the repeatability of the procedure. Attendant was directed to send the serial pictures

### Access this article online

#### Website:

www.ijo.in

#### DOI:

10.4103/ijo.IJO\_1560\_20

### Quick Response Code:



Department of Ophthalmology, Dr. Rajendra Prasad Centre for Ophthalmic Sciences, All India Institute of Medical Sciences, New Delhi, India

**Correspondence to:** Dr. Namrata Sharma, Professor of Ophthalmology, Cornea, Cataract and Refractive Surgery Services, Dr. Rajendra Prasad Centre for Ophthalmic Sciences, All India Institute of Medical Sciences, New Delhi - 110 029, India. E-mail: namrata.sharma@gmail.com

Received: 18-May-2020

Revision: 22-Jun-2020

Accepted: 14-Jul-2020

Published: 23-Sep-2020

This is an open access journal, and articles are distributed under the terms of the Creative Commons Attribution-NonCommercial-ShareAlike 4.0 License, which allows others to remix, tweak, and build upon the work non-commercially, as long as appropriate credit is given and the new creations are licensed under the identical terms.

**For reprints contact:** WKHLRPMedknow\_reprints@wolterskluwer.com

**Cite this article as:** Bafna RK, Beniwal A, Kalra N, Lata S, Asif MI, Sharma N. Use of 'U-shaped tool for follow up of corneal ulcer cases in the COVID-19 pandemic. Indian J Ophthalmol 2020;68:2199-201.

taken by them to the treating ophthalmologist every alternate day.

The images were edited with the help of a rectangle-shaped tool in photo editor software. Two rectangles were drawn encompassing horizontal and vertical margins of the ulcer, respectively, and bisecting limbs of “U”-shaped tool [Fig. 1d]. The length and width of the ulcer was measured by noting the 1-mm markings on the Schirmer’s strip lying within both the rectangles. In a similar manner, the rectangles were selected and drawn to measure the size of the epithelial defect in the images taken after fluorescein staining.

The “U”-shaped tool along with fluorescein strips was provided to the patient attendant. Instructions were given to the attendant to repeat the procedure with the “U”-shaped tool and to transmit the digital images to the treating ophthalmologist. Objective assessment was done by the treating ophthalmologist, and subjective assessment of symptoms was done using telemedicine facility every 48 h. The patients were encouraged to follow-up in the cornea clinic on any deterioration by objective or subjective assessment.

## Results

The “U”-shaped tool was used in five eyes of five patients with microbial keratitis who were followed up regularly via telemedicine every 48 h for an average duration of 7.6 days (range 6–9 days) [Table 1]. In all patients, the objective assessment showed a decrease in size of the ulcer and subjective assessment showed an improvement of the symptoms.

“U”-shaped tool was found to be helpful in corneal ulcer assessment and follow-up, even in children. While the child was sleeping, the parents were asked to gently retract the eyelid of the affected eye and align the U-shaped tool with the orbit

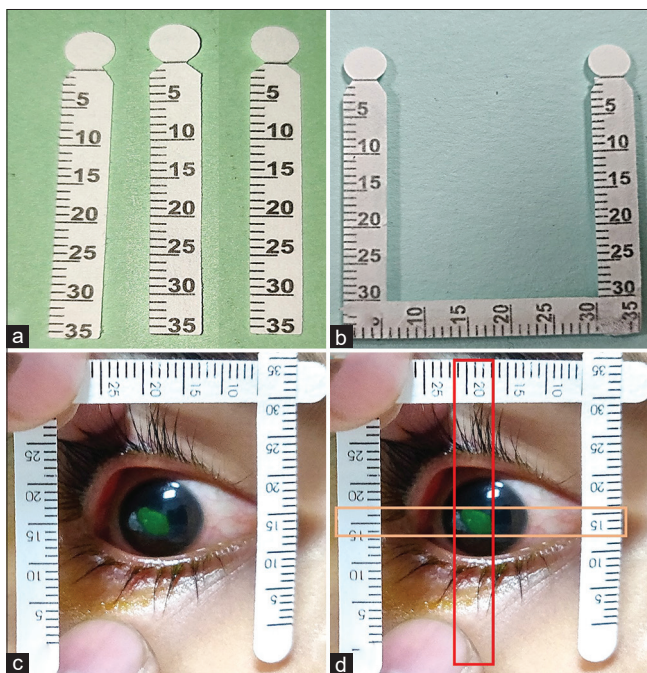
and capture an image [Fig. 2a]. The rectangle tools were then used to measure the ulcer using photo editor software [Fig. 2b]. Serial photographs every 48 h revealed a reduction in size of the ulcer [Fig. 2c and d]. The parents were reassured, and medical therapy was continued.

## Discussion

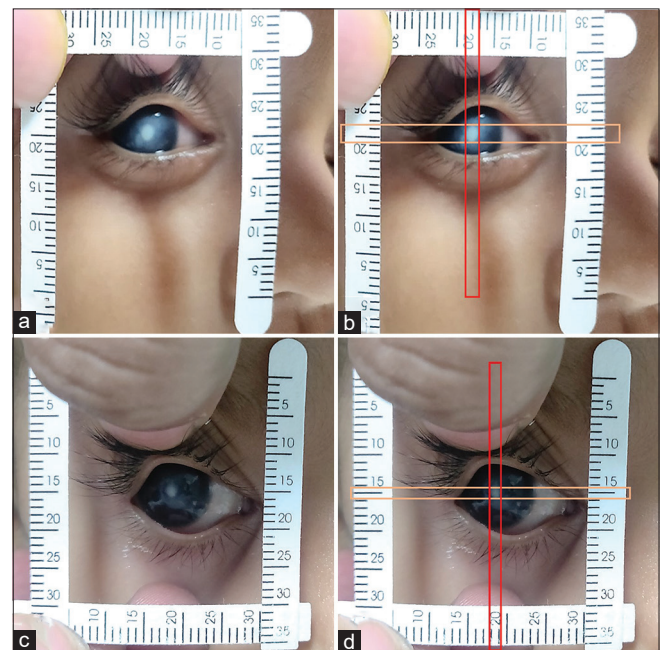
Corneal ulcer has been recognized as a silent epidemic in developing countries like India.<sup>[6]</sup> The course of the infective corneal ulcer could be evaluated by the following criteria: degree of pain, discharge, decrease in vision, injection, epithelial defect size, anterior chamber inflammation, and intraocular pressure.<sup>[7]</sup> Among the above, certain parameters are amenable to monitoring by telemedicine. The restrictions imposed amidst the global COVID-19 pandemic posed a unique challenge in the management of patients with microbial keratitis as frequent follow-ups were neither possible nor advisable, considering the higher probability of the patients contracting the COVID-19 infection.

A variety of methods have been described in literature for measuring anterior segment lesions. These have shown good agreement between different examiners in the measurement of the lesions. However, most of these are based on slit lamp examination.<sup>[8,9]</sup>

Schirmer’s strip is made up of Whatman filter paper 41 with dimensions of 35 mm length and 5 mm breadth. Along its length, there are black lines that are spaced at 1 mm interval.<sup>[10]</sup> These strips are commonly used in assessment of dry eye disease and are inexpensive and easily commercially available. Our “U”-shaped tool is made up of three Schirmer’s strips and is used to measure dimensions of corneal ulcer, without using a slit lamp. The measurement is done using a smartphone, by simply counting the number of 1 mm markings encompassing



**Figure 1:** (a) Three Schirmer’s strips, (b) the “U”-shaped tool, (c) digital image of an ulcer with fluorescein staining, and (d) rectangle tool on (c) showing epithelial defect: 4 × 4 mm approx



**Figure 2:** (a) Digital image of ulcer in a child, (b) rectangle drawn on (a) showing infiltrate: 2 × 2 mm, (c) the same eye after 48 h, (d) rectangle drawn on (c) infiltrate: 1.5 × 1 mm

**Table 1: Demography, Diagnosis, Follow up and progression of Ulcer**

Age/Sex	Diagnosis	Follow-up with the U-shaped tool electronically (Every 48 h)	Change in the Ulcer
3 years/Female	Bacterial keratitis	9 days	Improvement
5 year/Female	Bacterial keratitis	7 days	Improvement/reduced infiltrate
70 yrs/Male	Bacterial Keratitis	7 days	Improvement
40yrs/Male	Chemical Injury with resolving secondary bacterial keratitis	6 days	Reduced epithelial defect
41yrs/Female	Bacterial keratitis	9 days	Improvement

the rectangle. Serial images were compared with previous ones to monitor the change in dimensions of the ulcer. Digital images also provided an electronic record in patient database.

Though “U”-shaped tool is especially useful in monitoring and following up the patients under extreme conditions like a pandemic, it has few limitations. Most importantly, the depth of the ulcer could not be assessed using this method. Anterior chamber inflammation, occurrence of cataract, glaucoma, or any other secondary complications could not be monitored. One other drawback was the technical difficulty in placing the tool right at the orbital plane every time. If the distance between the U-shaped tool and the orbit would increase, there could be an error in the apparent dimensions of the ulcer. This was ensured by explaining the attendants that the tool had to be placed parallel to the orbital plane without any tilt. The smartphone had to be placed parallel to the tool again without any tilt at a fixed distance (arm’s length) every time. In this manner, even if the actual dimensions of the ulcer could not be measured, the change in size was correctly measured. Considering the limitations of the COVID scenario, this tool was excellent in providing information about change in ulcer size.

Even in our paediatric patients, the parents were able to capture good corneal images, when child was asleep. But it might require more than a person in capturing the image in children depending on the level of cooperation. The attendants were asked to use the patient’s own prescription drops only to wet the fluorescein strip and not any other fluid.

Though there were limitations in this method of follow-up, yet it provided valuable information to the ophthalmologist in deciding the course of therapy and to decide which patients required clinic visit. It also provided reassurance to the patients and attendants by being involved in the treatment process and were in constant touch with their treating ophthalmologist.

## Conclusion

In the wake of the ongoing lockdown and uncertainty of resumption of elective services, this novel “U”-shaped tool has the potential to provide effective monitoring to the vast clientele of corneal ulcers in our country. It could also be used

by primary care, emergency room, or inpatient health care providers in locations or situations where an ophthalmologist is not immediately available. It can also be used by residents and trainees to communicate progress with the supervising ophthalmologist who may not always be present.

## Financial support and sponsorship

Nil.

## Conflicts of interest

There are no conflicts of interest.

## References

- Kim RY, Cooper KL, Kelly LD. Predictive factors for response to medical therapy in bacterial ulcerative keratitis. *Graefes Arch Clin Exp Ophthalmol* 1996;234:731-8.
- Toutain-Kidd CM, Porco TC, Kidd EM, Srinivasan M, Prajna NV, Acharya N, *et al.* Evaluation of fungal keratitis using a newly developed computer program, Optscore, for grading digital corneal photographs. *Ophthalmic Epidemiol* 2014;21:24-32.
- Mukerji N, Vajpayee RB, Sharma N. Technique of area measurement of epithelial defects. *Cornea* 2003;22:549-51.
- Patel TP, Prajna NV, Farsiou S, Valikodath NG, Niziol LM, Dudeja L, *et al.* Novel image-based analysis for reduction of clinician-dependent variability in measurement of the corneal ulcer size. *Cornea* 2018;37:331-9.
- Mazumder H, Hossain MM, Das A. Geriatric care during public health emergencies: Lessons learned from novel corona virus disease (COVID-19) pandemic. *J Gerontol Soc Work* 2020;63:257-8.
- Gupta N, Tandon R, Gupta SK, Sreenivas V, Vashist P. Burden of corneal blindness in India. *Indian J Community Med* 2013;38:198-206.
- Lin A, Rhee MK, Akpek EK, Amescua G, Farid M, Garcia-Ferré FJ, *et al.* Bacterial keratitis preferred practice pattern®. *Ophthalmology* 2019;126:P1-55.
- VanRoekel RC, Bower KS, Burka JM, Howard RS. Anterior segment measurements using digital photography: A simple technique. *Optom Vis Sci* 2006;83:391-5.
- Parikh PC, Valikodath NG, Estopinal CB, Shtein RM, Sugar A, Niziol LM, *et al.* Precision of epithelial defect measurements. *Cornea* 2017;36:419-24.
- Stevens S. Schirmer’s test. *Community Eye Health* 2011;24:45.