



Endoscopic combined intrarenal surgery (ECIRS) – Tips and tricks to improve outcomes: A systematic review

Cecilia Maria Cracco , Cesare Marco Scoffone 

Cite this article as: Cracco CM, Scoffone CM. Endoscopic combined intrarenal surgery (ECIRS) - Tips and tricks to improve outcomes: A systematic review. Turk J Urol 2020; 46(Supp. 1): S46-S57.

ABSTRACT

Objective: This study aimed at assessing current efficacy and safety of endoscopic combined intrarenal surgery (ECIRS) for the treatment of large and/or complex urolithiasis and identifying relevant tips and tricks able to improve its outcomes, mainly deriving from the adjunct of retrograde flexible ureteroscopy to the traditional antegrade approach of percutaneous nephrolithotomy (PNL).

Material and methods: A systematic review was conducted using relevant databases (Ovid Medline, PubMed, Scopus, and Web of Sciences), employing “ECIRS” as the search term in all cases, and then adding “endoscopic combined intrarenal surgery” and “flexible ureteroscopy AND percutaneous nephrolithotomy” as search terms for PubMed and Scopus. Original articles and systematic reviews were selected according to the Preferred Reporting Items for Systematic Reviews and Meta-analyses guidelines. Additionally, the reference lists of the selected publications were checked manually.

Results: A total of 14 studies were selected for analysis: two systematic reviews, one randomized controlled trial, five nonrandomized comparative studies, three prospective case series, and three retrospective case series. ECIRS achieves high stone-free rates and rather low/low Clavien-Dindo grade complication rates, confirming the role of retrograde ureteroscopy in the maximization of its efficacy and safety. A narrative synthesis of the most recognized tips and tricks of ECIRS is provided.

Conclusion: The contribution of retrograde flexible ureteroscopy during PNL is essential. It plays a dual role, both diagnostic and active, allowing tailoring of the procedure to the patient, urolithiasis, and anatomy of the collecting system and optimization of the PNL efficacy and safety. This is ECIRS: an updated, complete, and versatile version of PNL.

Keywords: Endoscopic combined intrarenal surgery; flexible ureteroscopy; percutaneous nephrolithotomy; PCNL; urolithiasis.

Introduction

ECIRS is an acronym first used in 2008,^[1] for endoscopic combined intrarenal surgery, standardizing the combined retrograde and antegrade approaches to large and/or complex urolithiasis using both rigid and flexible endoscopes.

This way of performing percutaneous nephrolithotomy (PNL)—although sparsely described and reserved for particular clinical situations of urolithiasis—has not been very popular for a long time, being employed by a rather restricted number of urologists concentrated in definite geographical areas (Spain, the native land of ECIRS and of the

supine/supine-modified PNL positions, and Spanish-speaking countries; Italy, the adoptive homeland of ECIRS; and Japan, using ECIRS in a prone-modified position). Until 2014, our group was practically the only one publishing papers using “ECIRS” or its extended form “endoscopic combined intrarenal surgery” as keywords.^[2-4]

Conversely, during the last six years, ECIRS has become more accepted and diffused, as indicated by the growing number of papers published on the topic,^[3,4] by its introduction in the European Association of Urology (EAU) guidelines,^[5] in endourology textbooks^[6] and in training programs.^[7] In 2011, less than 20% of PNL patients from all over the world

ORCID iDs of the authors:

C.M.C. 0000-0001-7154-1451;
C.M.S. 0000-0002-8991-7709.

Department of Urology,
Cottolengo Hospital, Torino,
Italy

Submitted:

24.06.2020

Accepted:

06.07.2020

Available Online Date:

25.08.2020

Corresponding Author:

Cesare Marco Scoffone
E-mail: scoof@libero.it

©Copyright 2020 by Turkish
Association of Urology

Available online at
www.turkishjournalofurology.com

were operated in the supine position and less than 10% with a combined approach^[8]; in 2014, 10% of the PNLs in the United States were performed in the supine position and 12% with a combined antegrade–retrograde approach^[9]; in 2017, the practice of ECIRS among Latin American urologists ranged from 32% to 45%.^[10]

This study aimed to update the data about the efficacy and safety of ECIRS and to identify the main tips and tricks of this combined approach, possibly easing the steps of the procedure and improving its outcomes, based on a systematic review of the existing literature.

Material and methods

Literature search and article selection

A systematic review of the literature using relevant databases, including Ovid MedLine, PubMed, Scopus, and Web of Science, was concluded on April 29th, 2020 independently by both authors to identify relevant studies, according to the four-item Preferred Reporting Items for Systematic Reviews and Meta-analysis (PRISMA) flow diagram (Figure 1).^[11] The comprehensive and highly sensitive electronic search had neither language nor period of publication restrictions. The following National Library of Medicine Medical Subject Headings (MeSH) terms and keywords were employed: “ECIRS” (for all the databases), “endoscopic combined intrarenal surgery,” and “flexible ureteroscopy AND percutaneous nephrolithotomy” for PubMed and Scopus (not for Ovid Medline or Web of Science, because of the very high number of nonrelated citations). Additionally, the reference lists of the selected publications were checked manually for eligible articles. Screening, to improve specificity, was applied to each title and abstract identified in a standardized manner by one author (C.M.C.); the other author (C.M.S.) screened a random sample (10%) of excluded records and independently assessed all studies that met inclusion criteria. A narrative synthesis for analysis of the selected studies was used.

Main Points:

- ECIRS stands for endoscopic combined intrarenal surgery and is the combined antegrade and retrograde approach to large and/or complex urolithiasis, using both rigid and flexible scopes.
- ECIRS achieves high stone-free rates with low complication rates, mainly of low grade according to the Clavien–Dindo classification.
- In ECIRS, safety and efficacy are enhanced by a number of tips and tricks, including preliminary diagnostic retrograde flexible ureteroscopy, endovision control of the percutaneous access, application of a through-and-through guidewire, bilateral irrigation with optimal vision and fragments drainage, retrograde cooperation in stone preparation, clearance, and treatment.

Types of study design included

Randomized controlled trials (RCTs), quasi-RCTs, nonrandomized comparative studies (NRCSSs), single-arm case series with at least 50 patients, systematic reviews, and meta-analyses were considered eligible for inclusion.

Exclusion criteria were the following: commentaries, editorials only, expert opinions, absence of outcome data, incomplete technical description of the surgical technique, inability to read the complete article, case reports, book chapters, theses, reviews, congress abstracts, absence of abstract, and single-arm case series with less than 50 patients.

Types of patients included

The study population included patients who underwent ECIRS for urolithiasis eligible for PNL according to the EAU guidelines^[5] irrespective of age, sex, American Society of Anaesthesiologists (ASA) score, body mass index (BMI), presence of congenital or acquired abnormalities of the urinary tract, urinary diversions, or kidney transplantation.

Types of interventions included

Only studies clearly reporting about ECIRS, i.e. combining retrograde ureteroscopy and PNL in the same procedure, were included, without any discrimination regarding the patient position during PNL (prone, prone-modified, supine, supine-modified, etc.), kind of retrograde ureteroscope used (semirigid or flexible), or the diameter of the percutaneous access.

Objectives and outcome measures

The primary objective was to assess the current efficacy and safety of ECIRS, using stone-free rates (SFRs) and complication rates (CRs) with their Clavien–Dindo grading^[12] as outcome measures, respectively.

Additional outcome measures included were: number of percutaneous accesses, operative time, length of hospital stay, hemoglobin drop, transfusion rates (TRs), qualitative analysis of the reported complications, and need for secondary procedures.

The secondary objective was to identify relevant tips and tricks useful during the daily practice of ECIRS, possibly simplifying some PNL surgical steps.

Results

A total of 14 studies were included in the present systematic review: two systematic reviews,^[4,13] one RCT,^[14] three prospective case series,^[1,15,16] three retrospective case series,^[17-19] and five NRCSSs (Figure 1; Tables 1 and 2).^[20-24]

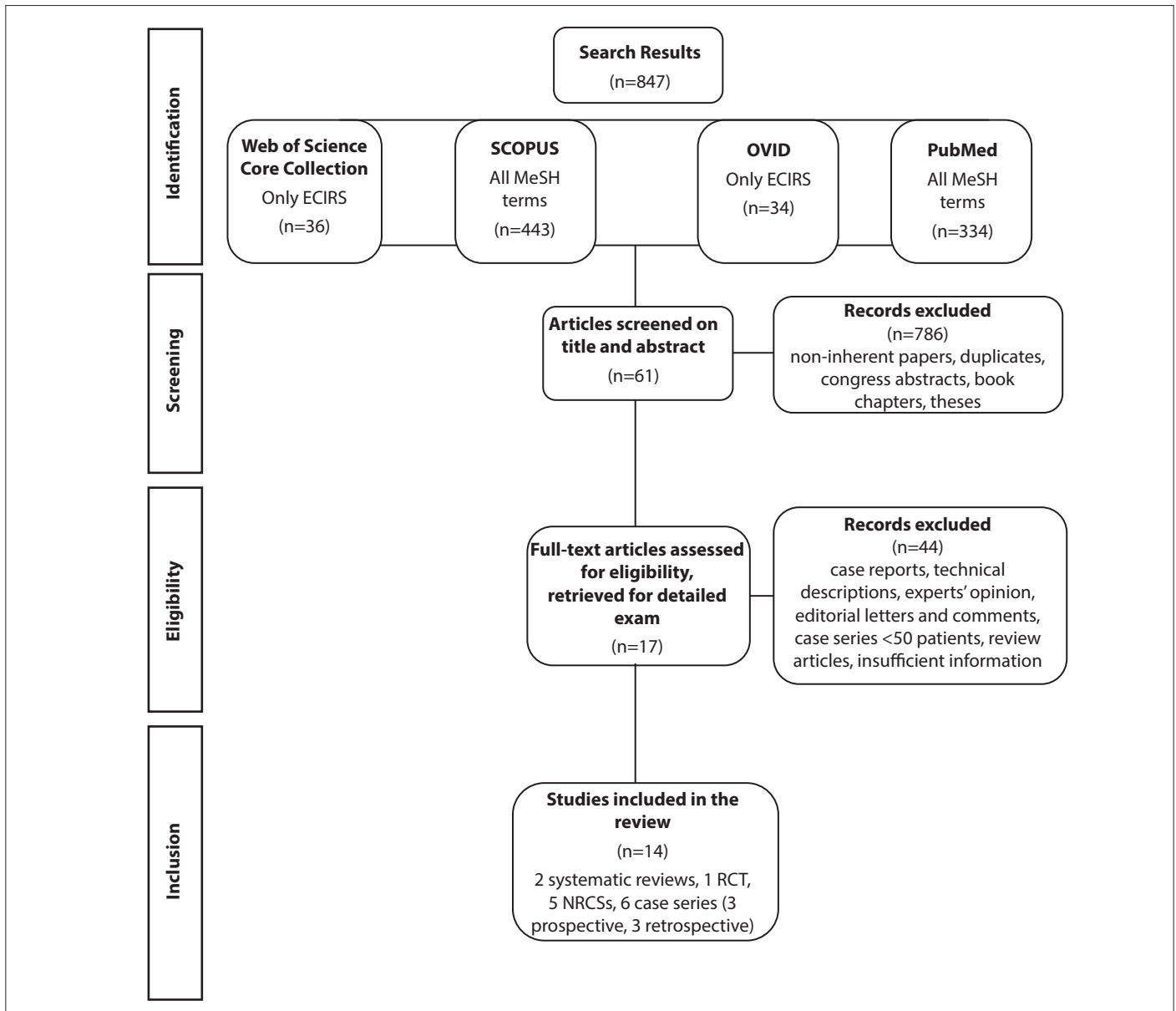


Figure 1. PRISMA flow diagram

Stone-free rates

For ECIRS, the selected studies report SFRs ordinarily >80% through a single percutaneous access most of the times,^[1,4,13-24] ranging from 61%^[24] to 97%.^[20] The highest SFRs are described for standard accesses (24–30F) and smaller stones^[1,4,13,15,16,20], and the lowest for the miniaturized approaches employed to treat high-burden urolithiasis.^[19,22-24]

Complication rates

CRs reporting has been done in almost all selected studies according to the Clavien–Dindo classification. The range is 5.8%–44%, regardless of the tract size or puncture guidance, but mostly correlated with larger staghorn stones and longer operation times.^[4,19,24]

Most complications are grade 1 and 2, with none^[15,17,19,23] or very rare grade 3^[1,14,18,19,24] anecdotal grade 4,^[18,24] and no grade 5.

The bleeding risk appears to be rather low, as demonstrated by the limited postoperative hemoglobin drops (0.8–2.1 g/dL) and the 0.5%–3% TRs, irrespective of the tract size. The reported rate of fever (body temperature >38°C) and of systemic inflammation response syndrome (SIRS), possibly evolving into urosepsis/septic shock, is also very variable, ranging from 3% to 40%.^[4,18]

Other parameters

The *decreased need for multiple accesses* in ECIRS is evident in all the selected papers: some surgeons performed ECIRS

Table 1. Summary of the literature review

Author [ref]	Publ in	Kind of study	Period of surgery	Number of pts = 1678 (six studies 666 pts)	Patient position	Percutaneous Access	Ureterscope	UAS	Puncture guidance
Cracco et al. ^[4]	2017	Systematic review	2004-2014	(six studies 666 pts)	Any	Any (18–30F)	NA	Yes/No	Any
Keller et al. ^[13]	2020	Systematic review	NS	NS	Any	NS	NS	NS	NS
Wen et al. ^[14]	2016	RCT	05-2012/10-2014	67	Prone/GMSV	20F	URF-V Olympus	Yes (12–14F)	US
Scoffone et al. ^[1]	2008	Prospective series	04-2004/ 12-2007	127	GMSV	30F 77% (nephro 24F); 24F 23% (nephro 18F)	FlexX2/C Storz	No	Rx-US-Endovision
Gökce et al. ^[15]	2019	Prospective series	09-2016/03-2018	137	GMSV	16F (nephro 12F); 24F (nephro 21F)	FlexX2 Storz	Yes (9.5-11.5F)	Rx
Schulster et al. ^[16]	2019	Prospective series	07-2017/01-2018	110	Prone split-leg	30F (>85%)	FlexXC Storz	Yes (11-13F)	Rx-Endovision
Hamamoto et al. ^[17]	2014	Retrospective series	12-2010/01-2013	60	Prone split-leg	18F (nephro 12F)	FlexX2 Storz	Yes (12-14F)	Rx-US
Tabei et al. ^[18]	2016	Retrospective series	04-2010/10/2014	370	GMSV	30F (nephro 24F); 18–24F (nephro 12–18F)	FlexX2 Storz	Yes (11-13F or 13-15F)	Rx-US
Yamashita et al. ^[19]	2017	Retrospective series	02-2008/04-2015	75	Prone split-leg	16.5–19.5F (nephro 12F)	URF-P5/V Olympus	Yes (12-14F or 14-16F)	Rx-US-Endovision
Isac et al. ^[20]	2013	NRCS	08-2010/01-2012	159	Prone split-leg	30F	Flexible ureteroscopy	Yes (12-14F or 14-16F)	Rx-Endovision
Hamamoto et al. ^[21]	2014	NRCS	02-2004/01-2013	161	Prone split-leg	18F/30F	FlexX2 Storz	Yes (12-14F)	Rx-US
Nuño et al. ^[22]	2014	NRCS	01-2005/12-2011	171	GMSV	16–18F/24–30F	FlexX2 Storz/ URF-P5 Olympus	Yes (11-13F or 13-15F)	NS
Leng et al. ^[23]	2018	NRCS	03-2014/01-2016	87	Oblique supine lithotomic	16–18F	URF-P5 Olympus	Yes	US
Usui et al. ^[24]	2020	NRCS	04-2009/05-2016	154	GMSV	16.5F (nephro 15.9F)/24–30F (nephro24F)	Semirigid 6-7.5F Wolf ureteroscope	Yes (11-13F or 13-15F)	Rx-US

RCT: randomized controlled trial; NRCS: nonrandomized comparative study; UAS: ureteral access sheath; GMSV: Galdakao-modified supine Valdivia (position). NS: not specified; NA: not applicable; nephro: nephroscope; US: ultrasound

through a single-access tract in 100% of cases,^[14,17,21,22] whereas some others adopted an additional tract when necessary, but only in 1.6%–10% of cases.^[1,4,13,15,18,20]

Operative time is sometimes considered longer in ECIRS,^[14,22] but more often shorter than for traditional PNL,^[4,13,17,21] being as low as 70 min, including patient positioning.^[1]

The *hospital stay* ranges from 5.1 to 9.8 days (but this parameter is not specified in five out of the 14 selected articles).^[13,15,16,18,20]

ECIRS apparently implies *less need for ancillary procedures*,^[1,17,19,20] being a versatile procedure for one-step complete resolution even in cases of large stone burdens.^[17]

Tips and tricks

Preliminary retrograde ureteroscopy is not time-consuming and is a very useful tool for evaluating the features of both lower and upper urinary tracts and then tailor the steps of PNL to the individual clinical situation. In all the studies, except in one, the insertion of a ureteral access sheath (UAS) has been reported.^[1]

The *Endovision puncture* consists of the unique opportunity to endoscopically direct and check the percutaneous puncture of the chosen calyx (Figures 2 and 3).^[1,4,13] Subsequent monitoring of the creation of the access tract (i.e., checking balloon dilation and advancement of the Amplatz working sheath) under direct vision

Table 2. Summary of the literature review

Author [ref]	Mean stone size	SFR, (%)	Operation time (mins)	CR, (%)	Hospital stay (days)	Hb drop/ loss, TR	Number of tracts	Lithotripsy	Rx	Exit strategy
Cracco et al. ^[4]	34–39 mm; 645–735 mm ²	82–97	70–165	10–48	5.1–9.7	NS (reduced)	1 most times	NS	NS	NS
Keller et al. ^[3]	Staghorn	88–91	110	NS	NS	2.1 g/dL	1 most times	NS	NS	NS
Wen et al. ^[14]	Partial staghorn (640–690 mm ²)	88	105	48.5	9.8	77 ml	1	Holmium laser	NS	6F JJ, 16F nephrostomy
Scoffone et al. ^[11]	33% multiple or staghorn, 34–39 mm	82	70	38.6	5.1	3% TR	1 98.4%	Ballistic-US-Holmium laser	8.7 mins	52% JJ, 22F nephrostomy 68.5%, 8F 31.5%
Gokce et al. ^[15]	29.6 mm	93	81	5.8	NS	0.8 g/dL	2 in 8.8%	Ballistic-Holmium laser	74 secs	NS
Schulster et al. ^[16]	33 mm	76–90	NS	NS	NS	NS	1 (?)	Ballistic US-Holmium laser	73 secs	JJ, no nephrostomy
Hamamoto et al. ^[17]	39 mm	82	120	10 (Clavien 1–2)	7	1.04 g/dL, 1.7% TR	1 100%	Holmium laser	NS	6F JJ, 18F nephrostomy
Tabei et al. ^[18]	710–883 mm ²	NS	123	15.5 SIRS, 20.8	NS	0.5% TR	2 in 5%–10%	Ballistic US-Holmium laser retro	NS	6F JJ, 14–22F nephrostomy
Yamashita et al. ^[9]	4.17 cm ²	69	124 n	32	9	1.3 g/dL	1 (?)	Ballistic-Holmium laser retro	NS	6F JJ, 16F nephrostomy
Isac et al. ^[20]	33 mm	88–97	100	3 (8% aborted for bleeding)	NS	1.1 g/dL, 1.6% TR	1.03	Cyberwand-Holmium laser	3.2 mins	NS (postoperative drain)
Hamamoto et al. ^[21]	39 mm	82	120	NS	7	<1% TR	1 100%	Holmium laser	NS	4–7F JJ, 18F nephrostomy
Nuño et al. ^[22]	40 mm; 154 mm ²	75	165	29	5.3	NS	1 100%	NS	NS	NS
Leng et al. ^[23]	5.2 mm, staghorn	79.5	87.5	6.8	9.6	1.6 g/dL	1	Holmium laser	NS	5–7F JJ, 16F nephrostomy
Usui et al. ^[24]	650 mm ²	61	131	32–44	7.2	1.9 g/dL	1 (?)	Ballistic-US-Holmium laser	3.85 mins	52% 6F JJ, 14–20F nephrostomy

SFR: stone-free rate; CR: complication rate; SIRS: systemic inflammation response syndrome; TR: transfusion rate; NS: not specified. mins: minutes; secs: seconds; US: ultrasound

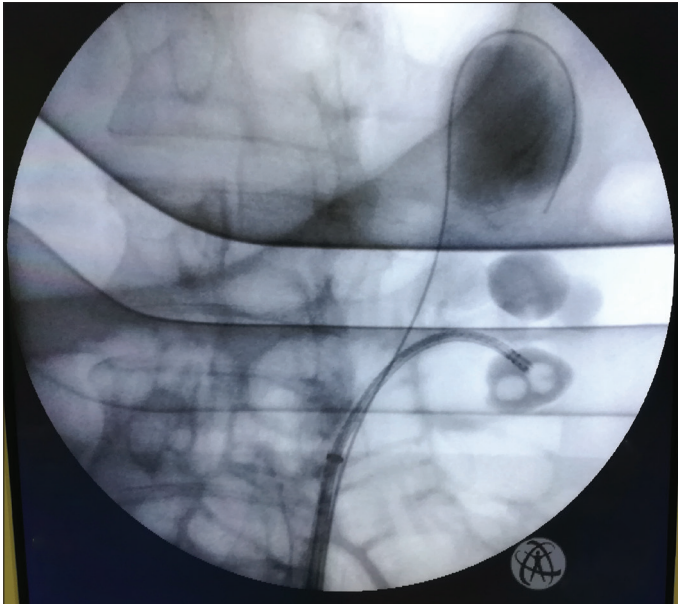


Figure 2. ECIRS in the Galdakao-modified supine Valdivia position. Ureteroscopic choice of the inferior-posterior calyx containing stones for the percutaneous renal puncture, fluoroscopic image after delicate retrograde contrast medium injection

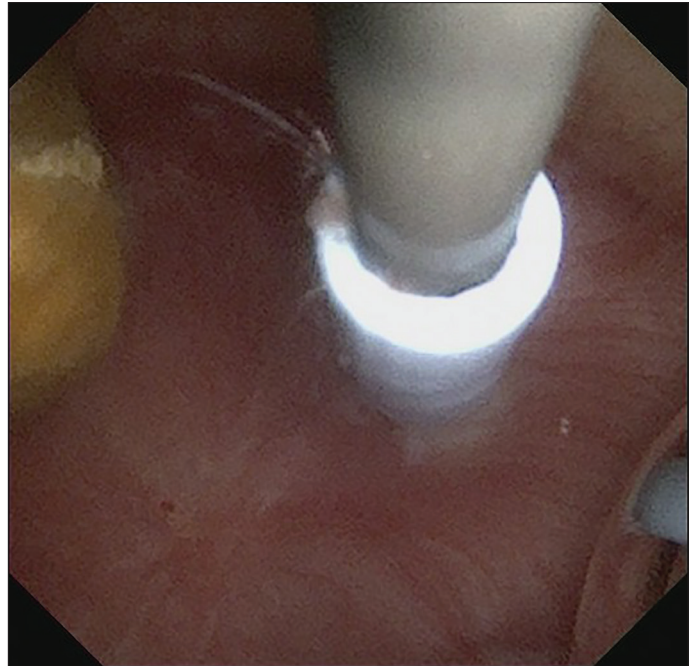


Figure 4. Endoscopic vision of fascial 8F dilator inserted over the 0.038" hydrophilic guidewire (FlexXC, Storz)

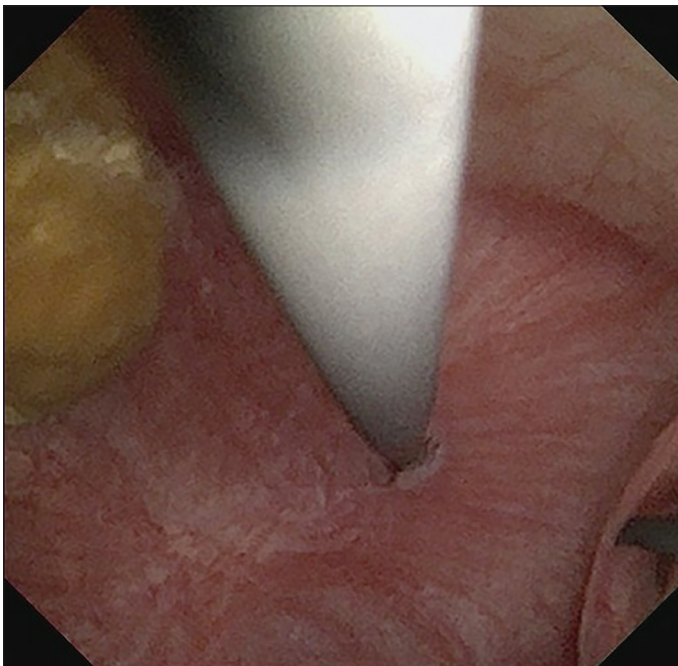

Figure 3. Endoscopic vision of the hydrophilic 0.038" guidewire exiting from the tip of the calyceal papilla after the percutaneous renal puncture (FlexXC, Storz)

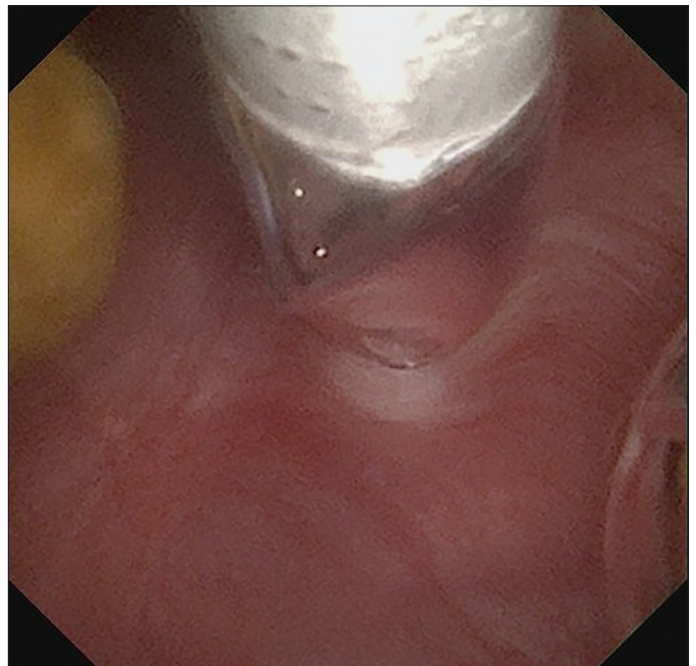


Figure 5. Endoscopic vision of the balloon dilator insertion and inflation (FlexXC, Storz)

minimizes the risk of underdilation in the parenchymal tissue (possibly causing bleeding and need to redilate the tract) or, conversely, of overdilation (possibly injuring the collecting system and also causing bleeding) (Figures 4-6).^[1,20]

The possibility of checking under vision all the steps of the percutaneous access allows for a *reduced X-ray exposure* (for the patient and all the people working in the operating theater), as demonstrated by the shorter fluoroscopy times of ECIRS. ^[15,16,18,20,24]

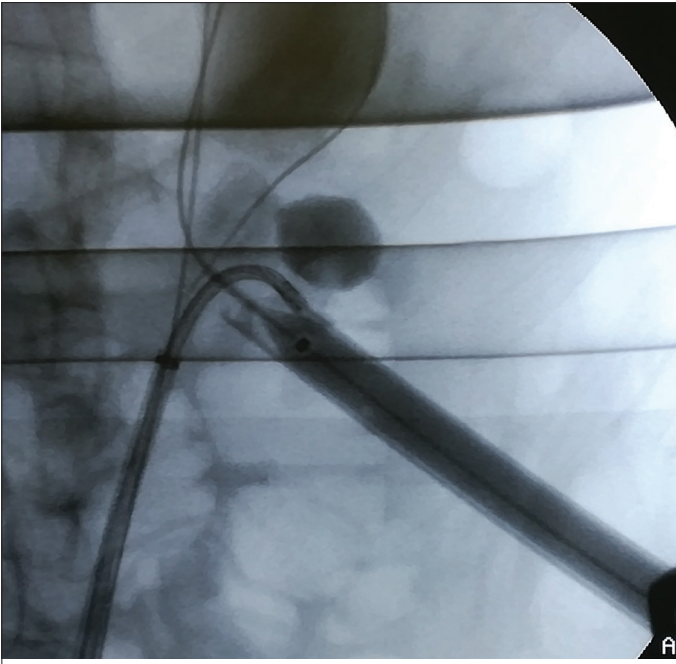


Figure 6. Ureteroscopic control of Amplatz sheath application, fluoroscopic image

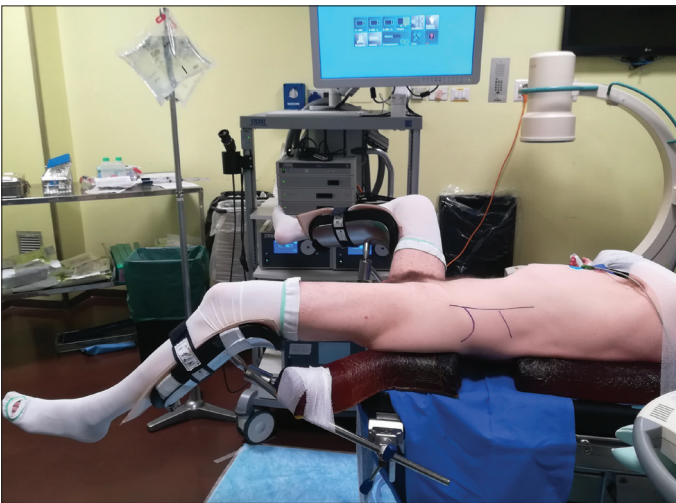


Figure 7. Patient in the Galdakao-modified supine Valdivia position, ready for ECIRS, with reference lines (posterior axillary line, iliac crest, 12th rib)

The retrieval of a through-and-through guidewire by ureteroscopy, grasping the antegrade wire once it reaches the view of the ureteroscope and pulling it down through the ureter/bladder/urethra, guarantees maximal safety and stability of the kidney, eliminating the risk of inadvertent loss of access during the procedure.^[13,20]

A “hydraulic” advantage of ECIRS has also been described. In fact, the *bilateral (antegrade and retrograde) irrigation*

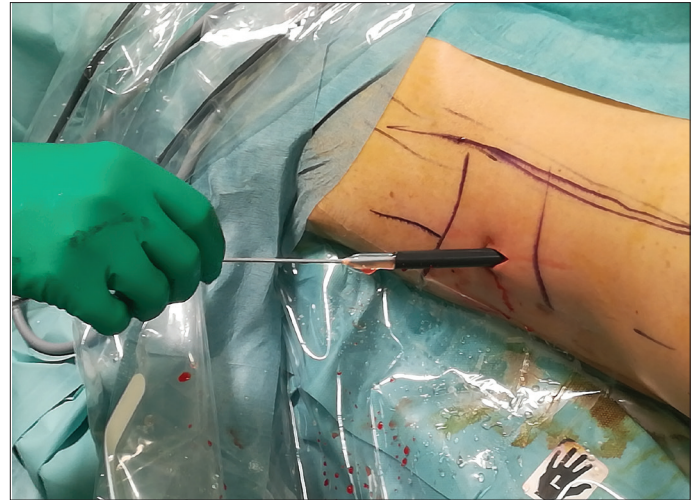


Figure 8. In the supine and supine-modified positions the Amplatz sheath is horizontal or slightly inclined downwards, favouring irrigation outflow and stone fragments drainage

of the collecting system is effective for better endoscopic vision (which might be worse in the supine positions because of the low intrarenal pressure and the easy irrigation outflow) and the spontaneous drainage of small stone fragments, also taking into account the favorable inclination of the Amplatz sheath, which is horizontal or slightly inclined downwards in the supine and supine-modified positions (Figures 7 and 8).^[1,17,20,23]

The concept of ECIRS extends beyond the diagnostic role of retrograde ureteroscopy and might well include an *active role in stone preparation, clearance, and treatment*.^[1,13,20,23] Stones lying in the ureter or in calyces parallel to the percutaneous tract might be reached retrogradely without the need for a second puncture, can be basketed and relocated for access by a rigid or flexible nephroscope, or even carried out through the Amplatz sheath with the “pass the ball” maneuver. In this case, the risk of damage to the flexible ureteroscope is reduced. Additionally, if a stone is stuck in the target calyx or its infundibulum, retrograde holmium laser lithotripsy can drill a passage through the calculus for the ureteroscope to expose the target calyx and visualize the puncture or for the descending guidewire and the free flow of irrigation.

Final exploration of all calyces is greatly improved by the cooperation of retrograde flexible ureteroscope with the antegrade rigid and flexible nephroscope, integrated by pyelography,^[1,13] making it possible to complete stone fragment removal, improve SFRs, reduce secondary procedures, and even avoid postoperative computed tomography (CT) scans.^[16]

Discussion

Stone-free rates

PNL monotherapy of large and/or complex urolithiasis usually displays rather high SFRs: generally >75% when considering standard access and the possibility of multiple tracts, being 57% for staghorn stones, 66% for complex stones, and 78% and even more for simple stones and miniaturization.^[4,8,25-28] For ECIRS, SFRs turn out to be even higher (61%–97%), especially in the case of standard accesses and smaller stones and usually through a single percutaneous access.

Generally speaking, the high variability of PNL SFRs reported in the literature (even ranging from 40% to 90%) springs from two main sets of problems: one is how the “stone-free” status is defined; the other one is how and how long after PNL it is assessed case by case.^[5,29,30]

In the selected papers, the criteria for the stone-free status are sometimes not specified,^[1,4,13,18,20] usually correspond to fragments <4 mm,^[14,17,19,21,23,24] in one case <5 mm,^[22] in another <2 mm,^[16] and, only in one article, to complete absence of residual fragments.^[15]

Some authors use only plain kidney–ureter–bladder (KUB) X-rays and/or ultrasound (US)^[17,21]; others interchange X-rays and Non Contrast Computed Tomography (NCCT)^[14,22] based on their own judgment; the majority of the authors employ NCCT (considered as the imaging with the higher sensitivity in spite of the higher exposure to ionizing radiations when compared with KUB and US^[5]), variously integrated with US, KUB, and/or endoscopic final exploration at the end of surgery.^[1,15,16,19,23,24]

The timing of such postoperative evaluation is sometimes not specified^[1,4,13,18,20,22]; it is extremely variable, ranging from the first or second postoperative day^[16,23] to 1/2,^[14,15] 4,^[17,21,23,24] or even 12 weeks^[19] after ECIRS, occasionally with both an early and a late check.^[15] The recommended time interval according to the current EAU guidelines is 4 weeks,^[5] considering that a too premature NCCT after PNL could produce false positive results from dust or residual fragments amenable to spontaneous elimination without any stone-related event.

It is credible that in traditional standard PNL, larger staghorn or multiple stones might equally require more percutaneous tracts and/or more ancillary procedures, especially in the case of miniaturized tracts,^[31] bringing the problems of the small-sized retrograde intrarenal surgery (RIRS) monotherapy into the PNL technique in terms of efficacy (speed of lithotripsy and time of stone debulking).

Additionally, it is also credible that in a single-access ECIRS, the integrated use of flexible nephroscopy and flexible retrograde ureteroscopy might represent an effective strategy to improve the one-step SFR (implying less secondary procedures, and thus less economic burden and weight on the patient’s quality of life, in spite of the requirement of two operating surgeons with two sets of equipment and ancillary instrumentation).^[4,32,33]

Complication rates

PNL monotherapy displays extremely variable CRs, ranging from 10.5% to 42% and predominantly classified as grade 1–3 according to Clavien–Dindo, when considering standard access and the possibility of multiple tracts.^[4,8] CRs can be as high as 83% in some series of standard PNL, the major ones occurring between 1.1% and 7%,^[28] and as low as 15%–19% in miniaturized approaches.^[25-27] In addition, multiple percutaneous tracts are known to increase hemorrhagic risk.^[34,35]

Similarly, ECIRS displays extremely variable CRs, ranging from 5.8% to 42%, but again predominantly of low grade. For sure, in traditional PNL as well as in ECIRS, the different complexities of stone features, anatomy of the collecting system, and patient’s factors/comorbidities might contribute to make CRs so heterogeneous, as well as the extent of the urologist’s experience and the completeness of the endoscopic armamentarium available. CRs may also be influenced by the “fussiness” in filling out the databases, and we can affirm this in our experience: in fact, in our first case series of 127 ECIRSs, we reported 38.6% CRs, including 3.9% clinically insignificant hematuria (with no hemoglobin drop, no clinical implications, and no additional measures) and 26% of transient fevers (also including transient elevation of the body temperature up to 37.5°C during the first 48 postoperative hours, with no SIRS nor urosepsis, requiring no further treatment).^[11] Excluding those events, CRs would have been more or less 10%, and in fact, later on, a new case series of 310 ECIRS displayed a 7.4% CR.^[36]

The reduced bleeding risk of ECIRS–proven by the limited hemoglobin drop and the decreased TRs, 0.5%–3% versus 6.1%–7% for the standard prone PNL and 4.3% for the supine—is evident and fully understandable because it is performed through a single tract most of the times.^[5,34,35,37] In spite of the reduced hemorrhagic risk of the miniaturized accesses,^[25-27] bleeding in ECIRS displays no evident correlation with tract size (it is hardly believable that a 24 F access, equivalent to 7.92 mm, could definitely cause more bleeding than a 18 F one, equivalent to 5.94 mm). Rather, the role of the puncture technique (papillary or nonpapillary)^[38-40] as well as the entity of intraoperative torquing^[40] might represent additional factors affecting the bleeding rate, largely dependent upon the surgeon’s skills and experience. In particular, the need for torquing the rigid nephroscope is implicitly reduced in ECIRS by the use of flexible scopes, additionally assisting a safe papillary puncture.

Infectious complications of PNL include fever (10.8% according to EAU guidelines), SIRS, and urosepsis (0.5% with high mortality rates) and range from 3% to 40%,^[4,5,18] especially in the case of bacteriuria and urinary tract infections, comorbidities such as diabetes or neurogenic bladder, renal abnormalities, multiple accesses, larger stone size, prolonged operative time, and high irrigation flow pressure. The role of intrarenal pressures during PNL might be relevant. One might think that a 30F PNL should have an optimal irrigation outflow by definition, but the truth is that many factors, including the perpendicular antigravitational positioning of the Amplatz sheath in the prone position or an unfavorable ratio between working sheath and nephroscope, might increase the working intrarenal pressures. The importance of the ratio between the access tract size and the diameter of the nephroscope used has been recognized for many years,^[41,42] and a difference of at least 4F is relevant to guarantee continuous and low-pressure irrigation outflow. Small accesses develop high intrarenal pressures and a higher risk of end organ bacterial seeding in the setting of an infected collecting system, suggesting a higher potential for infectious complications in a clinical setting.^[43] The use of miniaturized ECIRS with respect to the 4F rule actually results in a particularly low incidence of complications.^[15] Finally, the regular application of a protocol for prevention of infectious complications might practically nullify the infection risk.^[44]

Other parameters

The *decreased need for multiple accesses* in ECIRS, evident in all the selected papers, has been underlined in several circumstances since the 1990s.^[4,32,33] In fact, the adjunct of flexible nephroscopy and flexible retrograde ureteroscopy well compensate the need for multiple percutaneous tracts, also implying an increased hemorrhagic risk.^[34,35]

The *operative time*, sometimes considered longer in ECIRS, as already spotted with some biases in the past,^[37] is in the end somehow shorter. In fact, the correct way of calculating the operative time is to consider the beginning of the retrograde access as the starting point and the application of the drainages (nephrostomy, ureteral, and urethral catheters) as the final step. Patient positioning was even included in one study.^[11] The Clinical Research Office of the Endourological Society (CROES) study excluded the preliminary retrograde application of the ureteral catheter from the calculation and considered the renal puncture as the starting point, thus obtaining slightly shorter operating times for PNL when compared with ECIRS.^[37]

The *hospital stay* displays a very wide range (2–31 days) with a mean value of 6 days. We believe that this is a very evanescent parameter, because it strongly depends on local habits, “national” attitudes (try and send an Italian patient home with nephrostomy and/or urethral catheter! In contrast, in the United States,

outpatient PNL has been safely and effectively performed for moderate-sized stones, almost regardless of comorbidity status^[45]), and reimbursement modalities/health system and assistance.

As to *secondary procedures*, it is well known that patients with staghorn stones will probably require multiple PNLs or a number of second-look procedures,^[28] which should be included when calculating the global economic burden of a stone patient rather than the cost of a single ECIRS, a versatile procedure for one-step complete resolution.^[19,32]

Tips and tricks

Preliminary retrograde ureteroscopy is not particularly time-consuming (it is like putting the eye of the urologist on the tip of a retrogradely applied ureteral catheter, additionally reducing X-ray exposure) and is advantageous for the information the urologist can obtain, especially about the dynamic anatomy of the stone and the collecting system. At the same time, it does not pose a risk for the scope because the use is mainly diagnostic and can also be a very good didactic tool in an academic setting.^[3,32,33] If retrograde ureteroscopy is not possible, the indication is to avoid forcing the situation and causing long-lasting damage of a noncompliant ureter.

UAS application is not an essential step of ECIRS,^[11] because routine irrigation outflow through the Amplatz sheath is adequate and the intrarenal pressure is low. The retrograde urologist must only remember to stop irrigation in unfavorable moments such as when there is only the guidewire inside or during dilation. UAS might become useful in miniaturized accesses or when a prolonged active role of the retrograde approach is expected.

Endovision puncture is not an absolute obligation (in case of staghorn stones or obstructed infundibula do not force, risking damage to the ureteroscope). The retrograde approach can simply potentiate irrigation from below vision, and thus water path for the wire, and, later on, the spontaneous drainage of stone fragments using the washout mechanism and the transport technique, enhanced by the downward orientation of the Amplatz sheath in the supine and supine-modified positions, continuously discharging bilateral irrigation and stone fragments.^[46] In case it is possible, Endovision checks the renal puncture minimizing bleeding.^[3,20,32]

The possibility to *check under vision all the steps of the percutaneous access* allows us to reduce X-ray exposure, for the patient and all the people working in the operating theater. This is also our experience and can be further improved by paying attention and maximally avoiding fluoroscopy when it is not strictly necessary. In fact, in 2008, we reported 8.7 minutes as mean

fluoroscopy time; later on, it became 3.3 minutes in Endovision-assisted ECIRS, being 5.5 min in ECIRS during which Endovision-controlled percutaneous access was not possible.^[1,36,47]

The *retrieval of a through-and-through guidewire* by retrograde ureteroscopy guarantees maximal safety during ECIRS and stability of the kidney, resulting much more mobile in the supine positions.^[2,3] Alternatively, a retrograde guidewire can be externalized with a basket or forceps from the Amplatz sheath with the nephroscope, after a provisional guidewire coiled within the collecting system for access creation, eliminating the risk of inadvertent loss of access during the procedure.^[2,3,32,33]

The *active role of retrograde flexible ureteroscopy during ECIRS* is a minor possibility, but can occasionally contribute to solving problems or completing stone clearance (a calcified JJ stent in the bladder, a ureteric stone or stricture, calculi within a calyx parallel to the access tract or in calyces difficult to reach antegradely even with the flexible nephroscope, pass the ball technique with stone relocation, or *in situ* laser lithotripsy).^[2,3,32,33]

Final exploration of all calyces is fundamental to improve SFRs^[4] and might also reduce the use of postoperative imaging with related radiation exposure.^[2,3,16,47]

Finally, innovative roles for ECIRS are outlined in the 13 excluded case reports, underlining ECIRS versatility for encrusted stent removal and treatment of refractory staghorn stones in single kidneys, of squamous cell carcinomas and obstructing stones in calyceal diverticula, of staghorn stones in embolized kidneys, and in complex renoureteral lithiasis involving normal and ileal ureters in children.^[48-50]

In conclusion, the current evidence suggests that patients with large and/or complex urolithiasis might benefit from the adjunct of flexible nephroscopy and ureteroscopy to rigid PNL. In particular, retrograde flexible ureteroscopy during PNL plays a dual role, both diagnostic and active, allowing tailoring of the procedure to the patient, the urolithiasis, and the anatomy of the collecting system, and to optimize PNL efficacy and safety. This is ECIRS: an updated, complete, and versatile version of PNL.

Peer-review: This manuscript was prepared by the invitation of the Editorial Board and its scientific evaluation was carried out by the Editorial Board.

Author Contributions: Concept – C.M.S., C.M.C.; Design – C.M.S., C.M.C.; Supervision – C.M.S.; Materials – C.M.C.; Data Collection and/or Processing – C.M.S., C.M.C.; Analysis and/or Interpretation – C.M.S., C.M.C.; Literature Search – C.M.C.; Writing Manuscript – C.M.C.; Critical Review – C.M.S.

Conflict of Interest: Boston Scientific, Coloplast Porgés, Cook Medical, DBI, EMS, Olympus, Promed, Rocamed, Karl Storz (C.M.S.); Boston Scientific, Coloplast Porgés (C.M.C.).

Financial Disclosure: The authors declared that this study has received no financial support.

References

1. Scoffone CM, Cracco CM, Cossu M, Grande S, Poggio M, Scarpa RM. Endoscopic combined intrarenal surgery in Galdakao-modified supine Valdivia position: a new standard for percutaneous nephrolithotomy? *Eur Urol* 2008;54:1393-403. [\[Crossref\]](#)
2. Scoffone CM, Hoznek A, Cracco CM, editors. *Supine percutaneous nephrolithotomy and ECIRS*. First edition, Paris, France: Springer; 2014. [\[Crossref\]](#)
3. Scoffone CM, Cracco CM. Invited review: the tale of ECIRS (Endoscopic Combined IntraRenal Surgery) in the Galdakao-modified supine Valdivia position. *Urolithiasis* 2018;46:115-23. [\[Crossref\]](#)
4. Cracco CM, Knoll T, Liatsikos EN, Ooster PJ, Smith AD, Scarpa RM, Scoffone CM. Rigid-only versus combined rigid and flexible percutaneous nephrolithotomy: a systematic review. *Minerva Urol Nefrol* 2017;69:330-41.
5. Türk C, Neisius A, Petrik A, Seitz C, Skolarikos A, Thomas K et al. EAU guidelines on urolithiasis. <https://uroweb.org/wp-content/uploads/EAU-Guidelines-on-Urolithiasis-2020.pdf>.
6. Scoffone CM, Cracco CM. Patient positioning, the supine position and the rationale of ECIRS, chapter 11. In: Smith A, Preminger G, Kavoussi L, Badlani G editors, Wiley-Blackwell 2019. [\[Crossref\]](#)
7. Veys R, Verpoort P, Van Haute C, Wang ZT, Chi T, Taily T. Thiel-embalmed cadavers as a novel training model for ultrasound-guided supine endoscopic combined intrarenal surgery. *BJU Int* 2020;125:579-85. [\[Crossref\]](#)
8. de la Rosette J, Assimos D, Desai M, Gutierrez J, Lingeman J, Scarpa RM, Tefekli A. The Clinical Research Office of the Endourological Society Percutaneous Nephrolithotomy Global Study: indications, complications, and outcomes in 5803 patients. *J Endourol* 2011;25:11-7. [\[Crossref\]](#)
9. Sivalingam S, Cannon ST, Nakada SY. Current practices in percutaneous nephrolithotomy. *J Endourol* 2014;28:524-7. [\[Crossref\]](#)
10. Manzo BO, Lozada E, Vicentini FC, Sanchez FJ, Manzo J. Differences in the percutaneous nephrolithotomy practice patterns among Latin American urologists with and without endourology training. *Int Braz J Urol* 2017;44:512-23. [\[Crossref\]](#)
11. Moher D, Liberati A, Tetzlaff J, Altman DG, PRISMA Group. Preferred reporting items for systematic reviews and meta-analyses: the PRISMA statement. *PLoS Med* 2009;6:e1000097. [\[Crossref\]](#)
12. De la Rosette JJ, Opondo D, Daels FP, Giusti G, Serrano A, Kandasami SV, et al. Categorization of complications and validation of the Clavien score for percutaneous nephrolithotomy. *Eur Urol* 2012;62:246-55. [\[Crossref\]](#)
13. Keller EX, De Coninck V, Doizi S, Traxer O. The role of ureteroscopy for the treatment of staghorn calculi: a systematic review. *Asian J Urol* 2020;7:110-5. [\[Crossref\]](#)
14. Wen J, Xu G, Du C, Wang B. Minimally invasive percutaneous nephrolithotomy versus endoscopic combined intrarenal surgery

- with flexible ureteroscope for partial staghorn calculi: a randomized controlled trial. *Int J Surg* 2016;28:22-7. [\[Crossref\]](#)
15. Gökçe MI, Gülpınar O, Ibis M, Kubilay E, Süer E. Retrograde vs. antegrade flexible nephroscopy for detection of residual fragments following PNL: a prospective study with computerized tomography control. *Int Braz J Urol* 2019;45:581-7. [\[Crossref\]](#)
 16. Schulster M, Small AC, Silva MV, Abbott JE, Davalos JG. Endoscopic combined intrarenal surgery can accurately predict high stone clearance rates on postoperative CT. *Urology* 2019;133:46-9. [\[Crossref\]](#)
 17. Hamamoto S, Yasui T, Okada A, Takeuchi M, Taguchi K, Shibamoto Y, et al. Developments in the technique of endoscopic combined intrarenal surgery in the prone split-leg position. *Urology* 2014;84:565-70. [\[Crossref\]](#)
 18. Tabei T, Ito H, Usui K, Kuroda S, Kawahara T, Terao H, et al. Risk factors of systemic inflammation response syndrome after endoscopic combined intrarenal surgery in the modified Valdivia position. *Int J Urol* 2016;23:687-92. [\[Crossref\]](#)
 19. Yamashita S, Kohjimoto Y, Iba A, Kikkawa K, Hara I. Stone size is a predictor for residual stone and multiple procedures of endoscopic combined intrarenal surgery. *Scand J Urol* 2017;51:159-64. [\[Crossref\]](#)
 20. Isac W, Rizkala E, Liu X, Noble M, Monga M. Endoscopic-guided versus fluoroscopic-guided renal access for percutaneous nephrolithotomy: a comparative analysis. *Urology* 2013;81:251-6. [\[Crossref\]](#)
 21. Hamamoto S, Yasui T, Okada A, Taguchi K, Kawai N, Ando R, et al. Endoscopic combined intrarenal surgery for large calculi: simultaneous use of flexible ureteroscopy and mini-percutaneous nephrolithotomy overcomes the disadvantages of percutaneous nephrolithotomy monotherapy. *J Endourol* 2014;28:28-33. [\[Crossref\]](#)
 22. Nuño de la Rosa I, Palmero JL, Miralles J, Pastor JC, Benedicto A. A comparative study of percutaneous nephrolithotomy in supine position and endoscopic combined intrarenal surgery with flexible instrument. *Actas Urol Esp* 2014;38:14-20. [\[Crossref\]](#)
 23. Leng S, Xie D, Zhing Y, Huang M. Combined single-tract of minimally percutaneous nephrolithotomy and flexible ureteroscopy for staghorn calculi in oblique supine lithotomy position. *Surg Innov* 2018;25:22-7. [\[Crossref\]](#)
 24. Usui K, Komeya M, Taguri M, Kataoka K, Asai T, Ogawa T, et al. Minimally invasive versus standard endoscopic combined intrarenal surgery for renal stones: a retrospective pilot study analysis. *Int Urol Nephrol* 2020;52:1219-25. [\[Crossref\]](#)
 25. Zeng G, Zhao Z, Wan S, Mai Z, Wu W, Zhong W, Yuan J. Minimally invasive percutaneous nephrolithotomy for simple and complex renal caliceal stones: a comparative analysis of more than 10,000 cases. *J Endourol* 2013;27:1203-8. [\[Crossref\]](#)
 26. Jones P, Elmussareh M, Aboumarzouk OM, Mucksavage P, Somani BK. Role of minimally invasive (Micro and Ultra) PCNL for adult urinary stone disease in the modern era: evidence from a systematic review. *Curr Urol Rep* 2018;19:27. [\[Crossref\]](#)
 27. Kandemir E, Savun M, Sezer A, Erbin A, Akbulut MF, Sarilar Ö. Comparison of miniaturized percutaneous nephrolithotomy and standard percutaneous nephrolithotomy in secondary patients. *J Endourol* 2020;34:26-32. [\[Crossref\]](#)
 28. Gadzhiev N, Malkhasyan V, Akopyan G, Petrov S, Jefferson F, Okhunov Z. Percutaneous nephrolithotomy for staghorn calculi: troubleshooting and managing complications. *Asian J Urol* 2020;7:139-48. [\[Crossref\]](#)
 29. Prezioso D, Barone B, Di Domenico D, Vitale R. Stone residual fragments: a thorny problem. *Urologia* 2019;86:169-76. [\[Crossref\]](#)
 30. Suarez-Ibarrola R, Hein S, Miernik A. Residual stone fragments: clinical implications and technological innovations. *Curr Opin Urol* 2019;29:129-34. [\[Crossref\]](#)
 31. El-Nahas AR, Eraky I, Shokeir AA, Shome AM, el-Assmy AM, el-Tabey NA, et al. Factors affecting stone-free rate and complications of percutaneous nephrolithotomy for treatment of staghorn stone. *Urology* 2012;79:1236-41. [\[Crossref\]](#)
 32. Ghani K, Andonian S, Bultitude M, Desai M, Okhunov Z, Preminger GM, de la Rosette J. Percutaneous nephrolithotomy: update, trends, and future directions. *Eur Urol* 2016;70:382-96. [\[Crossref\]](#)
 33. Hiller SC, Ghani KR. Frontiers in stone management. *Curr Opin Urol* 2020;30:17-23. [\[Crossref\]](#)
 34. Ramón de Fata F, Pérez D, Resel-Folkersma L, Galán JA, Serano A, Servera A, et al. Analysis of the factors affecting blood loss in percutaneous nephrolithotomy: a registry of the Spanish Association of Urology in the supine position. *Actas Urol Esp* 2013;37:527-32. [\[Crossref\]](#)
 35. Arora AM, Pawar PW, Tamhankar AS, Sawant AS, Mundhe ST, Patil SR. Predictors for severe hemorrhage requiring angioembolization post percutaneous nephrolithotomy: a single-center experience over 3 years. *Urol Ann* 2019;11:180-6. [\[Crossref\]](#)
 36. Scoffone CM, Cracco CM. ECIRS (Endoscopic Combined Intra-Renal Surgery) in the Galdakao-modified supine Valdivia position. *J Urol* 2017;197(Suppl 4):e440-1. [\[Crossref\]](#)
 37. Valdivia JG, Scarpa RM, Duvdevani M, Gross AJ, Nadler RB, Nutahara K, et al. Supine versus prone position during percutaneous nephrolithotomy: a report from the Clinical Research Office of the Endourological Society Percutaneous Nephrolithotomy global study. *J Endourol* 2011;25:1619-25. [\[Crossref\]](#)
 38. Kallidonis P, Kyriazis I, Kotsiris D, Koutava A, Kamal W, Liatsikos E. Papillary vs nonpapillary puncture in percutaneous nephrolithotomy: a prospective randomized trial. *J Endourol* 2017;31(Suppl 1):S4-9. [\[Crossref\]](#)
 39. Kallidonis P, Liatsikos E. Puncture for percutaneous surgery; is papillary puncture a dogma? Yes! *Curr Opin Urol* 2019;29:470-1. [\[Crossref\]](#)
 40. Pearle MS. Puncture for percutaneous surgery: is papillary puncture a dogma? No! *Curr Opin Urol* 2019;29:472-3. [\[Crossref\]](#)
 41. Wilhelm K, Mueller PF, Schulze-Ardey J, Späth J, Suarez-Ibarrola R, Miernik A, et al. Characterization of flow-caused intrarenal pressure conditions during percutaneous nephrolithotomy in vitro. *J Endourol* 2019;33:235-41. [\[Crossref\]](#)
 42. Low RK. Nephroscopy sheath characteristics and intrarenal pelvic pressure: human kidney model. *J Endourol* 1999;13:205-8. [\[Crossref\]](#)
 43. Loftus CJ, Hinck B, Makovey I, Sivalingam S, Monga M. Mini versus standard percutaneous nephrolithotomy: the impact of sheath size on intrarenal pelvic pressure and infectious complications in a porcine model. *J Endourol* 2018;32:350-4. [\[Crossref\]](#)
 44. Scoffone CM, Cracco CM. Multimodal strategy for the prevention of infectious complications of percutaneous surgery: our experience. *J Endourol* 2013;27(Suppl 1):A86.
 45. Bechis SK, Han DS, Abbott JE, Holst DD, Alagh A, Di Pina T, et al. Outpatient percutaneous nephrolithotomy: the UC San Diego Health experience. *J Endourol* 2018;32:394-401. [\[Crossref\]](#)

46. Jung AD, Kim JC, Ahn HK, Kwon JH, Han K, Han WK, et al. Real-time simultaneous endoscopic combined intrarenal surgery with intermediate-supine position: washout mechanism and transport technique. *Inn Urol* 2018;59:348-54. [\[Crossref\]](#)
47. Cracco CM, Scoffone CM. Assessing radiation exposure during Endoscopic Combined IntraRenal Surgery (ECIRS). *J Endourol* 2015;29(Suppl 1):A314.
48. Manikandan R, Mittal JK, Dorairajan LN, Mishra AK, Sreerag KS, Verma A. Endoscopic combined intrarenal surgery for simultaneous renal and ureteral stones: a retrospective study. *J Endourol* 2016;30:1056-61. [\[Crossref\]](#)
49. Chen YC, Chen HW, Lo IS, Li CC, Shih PM, Huang TY. Management of large ureteral stone with severe ureteral tortuosity: a novel technique of “straightening” against the tortuous ureter using simultaneous supine percutaneous nephrolithotomy and retrograde semirigid ureterolithotripsy. *Int J Urol* 2018;25:896-7. [\[Crossref\]](#)
50. Keoghane SR, Deveril SJ, Woodhouse J, Shenoy V, Johnston T, Osborn P. Combined antegrade and retrograde access to difficult ureters: revisiting the rendezvous technique. *Urolithiasis* 2019;47:383-90. [\[Crossref\]](#)