

in COVID-19 patients. We are currently conducting a randomized, double-blinded, placebo controlled interventional study with 5ARis (dutasteride) as well as a novel anti-androgen (proxlutamide) in the treatment of COVID-19 (NCT04446429).

Conflicts of interest

John McCoy, PhD: Dr. McCoy, Flávio Adsuara Cadegiani, MD, PhD: Dr. Cadegiani, Carlos Gustavo Wambier, MD, PhD: Dr. Wambier, Sabina Herrera, MD, PhD: Dr. Herrera, Sergio Vaño-Galván, MD, PhD: Dr. Vano-Galvan, Natasha Atanaskova Mesinkovska, MD, PhD: Dr. Mesinkovska, Paulo Müller Ramos, MD, PhD: Dr. Ramos, Jerry Shapiro, MD: Dr. Shapiro, Rodney Sinclair, MD, PhD: Dr. Sinclair, Antonella Tosti, MD: Dr. Tosti, and Andy Goren, MD: Dr. Goren, have nothing to disclose.

Funding sources

None.

J. McCoy,^{1,*} F.A. Cadegiani,² C.G. Wambier,³ S. Herrera,⁴ S. Vaño-Galván,⁵ N.A. Mesinkovska,⁶ P.M. Ramos,⁷ J. Shapiro,⁸ R. Sinclair,⁹ A. Tosti,¹⁰ A. Goren¹

¹Applied Biology, Inc., Irvine, CA, USA, ²Department of Clinical Endocrinology, Federal University of São Paulo Medical School, Sao Paulo, Brazil, ³Department of Dermatology, Alpert Medical School of Brown University, Providence, RI, USA, ⁴Infectious Diseases Unit, Ramón y Cajal Hospital, Madrid, Spain, ⁵Dermatology Department, Ramón y Cajal Hospital, Madrid, Spain, ⁶Department of Dermatology, University of California, Irvine, CA, USA, ⁷Department of Dermatology, São Paulo State University – UNESP, São Paulo, Brazil, ⁸Ronald O. Perelman Department of Dermatology, New York University School of Medicine, New York, NY, USA, ⁹Sinclair Dermatology, Melbourne, Vic., Australia, ¹⁰Department of Dermatology and Cutaneous Surgery, Miller School of Medicine, University of Miami, Miami, FL, USA

*Correspondence: J. McCoy. E-mail: johnm@appliedbiology.com
IRB approval status: The study was approved by an ethics committee and registered with clinicaltrials.gov (NCT04446429).

References

- Wambier CG, Vaño-Galván S, McCoy J *et al*. Androgenetic alopecia present in the majority of hospitalized COVID-19 patients – the "Gabrin sign". *J Am Acad Dermatol* 2020; **83**: 680–682. <https://doi.org/10.1016/j.jaad.2020.05.079>
- Goren A, Vaño-Galván S, Wambier CG *et al*. A preliminary observation: male pattern hair loss among hospitalized COVID-19 patients in Spain – a potential clue to the role of androgens in COVID-19 severity. *J Cosmet Dermatol* 2020; **19**: 1545–1547.
- Wambier CG, Vaño-Galván S, McCoy J, Pai S, Dhurat R, Goren A. Androgenetic alopecia in COVID-19: compared to age-matched epidemiologic studies and hospital outcomes with or without the Gabrin sign. *J Am Acad Dermatol* 2020; **83**: e453–e454. <https://doi.org/10.1016/j.jaad.2020.07.099>
- Gebhard C, Regitz-Zagrosek V, Neuhauser HK, Morgan R, Klein SL. Impact of sex and gender on COVID-19 outcomes in Europe. *Biol Sex Differ* 2020; **11**: 29.
- Montopoli M, Zumerle S, Vettor R *et al*. Androgen-deprivation therapies for prostate cancer and risk of infection by SARS-CoV-2: a population-

based study (n=4532). *Ann Oncol* 2020; **31**: 1040–1045. <https://doi.org/10.1016/j.annonc.2020.04.479>

- Clark RV, Hermann DJ, Cunningham GR, Wilson TH, Morrill BB, Hobbs S. Marked suppression of dihydrotestosterone in men with benign prostatic hyperplasia by dutasteride, a dual 5 α -reductase inhibitor. *J Clin Endocrinol Metab* 2004; **89**: 2179–2184.

DOI: 10.1111/jdv.17021

Pityriasis rosea as a leading manifestation of COVID-19 infection

To the Editor

Reported cutaneous manifestation incidence during COVID-19 infection varied between countries, and a recent review showed a worldwide mean incidence of 1.7%.¹ These manifestations are polymorphic and vary dependently on the disease severity.² Few pityriasis rosea (PR) and PR-like eruptions have been reported during COVID-19 infection.^{3,4}

Herein, we report a case of PR-like eruption as a leading manifestation of COVID-19.

A 26-year-old woman with no previous medical history presented to our dermatology clinic for 1-week history of erythematous scaly annular and oval papules over the trunk in a 'Christmas tree' like pattern (Fig. 1a). The eruption was preceded with a herald annular plaque with a peripheral scaling collaret on her right thigh (Fig. 1b). The patient developed fever, cough and myalgia 48 h later. She underwent a PCR test for COVID-19, which came back positive.

In this case, PR may be directly linked to COVID-19 infection or to viral reactivation (e.g. HHV6, HHV7 and EBV) as previously reported⁵.

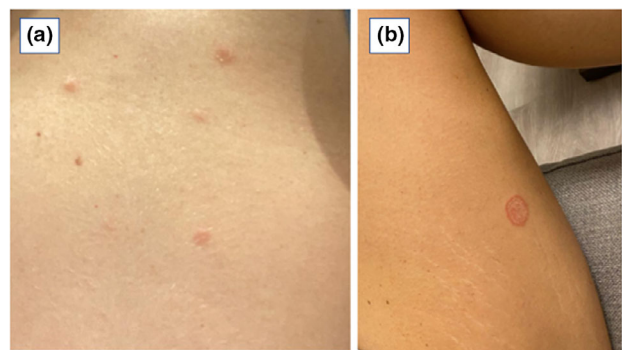


Figure 1 (a) Erythematous and scaly papules over the trunk, and (b) typical herald patch with the peripheral scaling collaret.

To our knowledge, reports on cutaneous manifestations that precede respiratory symptoms in COVID-19 are scarce. Dermatologists should be aware that cutaneous manifestations can be the presenting complaint of COVID-19 patients.

Acknowledgement


The patient in this manuscript has given written informed consent to publication of her case details.

Conflicts of interest

Dr. Merhy, Dr Sarkis and Dr Stephan have nothing to disclose.

Funding source

None.

R. Merhy,^{1,*}  A.S. Sarkis,¹ F. Stephan¹

Department of Dermatology, Hotel Dieu de France Hospital, Faculty of Medicine, Saint-Joseph University, Beirut, Lebanon

*Correspondence: R. Merhy. E-mails: reine.merhy@net.usj.edu.lb, reine.merhy@hotmail.com

References

- 1 Matar S, Oulès B, Sohier P *et al*. Cutaneous manifestations in SARS-CoV-2 infection (COVID-19): a French experience and a systematic review of the literature. *J Eur Acad Dermatol Venereol* 2020; **34**: e686–e689.
- 2 Freeman EE, McMahon DE, Lipoff JB *et al*. The spectrum of COVID-19-associated dermatologic manifestations: an international registry of 716 patients from 31 countries. *J Am Acad Dermatol* 2020; **83**: 1118–1129.
- 3 Martín Enguix D, Salazar Nieves MDC, Martín Romero DT. Pityriasis rosea Gibert type rash in an asymptomatic patient that tested positive for COVID-19. *Med Clin Engl Ed* 2020; **155**: 273.
- 4 Ehsani AH, Nasimi M, Bigdelo Z. Pityriasis rosea as a cutaneous manifestation of COVID-19 infection. *J Eur Acad Dermatol Venereol* 2020; **34**: e436–e437.
- 5 Drago F, Ciccarese G, Rebora A, Parodi A. Human herpesvirus-6, -7, and Epstein-Barr virus reactivation in pityriasis rosea during COVID-19. *J Med Virol* 2021; **93**: 1850–1851.

DOI: 10.1111/jdv.17052

Palmoplantar erythrodysesthesia: a diagnostic sign of COVID-19

Dear Editor,

Coronavirus disease 2019 (COVID-19) is a multisystemic disease with multiple symptoms. While some of them, such as respiratory problems or gastrointestinal disturbances, are common to other viral infections, others like anosmia or dysgeusia seem to be more specific of COVID-19. Cutaneous involvement appears in up to 45.65% of patients, showing different patterns.¹ We

report a non-previously described finding: palmoplantar erythrodysesthesia.

We performed a cross-sectional study between 15 March and 15 April 2020 (first Spanish pandemic peak) at a field hospital in Madrid, implemented for COVID-19 patients with mild-to-moderate pneumonia. Diagnosis was confirmed in all patients by means of positive QT-PCR or typical radiological findings. Analytical assessments, histological study and mycological culture were performed as needed whenever possible.

A total of 666 adult patients were examined. The mean age was 55.67 years; 58% were women. A total of 304 patients presented with mucocutaneous involvement (45.65%)

Palmoplantar involvement was observed in 121/304 (39.8%) patients; 22(7.2%) reported early burning sensation (erythrodysesthesia) with or without associated redness and swelling (Fig. 1a,b). Seventy-seven (25.3%) patients showed a fine and diffuse desquamation on palms and soles later in the evolution. All patients denied having any similar symptoms prior to COVID-19 disease diagnosis (Fig. 2a). Fungal cultures of plantar desquamation performed in nine patients ruled out concomitant dermatophytosis.

Interestingly, 46 (15.1%) of the patients showed reddish-to-brown macules on palms and soles (Figs 1b and 2a). Histological study performed in four patients showed a lymphocytic infiltrate within the dermis surrounding the eccrine sweat glands and blood vessels in all cases (Fig. 2b).

Mucocutaneous manifestations of COVID-19 are frequent but symptoms on palms and soles have been barely mentioned.² Although young patients with pseudo-chilblains and erythema multiforme-like findings have been largely reported, lesions were mostly present on dorsal hands and digits, occasionally associated with burning sensation.³ Interestingly, 7.2% of COVID-19 patients recalled a burning sensation as well as redness or swelling of the hands or feet shortly after COVID-19 symptoms began. SARS-CoV-2 is not the only virus that can cause redness and burning sensation on hands and feet. Several outbreaks of a poxvirus-related erythromelalgia have been reported in China. The first outbreak occurred in Wuhan in 1987, and all patients had respiratory symptoms as well as redness and swelling of the hands and feet.⁴ Also, Zika, chikungunya or HIV can show palmoplantar burning sensation and plantar desquamation.^{5,6}

Erythrodysesthesia is also a common finding in oncology patients; it is thought to be related to direct drug toxicity and inflammation of the eccrine glands.⁷ Therefore, we do not know whether this finding is related to SARS-Cov-2 infection or to symptomatic therapy. Palmoplantar desquamation was another common but previously unreported finding. We could not rule out fungal infection in all patients, but they denied its prior existence. Postinflammatory palmoplantar exfoliation has been reported in association bacterial infections and superantigens^{8,9}; however, it usually presents with larger scales and digital involvement rather than the diffuse desquamation observed in