


ATP1A3 variants and slowly progressive cerebellar ataxia without paroxysmal or episodic symptoms in children

MASAYUKI SASAKI¹  | NORIKO SUMITOMO¹ | YUKO SHIMIZU-MOTOHASHI¹ | ERI TAKESHITA¹ | KENJI KUROSAWA² | KENJIRO KOSAKI³ | KAZUHIRO IWAMA⁴ | TAKESHI MIZUGUCHI⁴ | NAOMICHI MATSUMOTO⁴

1 Department of Child Neurology, National Center of Neurology and Psychiatry, Tokyo; **2** Division of Genetics, Kanagawa Children's Medical Center, Yokohama; **3** Center for Medical Genetics, Keio University School of Medicine, Tokyo; **4** Department of Human Genetics, Yokohama City University Graduate School of Medicine, Yokohama, Japan.

Correspondence to Masayuki Sasaki, Department of Child Neurology, National Center of Neurology and Psychiatry (NCNP), 4-1-1 Ogawahigashi-cho, Kodaira, Tokyo, Japan.
E-mail: masasaki@ncnp.go.jp

This article is commented on by Ng on pages 12–13 of this issue.

PUBLICATION DATA

Accepted for publication 31st July 2020.

Published online 7th September 2020

ABBREVIATIONS

AHC	Alternating hemiplegia of childhood
CAPOS syndrome	Cerebellar ataxia, areflexia, pes cavus, optic atrophy, and sensory motor hearing loss

A heterogeneous spectrum of clinical manifestations caused by mutations in *ATP1A3* have been previously described. Here we report two cases of infantile-onset cerebellar ataxia, due to two different *ATP1A3* variants. Both patients showed slowly progressive cerebellar ataxia without paroxysmal or episodic symptoms. Brain magnetic resonance imaging revealed mild cerebellar cortical atrophy in both patients. Whole exome sequencing revealed a de novo heterozygous variant in *ATP1A3* in both patients. One patient had the c.460A>G (p.Met154Val) variant, while the other carried the c.1050C>A (p.Asp350Lys) variant. This phenotype was characterized by a slowly progressive cerebellar ataxia since the infantile period, which has not been previously described in association with *ATP1A3* variants or in *ATP1A3*-related clinical conditions. Our report contributes to extend the phenotypic spectrum of *ATP1A3* mutations, showing paediatric slowly progressive cerebellar ataxia with mild cerebellar atrophy alone as an additional clinical presentation of *ATP1A3*-related neurological disorders.

The disease causing missense variants in *ATP1A3* was first identified in families with rapid-onset dystonia parkinsonism in 2004, and since then several *ATP1A3*-related disorders have been recognized.^{1,2} Classic phenotypes include alternating hemiplegia of childhood (AHC)³ and rapid-onset dystonia parkinsonism.⁴ More recently other phenotypes have been associated with variants in *ATP1A3*, such as cerebellar ataxia, areflexia, pes cavus, optic atrophy, and sensory motor hearing loss (CAPOS syndrome),⁵ relapsing encephalopathy with cerebellar ataxia⁶/fever-induced paroxysmal weakness encephalopathy,⁷ early-onset epileptic encephalopathy,⁸ rapid-onset ataxia in childhood⁹ or adulthood,¹⁰ childhood-onset schizophrenia,¹¹ and autism spectrum disorders.¹²

Paroxysmal episodic symptoms such as transient tonic or flaccid hemiplegia, dystonia, tonic seizures, episodic cerebellar ataxia, and abnormal ocular movements are the most common symptoms in patients with *ATP1A3*-related disorders^{1,2} (Table 1), except for childhood-onset schizophrenia or autism spectrum disorders. Thus, identifying these symptoms can be helpful in clinical practice to aid in the early diagnosis of *ATP1A3*-related disorders. However, in intermittent periods between these paroxysmal symptoms, most patients with *ATP1A3*-related disorders present with persistent neurological deficits such as hypotonia, motor delay, ataxia, nystagmus, cognitive and behavioural dysfunction, or involuntary movements such as dystonia or

choreoathetosis.¹ Interestingly, less severe *ATP1A3* phenotypes have not been reported to date. Here we report two cases of *ATP1A3*-related neurological disorders with infantile-onset slowly progressive cerebellar ataxia and mild or moderate intellectual disability, but without paroxysmal episodic signs or motor fluctuation.

CASE REPORT

Two adolescent (case 1: male, 15y; case 2: female, 12y) patients from the National Center of Neurology and Psychiatry in Tokyo were studied. Ataxia was assessed using the Scale for the Assessment and Rating of Ataxia (0–40). This study was approved by the ethical committee of the National Center of Neurology and Psychiatry. Written informed consent was obtained from the parents.

Case 1

Case 1 was born after an uneventful pregnancy from non-consanguineous parents. He was able to smile at 2 months, hold his neck up at 3 months, sit without support at 8 months, walk unassisted at 24 months, and vocalize words at 22 months. He presented unsteadiness at 12 months in his sitting position. Walking was always unsteady with wide-based gait. He communicated using several words slowly and unclearly. At 15 years, his ataxic symptoms gradually became worse and he often fell while walking; he was referred to our hospital at this stage. Based on the

Wechsler Intelligence Scale for Children, his IQ was 40 and the neurological examination performed at 15 years indicated cerebellar ataxia including saccadic eye movement, ocular motor apraxia, dysarthria, dysdiadochokinesis, dysmetria, intention tremor, decomposition of movements, and wide-based gait. Deep tendon reflexes were within the normal range. His Scale for the Assessment and Rating of Ataxia score was 20. He had no positive family history. He had no telangiectasia, pes cavus, or visual/hearing disabilities. There were no signs of episodic abnormal ocular movement, seizures, dystonic events, bulbar symptoms, autonomic dysfunction, or respiratory disturbances. Brain magnetic resonance imaging (MRI) revealed pure cerebellar cortical atrophy dominantly in the vermis (Fig. 1a).

Case 2

Case 2 was born after an uneventful pregnancy from non-consanguineous parents. She was able to hold her neck up at 5 months, sit without support at 15 months, walk unassisted at 2 years 11 months, and vocalize a word at 3 years. Her walking was always unsteady. At 7 years, she went to a hospital for unsteady walking, and brain MRI revealed a slight cerebellar cortical atrophy (Fig. 1b). Increased unsteadiness was reported when she had fever by viral infection. The unsteadiness gradually increased, and she was then referred to our hospital. Neurological examination revealed mild intellectual disability, saccadic eye movement and wide-based gait, dysdiadochokinesis, dysmetria, and intention tremor. Normal deep tendon reflexes, visual acuity, and hearing ability were attested. Her Scale for the Assessment and Rating of Ataxia score was 12. She had no positive family history. She had no telangiectasia,

What this paper adds

- Novel *ATP1A3* variants are associated with slowly progressive cerebellar ataxia.
- No paroxysmal or episodic symptoms were found in our cases arising from *ATP1A3* variants.

pes cavus, or visual/hearing disabilities. There were no signs of episodic abnormal ocular movement, seizures, dystonic events, bulbar symptoms, autonomic dysfunction, or respiratory disturbances.

Both patients showed motor developmental delay, gradually progressive cerebellar ataxia, and mild intellectual disabilities.

RESULTS

Blood tests including alpha-fetoprotein, albumin, cholesterol, lactate/pyruvate, and cytosine-thymine-guanine repeats in spinocerebellar ataxia 1, 2, 3, and dentatorubral pallidolusian atrophy disclosed no abnormalities in both patients. From the clinical and examination findings, ataxia telangiectasia, mitochondrial encephalopathies, neuronal ceroid lipofuscinosis, infantile neuroaxonal dystrophy, congenital disorders of glycosylation, spinocerebellar ataxia 1, 2, 3, and dentatorubral pallidolusian atrophy were ruled out. Then, trio whole exome sequencing was carried out using previously described methodology.¹³

Variants in *ATP1A3* (NM. 152296.5) were identified by whole exome sequencing: c.460A>G: p.(Met154Val) in case 1 and c.1050C>A: p.(Asp350Lys) in case 2. These variants were confirmed by Sanger sequencing in the patients and their parents, and were found to be heterozygous de novo variants. These variants have not been reported previously, and computed analysis tools (SIFT, Polyphen2) predicted

Table 1: Main features reported in *ATP1A3*-related disorders

	AHC ^{1,2,3}	RDP ^{1,2,4}	CAPOS ⁵	RECA ⁶ /FIPWE ⁷	ROA in childhood ⁹ or adulthood ¹⁰	Present cases
Main symptoms	Repeated attacks of hemiplegia that alternate in laterality Dystonic spells Seizure-like episodes	Rapid-onset of dystonia and parkinsonism Prominent bulbar findings	Cerebellar ataxia, areflexia, pes cavus, optic atrophy, and sensorineural hearing loss	Relapsing cerebellar ataxia and/or weakness	Rapid-onset cerebellar ataxia	Slowly progressive cerebellar ataxia
Paroxysmal or episodic symptoms	Paroxysmal onset of hemiplegia Several times a month	Rapid-onset dystonia Rarely repeated	Episodic cerebellar ataxia Less than once a year	Episodic onset ataxia/weakness Less than once a year	Rapid-onset and stabilized ataxia Rarely repeated	No paroxysmal nor episodic symptoms
Cerebellar symptoms	Ataxia (slowly progressive in some cases)	Ataxia	Ataxia (recover or persistent)	Ataxia (stepwise progressive)	Ataxia (rapid-onset, stabilized)	Ataxia (insidious onset)
Brain MRI findings	Cerebellar cortical atrophy (in some cases)	Normal	Normal	Normal	Cerebellar cortical atrophy	Cerebellar cortical atrophy

AHC, alternating hemiplegia of childhood; RDP, rapid-onset dystonia parkinsonism; CAPOS, cerebellar ataxia, areflexia, pes cavus, optic atrophy, and sensorineural hearing loss; RECA, relapsing encephalopathy with cerebellar ataxia; FIPWE, fever-induced paroxysmal weakness and encephalopathy; ROA, rapid-onset ataxia; MRI, magnetic resonance imaging.

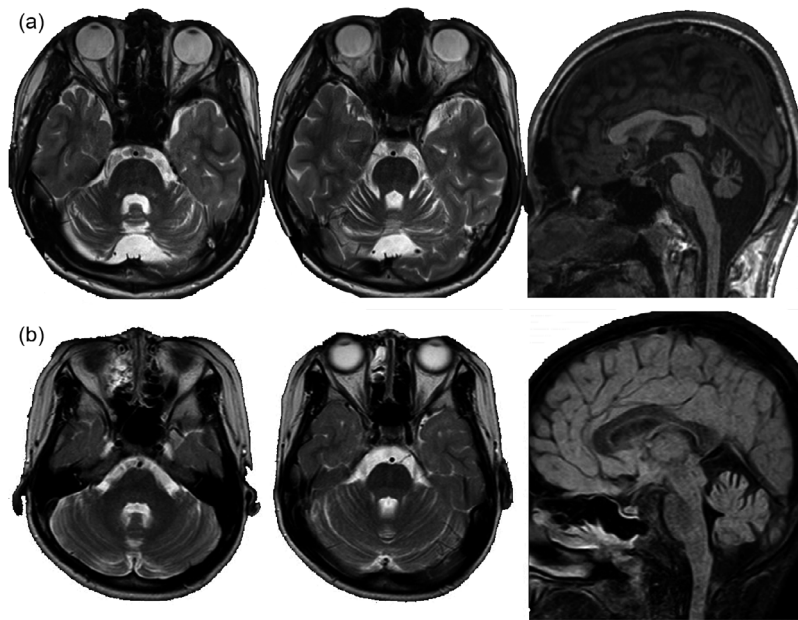


Figure 1: Brain magnetic resonance imaging (MRI) in case 1 (a) and Case 2 (b). (a) Brain MRI findings (axial; T2-weighted images, coronal; short-T1 inversion recovery, sagittal; T1) of case 1 (age 15y). Diffuse cerebellar cortical atrophy is seen predominantly in the vermis. No abnormal signal intensity is seen. (b) Brain MRI findings (axial; T2-weighted images, sagittal; fluid-attenuated inversion recovery) of case 2 (age 7y). Diffuse mild cerebellar cortical atrophy is seen. No abnormal signal intensity is seen.

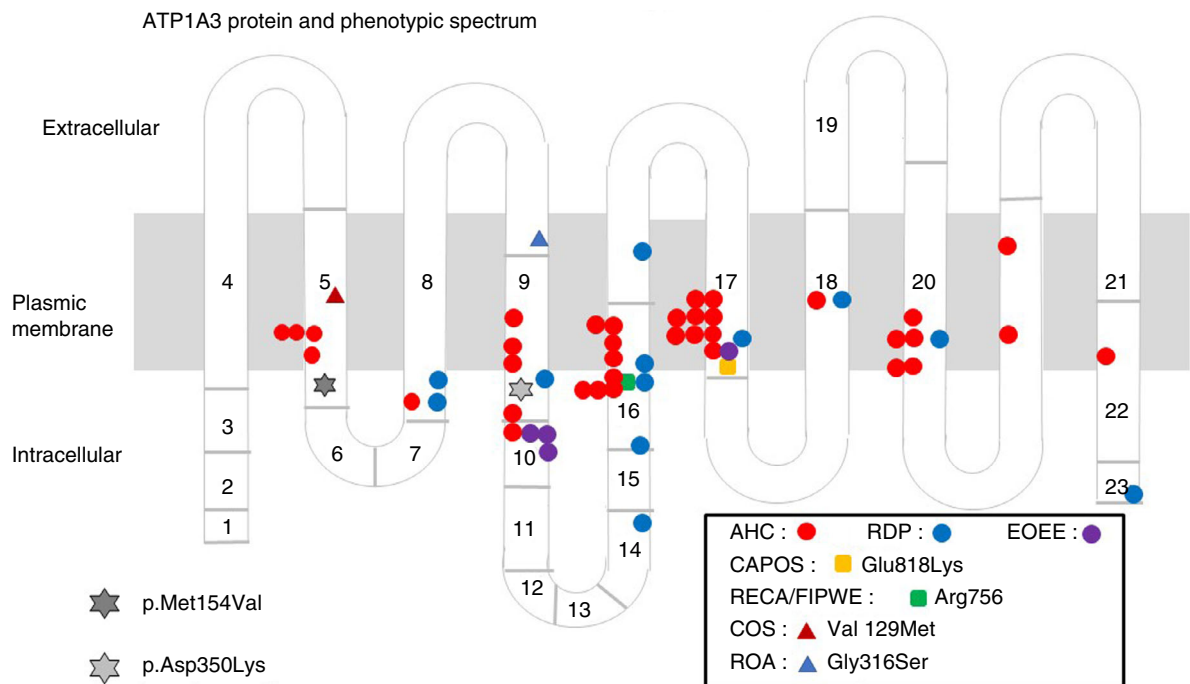


Figure 2: ATP1A3 protein and phenotypic spectrum. AHC, alternating hemiplegia of childhood; RDP, rapid-onset dystonia-parkinsonism; EOEE, early-onset epileptic encephalopathy; CAPOS, cerebellar ataxia, areflexia, pes cavus, optic atrophy, and sensorineural hearing loss; RECA/FIPWE, relapsing encephalopathy with cerebellar ataxia/fever-induced paroxysmal weakness and encephalopathy; COS, childhood-onset schizophrenia; ROA, rapid-onset ataxia.

the likely pathogenic in each. Both variants are located on the intracellular region of Na⁺/K⁺-ATPase α3 subunit (Fig. 2).

Whole exome sequencing excluded ataxia telangiectasia, ataxia-oculomotor apraxia 1/2, spinocerebellar ataxia 5/13/29, and many other autosomal dominant or recessive cerebellar ataxia disorders in childhood.

DISCUSSION

The purpose of this study was to advance the understanding of phenotypes associated with variants in *ATPIA3*. Specifically, we reported two cases with symptoms that have not been previously associated with variants in *ATPIA3*. These symptoms include infantile-onset of slowly progressive pure cerebellar ataxia and mild to moderate intellectual disability, which have not been previously reported in patients with *ATPIA3*-related disorders (Table 1). Thus, these two cases did not show any characteristic symptoms of CAPOS⁵ syndrome, relapsing encephalopathy with cerebellar ataxia⁶/fever-induced paroxysmal weakness encephalopathy,⁷ nor any paroxysmal symptoms usually seen in AHC³ and rapid-onset dystonia parkinsonism.⁴

Brain MRI in both patients revealed pure mild cerebellar cortical atrophy. In *ATPIA3*-related disorders, brain MRI abnormalities are not generally detected. However, as we previously reported,¹⁴ some patients with typical AHC show mild cerebellar cortical atrophy in adulthood. The cerebellar atrophy detected by brain MRI in both cases of the current study is similar to the atrophy previously reported in typical patients with AHC and the c.2401G>A (p.Asp801Asn) variant or c.2423C>T (p.Pro808Leu) variant in *ATPIA3*.¹⁴ Therefore, pure mild cerebellar cortical atrophy may be a trait that can help to identify progressive cerebellar ataxia cases of *ATPIA3*-related neurological disorders. The mechanisms of underlying this relation are unknown, as the Na⁺/K⁺-ATPase α3 subunit is ubiquitously expressed in the brain, including the cerebellar cortex,¹⁵ which does not explain our current finding of pure cerebellar atrophy.

Recently, some adult patients with rapid-onset ataxia were reported,¹⁰ and patients with childhood-onset ataxia-dominant with *ATPIA3* variants were also reported.⁹ However,

patients with infantile-onset and pure slowly progressive cerebellar ataxia caused by *ATPIA3* variants without any paroxysmal symptoms have not been reported. Currently, some phenotype/genotype correlations have been described. For instance, CAPOS syndrome is caused by p.Glu818Lys mutation⁵ and relapsing encephalopathy with cerebellar ataxia⁶/fever-induced paroxysmal weakness encephalopathy⁷ is caused by p.Arg756 Ser/His/Cys mutation. The mutations which cause AHC are mostly different from those causing rapid-onset dystonia parkinsonism. In AHC, a correlation between a relatively severe phenotype with the genotype of p.Glu815Lys, and a moderate phenotype with the genotype of p.Asp801Asn and p.Gln947Arg has been reported.³ In the present report, we describe for the first time two *ATPIA3* variants, namely p.Met154Val (case 1) and p.Asp350Lys (case 2). These are both located in the intracellular cytoplasmic region of the Na⁺/K⁺-ATPase, but further research is needed to clarify the potential modifications affecting the regulation of Na⁺/K⁺-ATPase.

Although based on only two patients, we believe that the symptoms reported, namely infantile-onset and slowly progressive cerebellar ataxia, could be a new subtype of *ATPIA3*-related neurological disorders. Overall, the findings have important implications for the diagnosis of spinocerebellar ataxia.

ACKNOWLEDGEMENTS

This study was in part supported by the Intramural Research Grant (30-6) for Neurological and Psychiatric Disorders of the National Center of Neurology and Psychiatry (M Sasaki), Research Committee of the Ataxia, Research on Policy Planning and Evaluation for Rare and Intractable Diseases, Health and Labour Sciences Research Grants, The Ministry of Health, Labour and Welfare, Japan (M Sasaki), the Initiative on Rare and Undiagnosed Diseases (Grant number: 17ek0109151) from the Japan Agency for Medical Research and Development (K Kurosawa, K Kosaki), AMED under the grant numbers JP19ek0109280, JP19dm0107090, JP19ek0109301, JP19ek0109348, and JP18kk020501 (N Matsumoto), and JSPS KAKENHI under the grant numbers JP17H01539 (N Matsumoto). The authors declare that there is no conflict of interest to report.

REFERENCES

1. Brashear A, Sweadner KJ, Cook JF, Swoboda KJ, Ozeilius L. *ATPIA3*-related neurologic disorders. In Adam MP, Ardinger HH, Pagon RA, editors. GeneReviews® [Internet]. Seattle (WA): University of Washington, Seattle, 1993–2019.
2. Rosewich H, Sweney MT, DeBrosse S, et al. Research conference summary from the 2014 international task force on *ATPIA3*-related disorders. *Neurol Genet* 2017; 3: e139.
3. Sasaki M, Ishii A, Saito Y, et al. Genotype-phenotype correlations in alternating hemiplegia of childhood. *Neurol* 2014; 82: 482–90.
4. Brashear A, Dobyns WB, de Carvalho Aguiar P, et al. The phenotypic spectrum of rapid-onset dystonia-parkinsonism (RDP) and mutations in the *ATPIA3* gene. *Brain* 2007; 130: 828–35.
5. Demos MK, van Karnebeek CD, Ross CJ, et al. A novel recurrent mutation in *ATPIA3* causes CAPOS syndrome. *Orphanet J Rare Dis* 2014; 9: 15.
6. Dard R, Mignot C, Durr A, et al. Relapsing encephalopathy with cerebellar ataxia related to an *ATPIA3* mutation. *Dev Med Child Neurol* 2015; 57: 1183–6.
7. Yano ST, Silver K, Young R, et al. Fever-induced paroxysmal weakness and encephalopathy, a new phenotype of *ATPIA3* mutation. *Pediatr Neurol* 2017; 73: 101–5.
8. Paciorowski AR, McDaniel SS, Jansen LA, et al. Novel mutations in *ATPIA3* associated with catastrophic early life epilepsy, episodic prolonged apnea, and postnatal microcephaly. *Epilepsia* 2015; 56: 422–30.
9. Schirinzi T, Graziola F, Nicita F, et al. Childhood rapid-onset ataxia: expanding the phenotypic spectrum of *ATPIA3* mutations. *Cerebellum* 2018; 17: 489–93.

10. Sweadner KJ, Toro C, Whitlow CT, et al. *ATPLA3* mutation in adult rapid-onset ataxia. *PLoS One* 2016; **11**: e0151429.
11. Smedemark-Margulies N, Brownstein CA, Vargas S, et al. A novel de novo mutation in *ATPLA3* and childhood-onset schizophrenia. *Cold Spring Harb Mol Case Stud* 2016; **2**: a001008.
12. Takata A, Miyake N, Tsurusaki Y, et al. Integrative analyses of de novo mutations provide deeper biological insights into autism spectrum disorder. *Cell Rep* 2018; **22**: 734–47.
13. Sekiguchi F, Tsurusaki Y, Okamoto N, et al. Genetic abnormalities in a large cohort of Coffin-Siris syndrome patients. *J Hum Genet* 2019; **64**: 1173–86.
14. Sasaki M, Ishii A, Saito Y, Hirose S. Progressive brain atrophy in alternating hemiplegia of childhood. *Mov Disord Clin Prac* 2017; **4**: 406–11.
15. McGrail KM, Phillips JM, Sweadner KJ. Immunofluorescent localization of three Na, K-ATPase isozymes in the rat central nervous system: both neurons and glia can express more than one Na, K-ATPase. *J Neurosci* 1991; **11**: 381–91.

Mac Keith Press

Practical Guide




Movement Difficulties in Developmental Disorders

Practical Guidelines for Assessment and Management

David Sugden and Michael Wade

- Guidelines are underpinned by motor learning theory, empiricism, and professional practice.
- Case studies demonstrate the adaptability of these guidelines and show how they may be applied to children of different ages, abilities, and environments.
- Includes interviews of thirteen notable clinicians and academics with intervention methodologies from around the world.

Movement Difficulties in Developmental Disorders
Practical Guidelines for Assessment and Management



October 2019 / 240 x 170mm / 240 pages / Paperback / ISBN 978-1-909962-94-1 / £39.99

www.mackeith.co.uk/shop