

# Clinical evaluation of arthrodesis with Ilizarov external fixator for the treatment of end-stage ankle osteoarthritis

## A retrospective study

Nan Ma, MD<sup>a,\*</sup> , Zhi Li, MD<sup>b</sup>, Delei Li, MD<sup>a</sup>, Yehua Hu, MD<sup>c</sup>, Ning Sun, MD<sup>d</sup>

### Abstract

To analyze the efficacy of arthrodesis with Ilizarov external fixator for the treatment of end-stage ankle osteoarthritis.

This retrospective study included 88 patients with end-stage (stage-3) ankle osteoarthritis according to Morrey–Wiedeman classification who underwent arthrodesis with Ilizarov external fixator from January 2016 to January 2019. There were 47 males and 41 females with a mean age of (57.21 ± 7.12) years old (range 49–76). Outcomes were measured by the American Orthopaedic Foot and Ankle society (AOFAS) Ankle Hindfoot Scale, Visual Analog Scale (VAS) pain scores, complications, subjective satisfaction, ankle function, correction of deformity, and complications.

With an average follow-up of (13.50 ± 5.41) months (range 10–21), all 88 patients returned for final follow-up. All patients achieved bony healing with a success rate of 100%. Mean postoperative healing time (3.56 ± 1.04) months (range 3–6). Two patients developed sinus tract infection, delayed healing in 1 patient, and 2 patients had pain and swelling again in the ankle joint. No serious complications occurred in other patients. All the patients evaluated with the VAS scores and AOFAS scores at final follow-up showed significant improvement ( $P < .05$ ). Through imaging analysis, medial tibial talar angle (MTTA) improved from (85.76 ± 6.01) degrees to (88.98 ± 1.35) degrees postoperative. Lateral talar station (LTS) decreased from (5.32 ± 3.81) mm to (2.71 ± 2.62) mm after operation ( $P < .05$ ). The overall satisfaction of patients is 88.64%.

In the treatment of end-stage ankle osteoarthritis, arthrodesis with Ilizarov external fixator can achieve good radiological and clinical outcomes with low prevalence of ankle joint malalignment and high fusion rates and satisfaction.

**Abbreviations:** AOFAS = American Orthopaedic Foot and Ankle Society, LTS = lateral talar station, MTTA = medial tibial talar angle, VAS = Visual Analog Scale Pain Scores.

**Keywords:** Ilizarov, external fixator, ankle arthrodesis, end-stage ankle arthritis

Editor: Arjun Ballal.

The patients' data were collected in the General Hospital of Jizhong energy Xingtai Mining Group Co., Ltd. The datasets used and/or analyzed during the current study are available from the corresponding author on reasonable request.

This study was conducted with approval from the General Hospital of Jizhong energy Xingtai Mining Group Co., Ltd. Written informed consent to participate was obtained from all participants.

The authors have no conflicts of interest to disclose.

The datasets generated during and/or analyzed during the current study are available from the corresponding author on reasonable request.

<sup>a</sup> Department of Orthopaedic Trauma, <sup>b</sup> Department of infection management, <sup>c</sup> Department of Rehabilitation, General Hospital of Jizhong Energy Xingtai Mining Group Co., Ltd, Xingtai, Hebei, 054000, <sup>d</sup> Department of Orthopaedic, The Third Hospital of Hebei Medical University, No. 139 Ziqiang Road, Shijiazhuang 050051, PR China.

\* Correspondence: Nan Ma, Department of Orthopaedic Trauma, General Hospital of Jizhong Energy Xingtai Mining Group Co., Ltd, 202 Bayi Street, Xindu District, Xingtai, 054000, PR China (e-mail: drtgzy@sina.com).

Copyright © 2020 the Author(s). Published by Wolters Kluwer Health, Inc. This is an open access article distributed under the terms of the Creative Commons Attribution-Non Commercial License 4.0 (CCBY-NC), where it is permissible to download, share, remix, transform, and buildup the work provided it is properly cited. The work cannot be used commercially without permission from the journal.

How to cite this article: Ma N, Li Z, Li D, Hu Y, Sun N. Clinical evaluation of arthrodesis with Ilizarov external fixator for the treatment of end-stage ankle osteoarthritis: A retrospective study. *Medicine* 2020;99:52(e23921).

Received: 25 March 2020 / Received in final form: 6 September 2020 / Accepted: 30 November 2020

<http://dx.doi.org/10.1097/MD.00000000000023921>

## 1. Introduction

Ankle osteoarthritis is one of the most common joint diseases, which is an important source of joint pain and disability for middle-aged and elderly people in the world.<sup>[1]</sup> Owing to more stress the ankle joint will bear in daily activities, it is easy to be affected by traumatic factors, leading to the occurrence of traumatic osteoarthritis.<sup>[2]</sup> In addition, rheumatoid arthritis, Kashin Beck disease, ankle deformity, and other causes of ankle disease, also can cause ankle degeneration and deformity.<sup>[3]</sup> The end-stage ankle disease will lead to ankle pain, limited activity, and affect the daily life and work of patients.<sup>[4]</sup> Although the arthroplasty technique is constantly updated and developed and gradually recognized by patients especially in Western countries, the application is relatively restricted in developing countries due to some certain limitations such as high requirements for indications, high technical requirements for the operator, and high price.<sup>[5]</sup> For advanced ankle osteoarthropathy, compared with ankle replacement, ankle arthrodesis is one of the most common treatments and is also the gold standard of current treatment.<sup>[6,7]</sup>

Ankle arthrodesis was first proposed in 1879. There are many specific methods of ankle arthrodesis, including traditional open fusion and internal fixation, arthroscopic fusion and internal fixation, minimally invasive small incision fusion and internal fixation, and ankle arthrodesis with external fixation.<sup>[8]</sup> Up to now, many ankle surgeons still regard ankle arthrodesis as a gold standard in treatment of traumatic ankle arthritis due to its effects

of preventing disease progression, relieving the ankle pain, and stabilizing the ankle.<sup>[9]</sup> However, with the development of medical conditions and the increasingly higher demanding of health care, more attention has been paid to the function improvement of ankle joint. Some scholars pointed out that ankle arthrodesis will lead to the biomechanical changes around the joint, increase the abnormal stress of the adjacent joint, cause pain and walking disorder, further accelerate the degeneration of the adjacent joint, thus affecting the functional recovery and long-term effect of the patients.<sup>[10]</sup> Moreover, according to different fixation methods and studies, the reported rate of ankle fusion nonunion varies, even up to 50%.<sup>[11]</sup>

Based on the theory of “retraction osteogenesis,” the technique of ankle arthrodesis with Ilizarov’s external fixator was first proposed by Ilizarov in 1976. It is mainly applied to the serious foot and ankle diseases with complex deformities and poor soft tissue conditions, and the deformities are corrected at the same time of fusion, with good results.<sup>[12]</sup> Compared with internal fixation, Ilizarov instrument can significantly reduce the incidence of soft tissue necrosis and increase the stability of ankle fusion, although it usually needs a larger surgical range and the operation is more complex.<sup>[13]</sup>

In order to understand the clinical effect of Ilizarov external fixator assisted ankle fusion in the treatment of end-stage ankle osteoarthritis, this study analyzed the functional recovery and pain improvement, the success rate of fusion, the incidence of complications, and the correction of combined deformities of the patients by retrospective study of Ilizarov external fixator assisted ankle arthrodesis. This study will provide more reference for the clinical practice.

## 2. Methods

For every patient with ankle osteoarthritis, arthrodesis is the most helpless choice. All the treatment plans will be explained to the patients in detail. From January 2016 to January 2019, patients with end-stage ankle osteoarthritis who underwent ankle arthrodesis with Ilizarov external fixator were studied retrospectively. The institutional review board approved the study, and all patients provided informed consent for study.

**Inclusion criteria:** Patients with end-stage ankle osteoarthritis underwent arthrodesis using Ilizarov external fixator were included in this study (the classification standard of ankle arthritis was in accordance with Morrey–Wiedeman radiological staging for arthritis<sup>[14]</sup> and showed in Table 1). Pain and swelling of ankle joint, no significant improvement after long-term conservative treatment; hyperosteoegeny of ankle joint in X-ray or CT imaging, destruction of cartilage, and reduced tibiotalar joint space; no surgical procedure performed on ankle joint and foot before admission; informed consent signed and long-term follow-up accepted by the patient.

**Exclusion criteria:** Patient did not receive ankle arthrodesis with Ilizarov external fixator. Peripheral vascular disease; active

infection in ankle joint; ankle fracture history; peripheral neuropathy involved in ankle joint, charcot neuroarthropathy; lymphedema and venous insufficiency; severe medical diseases; mental disorders.

Eighty-eight patients with end-stage (stage-3) ankle osteoarthritis were treated with Ilizarov external fixator assisted ankle arthrodesis. There were 47 males and 41 females from 49 to 76 years old, with an average age of  $57.21 \pm 7.12$  years. The body mass index (BMI) ranged from 21.48 to 35.08 kg/m<sup>2</sup>, with an average of  $(27.92 \pm 2.96)$  kg/m<sup>2</sup>. Included 42 cases of ankle osteoarthritis, 35 cases of traumatic arthritis, 1 case of rheumatoid arthritis, 4 cases of talipes equinovarus, and 6 cases of others. According to the stage of Morrey–Wiedeman’s ankle arthritis,<sup>[14]</sup> there were 88 cases in 3-stage in this study.

## 3. Operative procedures

After successful anesthesia, the patient was placed in the supine position and a thigh tourniquet was applied. After the regular disinfection with iodine and alcohol, a longitudinal incision about 8 cm was made in the front median of the ankle joint and then cut the calf deep fascia and extensor retinaculum; protect the extensor digitorum longus and musculus extensor hallucis longus and explore the neurovascular bundle in the medial side of the musculus extensor hallucis longus; then pulled the extensor digitorum longus outward, and the neurovascular bundle and the extensor digitorum longus were pulled medially; the joint capsule was opened longitudinally to expose the ankle joint. Then use a curette to carefully cleaned the hardened bone and articular cartilage until fresh blood oozes out from the articular surface; correct the varus or valgus deformity, and implanted the small pieces of autogenous bone in the joint space of the patient. Afterwards, a drainage tube was placed and the incision was sutured.

The ankle joint was placed in neutral position and the initial traction frame was formed by 2 rings, the proximal ring 5 cm below the knee and the distal ring 5 cm above the ankle, each of which was fixed perpendicular to the tibia with 2 kirschner wires. Then the rings were connected with 4 threaded rods. The other 2 kirschner wires were fixed on the heel bone at 45° angle, and the kirschner wires were tightened on the u-shaped foot ring. A kirschner wire was pulled through the metatarsal bone and fixed on the forefoot half-ring. The forefoot half-ring and u-shaped ring were connected as the pedal. It should be parallel to the axis of the foot. Then 4 Ilizarov retractor rods would be used to connect the foot to tibia. Under the fluoroscopy of the C-arm X-ray machine, the fixed position of the ankle joint could be carefully adjusted, that is, flexion and extension must be in neutral position with varus 5°, external rotation 5°; the talus was slightly moved backward under the tibia, and no dorsiflexion was allowed.

### 3.1. Postoperative management

Prevention of infection by routine antibiotics was used in perioperative period. Iodine volts wipes are used to the pin sites to prevent infection; meanwhile, isometric quadriceps contraction and toes stretching exercise should be done to prevent deep vein thrombosis of lower extremities. The ankle joint was fixed in neutral position for 6 weeks, and after 12 weeks, the weight-bearing walk was started according to the patient’s condition. The patients with poor soft tissue conditions and severe swelling

**Table 1**  
Morrey–Wiedeman radiological staging for arthritis.

Stages	X-ray imaging manifestations
0	No radiographic features of OA are present
1	Slightly narrowed joint space with osteophyte formation
2	Moderately narrowed joint space with osteophyte formation
3	Significantly narrowed joint space with osteophyte formation

and bleeding of the wound, which affect the wound healing, should delay the load-bearing time of the affected limb. X-ray films were reexamined after operation. For patients with poor alignment, ankle alignment could be adjusted by external fixator in the early stage. For patients with inadequate bone surface contact, the external fixator can be used to compress and fuse the bone surface for many times in the early stage to promote bone healing. Patients were followed up regularly in outpatient department, and the possible complications and bone healing were monitored and recorded. After the clinical and imaging examination confirmed the bone healing, the external fixation frame was powered and the patient was asked to bear the weight for 72 hours. After no pain and discomfort, the external fixation frame was removed and normal activities were resumed. The anteroposterior and lateral ankle joint X-rays should be taken at 1, 3, 6, and 12 months after surgery to understand the fusion.

### 3.2. Clinical outcome assessment and data collection

During the follow-up period, the American Orthopedic Foot & Ankle Society (AOFAS) Ankle-Hindfoot Scale and the Visual Analog Scale (VAS) were pre- and postoperative used to determine clinical outcomes and associated levels of pain.

The AOFAS score mainly includes ankle pain, function, and force line evaluation and has a maximum score of 100. An ankle evaluation of 90 to 100 points indicates that the outcome is excellent, 80 to 89 points is a good outcome, 70 to 79 is a fair outcome, and 70 points or less means poor recovery after surgery. The VAS score ranges from 0 to 10 points, with no pain being 0 points, mild pain being 1 to 3 points, moderate pain being 4 to 6 points, and severe pain being 7 to 10 points.

Patients' satisfaction was evaluated from the appearance, function, and pain of ankle joint, and the results included excellent, good, fair, poor.<sup>[15]</sup> (Evaluative criteria is showed in Table 2.)

Another important index of follow-up is the healing after ankle arthrodesis, whether delayed union or nonunion, and whether there is continuous trabecular bone passing between tibia and talus. The angle between tibia and talus was measured pre- and

postoperation. (The angle between the central axis of tibia and the medial apex of talus.)

### 4. Statistical analysis

The statistical analysis was performed using the data analysis program SPSS Statistics version 24.0 software (version 24.0 for Windows; SPSS, Inc., Chicago, IL). Data normality was assessed by the Kolmogorov–Smirnov test. The paired *t* test and Wilcoxon's signed-rank test were used to compare pre- and postoperative values (AOFAS ankle-hindfoot scores, VAS scores, radiological measurements). Statistical significance was accepted for *P* values < .05.

### 5. Results

All 88 patients were followed up for 10 to 21 months, with an average of (13.50±5.41) months. Most patients achieved satisfactory results at the last follow-up. In the feedback of patients' satisfaction, 60 patients (68.18%) chose the "Excellent," 18 patients (20.45) chose the "Good," 8 patients (9.09%) chose the "Fair," only 2 patients (2.27%) chose the "Poor," and the overall satisfaction rate (Excellent+Good) was 88.64%. At 6 months after surgery, the 2 patients had improved ankle pain and swelling, and statistically significant differences, but with the prolonged follow-up time, the 2 patients had pain and swelling again in the ankle joint.

The ankle joint function and pain symptoms of the patients also improved significantly after operation. AOFAS score of ankle and hind foot increased from (39.00±8.34) before operation to (80.65±8.86) after operation, and VAS score decreased from (6.25±0.91) before operation to (0.80±0.77) after operation.

All of the 88 patients had bone healing finally, and the successful rate of fusion was 100%. The average healing time was (3.56±1.04) months ranging from 3 months to 6 months. One patient, at 2 months after surgery, X-ray of the ankle joint showed that there was less trabecular bone between the tibia and the talus, and bone healing was achieved after 1 month of extracorporeal shock wave treatment of which 2 patients developed sinus tract infection 15 days after surgery and healed after dressing change and no other serious complications occurred.

At the last follow-up, the imaging results showed that the patients' condition of varus of ankle and anteversion of talus were significantly improved after operation, and the difference was statistically significant (*P* < .05). The angle of medial tibial talar angle (MTTA) increased from (85.76±6.01) degrees preoperative to (88.98±1.35) degrees postoperative. Lateral talar station decreased from (5.32±3.81)mm to (2.71±2.62)mm (Table 3 and Fig. 1).

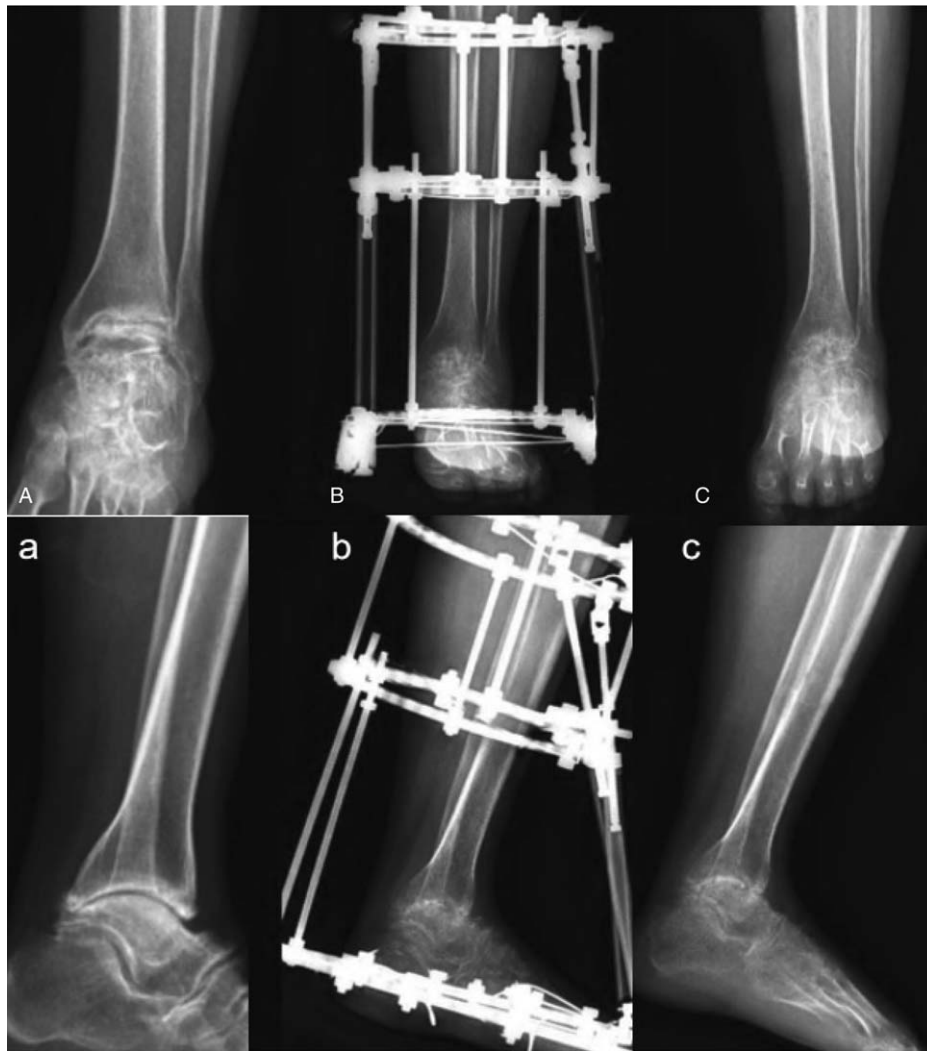
**Table 2**  
Clinical rating scale for postoperative foot and ankle.

Rating	Description
Excellent	Full range of motion equal to the contralateral ankle without pain. Unrestricted work or sports activity.
Good	Functional range of motion and stable ankle. With minimal pain with work or sport activity.
Fair	Functional range of motion, good stability, moderate level of pain, and/or stiffness with activities of daily living and sports activity.
Poor	Persistent pain, the same or worse than before surgery.

**Table 3**  
Preoperative and final follow-up values of the assessed variables (n=88).

Index	Preoperative	Last follow-up	Test statistic	<i>P</i> value
AOFAS	39.00±8.34	80.65±8.86	-25.874	<i>P</i> < .05
VAS	6.25±0.91	0.80±0.77	20.115	<i>P</i> < .05
MTTA° ( $\bar{x} \pm s$ )	85.76±6.01	88.98±1.35	-8.259	<i>P</i> < .05
LTS° ( $\bar{x} \pm s$ )	5.32±3.81	2.71±2.62	10.248	<i>P</i> < .05

AOFAS=American Orthopaedic Foot and Ankle Society, LTS=lateral talar station, MTTA=medical tibial talar angle, VAS=Visual Analog Scale.



**Figure 1.** (A–C) Anteroposterior X-ray of ankle joint: preoperation, postoperation, and remove the external fixator. (a–c) Lateral position: Preoperation, postoperation, and remove the external fixator. Preoperation, the joint space became narrower, the osteochondral was destroyed, osteophyte formation, and marginal hyperplasia were seen. Postoperation, the ankle joint was fused and the angle between tibiotalar joints was appropriate, and the deformity was corrected.

## 6. Discussion

Ankle osteoarthritis is a kind of degenerative disease, which is caused by a variety of factors. The most common clinical disease is traumatic arthritis. The main clinical manifestations are swelling of ankle joint, pain, and limitation of movement in different degrees. In severe cases, ankle joint deformity and loss of function may occur. The incidence rate of ankle osteoarthritis is lower than that of knee joint and hip joint arthritis, but its influence on the quality of life of patients is similar to that of hip arthritis, even more than that of knee osteoarthritis.<sup>[16]</sup> The end-stage ankle arthritis makes the patients in a state of loss of function. The patients have experienced long-term pain, sustained functional damage, and poor quality of life. At present, the treatment methods for the end-stage ankle include ankle fusion, ankle traction, and total ankle replacement.

The formation mechanism of traumatic ankle arthritis is complex. In order to achieve good clinical effect, the operation should be individually designed according to the age of patients, clinical symptoms, auxiliary examination, and especially different stages of ankle diseases. At present, there is no specific grading

method for ankle arthritis, but Morrey–Wiedeman classification for ankle arthritis (0–3 stage) is worthy of reference, among which stage-0 has no imaging abnormality, stage-1 is early stage, stage-2 is middle stage, and stage-3 is end stage.

The internationally recognized gold standard for the treatment of ankle joint disease in the end stage is ankle arthrodesis. Although ankle arthrodesis makes ankle joint lose its proper function, it cannot be replaced by other treatments in the correction of ankle joint deformity, relief, or even elimination of pain. Ankle arthrodesis is an important method to relieve pain and improve function. At present, there are various surgical methods such as arthroscopic-assisted fusion, open fusion, internal fixation, external fixation, etc.<sup>[17]</sup> Open fusion and internal fixation require secondary removal of the internal fixation with higher risks. While for ankle arthrodesis, the Ilizarov material can be fixed through the non-affected sites around ankle joint to avoid infection especially for patients with poor soft tissue conditions or co-infection.<sup>[18]</sup> Biomechanically, Ilizarov external fixation has a high stability, which can help patients to carry out weight-bearing training as soon as possible;



at the same time, this device can also perform axial activity. Through continuous compression, it can improve the fusion rate and restore the force line of the foot and lower extremity. The technical advantages include not only the timely adjustments of the external fixation frame to avoid posterior movement of the talus but a good therapeutic effect for patients with ankle contracture and deformity. In this group, all patients were fixed with external fixator, including 2 patients who had undergone revision operation due to the failure of ankle fusion before. The average postoperative bone healing rate was about 3.7 months, which indicated that Ilizarov external fixator was effective in the success rate of fusion.

The fixation time of external fixator after ankle fusion is related to the initial disease, the state of bone and soft tissue and whether other operations are performed at the same time. The fixation time is 9 to 92 weeks, most of which can be removed safely in 19 to 21 weeks.<sup>[19]</sup> The average removal time of the patients in this group was about 16 weeks after the operation. Only 6 patients had infection of the needle channel, delayed healing, and swelling of the wound, without serious complications. The lower incidence of complications was also consistent with other research results.<sup>[20]</sup> Ilizarov external fixation has the characteristics of strong fixation and allowing axial load compression, which is conducive to the early load-bearing activities of patients after ankle fusion and promotes bone healing. The wearing time of external fixator reduced, which is also conducive to the early recovery of normal life and work. Ankle osteoarthropathy at the end of the period will lead to the abnormal force line of ankle joint, among which the most common is varus malleolus. The previous literature reported that the angle of MTTA was 84.9° to 88.8°. About 49% of the patients had varus deformity.<sup>[21]</sup> Compensatory valgus of subtalar joint is often found in ankle varus deformity. Researchers have found that about 58% of patients with ankle osteoarthritis have compensatory valgus of subtalar joint. If the ankle fusion is in the pronation position, the long-term compensatory valgus will lead to the abnormal stress of subtalar joint. It is easy to change the osteoarthritis of subtalar joint, which will affect the long-term effect of ankle fusion. Therefore, the ankle fusion should be in neutral 0° to 5°.<sup>[22]</sup> In addition, talus forward movement will also affect the normal gait of patients, resulting in slower pace and increased energy consumption. Therefore, Paley and others suggested that talus forward movement should be eliminated as much as possible to avoid possible problems during ankle fusion surgery. The mean preoperative MTTA was 86.84°. In accordance with the results of previous studies, the postoperative MTTA was corrected to 89.90°. The talus forward movement decreased from 5.50 mm before operation to 2.85 mm after operation, which corrected the alignment and alignment of ankle joint.<sup>[23]</sup>

AOFAS Ankle Hindfoot Scale is one of the scoring standards proposed by the American Orthopedic ankle association to evaluate ankle function. He assessed ankle and hind foot function in terms of pain, functional and autonomic activity, maximum walking distance, ground walking, abnormal gait, fore-and-aft activity, hind foot activity, ankle and hind foot stability, and foot alignment. Vas is one of the commonly used pain scoring standards. The full name is visual simulation scoring method. The pain is divided into 10 points, 2 points for no pain, 10 points for severe pain, and the middle part for different degrees of pain. Ask the patient to mark the horizontal line according to their feelings to indicate the degree of pain, 2 to 4 points for mild pain, 5 to 7 points for moderate pain, 8 to 9 points for severe pain. In this

study, patients who received arthrodesis with Ilizarov external fixator for the treatment of end-stage ankle osteoarthritis achieved higher satisfaction. And there were significant differences in AOFAS, VAS scores between pre- and postoperative assessments ( $P < .05$ ). All the scores showed a rising trend in 1 year and final follow-ups.

It is undeniable that there are some deficiencies in this study. This study is a retrospective study. This study is a retrospective study with a short follow-up time. It also lacks the long-term follow-up results of large groups of cases. It does not routinely carry out weight-bearing position and axial film of calcaneus. Therefore, it is unable to evaluate the angle between tibia and plantar plane and calcaneus valgus. In addition, it is also lack of comparative analysis of the effect of ankle fusion with internal fixation. Further research is needed in the future to better clarify the external fixation of ankle joint advantages and possible problems of fusion.

## 7. Conclusion

To sum up, arthrodesis with Ilizarov external fixator for the treatment of end-stage ankle osteoarthritis has a high success rate of bone healing, and can correct the combined ankle joint alignment and alignment abnormalities. It can also improve the ankle joint function of patients effectively, and have a therapeutic effect.

## Author contributions

Nan Ma designed the study; Zhi Li and Ning Sun inquired the EMR for variables of interest; Delei Li and Yehua Hu searched relevant literature and analyzed and interpreted the data; Nan Ma wrote the manuscript; and Nan Ma approved the final version of the manuscript.

**Data curation:** Zhi Li, Delei Li.

**Investigation:** Nan Ma, Zhi Li, Ning Sun.

**Methodology:** Nan Ma, Delei Li, Yehua Hu, Ning Sun.

**Resources:** Zhi Li, Delei Li, Yehua Hu.

**Supervision:** Nan Ma, Delei Li, Yehua Hu.

**Writing – original draft:** Nan Ma.

**Writing – review & editing:** Nan Ma.

## References

- [1] Daniels T, Thomas R. Etiology and biomechanics of ankle arthritis. *Foot Ankle Clin* 2008;13:341–52. vii.
- [2] Thomas RH, Daniels TR. Ankle arthritis. *J Bone Joint Surg Am* 2003;85f51:923–36.
- [3] Khlopas H, Khlopas A, Samuel LT, et al. Current concepts in osteoarthritis of the ankle: review. *Surg Technol Int* 2019;35:280–94.
- [4] Glazebrook M, Daniels T, Younger A, et al. Comparison of health-related quality of life between patients with end-stage ankle and hip arthrosis. *J Bone Joint Surg (Am)* 2008;90:499–505.
- [5] Morash J, Walton DM, Glazebrook M. Ankle arthrodesis versus total ankle arthroplasty. *Foot Ankle Clin* 2017;22:251–66.
- [6] Stapleton JJ. Foot and ankle arthrodesis. *Clin Podiatr Med Surg* 2017;34:xi.
- [7] Slater GL, Sayres SC, O'Malley MJ. Anterior ankle arthrodesis. *World J Orthop* 2014;5:1–5.
- [8] Nihal A, Gellman RE, Embil GM, et al. Ankle arthrodesis. *Foot Ankle Surg* 2008;14:1–0.
- [9] Mendicino SS, Kreplick AL, Walters JL. Open ankle arthrodesis. *Clin Podiatr Med Surg* 2017;34:489.
- [10] Ling JS, Smyth NA, Fraser EJ, et al. Investigating the relationship between ankle arthrodesis and adjacent-joint arthritis in the hindfoot: a systematic review. *J Bone Joint Surg Am* 2015;97:513–20.
- [11] Perlman MH1, Thordarson DB. Ankle fusion in a high risk population: an assessment of nonunion risk factors. *Foot Ankle Int* 1999;20:491–6.

- [12] Fragomen AT, Borst E, Schachter L, et al. Complex ankle arthrodesis using the Ilizarov method yields high rate of fusion. *Clin Orthop Relat Res* 2012;470:2864–73.
- [13] Morasiewicz P, Dejneq M, Orzechowski W, et al. Clinical evaluation of ankle arthrodesis with Ilizarov fixation and internal fixation. *BMC Musculoskelet Disord* 2019;20:167.
- [14] Morrey BF Jr WG. Complications and long-term results of ankle arthrodeses following trauma. *J Bone Joint Surg Am* Vol 1980;62:777.
- [15] Paterson KL, Gates L. Clinical assessment and management of foot and ankle osteoarthritis: a review of current evidence and focus on pharmacological treatment. *Drugs Aging* 2019;36:203–11.
- [16] Usulli FG, D'Ambrosi R, Manzi L, et al. Treatment of ankle osteoarthritis with total ankle replacement through a lateral transfibular approach. *J Vis Exp* 2018;56396.
- [17] Raikin SM, Rasouli MR, Espandar R, et al. Trends in treatment of advanced ankle arthropathy by total ankle replacement or ankle fusion. *Foot Ankle Int* 2014;35:216–24.
- [18] Paley D, Lamm B, Katsenis D, et al. Treatment of malunion and nonunion at the site of an ankle fusion with the Ilizarov apparatus. Surgical technique. *J Bone Joint Surg Am* 2005;87:302–9.
- [19] Morasiewicz P, Dejneq M, Urbanski W, et al. Radiological evaluation of ankle arthrodesis with Ilizarov fixation compared to internal fixation. *Injury* 2017;48:1678–83.
- [20] Hasan O, Fahad S, Sattar S, et al. Ankle arthrodesis using Ilizarov ring fixator: a primary or salvage procedure? An analysis of twenty cases. *Malays Orthop J* 2018;12:24–30.
- [21] Wang B, Saltzman CL, Chalayan O, et al. Does the subtalar joint compensate for ankle malalignment in end-stage ankle arthritis? *Clin Orthop Relat Res* 2015;473:318–25.
- [22] Khanfour AA. Versatility of Ilizarov technique in difficult cases of ankle arthrodesis and review of literature. *Foot Ankle surg* 2013;19:42–7.
- [23] Paley D, Lamm BM, Katsenis D, et al. Treatment of malunion and nonunion at the site of an ankle fusion with the Ilizarov apparatus. Surgical technique. *J Bone Joint Surg(Am)* 2006;88:119–34.