

Myasthenia gravis: MuSK MG, late-onset MG and ocular MG

Feza Deymeer

Department of Neurology, Istanbul Medical Faculty, Istanbul University, Istanbul, Turkey

Myasthenia gravis (MG) is an autoimmune disease of the neuromuscular junction which affects all striated muscles, resulting in fluctuating weakness. Approaching MG as a disease with subgroups having different clinical, serological and genetic features is crucial in predicting the progression and planning treatment. Three relatively less frequently seen subtypes of MG are the subject of this review: MG with anti-MuSK antibodies (MuSK MG), non-thymomatous late-onset MG (LOMG), and ocular MG (OMG). In addition to reviewing the literature, mainly from a clinical point of view, our experience in each of the subgroups, based on close to 600 patients seen over a 10 year period, is related. MuSK MG is a severe disease with predominant bulbar involvement. It is more common in women and in early-onset patients. With the use of high dose corticosteroids, azathioprine and more recently rituximab, outcome is favorable, though the patients usually require higher maintenance doses of immunosuppressives. LOMG with onset \geq 50 years of age is more common in men and ocular onset is common. Frequency of anti-AChR and anti-titin antibodies are high. Although it can be severe in some patients, response to treatment is usually very good. OMG is reported to be more frequent in men in whom the disease has a later onset. Anti-AChR antibodies are present in about half of the patients. Generalization is less likely when symptoms remain confined to ocular muscles for 2 years. Low dose corticosteroids are usually sufficient. Thyroid disease is the most common autoimmune disease accompanying all three subgroups.

Received: November 17, 2020
Accepted: November 17, 2020

Correspondence

Feza Deymeer

Department of Neurology, Istanbul Medical Faculty, Istanbul University, Istanbul, Turkey. Tel.: 90 532 6049534
E-mail: fezadeymeer@gmail.com

Conflict of interest

The Author declares no conflict of interest

How to cite this article: Deymeer F. Myasthenia gravis: MuSK MG, late-onset MG and ocular MG. Acta Myol 2020;39:345-52. <https://doi.org/10.36185/2532-1900-038>

© Gaetano Conte Academy - Mediterranean Society of Myology



OPEN ACCESS

This is an open access article distributed in accordance with the CC-BY-NC-ND (Creative Commons Attribution-NonCommercial-NoDerivatives 4.0 International) license. The article can be used by giving appropriate credit and mentioning the license, but only for non-commercial purposes and only in the original version. For further information: <https://creativecommons.org/licenses/by-nc-nd/4.0/deed.en>

Key words: Myasthenia gravis, MuSK MG, Late-onset MG, Ocular MG

Introduction

Myasthenia gravis (MG) is an autoimmune disease of the neuromuscular junction which affects all striated muscles, resulting in fluctuating weakness¹. MG is mostly caused by antibodies against the acetylcholine receptor (AChR) and rarely by antibodies against muscle specific kinase (MuSK). In some of the patients without any detected antibodies (seronegative MG, SN MG), anti-AChR and anti-MuSK antibodies can be found with finer techniques². The clinical significance of anti-LRP4 antibodies, many times co-existing with the classical antibodies in the same patient, is unknown.

Approaching MG as a disease with subgroups having different clinical, serological and genetic features³⁻⁵ is crucial in predicting the progression and planning treatment. MG is associated with thymoma in 10-15% of patients. Among those without a thymoma, the largest subgroup consists of young women (age < 50 years) with anti-AChR antibodies. An increasingly important subgroup is MG with later onset (\geq 50 years). A very small subgroup is caused by antibodies against the MuSK antigen. MG usually tends to affect the oculobulbar and extremity muscles in all

of these patients. In a small subgroup, it affects only the ocular muscles.

Three relatively less frequently seen subtypes of MG are the subject of this review: MG with anti-MuSK antibodies (MuSK MG), late-onset MG (LOMG), and ocular MG (OMG). Attempt was made to define the subgroups carefully with particular attention given to distinguishing generalized from ocular disease. In addition to reviewing the literature, mainly from a clinical point of view, our experience in each of the subgroups, based on close to 600 patients seen over a 10 year period, is related. To put our data on the subgroups into perspective, it is necessary to describe our cohort first.

Istanbul University MG cohort

Our cohort consisted of 576 patients, derived from our MG Database, who applied for the first time to the Neuromuscular Outpatient Clinic, Neurology Department, Istanbul Medical Faculty, Istanbul University (IU) during a 10 year period between 2001 and 2010. It is an unselected group with consecutive patients, subjected to the same criteria for inclusion in a set period of time.

Some patients with MuSK MG from this cohort were reported in two articles ^{6,7}, they consisted of all MuSK MG patients seen until 2005 ⁶ and until 2009 ⁷. Patients with LOMG in this cohort were also reported ⁸. A manuscript on ocular MG, again with patients in this cohort, is in preparation.

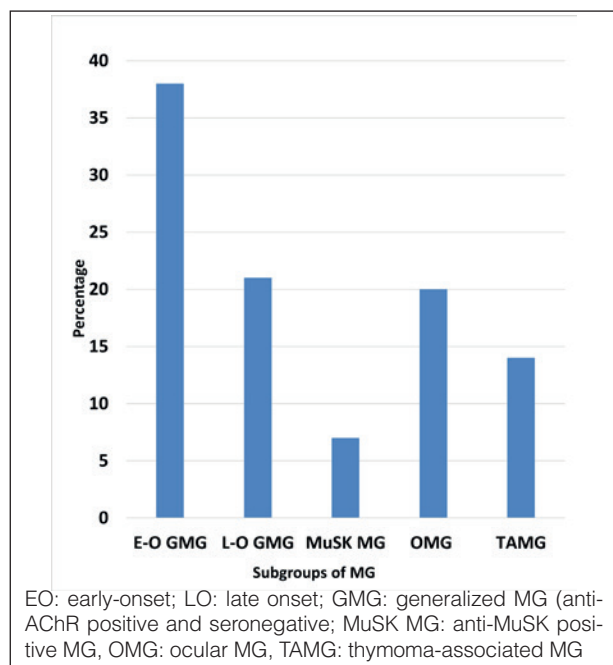


Figure 1. Subgroups of MG (576 patients).

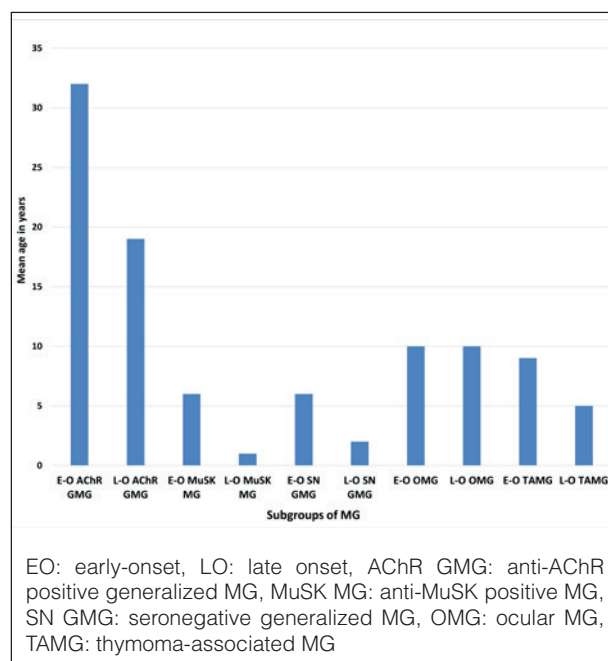


Figure 2. Subgroups of MG according to onset age (576 patients).

Evaluating the frequency of the subgroups, thymoma-associated MG (TAMG) was found in 14%. Early-onset (< 50 years) generalized MG was the most common subgroup comprising close to 40% of the cohort. Late-onset (≥ 50 years) generalized MG and ocular MG (OMG) each made up about one fifth of the patients. MuSK MG comprised 7% of the cohort (Fig. 1). Taking both onset age and antibody status into consideration (Fig. 2), it was striking to note that the subgroups of MuSK MG and SN MG were extremely rare in older ages. Also interesting was the

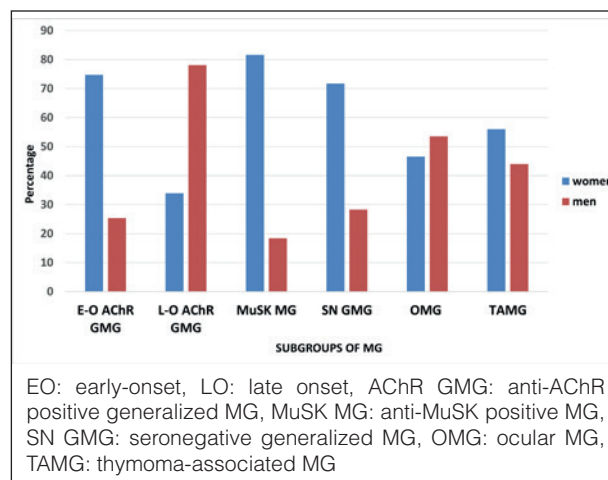


Figure 3. Subgroups of MG. Percentages of gender (576 patients).

fact that thymoma was more common in younger patients in this cohort. Antibody status of ocular MG, about half with anti-AChR antibodies, is not indicated in the figure to avoid confusion. Almost all patients with thymoma had anti-AChR antibodies.

Gender differences among the subgroups were noteworthy. Women predominated in early-onset generalized AChR MG and MuSK MG. Women also predominated in seronegative generalized MG, both early-onset and late-onset. Men predominated in late-onset generalized AChR MG. The two genders were comparable in ocular MG and TAMG (Fig. 3).

Our percentages in general reflected what is reported in the literature, except that thymoma was more common in younger patients in our cohort.

MuSK MG

MG with antibodies to the postsynaptically located MuSK protein is a relatively newly defined disease. It constitutes less than 10% of the MG patients, being more prevalent in the Mediterranean countries as compared to the northern ones in Europe, but more prevalent in the north as compared to the south in China⁵. The antibodies are mainly of the IgG4 class as opposed to IgG1 in MG with anti-AChR antibodies (AChR MG)². There is a specific association with HLA-DRB1*14, -DRB1*16 and -DQB1*05 HLA^{9,10}.

Onset age peaks in the late 30's and it is uncommon in prepubertal and elderly patients^{6,11}. The disease is reported to be more common in women¹¹ although female preponderance was found to be comparable to AChR MG and SN MG in one report⁶. Clinically, it constitutes the most severe form of MG, paralleled by TAMG⁵. Bulbar, neck and respiratory muscles are involved with fast progression of the disease to life-threatening symptoms^{11,12}. Dropped head syndrome with neck extensor muscle weakness can be the presenting symptom^{13,14}. Ocular muscles are frequently mildly involved, and conjugate limitation of eye movements which is exceptional in MG can occur in MuSK MG¹¹. Extremity muscles are usually spared or mildly affected. In those with ocular onset, generalization occurs in a short time. Rare patients generalize after a few years and pure ocular MG is extremely rare. Interestingly, we had one patient with onset at 3 years¹⁵ who remained with purely ocular symptoms for a prolonged period before generalization, similar to another reported patient with MuSK MG¹⁶, and in accordance with the frequent course of prepubertal-onset patients¹⁷.

There are difficulties in diagnosis when the onset is indolent and fluctuations are not evident. At least half of the patients do not respond to anticholinesterases and a few can get worse, fasciculations and cramps are com-

mon¹⁴. Decrement is usually not present in the extremity muscles with repetitive nerve stimulation. The muscle with the best yield was found to be the orbicularis oculi¹⁸. Needle EMG may show a myopathic pattern.

Corticosteroids are the most effective drugs, but they are needed in high doses in many patients. Usually a second immunosuppressive is required at an early stage. Plasma exchange is considered to be more beneficial than IVIg in MuSK MG¹⁹. Although the disease is usually severe, many patients eventually do well with appropriate therapy^{11,14}. We had previously compared all MuSK MG and generalized SN MG patients registered in our MG database with consecutive non-thymomatous 161 AChR MG patients⁶. Their outcome with conventional therapy was similar to AChR MG patients; however, they required higher dose of maintenance corticosteroid therapy. Tongue atrophy has been noted in MuSK MG, but the role of refractoriness and the use of long term high dose corticosteroids is questioned²⁰.

There are MuSK MG patients who are clinically not distinguishable from non-MuSK MG¹². Likewise, some MuSK MG patients can be easily treated. We had reported⁷ that fast and good response within 3 months of starting corticosteroids predicted good outcome in MuSK MG patients. These patients, comprising one third of the study population, had pharmacological remission or minimal manifestations on a mean low maintenance dose of 6 mg/day (or as is generally done, 12 mg on alternate days) of prednisolone, usually with additional azathioprine.

Newer drugs such as rituximab have changed the scene in MuSK MG, particularly for refractory patients²¹⁻²³. It is considered to be an early therapeutic option in the patients without a satisfactory initial response to conventional immunosuppressives¹⁹. Symptomatic treatment with 3,4-diaminopyridine (3,4-DAP) and albuterol is also being considered¹¹. Over the years, a better outcome is noted in MuSK MG patients, attributed to early diagnosis and better treatment¹¹.

It has been difficult to evaluate the effect of thymectomy, because of the confounding effect of steroids, which have usually been started before the surgery. The pathology of the thymus showed involution in most patients²⁴, further suggesting that the thymus may not play a similar role in MuSK MG as compared to AChR MG. Thymectomy is now not considered to be indicated in MuSK MG. There are exceptional cases with small thymomas²⁵. In parallel to the other subgroups of MG, thyroid disease was the most frequent autoimmune disease in MuSK MG¹¹.

One point needs to be emphasized. An important differential diagnosis of MuSK MG is with bulbar amyotrophic lateral sclerosis (ALS), particularly because of fasciculations²⁶ and myotonic discharges²⁷ in rare pa-

tients with MuSK MG. Absence of definite fluctuations, absence of response to anticholinesterases, and difficulty in finding decrement in classically-examined muscles in repetitive nerve stimulation in some patients with MuSK MG may suggest ALS in the face of bulbar symptoms/head drop without ocular symptoms. Even without fasciculations, the differential diagnosis of MuSK MG and bulbar ALS can be difficult. It is sometimes difficult to distinguish from ALS the speech in MuSK MG which may lack the nasal quality of typical MG. Furthermore, mild fluctuations, mild response to anticholinesterases and decrement can all be seen in ALS. Needle EMG of the extremities is usually normal when the symptoms are confined to bulbar muscles in ALS. Caution is necessary in the diagnosis of some cases with bulbar symptoms.

IU MG cohort: MuSK MG

In our cohort of 576 patients, 38 had MuSK MG. One patient, a man with onset at age 39, had a father with LOMG, who was negative for both anti-AChR and -MuSK antibodies. In the cohort, median age of onset was 34 years (range of 3-66 years). Below age 16, there was only one patient with onset at 3 years¹⁵. Onset age was ≥ 50 in 5 patients. Eighty-two percent were women. Onset with ocular symptoms was present in 15 patients (39%). None had ocular MG throughout the entire period of observation. Onset with bulbar symptoms was seen in 12 patients (32%). Three patients had head drop as an onset symptom. The rest had oculobulbar or extremity onset.

Most of our patients did not respond to anticholinesterases. However, some patients responded to lower doses so that anticholinesterases can still be an option to be used with caution in MuSK MG. Of note is the fact that the initial test dose was very good even in some of the non-responders. About half of the patients had hypersensitivity to anticholinesterases. As reported, we found that repetitive nerve stimulation of the orbicularis oculi muscles yielded the best results, both in the frequency and in the amount of decrement.

Maximum severity and outcome were evaluated in 36 patients excluding the two patients who had been seen only once. Median disease duration was 8 years (range: 1-20 years) and median follow-up was 6 years (range: 1-13 years). Using the Myasthenia Gravis Foundation of America (MGFA) Classification²⁸, 75% were MGFA Class 3 or above; 31% of these were 4b and 3 had been intubated (MGFA Class 5). Three patients had tongue atrophy; it was notable that two of these patients had been treated late and the response had taken a long time. Four patients had fasciculations, usually related to the beginning of MG or to exacerbations.

Treatment included corticosteroids and azathioprine. Prednisolone at 1 mg/kg/day or 60 mg/day was usually

needed and it was continued for a longer period than usual in some patients. A look at the outcome revealed that two patients had died of MG. Twenty patients (56%) had reached MGFA post-intervention status (PIS)²⁸ of pharmacological remission or minimal manifestations with a mean maintenance dose of about 10 mg/day of prednisolone, but there was none with complete stable remission. Two were unchanged and the rest had improved to some degree.

At the time of this cohort, treatment of MuSK MG was a little different in that we did not use rituximab and had not yet discontinued performing thymectomies. In fact, 23 patients had been thymectomized. No patient in our cohort had a thymoma. In most of these patients, corticosteroids had been started before thymectomy and in a few within 3-4 months after thymectomy so that it was impossible to evaluate the effect of thymectomy properly. Involution of the thymus was the main pathological result in these patients with a few showing mild hyperplasia. Overall, it is not possible to say that thymectomy has any effect in MuSK MG.

Late-onset MG

The prevalence of LOMG has increased in recent years,²⁹ worldwide³⁰. It is not clear whether the increase reflects a biological phenomenon³¹ or has been influenced by increased awareness, availability of the AChR antibody assay^{29,32} and longer lifespan²⁹. LOMG is different from early-onset MG (EOMG) with respect to demographic-clinical characteristics as well as serological properties. Specific HLA associations of LOMG have been discovered^{33,34}. Comparison between studies on LOMG is somewhat difficult because of different cut-off ages used to distinguish LOMG from EOMG, and the inclusion/exclusion of thymoma. Despite the difficulties, there seems to be consensus on many characteristics of LOMG.

The percentage of men is higher in LOMG^{8,17,35-37}. Anti-AChR antibodies were present in over 80%^{8,17,35-38}. A rising frequency with higher decades of the percentage of anti-AChR antibodies^{8,37} was reported, with 93% in very-late-onset MG (≥ 65 years)³⁷. Anti-MuSK antibodies were found to be uncommon after 65-70 years of age^{11,37}. The implication of these findings is that one has to be extremely cautious when diagnosing MG in double seronegative patients in the elderly and other causes have to be sought diligently.

Anti-titin antibodies were present in one third to over one half of the LOMG patients^{8,38-40}, being more frequent in LOMG than in EOMG. They increased in higher decades in LOMG^{8,40}. Anti-titin antibodies were not found to be a poor prognostic factor in LOMG in two studies^{8,40}.

Ocular onset was more frequent in LOMG^{8,17,36,37,41}. Myasthenic crisis occurred in 6-11% of the pa-

tients^{8,17,36,37}. Although a higher percentage of patients presented with life-threatening events at onset, they responded better to medications; those over 65 were particularly better than early-onset patients in terms of drug requirements and drug refractoriness³⁷. At the end of follow-up, over 80% were reported to be improved or better^{8,17,35,42}. Beneficial effect of thymectomy in LOMG has been reported, but it is usually not advised beyond age 55. Thyroid disease was reported to be the most frequent autoimmune disease accompanying LOMG^{8,36}.

IU MG cohort: Late-onset MG

In an attempt to understand more about non-thymomatous generalized LOMG and its outcome, we analyzed separately 95 of the LOMG patients with generalized symptoms (ocular MG excluded) who had been followed for ≥ 3 years in the same cohort. Although reported⁸, it might be useful to emphasize some of the findings. Men constituted 63% of the patients. Onset was ocular in 62%, bulbar in 23% and in the extremities in 15%. Anti-AChR antibodies were positive in 84% and anti-MuSK antibodies in only 5%. Anti-titin antibodies were present in 61%.

Half of the patients were MGFA Class 3 or above with myasthenic crisis in 6%. Outcome was good with 63% reaching MGFA PIS of complete stable remission, pharmacological remission or minimal manifestations with a mean maintenance dose of about 5 mg/day of prednisolone and a further 24% were improved. Patients in whom azathioprine was added to prednisolone did significantly better than those receiving only prednisolone. Another finding in the study was that many patients with mild disease who received a low maximum dose of prednisolone (≤ 30 mg/day), usually together with azathioprine, had a favorable outcome, implying that low-dose prednisolone with additional azathioprine may be sufficient in mild disease of older people. Thymectomy, done in 12 patients, was not found to be useful although it is not easy to evaluate thymectomy when corticosteroids are used.

Ocular MG

Ocular MG (OMG) refers to patients whose symptoms are confined to ocular muscles (levator palpebrae superioris and extraocular muscles), resulting in ptosis and diplopia; orbicularis oculi muscles are variably weak. Ocular muscles are involved in about 50% of patients at onset of MG. In about half of these patients, generalization occurs to non-ocular muscles, leaving about one fourth of patients with purely ocular symptoms for a prolonged/indefinite period⁴⁴⁻⁴⁶. Generalization usually occurs within one year, mostly within 2 years and it is uncommon after 2 years⁴⁴⁻⁴⁶. Generalization is reported to be more likely in anti-AChR positive^{47,48} and TAMG⁴⁹. Purely ocular MG is more com-

mon in Asians, particularly in juvenile-onset patients⁵⁰. It is reported to be more frequent in men^{51,52}. Spontaneous remissions with a mean of 4-5 years are reported to occur, mainly at earlier stages of the disease^{46,51}.

When a patient presents with ocular symptoms, there are several clinical clues which make the diagnosis of MG more likely. Complete or almost complete unilateral ptosis without pupillary changes, one sided ptosis alternating with ptosis on the other side, definite improvement in the mornings and presence of remissions are very suggestive of the diagnosis of MG. Ptosis can be mild. Eye movement limitation is usually asymmetrical, it can mimic all cranial nerve palsies as well as internuclear ophthalmoplegia.

Diagnosis is easy when anti-AChR antibodies, present in about half of them, are detected. Anti-MuSK antibodies are extremely rare in MG with prolonged pure ocular symptoms. When antibodies are not detected, diagnosis can be difficult in some patients. Response to anticholinesterases may not be present in some patients; on the other hand, other entities such as intracranial mass lesions may show a positive response, usually requiring cranial magnetic resonance imaging for the differential diagnosis⁴⁷. Repetitive nerve stimulation is not very useful with purely ocular symptoms. Single fiber EMG is very sensitive, but one has to be careful remembering that it is not specific to MG⁵³. One other caveat about single fiber EMG is in order: Presence of abnormalities in limb muscles of a patient with OMG does not indicate generalization⁵⁴, the diagnosis of generalized MG is clinical. When all tests are negative in a patient with ocular symptoms, a trial of corticosteroids may be necessary.

In the differential diagnosis, mitochondrial myopathy (progressive external ophthalmoplegia, PEO) must be considered. Diplopia is not a feature of PEO; however, ptosis can be asymmetrical and fluctuations can be present, making the differential diagnosis with MG difficult. Oculopharyngeal muscular dystrophy is usually bilateral and without eye movement limitation, at least for a long time. Congenital myasthenic syndromes usually start in infancy and it is then easy to eliminate MG. The distinction with thyroid ophthalmopathy can be difficult. In thyroid ophthalmopathy, ptosis is rare; esotropia (inward deviation of the eye) and hypotropia (downward deviation of the eye) are usually present since muscles causing restriction are medial rectus and inferior rectus. Thus, ptosis and exotropia (outward deviation of the eye) are suggestive of MG in a patient with thyroid ophthalmopathy⁵⁵.

Anticholinesterases provide symptomatic treatment for some patients with ptosis, but they are usually not useful for diplopia since the required precise alignment cannot be achieved⁵⁰. Corticosteroids have caused debates on whether they are beneficial or not⁵⁰. Observational

studies^{47,56} and one clinical trial⁵⁷ with a small number of patients (11 patients) have found them to be effective. Generalization appeared to be less likely in the patients who received immunosuppressives. It is emphasized that low doses are sufficient: About 25 mg/day or twice the dose on alternate days usually results in pharmacological remission. A real concern is the appearance of relapses upon discontinuation of steroids in many patients, necessitating long term administration with small doses. High dose intravenous methylprednisone has also been advocated⁵⁸. Azathioprine and mycophenolate mofetil have been found to be beneficial⁵⁰ and again lower than the standard doses may be sufficient in OMG. It takes a few months for them to take effect so that they are usually used as additive drugs. However, they can be given as the sole therapeutic agent in selected patients.

Intravenous immunoglobulins do not improve the symptoms⁵⁹. Thymectomy, reported to be beneficial in some patients⁶⁰, is usually not considered to be indicated in OMG, although some centers might have revised their indications after the advent of videothoroscopic thymectomy.

Eye patches for diplopia, prisms when eye movement limitation is mild and eyelid crutches for ptosis can be useful. There are rare patients who do not improve and have severe symptoms/signs despite all therapy. In these patients, if the signs are chronic and stable, blepharoplasty can be a good option, taking care not to cause the diplopia to be more disturbing once the ptosis is alleviated.

IU MG cohort: Ocular MG

In our cohort, 101 patients with a median disease duration of 8 years remained with purely ocular symptoms/signs throughout the entire period of observation. Two of the patients had thymomas. In the cohort, almost equal distribution was present regarding gender as well as onset age with very slight preponderance of men and early-onset. In patients with early-onset, women predominated while men predominated in late-onset. About half of the patients were anti-AChR positive.

Low dose prednisolone of 15-30 mg/day was sufficient in many patients. Addition of azathioprine, sometimes also at a low dose, appeared to be beneficial. Azathioprine was used as a single agent successfully in selected patients. We have also found that several courses of intravenous methylprednisone pulse, alone or in addition to oral steroids, was very helpful in difficult cases.

Myasthenia generalized after 2 years in another small group of patients. The majority of the patients were anti-AChR positive. Presence of thymoma was another risk factor for generalization. The two patients with anti-MuSK antibodies also generalized after several years.

Conclusions

In this review, the importance of analyzing the subgroups separately was emphasized because each has its own characteristics and different treatment approaches. Thymectomy, a very important treatment in MG, is not considered to be a widely-accepted therapeutic option in any of these subgroups. Corticosteroids are useful in all of the subgroups; however, while MuSK MG patients need high doses, low doses are usually effective in OMG, and LOMG patients can also respond well to low doses. Additional immunosuppressives are usually needed in order to taper corticosteroids to low maintenance doses and perhaps to be able to discontinue them. With the advent of new therapies, the differences between the subgroups are likely to play a more important role.

Acknowledgments

All of the patients were seen at the Neuromuscular Unit, Istanbul Medical Faculty, Istanbul University, founded by Coskun Ozdemir, and included, at the time of the data collection, Piraye Serdaroglu-Ofazer, Yesim Gulsen-Parman and Hacer Durmus-Tekce. Many neurology residents chose an aspect of MG as the subject of their theses, led by Feza Deymeer: Aylin Kilic on the development of the MG database and HLA, Ozlem Gungor-Tuncer on MuSK MG, Senay Yildiz-Celik on late-onset MG, Tugba Uyar on ocular MG and Ozlem Canbolat on early-onset MG. Serology was done by Guher Saruhan-Direskeneli and Vuolat Yilmaz. Thymectomies were performed by Alper Toket and Berker Ozkan. The author is grateful to all of them for the unique collaboration over many years. The author also remembers with a lot of fondness and nostalgia all the congresses organized by the late Giovanni Nigro, the late Lucia Comi, and their valuable colleagues.

References

- 1 Drachman DB. Myasthenia gravis. *N Engl J Med* 1994;330:1797-810.
- 2 Vincent A, Huda S, Cao M, et al. Serological and experimental studies in different forms of myasthenia gravis. *Ann N Y Acad Sci* 2018;1413:143-53. <https://doi.org/10.1111/nyas.13592> [Erratum in: *Ann N Y Acad Sci* 2018;1417:130. PMID: 29377162].
- 3 Compston DA, Vincent A, Newsom-Davis J, et al. Clinical, pathological, HLA antigen and immunological evidence for disease heterogeneity in myasthenia gravis. *Brain* 1980;103:579-601. <https://doi.org/10.1093/brain/103.3.579>
- 4 Gilhus NE, Verschuuren JJ. Myasthenia gravis: subgroup classification and therapeutic strategies. *Lancet Neurol* 2015;14:1023-36. [https://doi.org/10.1016/S1474-4422\(15\)00145-3](https://doi.org/10.1016/S1474-4422(15)00145-3)
- 5 Gilhus NE, Tzartos S, Evoli A, et al. Myasthenia gravis. *Nat Rev Dis Primers* 2019;5:30. <https://doi.org/10.1038/s41572-019-0079-y>

- 6 Deymeer F, Gungor-Tuncer O, Yilmaz V, et al. Clinical comparison of anti-MuSK- vs anti-AChR-positive and seronegative myasthenia gravis. *Neurology* 2007;68:609-11. <https://doi.org/10.1212/01.wnl.0000254620.45529.97>
- 7 Gungor-Tuncer O, Yilmaz V, Toker A, et al. Prompt response to prednisone predicts benign course in MuSK-MG. *Eur Neurol* 2017;78:137-42. <https://doi.org/10.1159/000479228>
- 8 Yildiz Celik S, Durmus H, Yilmaz V, et al. Late-onset generalized myasthenia gravis: clinical features, treatment, and outcome. *Acta Neurol Belg* 2020;120:133-40. <https://doi.org/10.1007/s13760-019-01252-x>
- 9 Niks EH, Kuks JB, Roep BO, et al. Strong association of MuSK antibody-positive myasthenia gravis and HLA-DR14-DQ5. *Neurology* 2006;66:1772-4. <https://doi.org/10.1212/01.wnl.0000218159.79769.5c>
- 10 Alahgholi-Hajibehzad M, Yilmaz V, Gülsen-Parman Y, et al. Association of HLA-DRB1*14, -DRB1*16 and -DQB1*05 with MuSK-myasthenia gravis in patients from Turkey. *Hum Immunol* 2013;74:1633-5. <https://doi.org/10.1016/j.humimm.2013.08.271>
- 11 Evoli A, Alboini PE, Damato V, et al. Myasthenia gravis with antibodies to MuSK: an update. *Ann N Y Acad Sci* 2018;1412:82-9. <https://doi.org/10.1111/nyas.13518>
- 12 Sanders DB, El-Salem K, Massey JM, et al. Clinical aspects of MuSK antibody positive seronegative MG. *Neurology* 2003;60:1978-80. <https://doi.org/10.1212/01.wnl.0000065882.63904.53>
- 13 Casasnovas C, Povedano M, Jaumà S, et al. Musk-antibody positive myasthenia gravis presenting with isolated neck extensor weakness. *Neuromuscul Disord* 2007;17:544-6. <https://doi.org/10.1016/j.nmd.2007.03.007>
- 14 Guptill JT, Sanders DB, Evoli A. Anti-MuSK antibody myasthenia gravis: clinical findings and response to treatment in two large cohorts. *Muscle Nerve* 2011;44:36-40. <https://doi.org/10.1002/mus.22006>
- 15 Gungor-Tuncer O, Orhan EK, Yilmaz V, et al. Prepubertal anti-MuSK positive myasthenia gravis with long remission. *Neuromuscul Disord* 2014;24:36-9. <https://doi.org/10.1016/j.nmd.2013.07.012>
- 16 Anlar B, Yilmaz V, Saruhan-Direskeneli G. Long remission in muscle-specific kinase antibody-positive juvenile myasthenia. *Pediatr Neurol* 2009;40:455-6. <https://doi.org/10.1016/j.pediatrneurol.2008.11.014>
- 17 Deymeer F, Serdaroglu P, Ozdemir C. Juvenile and late-onset myasthenia gravis. In: Deymeer F, Ed. *Neuromuscular diseases: from basic mechanisms to clinical management*. Basel: Karger 2000.
- 18 Oh SJ, Hatanaka Y, Hemmi S, et al. Repetitive nerve stimulation of facial muscles in MuSK antibody-positive myasthenia gravis. *Muscle Nerve* 2006;33:500-4. <https://doi.org/10.1002/mus.20498>
- 19 Sanders DB, Wolfe GI, Benatar M, et al. International consensus guidance for management of myasthenia gravis: executive summary. *Neurology* 2016;87:419-25. <https://doi.org/10.1212/WNL.0000000000002790>
- 20 Farrugia ME, Robson MD, Clover L, et al. MRI and clinical studies of facial and bulbar muscle involvement in MuSK antibody-associated myasthenia gravis. *Brain* 2006;129(Pt 6):1481-92. <https://doi.org/10.1093/brain/awl095>
- 21 Díaz-Manera J, Martínez-Hernández E, Querol L, et al. Long-lasting treatment effect of rituximab in MuSK myasthenia. *Neurology* 2012;78:189-93. <https://doi.org/10.1212/WNL.0b013e3182407982>
- 22 Tandan R, Hehir MK 2nd, Waheed W, et al. Rituximab treatment of myasthenia gravis: a systematic review. *Muscle Nerve* 2017;56:185-96. <https://doi.org/10.1002/mus.25597>
- 23 Hehir MK, Hobson-Webb LD, Benatar M, et al. Rituximab as treatment for anti-MuSK myasthenia gravis: multicenter blinded prospective review. *Neurology* 2017;89:1069-77. <https://doi.org/10.1212/WNL.0000000000004341>
- 24 Leite MI, Ströbel P, Jones M, et al. Fewer thymic changes in MuSK antibody-positive than in MuSK antibody-negative MG. *Ann Neurol* 2005;57:444-8. <https://doi.org/10.1002/ana.20386>
- 25 Saka E, Topcuoglu MA, Akkaya B, et al. Thymus changes in anti-MuSK-positive and -negative myasthenia gravis. *Neurology* 2005 Sep 13;65(5):782-3; author reply 782-3. doi: 10.1212/wnl.65.5.782.
- 26 Huijbers MG, Niks EH, Klooster R, et al. Myasthenia gravis with muscle specific kinase antibodies mimicking amyotrophic lateral sclerosis. *Neuromuscul Disord* 2016;26:350-3. <https://doi.org/10.1016/j.nmd.2016.04.004>
- 27 Magnussen M, Karakis I, Harrison TB. The myotonic plot thickens: electrical myotonia in antimuscle-specific kinase myasthenia gravis. *Case Rep Neurol Med* 2015;2015:242691. <https://doi.org/10.1155/2015/242691>
- 28 Jaretzki A 3rd, Barohn RJ, Ernstoff RM, et al. Myasthenia gravis: recommendations for clinical research standards. Task Force of the Medical Scientific Advisory Board of the Myasthenia Gravis Foundation of America. *Neurology* 2000;55:16-23. <https://doi.org/10.1212/wnl.55.1.16>
- 29 Aarli JA. Myasthenia gravis in the elderly: Is it different? *Ann N Y Acad Sci* 2008;1132:238-43. <https://doi.org/10.1196/annals.1405.040>
- 30 Murai H, Yamashita N, Watanabe M, et al. Characteristics of myasthenia gravis according to onset-age: Japanese nationwide survey. *J Neurol Sci* 2011;305:97-102. <https://doi.org/10.1016/j.jns.2011.03.004>
- 31 Pakzad Z, Aziz T, Oger J. Increasing incidence of myasthenia gravis among elderly in British Columbia, Canada. *Neurology* 2011;76:1526-8. <https://doi.org/10.1212/WNL.0b013e318217e735>
- 32 Pedersen EG, Hallas J, Hansen K, et al. Late-onset myasthenia not on the increase: a nationwide register study in Denmark, 1996-2009. *Eur J Neurol* 2013;20:309-14. <https://doi.org/10.1111/j.1468-1331.2012.03850.x>
- 33 Seldin MF, Alkhairy OK, Lee AT, et al. Genome-Wide Association Study of Late-Onset Myasthenia Gravis: confirmation of *TN*-

- FRSF11A* and identification of *ZBTB10* and Three Distinct HLA Associations. *Mol Med* 2016;21:769-81. <https://doi.org/10.2119/molmed.2015.00232>
- ³⁴ Saruhan-Direskeneli G, Hughes T, Yilmaz V, et al. Genetic heterogeneity within the HLA region in three distinct clinical subgroups of myasthenia gravis. *Clin Immunol* 2016;166-167:81-8. <https://doi.org/10.1016/j.clim.2016.05.003>
- ³⁵ Evoli A, Batocchi AP, Minisci C, et al. Clinical characteristics and prognosis of myasthenia gravis in older people. *J Am Geriatr Soc* 2000;48:1442-8. <https://doi.org/10.1111/j.1532-5415.2000.tb02635.x>
- ³⁶ Zivković SA, Clemens PR, Lacomis D. Characteristics of late-onset myasthenia gravis. *J Neurol* 2012;259:2167-71. <https://doi.org/10.1007/s00415-012-6478-6>
- ³⁷ Cortés-Vicente E, Álvarez-Velasco R, Segovia S, et al. Clinical and therapeutic features of myasthenia gravis in adults based on age at onset. *Neurology* 2020;94:e1171-80. <https://doi.org/10.1212/WNL.0000000000008903>
- ³⁸ Aarli JA, Romi F, Skeie GO, et al. Myasthenia gravis in individuals over 40. *Ann N Y Acad Sci* 2003;998:424-31. <https://doi.org/10.1196/annals.1254.055>
- ³⁹ Suzuki S, Utsugisawa K, Nagane Y, et al. Three types of striational antibodies in myasthenia gravis. *Autoimmune Dis* 2011;2011:740583. <https://doi.org/10.4061/2011/740583>
- ⁴⁰ Szczudlik P, Szyluk B, Lipowska M, et al. Antititin antibody in early- and late-onset myasthenia gravis. *Acta Neurol Scand* 2014;130:229-33. <https://doi.org/10.1111/ane.12271>
- ⁴¹ Suzuki S, Utsugisawa K, Nagane Y, et al. Clinical and immunological differences between early and late-onset myasthenia gravis in Japan. *J Neuroimmunol* 2011;230:148-52. <https://doi.org/10.1016/j.jneuroim.2010.10.023>
- ⁴² Slesak G, Melms A, Gemeth F, et al. Late-onset myasthenia gravis. Follow-up of 113 patients diagnosed after age 60. *Ann N Y Acad Sci* 1998;841:777-80. <https://doi.org/10.1111/j.1749-6632.1998.tb11017.x>
- ⁴³ Olanow CW, Lane RJ, Roses AD. Thymectomy in late-onset myasthenia gravis. *Arch Neurol* 1982;39:82-3. <https://doi.org/10.1001/archneur.1982.00510140016004>
- ⁴⁴ Grob D. Course and management of myasthenia gravis. *J Am Med Assoc* 1953;153:529-32. <https://doi.org/10.1001/jama.1953.02940230001001>
- ⁴⁵ Oosterhuis HJ. The natural course of myasthenia gravis: a long term follow up study. *J Neurol Neurosurg Psychiatry* 1989;52:1121-7. <https://doi.org/10.1136/jnnp.52.10.1121>
- ⁴⁶ Bever CT Jr, Aquino AV, Penn AS, et al. Prognosis of ocular myasthenia. *Ann Neurol* 1983;14:516-9. <https://doi.org/10.1002/ana.410140504>
- ⁴⁷ Sommer N, Sigg B, Melms A, et al. Ocular myasthenia gravis: response to long-term immunosuppressive treatment. *J Neurol Neurosurg Psychiatry* 1997;62:156-62. <https://doi.org/10.1136/jnnp.62.2.156>
- ⁴⁸ Galassi G, Mazzoli M, Ariatti A, et al. Antibody profile may predict outcome in ocular myasthenia gravis. *Acta Neurol Belg* 2018;118:435-43. <https://doi.org/10.1007/s13760-018-0943-7>
- ⁴⁹ Hong YH, Kwon SB, Kim BJ, et al. Prognosis of ocular myasthenia in Korea: a retrospective multicenter analysis of 202 patients. *J Neurol Sci* 2008;273:10-4. <https://doi.org/10.1016/j.jns.2008.05.023>
- ⁵⁰ Al-Haidar M, Benatar M, Kaminski HJ. Ocular myasthenia. *Neurol Clin* 2018;36:241-51. <https://doi.org/10.1016/j.ncl.2018.01.003>
- ⁵¹ Grob D, Brunner N, Namba T, et al. Lifetime course of myasthenia gravis. *Muscle Nerve* 2008;37:141-9. <https://doi.org/10.1002/mus.20950>
- ⁵² Smith SV, Lee AG. Update on ocular myasthenia gravis. *Neurol Clin* 2017;35:115-23. <https://doi.org/10.1016/j.ncl.2016.08.008>
- ⁵³ Sanders DB, Stålberg EV. AAEM minimonograph #25: single-fiber electromyography. *Muscle Nerve* 1996;19:1069-83. [https://doi.org/10.1002/\(SICI\)1097-4598\(199609\)19:9<1069::AID-MUS1>3.0.CO;2-Y](https://doi.org/10.1002/(SICI)1097-4598(199609)19:9<1069::AID-MUS1>3.0.CO;2-Y)
- ⁵⁴ Rostedt A, Sadlers LL, Edards LJ, et al. Predictive value of single-fiber electromyography in the extensor digitorum communis muscle of patients with ocular myasthenia gravis: a retrospective study. *J Clin Neuromuscul Dis* 2000;2:6-9. <https://doi.org/10.1097/00131402-200009000-00003>
- ⁵⁵ Bojikian KD, Francis CE. Thyroid eye disease and myasthenia gravis. *Int Ophthalmol Clin* 2019;59:113-24. <https://doi.org/10.1097/IIO.0000000000000277>
- ⁵⁶ Kupersmith MJ, Latkany R, Homel P. Development of generalized disease at 2 years in patients with ocular myasthenia gravis. *Arch Neurol* 2003;60:243-8. <https://doi.org/10.1001/archneur.60.2.243>
- ⁵⁷ Benatar M, Mcdermott MP, Sanders DB, et al. Efficacy of prednisone for the treatment of ocular myasthenia (EPITOME): a randomized, controlled trial. *Muscle Nerve* 2016;53:363-9. <https://doi.org/10.1002/mus.24769>
- ⁵⁸ Ozawa Y, Uzawa A, Kanai T, et al. Efficacy of high-dose intravenous methylprednisolone therapy for ocular myasthenia gravis. *J Neurol Sci* 2019;402:12-5. <https://doi.org/10.1016/j.jns.2019.05.003>
- ⁵⁹ Zinman L, Ng E, Bril V. IV immunoglobulin in patients with myasthenia gravis: a randomized controlled trial. *Neurology* 2007;68:837-41. <https://doi.org/10.1212/01.wnl.0000256698.69121.45>
- ⁶⁰ Schumm F, Wiethölter H, Fateh-Moghadam A, et al. Thymectomy in myasthenia with pure ocular symptoms. *J Neurol Neurosurg Psychiatry* 1985;48:332-7. <https://doi.org/10.1136/jnnp.48.4.332>