

## CORRESPONDENCE

## Microvascular Injury in the Brains of Patients with Covid-19

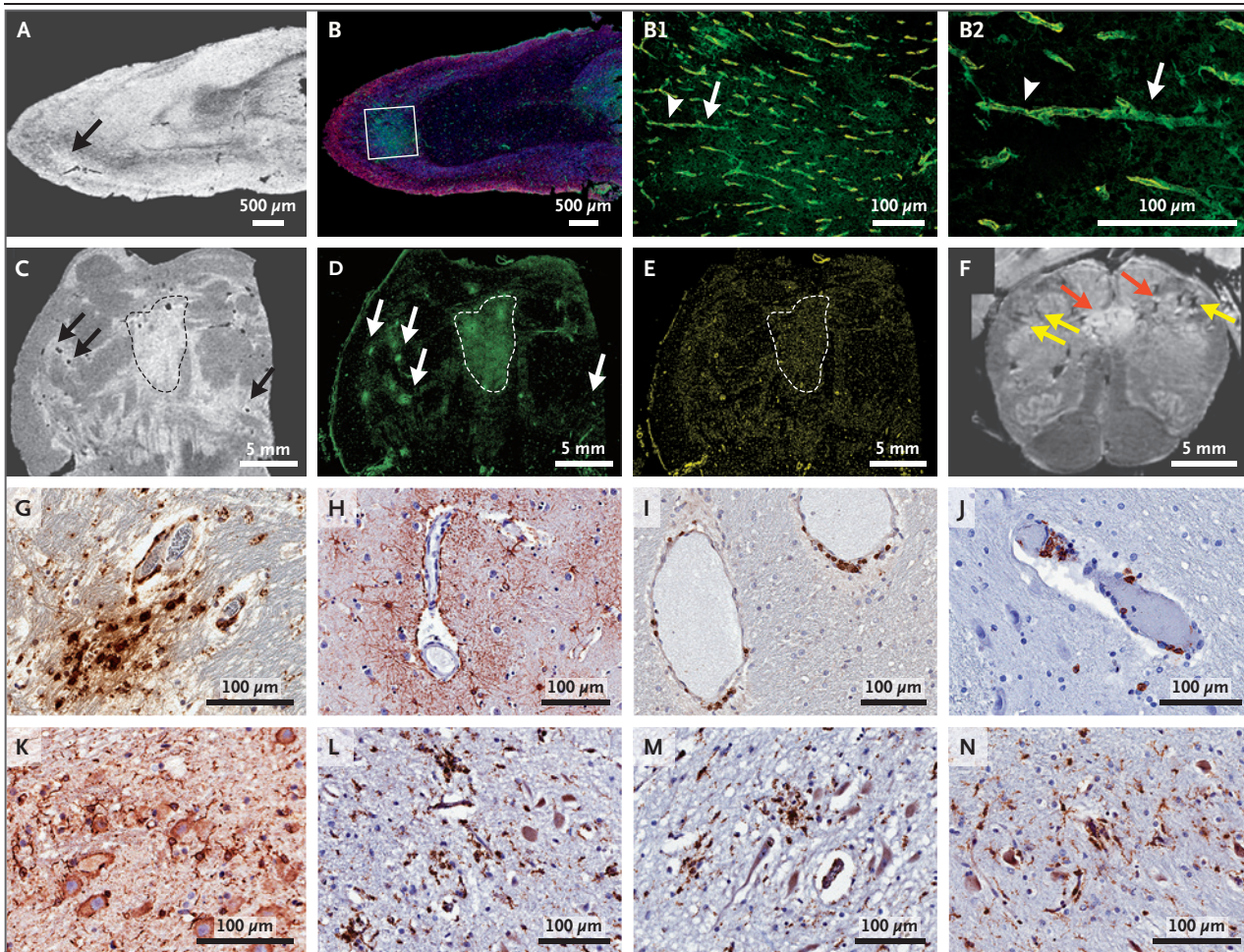
**TO THE EDITOR:** We conducted postmortem high-resolution magnetic resonance imaging (magnetic resonance microscopy) of the brains of patients with coronavirus disease 2019 (Covid-19) (median age, 50 years) and histopathological examination that focused on microvascular changes in the olfactory bulb and brain stem. (See the Materials and Methods section in the Supplementary Appendix, available with the full text of this letter at NEJM.org.) Images were obtained from the brains of 13 patients with the use of an 11.7-Tesla scanner at a resolution of 25  $\mu\text{m}$  for the olfactory bulb and at a resolution of 100  $\mu\text{m}$  for the brain. Abnormalities were seen in the brains of 10 patients. We examined the brains of patients that showed abnormalities by means of multiplex fluorescence imaging (in 5 patients) and by means of chromogenic immunostaining (in 10 patients). We performed conventional histopathological examination of the brains of 18 patients. Fourteen patients had chronic illnesses, including diabetes and hypertension, and 11 had been found dead or had died suddenly and unexpectedly. Of the 16 patients with available medical histories, 1 had delirium, 5 had mild respiratory symptoms, 4 had acute respiratory distress syndrome, 2 had pulmonary embolism, and the symptoms were not known in 3 (Table S1 in the Supplementary Appendix).

Magnetic resonance microscopy showed punctate hyperintensities in 9 patients, which represented areas of microvascular injury and fibrinogen leakage. These features were observed on corresponding histopathological examination performed with the use of fluorescence imaging (Fig. 1A and 1B). These areas showed thinning of the basal lamina of the endothelial cells, as determined by collagen IV immunostaining in 5 patients (Fig. 1B1 and 1B2). Punctate hypointensities on imaging in 10 patients corresponded to congested blood vessels (Fig. 1C) with sur-

rounding areas of fibrinogen leakage (Fig. 1D and Fig. S1) and relatively intact vasculature (Fig. 1E). Areas of linear hypointensities were interpreted as microhemorrhages (Fig. 1F and Fig. S2). There was minimal perivascular inflammation in the specimens examined, but there was no vascular occlusion, as previously described in the *Journal*.<sup>1</sup> Perivascular-activated microglia, macrophage infiltrates, and hypertrophic astrocytes were seen in 13 patients (Fig. 1G and 1H, Fig. S3, and Table S4).<sup>2</sup> There were CD3+ and CD8+ T cells in the perivascular spaces and in lumens adjacent to endothelial cells in 8 patients, which may have contributed to vascular injury (Fig. 1I and 1J), as suggested in a previous report.<sup>3</sup> Activated microglia were found adjacent to neurons in 5 patients, which is suggestive of neuronophagia in the olfactory bulb, substantia nigra, dorsal motor nucleus of the vagal nerve, and the pre-Bötzinger complex in the medulla, which is involved in the generation of spontaneous rhythmic breathing (Fig. 1K through 1N and Fig. S3).

Severe acute respiratory syndrome coronavirus 2 was not detected by means of polymerase chain reaction with multiple primer sets, RNA sequencing of several areas of the brain, or RNA in situ hybridization and immunostaining (Table S5). It is possible that the virus was cleared by the time of death or that viral copy numbers were below the level of detection by our assays.

In a convenience sample of patients who had died from Covid-19, multifocal microvascular injury was observed in the brain and olfactory bulbs by means of magnetic resonance microscopy, histopathological evaluation, and immunohistochemical analysis of corresponding sections, without evidence of viral infection. These findings may inform the interpretation of changes observed on magnetic resonance imaging of punctate hyperintensities and linear hypointensities in patients with Covid-19. Because of the



**Figure 1. Pathological Studies of Microvascular Injury in the Brains of Patients Who Died from Covid-19.**

Panel A (magnetic resonance microscopy of the olfactory bulb) shows an area of hyperintense signal (arrow). Panel B shows the corresponding area on multiplex immunofluorescence imaging, which revealed a focal area of fibrinogen leakage (in the box, fibrinogen is shown in green, collagen IV is shown in yellow, and nuclei are shown in blue). Panel B1 shows diffuse leakage of fibrinogen in the parenchyma (an enlarged view showing marked blood vessel staining for collagen IV is shown in Panel B2). Panel B2 (collagen IV immunostaining) shows intact (arrowhead) and thinned (arrow) basal lamina with fibrinogen leakage into the parenchyma. Panel C shows magnetic resonance microscopy of the pons, and Panel D (fibrinogen staining) shows areas of increased signal intensity corresponding to the vascular leakage visible on magnetic resonance microscopy. The arrows and the area within the dashed lines in Panels C and D indicate the vascular leakage. Panels A through E represent imaging performed in Patient IA1. Panel E (collagen IV immunostaining) shows areas of fibrinogen leakage in blood vessels in Patient IA1. Panel F shows magnetic resonance microscopy of the medulla in Patient IA3. The yellow arrows indicate linear hypointense signals, and the red arrows indicate linear hyperintense signals. Panel G shows CD68+ perivascular macrophages in the pons in Patient NY6. Panel H shows perivascular astrocytosis in the basal ganglia in Patient NY5. Panel I shows perivascular CD3+ cells in the cerebellum in Patient IA1. Panel J shows intraluminal and perivascular CD8+ cells in the pons in Patient NY6. Panel K shows perineuronal IBA1 cells in the pons in Patient NY6. Panel L shows CD68+ cells in the dorsal motor nucleus of the vagus nerve in Patient IA1. Panel M shows a solitary nucleus in the medulla and Panel N shows a pre-Bötzinger complex in Patient IA1. (Diaminobenzidine staining was used in Panels G through N.)

limited clinical information that was available, no conclusions can be drawn in relation to neurologic features of Covid-19.

Myoung-Hwa Lee, Ph.D.

National Institute of Neurological Disorders and Stroke  
Bethesda, MD

Daniel P. Perl, M.D.

Uniformed Services University of the Health Sciences  
Bethesda, MD

Govind Nair, Ph.D.

Wenxue Li, Ph.D.

Dragan Maric, Ph.D.

Helen Murray, Ph.D.

Stephen J. Dodd, Ph.D.

Alan P. Koretsky, Ph.D.

National Institute of Neurological Disorders and Stroke  
Bethesda, MD

Jason A. Watts, M.D., Ph.D.

Vivian Cheung, M.D.

University of Michigan  
Ann Arbor, MI

Eliezer Masliah, M.D.

National Institute on Aging  
Bethesda, MD

Iren Horkayne-Szakaly, M.D.

Robert Jones, M.D.

Defense Health Agency  
Silver Spring, MD

Michelle N. Stram, M.D.

Office of Chief Medical Examiner  
New York, NY

Joel Moncur, M.D.

Defense Health Agency  
Silver Spring, MD

Marco Hefti, M.D.

University of Iowa  
Iowa City, IA

Rebecca D. Folkerth, M.D.

Office of Chief Medical Examiner  
New York, NY

Avindra Nath, M.D.

National Institute of Neurological Disorders and Stroke  
Bethesda, MD  
natha@ninds.nih.gov

Drs. Folkerth and Nath contributed equally to this letter.

The opinions expressed here are those of the authors and are not necessarily representative of those of the Uniformed Services University, the U.S. Department of Defense, or the U.S. Army, Navy, or Air Force or any other federal agency.

Supported by intramural funds (K23NS109284 [to Dr. Hefti]) from the National Institute of Neurological Disorders and Stroke. The reagent used in this study (Genomic RNA from SARS-CoV-2, Isolate USA-WA1/2020, NR-52285) was deposited by the Centers for Disease Control and Prevention and obtained through BEI Resources Repository of the National Institute of Allergy and Infectious Diseases of the National Institutes of Health.

Disclosure forms provided by the authors are available with the full text of this letter at NEJM.org.

This letter was published on December 30, 2020, at NEJM.org.

1. Solomon IH, Normandin E, Bhattacharyya S, et al. Neuropathological features of Covid-19. *N Engl J Med* 2020;383:989-92.
2. Matschke J, Lütgehetmann M, Hagel C, et al. Neuropathology of patients with COVID-19 in Germany: a post-mortem case series. *Lancet Neurol* 2020;19:919-29.
3. Varga Z, Flammer AJ, Steiger P, et al. Endothelial cell infection and endotheliitis in COVID-19. *Lancet* 2020;395:1417-8.

DOI: 10.1056/NEJMc2033369

Correspondence Copyright © 2020 Massachusetts Medical Society.