

Mutational characteristics of gastrointestinal stromal tumors: A single-center analysis of 302 patients

LI LIANG, XIN LI, DONG LI, PING LIU, LIN NONG, YING DONG, JUMEI LIU, SIXIA HUANG and TING LI

Department of Pathology, Peking University First Hospital, Beijing 100034, P.R. China

Received August 21, 2020; Accepted November 20, 2020

DOI: 10.3892/ol.2021.12435

Abstract. Gastrointestinal stromal tumors (GISTs) represent a spectrum of tumors characterized by variable behaviors and activating mutations in KIT proto-oncogene, receptor tyrosine kinase (*KIT*) or platelet derived growth factor receptor α (*PDGFRA*) genes. However, whether genotype analysis should be regarded as a prognostic indicator remains unclear. In the present study, clinicopathological data and the mutation phenotypes of *KIT* and *PDGFRA* genes were assessed in a series of 302 patients with GISTs at a single center. Univariate and multivariate Cox regression analyses were performed to identify the clinicopathological and mutational factors associated with relapse-free survival (RFS) in patients who had undergone complete primary GIST resection. *KIT* and *PDGFRA* mutations were identified in 233 (77.2%) and 30 (9.9%) cases, respectively. The following clinicopathological parameters were significantly associated with a shorter RFS: Male, non-gastric tumor origin, larger tumor size (>5 cm), high mitotic activity (>5/50 high-power fields), necrosis and epithelioid morphology. Tumors at non-gastric sites, with high National Institutes of Health risk classification, high World Health Organization (WHO) grade and *KIT* deletion involving codons 557/558/559 exhibited a significantly higher risk of progression. In the Cox regression model, *KIT* deletion involving codons 557/558/559, non-gastric origin and high WHO grade were independent indicators of RFS. The adverse prognosis associated with *KIT* deletions involving codons 557/558/559 was also observed for gastric GISTs. Conversely, spindle morphology, *KIT* exon 11 substitution and *PDGFRA* exon 18 mutation were associated with a longer RFS and lower rate of relapse. Furthermore, the coexistence of *KIT* exon 11 deletion and exon 13 duplication was observed in one tumor, with adverse prognostic features. Heterogeneity affecting morphology, immunostaining and

genotype was identified in 4 cases. In addition, the presence of succinate dehydrogenase-deficient GIST was found in 5 cases (3.6%). In conclusion, the tumor genotype with regard to *KIT* and *PDGFRA* mutations exhibited prognostic significance for the risk of GIST progression and may be helpful for the optimization of tailored adjuvant therapy.

Introduction

Gastrointestinal stromal tumors (GISTs) are the most frequently occurring mesenchymal tumors of the digestive tract and are characterized by differentiation from the interstitial cells of Cajal (1). GISTs predominantly (60-70%) arise in the stomach, followed by the small bowel (20-30%) (2). The pathological diagnosis of GISTs is based on various morphological manifestations together with sensitive and specific markers, including CD117, discovered on GIST-1 (DOG1, also known as anoctamin 1) and CD34, identified by immunostaining (3). GISTs represent a wide spectrum of tumors, with variable disease behaviors associated with tumor size, mitotic activity and anatomical origin (3-5). According to these three clinicopathological features, several recurrence risk assessment systems have been developed and used for primary GISTs. The Chinese Society of Clinical Oncology Expert Committee recommends the modified US National Institutes of Health (NIH) classification, which they consider to be particularly suitable for Asian populations (6,7). In addition, the World Health Organization (WHO) classification recommends the US Armed Forces Institute of Pathology criteria, which are classified into eight grades (grades 1, 2, 3a, 3b, 4, 5, 6a and 6b) (8,9).

It has been reported that 82-87% of GISTs harbor gain-of-function mutations in the KIT proto-oncogene, receptor tyrosine kinase (*KIT*) or platelet derived growth factor receptor α (*PDGFRA*) oncogenes encoding type III receptor tyrosine kinases (10-12). *KIT* mutations have been reported to occur in 69-83% of all GISTs and *PDGFRA* mutations have been detected in 12.9-14.0% of primary GISTs (10,12,13). In adults, ~15% of GISTs without detectable mutations in *KIT* or *PDGFRA* are considered wild-type (WT) GISTs (14). The most frequent site of *KIT* mutation is at the 5' end of exon 11; this encodes the JM domain which has an autoinhibitory function under ligand-free conditions. Mutations of exon 11 disrupt this autoinhibitory function and thereby result in ligand-independent receptor activation (15). Several studies

Correspondence to: Dr Ting Li, Department of Pathology, Peking University First Hospital, 8 Xishiku Street, Xicheng, Beijing 100034, P.R. China
E-mail: lixiaoting12@hotmail.com

Key words: gastrointestinal stromal tumors, *KIT*, *PDGFRA*, mutation, heterogeneity

have demonstrated that exon 11 deletions of *KIT* are associated with a high risk of relapse and metastasis. In particular, GISTs with deletions affecting codons 557/558 exhibit a higher risk of progression (10,11,16,17). However, in comparison with *KIT* deletions, *KIT* exon 11 substitutions indicate an improved patient outcome (10,18). Furthermore, GISTs with *PDGFRA* exon 18 mutations have a lower risk of relapse than those with *KIT* deletions (11). However, although the roles of *KIT* and *PDGFRA* mutations in the assessment of the response to imatinib therapy are well documented (3,7,9), the prognostic significance of these mutations in the Chinese population has yet to be defined. Furthermore, whether genotype analysis should be considered as an additional prognostic approach is currently unclear.

Therefore, the aim of the present study was to analyze the clinicopathological and mutational characteristics of GISTs and evaluate the prognostic significance of these parameters in a large cohort of 302 cases in North China. The findings may be helpful for risk assessment and personalized targeted therapy.

Materials and methods

Patients and samples. A series of 302 GIST cases was retrospectively collected from records archived in the Department of Pathology, Peking University First Hospital (Beijing, China). The cases were diagnosed between May 2009 and June 2019, and represent ~2.1% of all gastrointestinal malignancies at this center. Inclusion and exclusion criteria were as follows. Patients with primary GIST diagnosis and primary therapy-naïve tumors with curative resection were eligible (R0 or R1). The information on clinicopathological factors, follow-up data and the mutational status of *KIT* and *PDGFRA* were available. Patients undergoing neoadjuvant imatinib or chemoradiotherapy for GIST before surgery were excluded. GIST was diagnosed based on histopathological features, immunochemical findings and genotype according to the 5th edition of the WHO classification (9). The study was approved by the ethics committee of Peking University First Hospital and was conducted in compliance with the Declaration of Helsinki. Written patient consent for use of their tissues in research was obtained.

For each case, the histological assessment included location, tumor size, mitotic count per 50 high-power fields (HPF; equivalent to 5 mm²), cell type and the presence or absence of rupture. Risk was stratified and prognostic grades were evaluated according to the modified NIH consensus and WHO classification, respectively (6,9).

Immunohistochemical staining was carried out on 4- μ m thick sections from a total of 302 cases of paraffin-embedded tissue blocks which were fixed using 10% formalin at room temperature for 24 h. Briefly, tissue sections were incubated at 65°C for 10 min, followed by two 10-min cycles of deparaffinization using xylene and then hydration in a graded ethanol series (100, 100, 95, 80 and 70% for 2 min, respectively). They were pretreated to promote antigen retrieval in EDTA-Tris (pH 9.0) at 95°C for 20 min (PT Link; Dako; Agilent Technologies, Inc.) and were treated with 3% hydrogen peroxide for 10 min to block endogenous peroxidase. Tissues were subsequently incubated with primary antibodies for

50 min at room temperature. The panel of protein immunostained for GIST diagnosis was as follows: CD117 (working solution, Maixin), DOG1 (1:100; ZSGB-BIO), CD34 (1:200; ZSGB-BIO), Ki67 (1:100; ZSGB-BIO), S-100 (1:200; ZSGB-BIO), SDHB (1:100; ZSGB-BIO), smooth muscle actin (1:200; ZSGB-BIO) and desmin (1:100; ZSGB-BIO). Sections were incubated with secondary antibody using a EnVision™, FLEX+, High pH kit (cat. no. K8002; Dako; Agilent Technologies, Inc.) according to the manufacturer's instructions. Strong positive expression of CD117, DOG1, CD34 or SDHB in >50% of the tumor tissue was defined as cytoplasmic immunopositivity by eye under a light microscope.

Follow-up were performed for 259 GIST cases and patient information was obtained by regular outpatient visits or by telephone. Relapse-free survival (RFS) was defined as the duration from surgery to relapse (local recurrence or metastasis). Relapse was identified based on biopsy and/or imaging assessment.

Gene mutation analysis. Genomic DNA was extracted from formalin-fixed, paraffin-embedded tissue using a DNeasy Blood & Tissue Kit (Qiagen, Inc.). Prior to extraction, histological assessment was performed to ensure that the percentage of tumor in the specimens by area was >80%. Mutational analysis of *KIT* and *PDGFRA* was carried out by PCR amplification, followed by Sanger sequencing of the amplified products. Briefly, initial amplification was performed using Takara LA Taq polymerase (cat. no. RR02MA; Takara Bio, Inc.). The PCR amplification program was as follows: Denaturation at 94°C for 5 min, 45 cycles of denaturation at 94°C for 30 sec, annealing at 56°C for 45 sec, extension at 72°C for 20 sec, and finally, incubation at 72°C for 10 min. The sequencing reaction products were electrophoresed on an ABI3700 genetic analyzer (Applied Biosystems; Thermo Fisher Scientific, Inc.). *KIT* exons 9, 11, 13 and 17, and *PDGFRA* exons 12, 14 and 18 were analyzed. The primer sequences used are shown in Table SI.

Statistical analysis. For univariate analysis, the χ^2 test or Fisher's exact test was used to compare categorical variables. Survival analysis was carried out using the Kaplan-Meier method, and statistical significance was determined using the log-rank test. Univariate and multivariate Cox proportional hazard models were used to determine the prognostic impact of variables on RFS. The strengths of the associations are shown as hazard ratios (HRs) and corresponding 95% confidence intervals (CIs). A 2-sided $P < 0.05$ was considered to indicate a statistically significant result. Analyses were performed using IBM SPSS Statistics V23.0 software (IBM Corp.).

Results

Clinicopathological characteristics. The detailed clinical and pathological characteristics of the 302 patients with GISTs are provided in Table I. There were 160 males (53.0%) and 142 females (47.0%), who ranged in age from 13 to 84 years (median, 61.8 years), with patients >60 years old accounting for 54.3% of cases. The majority of tumors were located in the stomach (66.9%), and the small intestine was the second most common location (25.5%). Only 14 cases

Table I. Clinicopathological and mutational characteristics of GISTs (n=302).

Characteristics	All cases (n=302)	Gastric (n=202)	Non-gastric (n=100)
Sex			
Male	160 (53.0)	94 (46.5)	66 (66.0)
Female	142 (47.0)	108 (53.5)	34 (34.0)
Age (years)			
Median (range)	61.8 (13-84)	62.5 (13-82)	59.8 (31-84)
≤60	138 (45.7)	85 (42.1)	53 (53.0)
>60	164 (54.3)	117 (57.9)	47 (47.0)
Site			
Stomach	202 (66.9)	202 (100.0)	NA
Small intestine	77 (25.5)	NA	77 (77.0)
Colon or rectum	14 (4.6)	NA	14 (14.0)
Others	9 (3.0)	NA	9 (9.0)
Tumor dimension (cm)			
Median (range)	4.2 (0.3-26.0)	3.4 (0.3-21.0)	5.9 (1.5-26.0)
≤2	62 (20.5)	56 (27.7)	6 (6.0)
>2 to ≤5	121 (40.1)	85 (42.1)	36 (36.0)
>5 to ≤10	78 (25.8)	42 (20.8)	36 (36.0)
>10	41 (13.6)	19 (9.4)	22 (22.0)
Mitotic count (/50HPF)			
Median (range)	2.4 (0-80)	2.4 (0-60)	2.4 (0-80)
≤5	229 (75.8)	157 (77.7)	72 (72.0)
>5	73 (24.2)	45 (22.3)	28 (28.0)
Necrosis			
Present	67 (22.2)	31 (15.3)	36 (36.0)
Absent	235 (77.8)	171 (84.7)	64 (64.0)
Morphology			
Spindle	264 (87.4)	181 (89.6)	83 (83.0)
Epithelioid	9 (3.0)	6 (3.0)	3 (3.0)
Mixed	29 (9.6)	15 (7.4)	14 (14.0)
Risk stratification			
Very low	58 (19.2)	53 (26.2)	5 (5.0)
Low	104 (34.4)	70 (34.7)	34 (34.0)
Intermediate	52 (17.2)	45 (22.3)	7 (7.0)
High	88 (29.1)	34 (16.8)	54 (54.0)
WHO grade			
1	58 (19.2)	53 (26.2)	5 (5.0)
2	108 (35.8)	74 (36.6)	34 (34.0)
3a	50 (16.6)	26 (12.9)	24 (24.0)
3b	14 (4.6)	5 (2.5)	9 (9.0)
4	4 (1.3)	3 (1.5)	1 (1.0)
5	14 (4.6)	12 (5.9)	2 (2.0)
6a	25 (8.3)	14 (6.9)	11 (11.0)
6b	29 (9.6)	15 (7.4)	14 (14.0)
CD117 immunostaining			
Positive	287 (95.0)	191 (94.6)	96 (96.0)
Negative	15 (5.0)	11 (5.4)	4 (4.0)
DOG1 immunostaining			
Positive	282 (93.4)	187 (92.6)	95 (95.0)
Negative	20 (6.6)	15 (7.4)	5 (5.0)
CD34 immunostaining			
Positive	245 (81.1)	192 (95.0)	53 (53.0)
Negative	57 (18.9)	10 (5.0)	47 (47.0)

Table I. Continued.

Characteristics	All cases (n=302)	Gastric (n=202)	Non-gastric (n=100)
<i>KIT</i> mutation			
WT	69 (22.8)	55 (27.2)	14 (14.0)
Exon 9	16 (5.3)	4 (2.0)	12 (12.0)
Exon 11	210 (69.5)	139 (68.8)	71 (71.0)
Substitution	79 (26.2)	58 (28.7)	21 (21.0)
Deletion ^a	110 (36.4)	67 (33.2)	43 (43.0)
Duplication	21 (7.0)	14 (6.9)	7 (7.0)
Exon 13	4 (1.3)	2 (1.0)	2 (2.0)
Exon 17	3 (1.0)	2 (1.0)	1 (1.0)
<i>PDGFRA</i> mutation			
WT	272 (90.1)	176 (87.1)	96 (96.0)
Exon 12	1 (0.3)	0 (0.0)	1 (1.0)
Exon 14	2 (0.7)	2 (1.0)	0 (0.0)
Exon 18	27 (8.9)	24 (11.9)	3 (3.0)
WT <i>KIT</i> / <i>PDGFRA</i>	39 (12.9)	29 (14.4)	10 (10.0)

^aOne case with the coexistence of exon 11 deletion and exon 13 duplication. Unless otherwise stated, results are presented as n (%). GISTs, gastrointestinal stromal tumors; HPF, high-power fields; WHO, World Health Organization; DOG1, discovered on GIST-1; *KIT*, *KIT* proto-oncogene, receptor tyrosine kinase; WT, wild type; *PDGFRA*, platelet derived growth factor receptor α .

(4.6%) had tumors in the colon or rectum, and the remaining locations (3.0%) involved the prostate (1 case), retroperitoneum (2 cases), abdominal cavity (5 cases) and pelvic cavity (1 case). The tumor size ranged from 0.3 to 26.0 cm (median, 4.2 cm) at initial diagnosis, and was ≤ 5 cm in most cases (60.6%) and >10 cm in 41 cases (13.6%). However, the sizes of the tumors in non-gastric sites were larger than those in the stomach. Most GISTs (75.8%) exhibited low mitotic activity ($\leq 5/50$ HPF), with no marked difference between gastric and non-gastric sites. Tumor necrosis was observed in 67 cases (22.2%), and was predominant in non-gastric sites. Only 2 cases (0.7%) had a ruptured tumor. The predominant morphology was spindle variant (87.4%), and only 9 cases (3.0%) presented epithelioid histology, which was more frequently seen in tumors in the stomach. The remaining 29 cases (9.6%) featured a combination of spindle and epithelioid morphology (mixed variant).

Strong expression of CD117, DOG1 and CD34 was detected in the majority of GIST cases (95.0, 93.4 and 81.1%, respectively). Among these cases, triple expression was detected in 219 cases (72.5%), double expression in 74 cases (24.5%) and single expression in 9 cases (3.0%). No triple-negative cases were observed in the study. Notably, CD34 expression was more frequently detected in tumors located in the stomach than in other sites (78.4 vs. 21.6%), and the loss of CD34 expression was predominant in specimens with epithelioid and mixed variant morphology (33.3 and 34.5%, respectively).

Based on the modified NIH consensus (6), as shown in Table I, more than half of cases were assessed as low or very low risk (162/302, 53.6%). There was very low risk of relapse in 19.2% of cases, in which the tumors were predominantly located in gastric sites. There was a high risk of relapse in

88 cases (29.1%), and this assessment was more frequent for non-gastric GISTs than for gastric GISTs. Correspondingly, based on the prognostic assessment recommended by the WHO classification (9), grade 6b tumors were predominantly located outside of the stomach, while grade 1 tumors were more frequently detected in the stomach (Table I).

Genotype analysis. Analyses of *KIT* and *PDGFRA* mutations were performed for all 302 GIST specimens in the present study. In total, *KIT* and *PDGFRA* mutations were identified in 233 (77.2%) and 30 (9.9%) cases, respectively, and WT *KIT* and *PDGFRA* were found in 39 specimens (12.9%). The mutational landscape is presented in Tables I and II. The predominant genotype was *KIT* exon 11 deletion (36.4%), followed by *KIT* exon 11 substitution (26.2%), *PDGFRA* exon 18 substitution (7.3%) and *KIT* exon 11 duplication (7.0%).

As shown in Fig. 1B, the spectrum of the exon 11 mutations involved codons ranging from codon 548 to 589. Among these codons, the more frequent mutations were found in codons 557-560, which harbored deletion and/or substitution subtypes, and the less frequent mutations were observed in codons 572-580, which exhibited duplication mutations. The length of the in-frame deletion ranged from 3 to 15 bp. The most prevalent type of deletion, involving codons 557/558/559, was identified in 86 cases (28.5%). Substitutions mostly involved codons 559 (n=36; p.V559D, p.V559A, p.V559G), 560 (n=20; p.V560D, p.V560E, p.V560G), 576 (n=9; p.L576P) and 557 (n=8; p.W557R, p.W557G).

In-frame duplication of exon 9 was detected in 16 cases (5.3%), and comprised p.A502_Y503dup (n=15) and p.F506_F508dup (n=1). There were 4 cases with exon 13 substitution (all p.K642E) and 3 cases with exon 17 substitutions (p.N822K, p.N822Y). Notably, in one tumor, the coexistence of exon 11

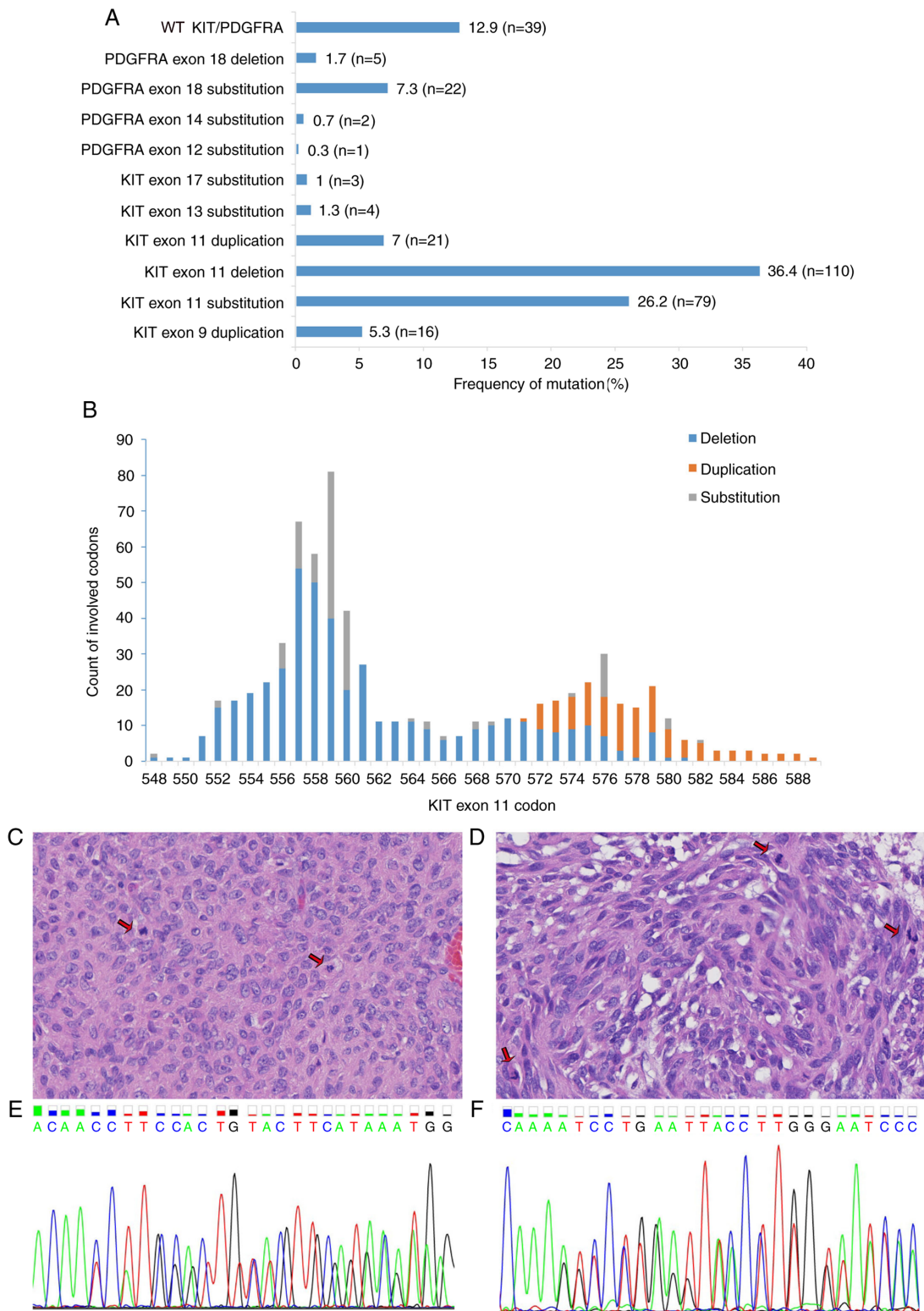


Figure 1. Spectrum of *KIT* and *PDGFRA* mutations in 302 cases of GISTs. (A) Distribution of *KIT* and *PDGFRA* mutations. *KIT* exon 11 deletion was the most common genotype (36.4%, n=110) among the GISTs. Less frequent mutations included *KIT* exon 11 substitution (26.2%, n=79) and *PDGFRA* exon 18 substitution (7.3%, n=22). *KIT* exon 17 substitution, *PDGFRA* exon 12 substitution and exon 14 substitution were rare genotypes. (B) Counts of *KIT* exon 11 codons affected by deletion, duplication and substitution are depicted. Deletions and substitutions frequently involved codons 557-560, whereas duplication was observed in codons 572-580. (C-F) One patient with a GIST exhibited the coexistence of *KIT* exon 11 deletion and exon 13 duplication. The specimen of this patient presented (C) epithelioid and (D) spindle morphology and high mitotic activity (arrows). Hematoxylin and eosin staining (magnification, x400). In this patient, the (E) in-frame deletion of *KIT* exon 11 (codons 553-558) and (F) in-frame insertion of exon 13 (one base pair insertion between codons 642 and 643) were detected. *KIT*, *KIT* proto-oncogene, receptor tyrosine kinase; *PDGFRA*, platelet derived growth factor receptor α ; GIST, gastrointestinal stromal tumor.

p.Y553_K558del and exon 13 duplication (one base pair insertion between codons 642 and 643) at a hotspot mutation site

was observed. This tumor, whose size was >10 cm and mitotic count was >5/50 HPF, presented spindle and epithelioid

Table II. Associations between *KIT* mutations and clinicopathological characteristics of patients with GISTs (n=302).

Characteristics	KIT exon11 mutation, n (%)		P-value	KIT mutation, n (%)		P-value
	Deletion (n=110)	Substitution (n=79)		Del 557/558/559 (n=86)	Others (n=147)	
Sex						
Male	57 (51.8)	37 (46.8)	0.499	48 (55.8)	74 (50.3)	0.419
Female	53 (48.2)	42 (53.2)		38 (44.2)	73 (49.7)	
Age (years)						
≤60	51 (46.4)	30 (38.0)	0.250	40 (46.5)	62 (42.2)	0.520
>60	59 (53.6)	49 (62.0)		46 (53.5)	85 (57.8)	
Site						
Gastric	67 (60.9)	58 (73.4)	0.073	54 (62.8)	93 (63.3)	0.942
Non-gastric	43 (39.1)	21 (26.6)		32 (37.2)	54 (36.7)	
Tumor dimension (cm)						
≤2	15 (13.6)	15 (19.0)	0.051	12 (14.0)	24 (16.3)	0.449
>2 to ≤5	44 (40.0)	42 (53.2)		34 (39.5)	64 (43.5)	
>5 to ≤10	30 (27.3)	16 (20.3)		22 (25.6)	40 (27.2)	
>10	21 (19.1)	6 (7.6)		18 (20.9)	19 (12.9)	
Mitotic count (/50HPF ^a)						
≤5	68 (61.8)	66 (83.5)	0.001	50 (58.1)	117 (79.6)	<0.001
>5	42 (38.2)	13 (16.5)		36 (41.9)	30 (20.4)	
Necrosis						
Present	35 (31.8)	12 (15.2)	0.009	27 (31.4)	33 (22.4)	0.132
Absent	75 (68.2)	67 (84.8)		59 (68.6)	114 (77.6)	
Morphology						
Spindle	97 (88.2)	75 (94.9)	0.246	74 (86.0)	137 (93.2)	0.072
Epithelioid	1 (0.9)	0 (0.0)		1 (1.2)	1 (0.7)	
Mixed	12 (10.9)	4 (5.1)		11 (12.8)	9 (6.1)	
Risk stratification						
Not high ^b	66 (60.0)	64 (81.0)	0.002	50 (58.1)	106 (72.1)	0.029
High	44 (40.0)	15 (19.0)		36 (41.9)	41 (27.9)	
WHO grade						
1/2/3a/4	68 (61.8)	63 (79.7)	0.008	50 (58.1)	110 (74.8)	0.008
3b/5/6a/6b	42 (38.2)	16 (20.3)		36 (41.9)	37 (25.2)	

^aEqual to 5 mm², ^bvery low/low/intermediate. GISTs, gastrointestinal stromal tumors; KIT, KIT proto-oncogene, receptor tyrosine kinase; HPF, high-power fields; WHO, World Health Organization.

morphology, and was classified as NIH high risk and high WHO grade 6b (Fig. 1C-F). Whether this patient received adjuvant therapy after resection is unknown.

The most frequent type of *PDGFRA* mutation comprised exon 18 substitutions involving codons 842 (n=21; p.D842V, p.D842T, p.D842Y) and 839 (n=1; p.L839Q). Exon 18 deletions were also found in 5 cases (p.D842_H845del, p.M844_S847del, p.M844_D846del). In addition, *PDGFRA* exon 12 (p.Y555C) and exon 14 (p.N659K) substitutions were detected in 1 and 2 cases, respectively.

Genotype and clinicopathological characteristics. The associations between genotype and clinicopathological characteristics are presented in Tables I and II. The *KIT* exon 11

substitution subtype was commonly detected in tumors at gastric sites (58/79, 73.4%), while *KIT* exon 9 duplication was more frequently found in tumors at non-gastric sites (12/16, 75%). In addition, *PDGFRA* exon 18 substitutions and deletions were more frequent in tumors of the stomach (24/27, 88.9%) than in those of other sites. Larger (>10 cm) tumors were more likely to bear GISTs with *KIT* exon 11 deletions than exon 11 substitutions. *KIT* exon 11 deletions were also more frequent than *KIT* exon 11 substitutions in tumors with high mitotic counts (>5/50 HPF), a high risk of relapse and high (3b/5/6a/6b) WHO grades (Table II; all P<0.05). Deletions involving *KIT* codons 557/558/559 were more frequently identified in gastric GISTs than in non-gastric GISTs (62.8 vs. 37.2%, respectively). Furthermore, when compared with cases with other

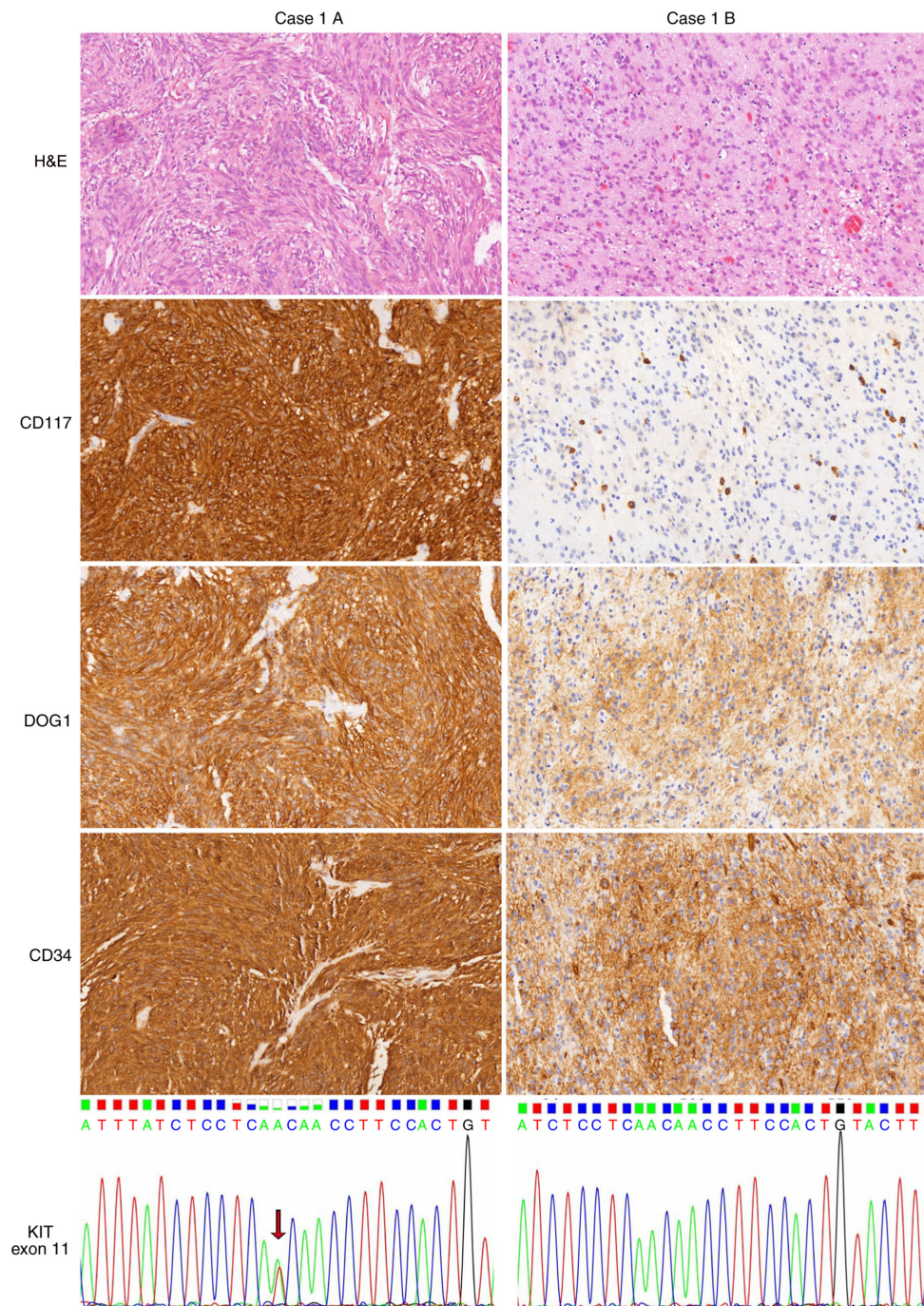


Figure 2. Heterogeneity of GISTs in one patient (case 1). Case 1A, a GIST at the greater curvature of the stomach, showed spindle cell and in distinct storiform morphology, with the strong expression of CD117, DOG1 and CD34 and the presence of *KIT* exon 11 substitution (p.V560D, arrow). By contrast, case 1B, a GIST at the lesser curvature of the stomach, had epithelioid morphology with uniform nuclei and cytoplasmic vacuoles. The tumor was positive for DOG1 and CD34 but negative for CD117. Mast cells served as an internal positive control. No mutation involving *KIT* exon 11 was detected in case 1B. Images show H&E, CD117, DOG1 and CD34 staining (magnification, x200). GIST, gastrointestinal stromal tumor; DOG1, discovered on GIST-1; KIT, KIT proto-oncogene, receptor tyrosine kinase; H&E, hematoxylin and eosin.

KIT mutations, cases with exon 11 deletions involving codons 557/558/559 were significantly associated with worse clinicopathological features: High mitotic activity, high risk according to the NIH classification and high WHO grade (Table II; all $P < 0.05$). These findings suggested that *KIT* exon 11 deletions, particularly those involving codons 557/558/559, may contribute to poor prognosis.

In the present study, 6 cases had two nodular masses that were located in different sites of the abdominal cavity at the

initial diagnosis of the primary tumor. Their clinicopathological features and genotypes are provided in Table III. Notably, in 4 cases (cases 1, 2, 5 and 6), specimens from the two different locations presented distinct morphological appearances and genetic alterations. However, in the other two cases (cases 3 and 4), the same morphological manifestations and genotypes were observed in specimens from both locations. In case 1, the primary tumor in the greater curvature of the stomach had spindle morphology, strong CD117

Table III. Features of patients with GISTs of heterogenous morphology, immunostaining and genotype.

Case no.	Sex	Age (years)	Case part	Site	Morphology	Mitoses (/50HPF) ^a	Expression					KIT mutation	PDGFRA mutation
							CD117	DOG1	CD34	Ki67 (%)			
1	F	66	A	Greater curvature of the stomach	Spindle	4	(+)	(+)	(+)	(+)	5	Exon 11 p.V560D	WT
			B	Lesser curvature of the stomach	Epithelioid	1	(-)	(+)	(+)	(+)	2	WT	WT
2	M	70	A	Posterior of the gastric fundus	Mixed	2	(+)	(-)	(+)	(+)	4	Exon 11 p.W557R	WT
			B	Greater curvature of the stomach	Spindle	5	(+)	(+)	(+)	(+)	5	Exon11 p.W557_K558 del	WT
3	F	82	A	Stomach	Spindle	26	(+)	(+)	(+)	(+)	20	Exon 11 p.P551_Q556 del	WT
			B	Omentum	Spindle	40	(+)	(+)	(+)	(+)	40	Exon 11 p.P551_Q556 del	WT
4	M	83	A	Abdominal cavity	Mixed	12	(+)	(+)	(-)	(-)	25	Exon 11 p.T574_Q575 insP	WT
			B	Small intestine	Mixed	12	(+)	(+)	(-)	(-)	20	Exon 11 p.T574_Q575 insP	WT
5	M	71	A	Stomach	Mixed	25	(+)	(+)	(+)	(+)	40	Exon 11 p.V555-V559del	WT
			B	Omentum	Spindle	20	(+)	(+)	(+)	(+)	30	Exon 11 p.Q556-V560del	WT
6	F	39	A	Stomach	Mixed (pleomorphic)	6	(+)	(+)	(-)	(-)	5	Exon 11 p.D579del	WT
			B	Between stomach and spleen	Spindle	1	(+)	(+)	(+)	(+)	3	Exon 11 p.W557G	WT

^aEqual to 5 mm². GISTs, gastrointestinal stromal tumors; HPF, high-power fields; DOG1, KIT proto-oncogene, receptor tyrosine kinase; PDGFRA, platelet derived growth factor receptor α ; F, female; M, male; WT, wild-type.

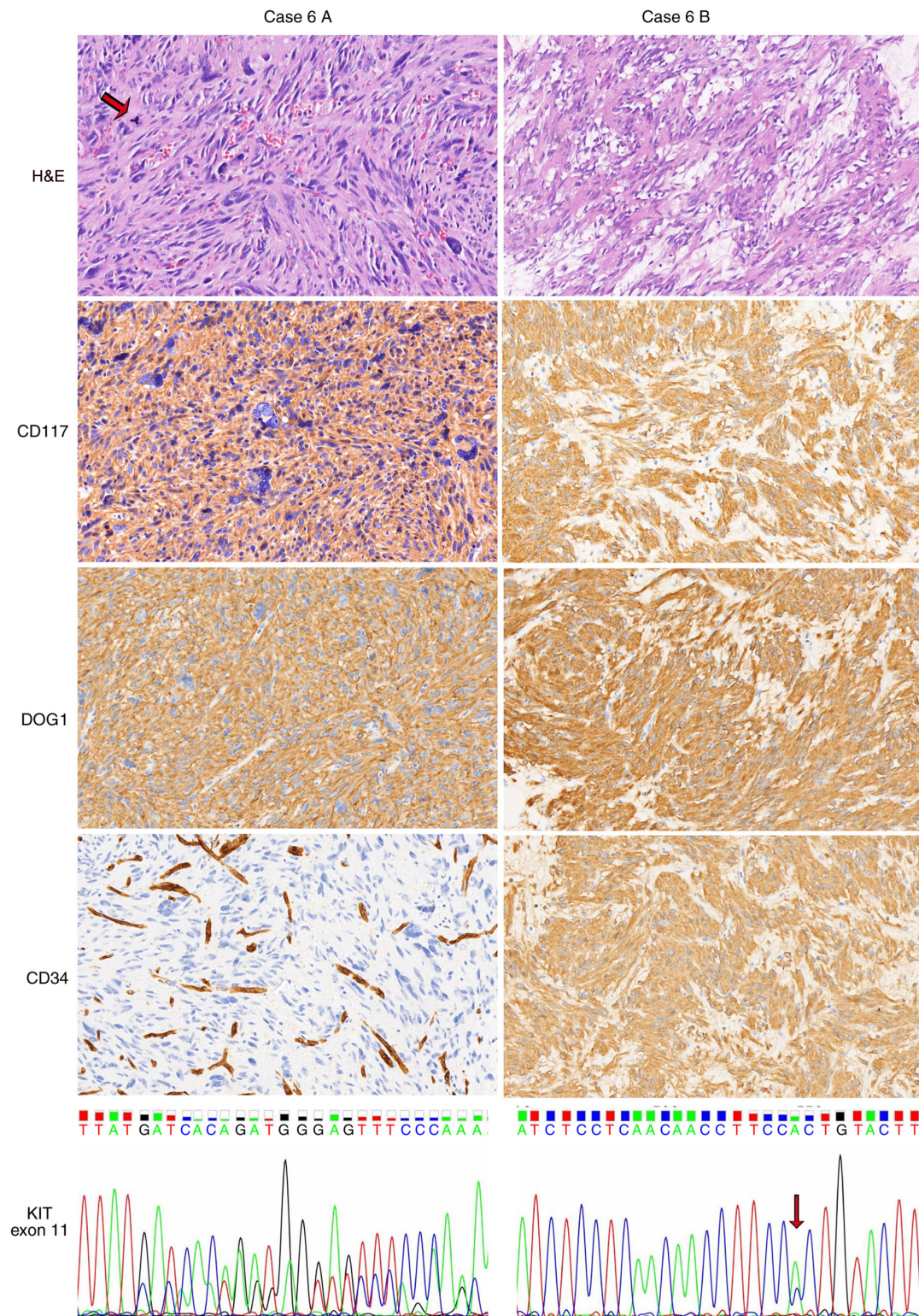


Figure 3. Heterogeneity of GISTs in a second patient (case 6). Hypercellular and pleomorphic histology was visible in the specimen of case 6A, a gastric GIST. Multinucleated giant cells and pathological mitoses (arrow) were observed. The tumor in case 6A was positive for CD117 and DOG1 but negative for CD34. Endothelial cells served as an internal positive control. Case 6B, a GIST between the stomach and spleen, exhibited a conventional spindle cell morphology, with the presence of myxoid stroma and the strong expression of CD117, DOG1 and CD34. *KIT* codon 579 was deleted in case 6A, whereas a *KIT* exon 11 substitution (p.W557G, arrow) existed in case 6B. Images show H&E, CD117, DOG1 and CD34 staining (magnification, x200). GIST, gastrointestinal stromal tumor; DOG1, discovered on GIST-1; KIT, KIT proto-oncogene, receptor tyrosine kinase; H&E, hematoxylin and eosin.

expression and *KIT* p.V560D mutation, whereas the other mass in the lesser curvature of the stomach was an epithelioid variant with loss of CD117 expression and WT *KIT* (Fig. 2). In case 6, as depicted in Fig. 3, most of the specimens of

the tumor in the stomach (case 6A) exhibited anaplastic/pleomorphic morphology with multinucleated giant cells, high mitotic activity and necrosis, but the tumor located between the stomach and spleen (case 6B) predominantly

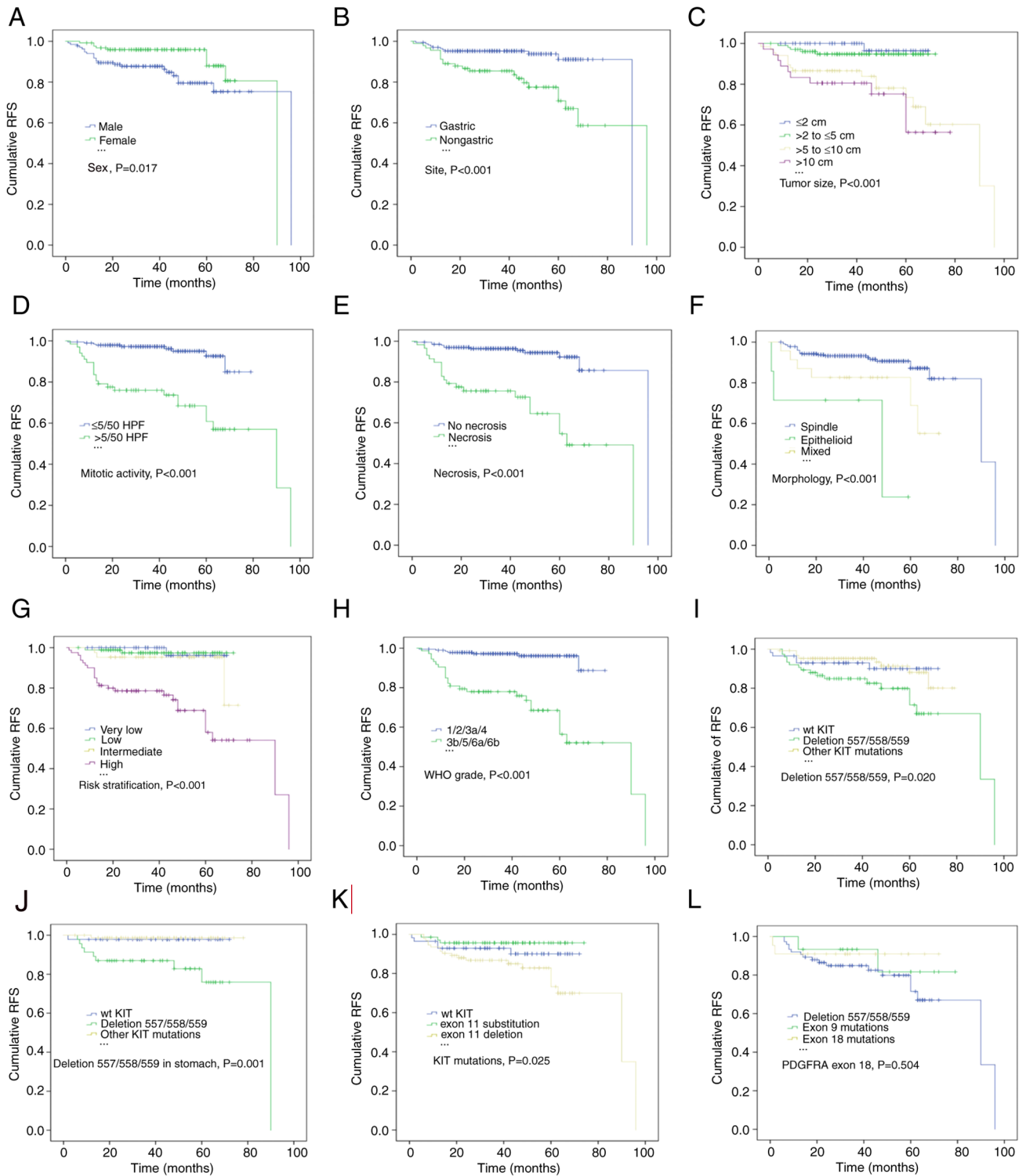


Figure 4. Estimates of RFS in patients with GISTs by Kaplan-Meier survival analysis with log-rank tests. (A) Male sex, (B) non-gastric origin, (C) tumor size >5 cm, (D) mitotic count $>5/50$ HPF and (E) necrosis were associated with a lower RFS rate. (F) Compared with spindle and mixed morphology, the epithelioid subtype was significantly associated with a shorter RFS. According to the (G) National Institutes of Health and (H) WHO classifications, patients classified as high risk and high grade (3b/5/6a/6b) had significantly lower RFS rates. *KIT* deletions involving codons 557/558/559 significantly reduced the RFS rates of patients with (I) GISTs and (J) gastric GISTs compared with those of patients with other *KIT* mutations or WT *KIT*. (K) *KIT* exon 11 substitution indicated a significantly improved RFS for patients with GISTs. (L) Patients with *PDGFRA* exon 18 mutations had a higher RFS rate, although the difference from that of patients with other *PDGFRA* mutations was not statistically significant. RFS, relapse-free survival; GIST, gastrointestinal stromal tumor; HPF, high-power fields; WHO, World Health Organization; *KIT*, *KIT* proto-oncogene, receptor tyrosine kinase; WT, wild-type; *PDGFRA*, platelet derived growth factor receptor α .

exhibited spindle histology. The deletion of *KIT* codon 579 occurred in the former, while *KIT* substitution (p.W557G) occurred in the latter. Furthermore, CD34 expression was

lost in the specimen of case 6A but not in that of case 6B. Thus, GISTs presented heterogeneous histopathological, immunostaining and gene mutation features, suggesting the

Table IV. Univariate and multivariate analysis of clinicopathological features and mutational status affecting the RFS of patients with GISTs (n=259).

Variables	Univariate		Multivariate	
	HR (95% CI)	P-value	HR (95% CI)	P-value
Sex				
Male	1.0 (reference)		1.0 (reference)	
Female	0.412 (0.195-0.873)	0.021	0.694 (0.303-1.587)	0.387
Age (years)				
≤60	1.0 (reference)		1.0 (reference)	
>60	1.229 (0.606-2.489)	0.568	1.848 (0.872-3.914)	0.109
Site				
Gastric	1.0 (reference)		1.0 (reference)	
Non-gastric	3.383 (1.629-7.025)	0.001	2.420 (1.116-5.251)	0.025
Morphology				
Mixed	1.0 (reference)		1.0 (reference)	
Spindle	0.351 (0.142-0.870)	0.024	0.911 (0.352-2.357)	0.847
Epithelioid	3.293 (0.914-11.865)	0.068	2.605 (0.578-11.728)	0.212
Risk stratification				
Very low/low	1.0 (reference)		1.0 (reference)	
Intermediate/high	10.359 (3.147-34.101)	<0.001	3.528 (0.772-16.135)	0.104
WHO grade				
1/2/3a/4	1.0 (reference)		1.0 (reference)	
3b/5/6a/6b	9.125 (3.930-21.187)	<0.001	3.166 (1.033-9.708)	0.044
<i>KIT</i> mutation				
Other mutations	1.0 (reference)		1.0 (reference)	
<i>KIT</i> del 557/558/559	2.722 (1.235-6.003)	0.013	2.794 (1.204-6.482)	0.017
WT	1.126 (0.385-3.298)	0.828	2.087 (0.586-7.432)	0.256

RFS, relapse-free survival; GISTs, gastrointestinal stromal tumors; HR, hazard ratio; CI, confidence interval; WHO, World Health Organization; *KIT*, *KIT* proto-oncogene, receptor tyrosine kinase; WT, wild-type.

need for comprehensive mutation detection and highlighting new challenges for diagnosis and therapy.

To evaluate the occurrence of morphological or genotypic heterogeneity in relapsed or metastatic GIST cases, histological and mutational analyses were performed for 9 patients with progression after resection (8 cases with recurrence and 1 case with hepatic metastasis). Of these cases, 3 were receiving imatinib treatment prior to progression. Notably, the morphological, immunohistochemical and mutational phenotypes of the primary tumors were observed to be the same as those of the recurrent and/or metastatic tumors (data not shown), suggesting the existence of homogenous features in recurrent and/or metastatic tumors, in contrast to the aforementioned primary tumors with two masses.

Succinate dehydrogenase (SDH)-deficient GIST accounts for approximately half of all WT GISTs. Previous studies have demonstrated that all SDH mutations are reliably detected by the loss of SDH subunit B (SDHB) expression using immunostaining (19,20). Thus, SDHB-immunohistochemistry (IHC) is an efficient method for the detection of SDH deficiency. In the present study, the results of SDHB-IHC were obtained for 139 GIST cases. Loss of SDHB expression was detected in 5 cases

(3.6%), suggesting the presence of SDH-deficient GIST. These SDH-deficient GIST tumors, which were predominantly found in women (4 cases), occurred in the stomach and in older adults (age ≥48 years). The tumor cells of SDH-deficient GIST exhibited spindle morphology, which is not in accordance with previous observations of the predominance of epithelioid or mixed types.

Survival analysis. Follow-up data were available for 259 GIST cases. In this group, the median follow-up time ranged from 12 to 129 months (median, 45 months), and the median RFS ranged from 1 to 96 months (median, 41 months). Of these cases, regular imatinib therapy following surgery was received by 59 cases (22.8%), including 40 cases classified as high risk, 17 cases classified as intermediate risk, and 2 cases classified as low risk. Disease progression was observed in 33 cases (12.7%) and hepatic metastasis occurred in 11 cases (4.2%).

Kaplan-Meier survival analysis and log-rank tests indicated that male sex, a larger tumor size (>5 cm), a high mitotic index (>5/50 HPF), necrosis and epithelioid morphology were associated with an inferior RFS (Fig. 4; P=0.017, P<0.001, P<0.001, P<0.001, respectively). In addition, patients with

Table V. Univariate and multivariate analysis of clinicopathological features and mutational status affecting the RFS of patients with gastric GISTs (n=168).

Variables	Univariate		Multivariate	
	HR (95% CI)	P-value	HR (95% CI)	P-value
Sex				
Male	1.0 (reference)		1.0 (reference)	
Female	0.318 (0.082-1.232)	0.097	0.407 (0.090-1.835)	0.242
Age (years)				
≤60	1.0 (reference)		1.0 (reference)	
>60	1.757 (0.453-6.810)	0.415	3.615 (0.684-19.108)	0.130
Morphology				
Mixed	1.0 (reference)		1.0 (reference)	
Spindle	0.219 (0.044-1.087)	0.063	0.319 (0.058-1.753)	0.189
Epithelioid	4.072 (0.559-29.678)	0.166	6.279 (0.628-62.802)	0.118
<i>KIT</i> mutation				
Other mutations	1.0 (reference)		1.0 (reference)	
<i>KIT</i> del 557/558/559	12.832 (1.602-102.768)	0.016	9.820 (1.142-84.484)	0.037
WT	1.612 (0.101-25.789)	0.736	0.855 (0.044-16.666)	0.918

RFS, relapse-free survival; GISTs, gastrointestinal stromal tumors; HR, hazard ratio; CI, confidence interval; WHO, World Health Organisation; *KIT*, *KIT* proto-oncogene, receptor tyrosine kinase; WT, wild-type.

non-gastric GISTs had poorer outcomes than those with gastric tumors (Fig. 4B; $P < 0.001$), and patients classified as high risk and high WHO grade also exhibited significantly lower RFS rate (Fig. 4G and H; all $P < 0.001$). Furthermore, *KIT* deletions involving codons 557/558/559 were significantly associated with a lower RFS rate than other genotypes (Fig. 4I; $P = 0.020$). This adverse effect of *KIT* deletions affecting codons 557/558/559 on RFS was also observed among patients with gastric GISTs (Fig. 4J; $P = 0.001$) but not among those with non-gastric tumors. *KIT* exon 11 deletion was significantly associated with a lower RFS rate, whereas exon 11 substitution was associated with a favorable outcome (Fig. 4K; $P = 0.025$). Compared with codon 557/558/559 deletion, *PDGFRA* exon 18 mutation was associated with a favorable prognosis, although the association was not statistically significant (Fig. 4L, $P = 0.504$).

Univariate analysis revealed that patients who were female or had tumors with spindle morphology had a lower risk of relapse (Table IV; $P = 0.021$ and $P = 0.024$, respectively). Conversely, non-gastric localization, high NIH risk stratification and high WHO grade were significantly associated with a higher risk of relapse [HR (95% CI)=3.383 (1.629-7.025), $P = 0.001$; HR (95% CI)=10.359 (3.147-34.101), $P < 0.001$; HR (95% CI)=9.125 (3.930-21.187), $P < 0.001$, respectively; Table IV]. Additionally, regarding cases with *KIT* deletions involving codons 557/558/559, the risk of tumor progression was almost 3-fold higher than that of cases with other *KIT* mutations [HR (95% CI)=2.722 (1.235-6.003), $P = 0.013$; Table IV]. Multivariate Cox regression analysis also indicated that patients bearing *KIT* deletions involving codons 557/558/559 had an almost 3-fold higher risk of relapse than those with other *KIT* mutations [HR (95% CI)=2.794 (1.204-6.482),

$P = 0.017$; Table IV], suggesting that this genotype is an independent predictor of RFS. According to this multivariate analysis, tumor location and WHO grade also markedly influenced the risk of tumor progression [HR (95% CI)=2.420 (1.116-5.251), $P = 0.025$; HR (95% CI)=3.166 (1.033-9.708), $P = 0.044$; Table IV]. In addition, based on multivariate Cox regression analysis, *KIT* codon 557/558/559 deletion was significantly associated with a high risk of recurrence in the gastric location [HR (95% CI)=9.820 (1.142-84.484), $P = 0.037$; Table V], but not in non-gastric sites (data not shown).

Discussion

The identification of pathological and molecular subtypes is essential in patients with GISTs for prognostic and therapeutic purposes, particularly in the adjuvant and/or advanced disease setting. Previous studies have revealed the prognostic significance of *KIT* and *PDGFRA* mutational alterations; however, studies of GISTs in the Chinese population have only investigated small groups of patients (21,22), and the data remain limited. In the present study, the profile and prognostic value of pathological variables and gene mutations were assessed in a large cohort comprising 302 GIST cases in a single center, with a detailed description of *KIT* and *PDGFRA* mutations and the prognostic value of specific gene alterations.

Based on their morphological manifestations, GISTs are classified as three variants: Spindle, epithelioid and mixed. The present study identified spindle morphology as the predominant variant (87.4%), which is consistent with previous reports. However, the frequency of epithelioid morphology (3.0%), which was mainly observed in GISTs located in the stomach, was lower than that in previous studies

(5-20%) (7,23,24). This discrepancy may be due to selection bias. In addition, tumors characterized by epithelioid and mixed histology showed a higher risk of progression than those of the spindle subtype, which may be due to the manifestation of pleomorphic/anaplastic features and high mitotic activity observed in epithelioid and mixed-histology tumors. In the present study, high mitotic activity and necrosis were also associated with a lower RFS rate, which is consistent with the study by Liu *et al* (25). The majority of specimens in the present study were positive for CD117, DOG1 and CD34 (95.0, 93.4 and 81.1%, respectively). Strong triple and double expression of these markers were detected in 72.5 and 24.5% of specimens, respectively. CD34 negativity was more common in tumors in non-gastric locations and with epithelioid and mixed morphology. In a study by Hashmi *et al* (23), CD117 and CD34 were found to be expressed in 46/48 (95.8%) and 34/46 (73.9%) of GISTs, respectively. The authors also observed that CD34 negativity was associated with epithelioid type. In a study by Liu *et al* (26), the CD34 positivity rate of primary GISTs was 92.3%. Therefore, the combined IHC detection of CD117, DOG1 and CD34 is helpful for GIST diagnosis. In the North American Intergroup Phase III Trial of imatinib mesylate, patients whose tumors were CD117-negative by immunostaining were found to have an inferior prognosis (13). However, no prognostic significance of CD117 expression was observed in the present study.

The frequency of gene mutations in the present study cohort was 87.1%, including 77.2% *KIT* mutations and 9.9% *PDGFRA* mutations. This frequency is in accordance with those detected in two phase III clinical trials of imatinib, conducted by the American College of Surgeons Oncology Group (ACOSOG) (87.4%) (12) and the European Organization for Research and Treatment of Cancer (86.2%) (27). The mutation rates in these trials are higher than those in a study based on the Polish Clinical GIST Registry (82.2%) (10) and a European multicenter analysis (85.1%) (11), but lower than that in a study of Chinese cases (93.8% overall, 89.1% for *KIT* and 4.7% for *PDGFRA*) conducted by Wang *et al* (28). *KIT* mutations have been reported to be associated with a high risk of progression (18,24,27). The proportion of high-risk subtypes in the single-center study conducted by Wang *et al* (28) was higher than that in the present series (42.5 vs. 29.1%, respectively), which explains the relatively lower frequency of *KIT* mutations in the present data. In one study of patients with GISTs in China, *KIT* mutations were identified in 76.1% of CD117-positive GIST cases (21). In another Chinese study, Du *et al* (22) found the frequency of *KIT* and *PDGFRA* mutations in GISTs was 76.6 and 2.8%, respectively. Thus, the frequency of *PDGFRA* mutations in the present study was higher than that in previous studies. In addition, the percentages of patients with tumors >10 cm in diameter and with a mitotic index >5/50 HPF were lower in the present study than in previous studies (10,12), further suggesting that relatively few cases were in a high-risk prognostic group, in contrast with the observations in the aforementioned phase III clinical trials. The spectrum of *KIT* and *PDGFRA* mutations was similar to that described in the literature (10,28). For example, the predominant mutated area of *KIT* exon 11 involved codons 557-560 with deletions and/or substitutions, followed by codons 572-580 with duplication. In addition to the common duplication of codons 502 and 503 of

KIT exon 9, a rare duplication of codons 506-508 was detected in one case. A less common genotype with *PDGFRA* exon 18 deletion was observed in 5 cases (1.7%), but its significance remains unclear.

Importantly, the findings of the present study demonstrated that *KIT* deletions affecting codons 557/558/559 are independent adverse predictors of RFS in patients with GISTs. Patients with deletions involving codons 557/558/559 had a significantly shorter RFS, higher mitotic activity, high risk of relapse (according to the NIH classification) and high WHO grade compared with those of patients with other *KIT* mutations. Previous studies have reported that deletions affecting codons 557/558 are associated with metastasis and poor patient outcomes (17,29). In the Polish Clinical GIST Registry study, patients whose tumors had *KIT* deletions encompassing codons 557/558 had a lower 5-year RFS rate than those with other exon 11 mutations or exon 11 deletions not involving codons 557/558 (10). The study also found that deletions involving codons 557/558 were more frequently present in tumors of larger size, with a higher mitotic count and high risk of relapse. Regarding gastric GISTs, the patients with *KIT* deletions in codons 557/558/559 had an almost 6-fold higher risk of relapse than patients with WT *KIT* (30). In a European multicenter study, *KIT* del-inc557/558 was a predictor of inferior outcomes in patients with gastric GISTs but not those with non-gastric GISTs (11). However, in the ACOSOG Z9001 trial, deletion of codons 557 and/or 558 did not independently affect RFS in either the placebo or imatinib arm (12). In addition, Wang *et al* (28) demonstrated that codon 557/558 deletion was associated with a high mitotic rate but not with 5-year RFS. In the present study, *KIT* deletions involving codons 557/558/559 were significantly associated with a high risk of recurrence in the stomach but not in non-gastric locations. Furthermore, this type of deletion was more frequently identified in gastric GISTs than in non-gastric cases and had an adverse effect on RFS in patients with gastric GISTs. Both the present study and previous studies identified non-gastric origin as an adverse indicator of GIST progression. Thus, we hypothesize that the adverse effect of deletions involving codons 557/558/559 may be associated with malignant features of the tumors, such as a higher mitotic count, which may result from the robust activation of *KIT* signaling. The loss of the side chains of amino acids encoded by codons 553, 557, 559 or 560 may be associated with increased phosphorylation. Deletions of these codons, which encode a juxta-membrane residue, may disrupt the conformation of the *KIT* protein and induce a loss of inhibitory control of the kinase activity in the *KIT* receptor. However, the detailed molecular mechanism requires further study.

The results of the present study suggest that another common molecular alteration, *KIT* exon 11 substitution, was a clinical predictor of an indolent tumor, namely, a tumor of small size, with a low mitotic count, low risk of relapse and low WHO grade. In the survival analysis, patients with exon 11 substitution had a significantly longer RFS than those with exon 11 deletions or WT *KIT*. In a Norwegian population-based study, GISTs with *KIT* substitutions exhibited low mitotic activity (18). In the Polish Clinical GIST Registry study, the 5-year RFS rate of patients with *KIT* exon 11 point mutations was improved compared with that of patients with other *KIT* exon 11 mutations; the study

also documented that tumors with *PDGFRA* mutations had a lower risk of recurrence (10). In the present study, the presence of a *PDGFRA* exon 18 mutation appeared to have a favorable influence on GIST relapse, although the effect was not found to be statistically significant. Thus, *KIT* exon 11 substitution and *PDGFRA* exon 18 mutation may be positive prognostic indicators for disease progression.

Notably, the coexistence of exon 11 deletion and exon 13 duplication was observed in the GIST of one female patient and was characterized by adverse prognostic indicators: larger tumor size, high mitotic activity and high risk of recurrence/relapse. The treatment and prognosis of this patient after resection is unknown as she was lost to follow-up. This molecular alteration is rarely seen, and has been reported in one imatinib-resistant tumor also featuring factors indicative of an inferior prognosis (31). Moreover, the cases in the present study and previous report exhibited a similar morphology (spindle and epithelioid histology). Activating mutations of *KIT* exon 11, particularly deletions, result in ligand-independent activation, ultimately increasing cell proliferation and inhibiting apoptosis, and mutations in *KIT* exon 13, which encodes the ATP-binding region of the protein, are considered to be associated with the autoinhibitory function of the JM domain (15). Thus, we hypothesize that the combination of exon 11 deletion and exon 13 duplication may increase the malignant behavior of GIST and adversely influence patient prognosis.

The existence of tumor heterogeneity with regard to morphology, immunostaining and genotype was observed in the present study. Four cases had tumors with distinct gene mutations and histology at two different sites, and three of these cases also had distinct immunostaining phenotypes. All these distinct gene mutations occurred in *KIT* exon 11, including *KIT* exon 11 p.V560D vs. WT, p.W557R vs. p.W557_K558 del and p.D579 del vs. p.W557G. A previous report emphasized the heterogeneity of clinical resistance to tyrosine kinase inhibitors in GIST (32). Recently, Serrano *et al* (33) detected the presence of secondary *KIT* mutations in patients whose GISTs were resistant to imatinib, and suggested that these distinct mutations may have resulted from tumor subclones that emerged after imatinib therapy. In the present study, the four cases with tumor heterogeneity did not receive any therapy prior to surgery. Furthermore, no heterogeneity was observed between the primary and recurrent and/or metastatic tumors of 9 patients, 3 of whom received imatinib therapy before progression. The observation of heterogeneous morphology, immunostaining and genotype in GISTs may be due to the presence of different tumor subclones, providing further challenges for diagnosis and therapy.

In summary, the present study found that *KIT* and *PDGFRA* mutations were frequent in GISTs. *KIT* exon 11 deletions, particularly deletions affecting codons 557/558/559, were genotypes indicative of more aggressive tumors and were associated with a higher risk of relapse. Furthermore, the emergence of specific genotypes, such as multiple coexisting mutations and heterogeneous genetic alterations, is challenging for individual targeted therapy. Based on different pathological features and *KIT/PDGFRA* mutations, the results contribute to the identification of patients with different subtypes of GIST for tailored adjuvant treatments, and support the notion

that specific molecular phenotypes should be included in the present risk classification system.

Acknowledgements

Not applicable.

Funding

The present study was supported by a research grant (grant no. 2018SF089) from the Scientific Research Seed Fund of Peking University First Hospital.

Availability of data and materials

The datasets used and/or analyzed during the present study are available from the corresponding author on reasonable request.

Authors' contributions

TL designed the study. LL, LN and YD collected and analyzed the patient data. LL, PL and TL evaluated and interpreted the clinicopathological data and mutation phenotypes. XL was responsible for the technical operation of PCR and Sanger sequencing. DL performed the immunohistochemical staining. JL and SH performed the statistical analysis and interpreted the results. LL and TL wrote the manuscript. TL revised the manuscript. All authors have read and approved the final manuscript.

Ethics approval and consent to participate

The present study was approved by the Ethics Committee of Peking University First Hospital and in compliance with the Declaration of Helsinki. Written patient consent for use of their tissues in research was obtained.

Patient consent for publication

Not applicable.

Competing interests

The authors declare that they have no competing interests.

References

- Huizinga JD, Thuneberg L, Klüppel M, Malysz J, Mikkelsen HB and Bernstein A: W/kit gene required for interstitial cells of Cajal and for intestinal pacemaker activity. *Nature* 373: 347-349, 1995.
- Joensuu H, Hohenberger P and Corless CL: Gastrointestinal stromal tumour. *Lancet* 382: 973-983, 2013.
- Yamamoto H and Oda Y: Gastrointestinal stromal tumor: Recent advances in pathology and genetics. *Pathol Int* 65: 9-18, 2015.
- DeMatteo RP, Lewis JJ, Leung D, Mudan SS, Woodruff JM and Brennan MF: Two hundred gastrointestinal stromal tumors: Recurrence patterns and prognostic factors for survival. *Ann Surg* 231: 51-58, 2000.
- Rossi S, Miceli R, Messerini L, Bearzi I, Mazzoleni G, Capella C, Arrigoni G, Sonzogni A, Sidoni A, Toffolatti L, *et al*: Natural history of imatinib-naïve GISTs: A retrospective analysis of 929 cases with long-term follow-up and development of a survival nomogram based on mitotic index and size as continuous variables. *Am J Surg Pathol* 35: 1646-1456, 2011.

6. Joensuu H: Risk stratification of patients diagnosed with gastrointestinal stromal tumor. *Hum Pathol* 39: 1411-1419, 2008.
7. Li J, Ye Y, Wang J, Zhang B, Qin S, Shi Y, He Y, Liang X, Liu X, Zhou Y, *et al*: Chinese consensus guidelines for diagnosis and management of gastrointestinal stromal tumor. *Chin J Cancer Res* 29: 281-293, 2017.
8. Goh BK, Chow PK, Yap WM, Kesavan SM, Song IC, Paul PG, Ooi BS, Chung YF and Wong WK: Which is the optimal risk stratification system for surgically treated localized primary GIST? Comparison of three contemporary prognostic criteria in 171 tumors and a proposal for a modified Armed Forces Institute of Pathology risk criteria. *Ann Surg Oncol* 15: 2153-2163, 2008.
9. Lokuhetty D, White VA and Watanabe R (eds): WHO Classification of Digestive System Tumours. 5th edition. Lyon, IARC Press, pp439-443, 2019.
10. Wozniak A, Rutkowski P, Piskorz A, Ciwoniuk M, Osuch C, Bylina E, Sygut J, Chosia M, Rys J, Urbanczyk K, *et al*: Prognostic value of KIT/PDGFR α mutations in gastrointestinal stromal tumours (GIST): Polish Clinical GIST Registry experience. *Ann Oncol* 23: 353-360, 2012.
11. Wozniak A, Rutkowski P, Schöffski P, Ray-Coquard I, Hostein I, Schildhaus HU, Le Cesne A, Bylina E, Limon J, Blay JY, *et al*: Tumor genotype is an independent prognostic factor in primary gastrointestinal stromal tumors of gastric origin: A European multicenter analysis based on ConticaGIST. *Clin Cancer Res* 20: 6105-6116, 2014.
12. Corless CL, Ballman KV, Antonescu CR, Kolesnikova V, Maki RG, Pisters PW, Blackstein ME, Blanke CD, Demetri GD, Heinrich MC, *et al*: Pathologic and molecular features correlate with long-term outcome after adjuvant therapy of resected primary GI stromal tumor: The ACOSOG Z9001 trial. *J Clin Oncol* 32: 1563-1570, 2014.
13. Heinrich MC, Owzar K, Corless CL, Hollis D, Borden EC, Fletcher CD, Ryan CW, von Mehren M, Blanke CD, Rankin C, *et al*: Correlation of kinase genotype and clinical outcome in the North American intergroup phase III Trial of imatinib mesylate for treatment of advanced gastrointestinal stromal tumor: CALGB 150105 study by cancer and leukemia group B and southwest oncology group. *J Clin Oncol* 26: 5360-5367, 2008.
14. Szucs Z, Thway K, Fisher C, Bulusu R, Constantinidou A, Benson C, van der Graaf WT and Jones RL: Molecular subtypes of gastrointestinal stromal tumors and their prognostic and therapeutic implications. *Future Oncol* 13: 93-107, 2017.
15. Lennartsson J, Jelacic T, Linnekin D and Shivakrupa R: Normal and oncogenic forms of the receptor tyrosine kinase kit. *Stem Cells* 23: 16-43, 2005.
16. Martín-Broto J, Gutierrez A, Garcia-Del-Muro X, Lopez-Guerrero JA, Martinez-Trufero J, de Sande LM, Lainez N, Maurel J, De Juan A, Losa F, *et al*: Prognostic time dependence of deletions affecting codons 557 and/or 558 of KIT gene for relapse-free survival (RFS) in localized GIST: A Spanish group for sarcoma research (GEIS) study. *Ann Oncol* 21: 1552-1557, 2010.
17. Martín J, Poveda A, Llombart-Bosch A, Ramos R, López-Guerrero JA, García del Muro J, Maurel J, Calabuig S, Gutierrez A, González de Sande JL, *et al*: Deletions affecting codons 557-558 of the c-KIT gene indicate a poor prognosis in patients with completely resected gastrointestinal stromal tumors: A study by the Spanish group for sarcoma research (GEIS). *J Clin Oncol* 23: 6190-6198, 2005.
18. Steigen SE, Eide TJ, Wasag B, Lasota J, Lasota J and Miettinen M: Mutations in gastrointestinal stromal tumors—a population-based study from Northern Norway. *APMIS* 115: 289-298, 2007.
19. Gill AJ: Succinate dehydrogenase (SDH) and mitochondrial driven neoplasia. *Pathology* 44: 285-292, 2012.
20. Miettinen M, Wang ZF, Sarlomo-Rikala M, Osuch C, Rutkowski P and Lasota J: Succinate dehydrogenase-deficient GISTs: A clinicopathologic, immunohistochemical, and molecular genetic study of 66 gastric GISTs with predilection to young age. *Am J Surg Pathol* 35: 1712-1721, 2011.
21. He HY, Fang WG, Zhong HH, Li Y, Zheng J, Du J, Heng WJ and Wu BQ: Status and clinical implication of c-kit and PDGFR α mutations in 165 cases of gastrointestinal stromal tumor (GIST). *Zhonghua Bing Li Xue Za Zhi* 35: 262-266, 2006 (In Chinese).
22. Du CY, Shi YQ, Zhou Y, Fu H and Zhao G: The analysis of status and clinical implication of KIT and PDGFR α mutations in gastrointestinal stromal tumor (GIST). *J Surg Oncol* 98: 175-178, 2008.
23. Hashmi AA, Faraz M, Nauman Z, Qureshi MU, Hashmi SK, Waseem HF, Edhi MM, Faridi N and Khan A: Clinicopathologic features and prognostic grouping of gastrointestinal stromal tumors (GISTs) in Pakistani patients: An institutional perspective. *BMC Res Notes* 11: 457, 2018.
24. Mayr P, Märkl B, Agaimy A, Kriening B, Dintner S, Schenkirsch G and Schneider-Stock R: Malignancies associated with GIST: A retrospective study with molecular analysis of KIT and PDGFR α . *Langenbecks Arch Surg* 404: 605-613, 2019.
25. Liu X, Qiu H, Zhang P, Feng X, Chen T, Li Y, Tao K, Li G, Sun X and Zhou Z; China Gastrointestinal Stromal Tumor Study Group (CN-GIST): Prognostic role of tumor necrosis in patients undergoing curative resection for gastric gastrointestinal stromal tumor: A multicenter analysis of 740 cases in China. *Cancer Med* 6: 2796-2803, 2017.
26. Liu FY, Qi JP, Xu FL and Wu AP: Clinicopathological and immunohistochemical analysis of gastrointestinal stromal tumor. *World J Gastroenterol* 12: 4161-4165, 2006.
27. Debiec-Rychter M, Sciort R, Le Cesne A, Schlemmer M, Hohenberger P, van Oosterom AT, Blay JY, Leyvraz S, Stul M, Casali PG, *et al*: KIT mutations and dose selection for imatinib in patients with advanced gastrointestinal stromal tumours. *Eur J Cancer* 42: 1093-1103, 2006.
28. Wang M, Xu J, Zhao W, Tu L, Qiu W, Wang C, Shen Y, Liu Q and Cao H: Prognostic value of mutational characteristics in gastrointestinal stromal tumors: A single-center experience in 275 cases. *Med Oncol* 31: 819, 2014.
29. Wardelmann E, Losen I, Hans V, Neidt I, Speidel N, Bierhoff E, Heinicke T, Pietsch T, Büttner R and Merkelbach-Bruse S: Deletion of Trp-557 and Lys-558 in the juxtamembrane domain of the c-kit protooncogene is associated with metastatic behavior of gastrointestinal stromal tumors. *Int J Cancer* 106: 887-895, 2003.
30. Capelli L, Petracci E, Quagliuolo V, Saragoni L, Colombo P, Morgagni P, Calistri D, Tomezzoli A, Di Cosmo M, Roviello F, *et al*: Gastric GISTs: Analysis of c-Kit, PDGFR α and BRAF mutations in relation to prognosis and clinical pathological characteristics of patients-A GIRCG study. *Eur J Surg Oncol* 42: 1206-1214, 2016.
31. Antonescu CR, Romeo S, Zhang L, Nafa K, Hornick JL, Nielsen GP, Mino-Kenudson M, Huang HY, Mosquera JM, Dei Tos PA and Fletcher CD: Dedifferentiation in gastrointestinal stromal tumor to an anaplastic KIT-negative phenotype: A diagnostic pitfall: Morphologic and molecular characterization of 8 cases occurring either de novo or after imatinib therapy. *Am J Surg Pathol* 37: 385-392, 2013.
32. Liegl B, Kepten I, Le C, Zhu M, Demetri GD, Heinrich MC, Fletcher CD, Corless CL and Fletcher JA: Heterogeneity of kinase inhibitor resistance mechanisms in GIST. *J Pathol* 216: 64-74, 2008.
33. Serrano C, Mariño-Enríquez A, Tao DL, Ketzner J, Eilers G, Zhu M, Yu C, Mannan AM, Rubin BP, Demetri GD, *et al*: Complementary activity of tyrosine kinase inhibitors against secondary kit mutations in imatinib-resistant gastrointestinal stromal tumours. *Br J Cancer* 120: 612-620, 2019.



This work is licensed under a Creative Commons Attribution-NonCommercial-NoDerivatives 4.0 International (CC BY-NC-ND 4.0) License.