



## NOTE

Surgery

# Osteochondrodysplasia in Scottish Fold cross-breed cats

Masamine TAKANOSU<sup>1)\*</sup> and Yuki HATTORI<sup>2)</sup><sup>1)</sup>Nasunogahara Animal Clinic, 2-3574-98 Asaka, Ohtawara, Tochigi 324-0043, Japan<sup>2)</sup>Tokyo Feline Medical Center, 1-5-4 Morishita, Koto-ku, Tokyo 135-0004, Japan*J. Vet. Med. Sci.*

82(12): 1769–1772, 2020

doi: 10.1292/jvms.20-0299

Received: 20 May 2020

Accepted: 23 October 2020

Advanced Epub:

6 November 2020

**ABSTRACT.** Two Scottish Fold mixed cats are described in this report. Case 1 is a mixed Scottish Fold and Munchkin cat. Extremities of this cat resembled the Munchkin cat, while the ear pinna were folded forward like the Scottish Fold cat. Case 2 is a mixed Scottish Fold and American Curl cat. The ear pinna were curled caudally like the American Curl. Severe exostosis in the hind leg was observed in radiographs taken around one year of age in both cats. Both cats were dominant homozygous for c.1024G>T of the *transient receptor potential vanilloid 4* gene, responsible for osteochondrodysplasia in the Scottish Fold cat. Cross breeding with Scottish Fold cats could produce unknown phenotypes, and should be avoided.

**KEY WORDS:** American Curl, Munchkin, osteochondrodysplasia, Scottish Fold

The Scottish Fold cat has folded ear pinna and develop osteochondrodysplasia in the extremities [1]. Both phenotypes are linked and inherited in an autosomal dominant manner [11]. This severe exostosis develops in the extremities and especially in the hind legs, which leads to lameness [1, 4]. Cats with severe exostosis suffer from osteochondrodysplasia through their life. Although radiation therapy may be useful to relieve pain, it is not curative for severe exostosis [2]. Thus, mating cats that have folded ear pinna is contraindicated. Although heterozygous Scottish Fold cats may be unlikely to develop severe exostosis [7, 10], and their bone lesions are mild, each epiphysis of the digit is deformed. In addition, metacarpal, carpal, metatarsal and tarsal bones are irregular in shape, and the boundaries are unclear on radiographs, with enhanced radiographic opacity in these regions. Symptoms in heterozygous cats are mild and do not impair the quality of life [10].

Munchkin cats have short limbs and their long bones are slightly curved. There is an anecdote that dominant homozygous Munchkin cats are embryonically lethal, but there is no report based on genetic examination. Thus, inheritance of skeletal abnormalities in Munchkin cats cannot be confirmed to be dominant or recessive. The Munchkin cat appears to be prone to degenerative joint disease, pectus excavatum and spinal lordosis [6]. Thus, Munchkin cats may have abnormalities similar to pseudoachondroplasia as observed in their human counterparts [5].

The ear pinna of American Curl cats are curled backward, the mechanism of which is unknown so far. The phenotype of American Curl cats has been examined genetically, and this phenotype is inherited in an autosomal dominant manner, and a dominant homozygous cat is not embryonically lethal [9]. Skeletal abnormalities in this breed have not been reported to date.

Recently, a responsible gene mutation for osteochondrodysplasia of the Scottish Fold cat has been identified [3]. A c.1024G>T in the *transient receptor potential vanilloid 4 (TRPV4)* gene coding a calcium-permeable ion channel gives gain of function and leads to abnormal osteochondrogenesis. This mutation has not been identified in many cat species apart from the Scottish Fold cat [3]. Thus, this mutation may be unique to the Scottish Fold cat.

In this report, we describe osteochondrodysplasia of a Scottish Fold cat crossed with the Munchkin cat that has a skeletal abnormality, or the American Curl that has ear pinna curling. Those cross cats were dominant homozygous for c.1024G>T in *TRPV4*.

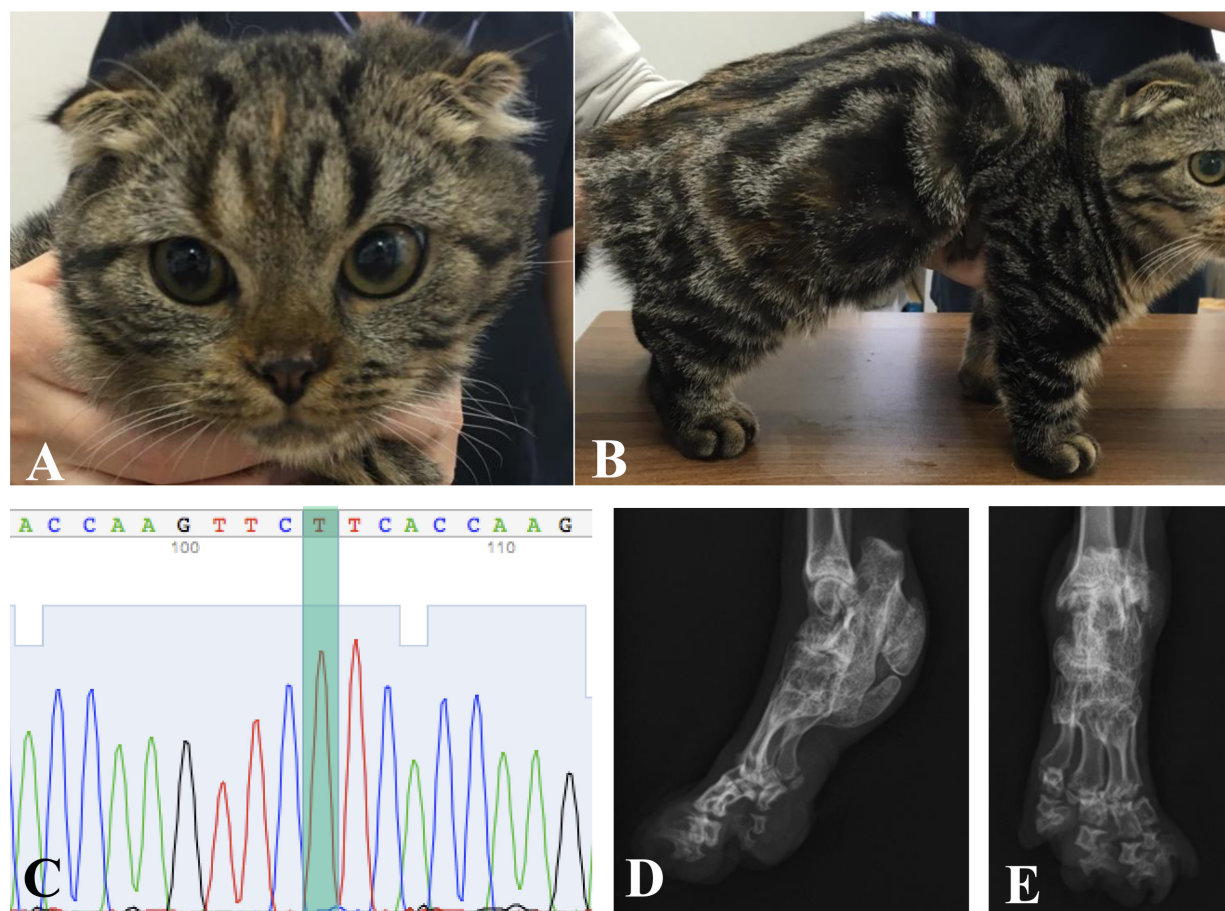
*Case 1: Scottish Fold and Munchkin cross cat:* A cat visited Tokyo Feline Medical Center at five months of age due to anorexia. The cat was the spayed female and the body weight was 1.65 kg. The anorexia improved with symptomatic treatment. Case 1 had been registered as Munchkin on the pedigree certificate; however, the pedigree certificates of the parents and information regarding their external appearance were unavailable. Although the macroscopic features of Case 1 resembled the Munchkin with shortened limbs, the ear pinna were folded forward, resembling the Scottish Fold cat (Fig. 1A and 1B). Thus, we considered that Case 1 was a mixed breed with the Munchkin and Scottish Fold cat. No severe exostosis was observed on the radiograph at five months of age, while the epiphysis of the digits were irregular in shape (data not shown). Genotyping of c.1024G>T in *TRPV4* was performed by Sanger sequencing with genomic DNA extracted from whole blood; the data showed only T at the codon 1024, confirming

\*Correspondence to: Takanosu, M.: volkerhall@me.com

©2020 The Japanese Society of Veterinary Science



This is an open-access article distributed under the terms of the Creative Commons Attribution Non-Commercial No Derivatives (by-nc-nd) License. (CC-BY-NC-ND 4.0: <https://creativecommons.org/licenses/by-nc-nd/4.0/>)

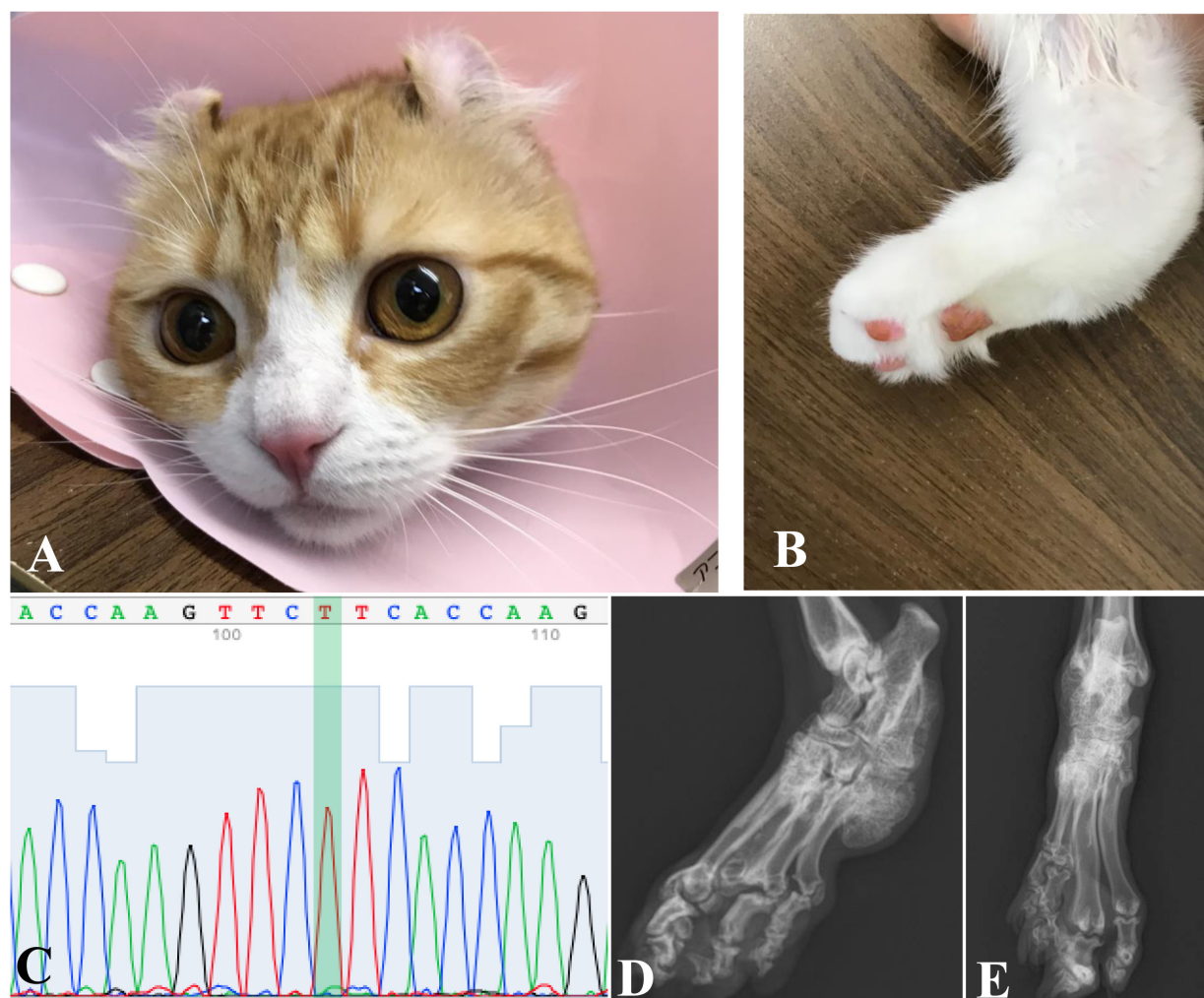


**Fig. 1.** Case 1: The Scottish Fold and Munchkin cross-breed cat. A: ear pinna showing the folding forward configuration, which resembles that of the Scottish Fold cat. B: Limbs are short and appearance (5 months of age) is the same as for Munchkin. C: DNA sequence of *TRPV4* c.1024G>T. The position of codon 1024 is highlighted, showing homozygous T (mutant) but not G (wild type). D and E: Radiographs of the hind leg taken at 12 months of age (D: mediolateral view, E: dorsoplantar view). Severe osteochondrodysplasia is seen at the tarsal joint and digits. A large exostosis is formed at the ventral side of calcaneus. Metatarsal bones are fused to each other.

dominant homozygosity of this mutation (Fig. 1C). Seven months later, when the cat was 12 months of age, severe exostosis was observed in the hind legs on radiographs (Fig. 1D and 1E). The severe exostosis was seen at the bottom of the calcaneus and the metatarsal bones, and the proximal end of the phalanges were fused with each other. The distal ends of the phalanges were irregular in shape.

*Case 2: Scottish Fold and American Curl cross cat:* A cat visited Tokyo Feline Medical Center at 13 months of age for contraceptive surgery. The cat was an intact female with body weight of 2.4 kg. Case 2 had been registered as the American Curl cat on its pedigree certificate. The pedigree certificates of the parents and information as to their external appearance were unavailable. At first glance, the ear pinna were curled backward like the American Curl cat (Fig. 2A). On closer inspection, although the base of the pinna was folded only slightly like Scottish Fold cats, the tip was curled backward like the American Curl cat. Large exostosis on the hind legs was palpated (Fig. 2B). At this point, it was impossible to recognize that Case 2 was mixed with the Scottish Fold cat. Genotyping of c.1024G>T in *TRPV4* by Sanger sequencing showed dominant homozygosity of T allele at the codon 1024 (Fig. 2C). Thus, we considered that Case 2 was a mixed breed with the American Curl cat and Scottish Fold cat. Osteochondrodysplasia with severe exostosis was observed at the distal part of hind legs on radiographs (Fig. 2D and 2E). However, exostosis was not observed in the forelimbs. The epiphysis of the phalanges was irregular in shape. The bone lesion was consistent with osteochondrodysplasia of the Scottish Fold cat.

Osteochondrodysplasia is considered to be a unique genetic disease of Scottish Fold cats. The folded ear pinna are the dominant trait in which a dominant homozygous cat shows severe osteochondrodysplasia, whereas most heterozygous cats show mild osteochondrodysplasia [7, 10, 11]. Case 1 was a cross breed between a Scottish Fold and Munchkin cat. Although Munchkin cats have shortened limbs that are believed to be an autosomal dominant trait, there is no academic evidence to support this. Munchkin cats are likely to predispose to lordosis and pectus excavatum [6], but again no academic evidence supports this. In addition, dominant homozygosity may be embryonically lethal, suggesting a mutation responded to shortened limbs of Munchkin cats has a significant impact for embryogenesis. Munchkin cats can have impaired chondrogenesis, and Scottish Fold cats with



**Fig. 2.** Case 2: The Scottish Fold and American Curl cross-breed cat (13 month of age). A: the tip of the ear pinna is curled backward, which resembles that of the American Curl cat. B: The exostosis at the tarsal joint is palpable. C: DNA sequence of *TRPV4* c.1024G>T. The position of codon 1024 is highlighted, showing homozygous T. D and E: Radiographs of the hind leg (D: mediolateral view, E: dorsoplantar view). Severe osteochondrodysplasia is seen at the tarsal joint and digits. A large exostosis has formed at the ventral side of the calcaneus. The metatarsal bones are fused to each other.

severe exostosis are dominant homozygous for chondrodysplasia. Thus, both cats have distinct congenital skeletal anomalies. It is impossible to predict what abnormalities would be developed from cats with different skeletal anomalies. In humans, a patient from parents who both have a different mutation for a skeletal disease develops a severe phenotype as a compound heterozygote [8]. Although no clinical signs of skeletal diseases other than osteochondrodysplasia were observed by 12 months of age, careful observation is needed throughout life for the Case 1 cat.

Case 2 was an American Curl and Scottish Fold cross-breed cat. The curling phenotype of the American Curl cat is an autosomal dominant trait [9]. It has been reported that American Curl cats do not develop any abnormalities within two years of follow-up after birth [9]. A responsible mutation for curling of the pinna has not been identified to date, and any such gene mutation may be related to conformation or function of cartilage. The ear pinna of Case 2 were mainly curled backward, and the phenotype of Scottish Fold cat was not observed so clearly. The base of the pinna appeared to be folded slightly forward. Thus, curling and folding phenotypes may present at the same time, suggesting that both phenotypes are co-dominant. Alternatively, each mutation responsible for each phenotype may affect different regions of the ear cartilage. Overall, the shape of the pinna was similar to that of the American Curl cat. Thus, the presence of Scottish Fold cat strains cannot be predicted only by the phenotype of the ear pinna in this cross-breed case, especially in cases of heterozygosity c.1024G>T in *TRPV4*. Osteochondrodysplasia in cats with heterozygous mutations results in mild lesions of the extremities. Thus, if no exostoses are palpable, radiographic examination or genotyping of *TRPV4* are necessary for identification of the presence of the Scottish Fold cat strain among cross breed cats of the American Curl and Scottish Fold species. Although exactly how curling of the pinna is produced remains to be elucidated, it could be related to chondrogenesis of the ear cartilage [9]. Similar to the cross breed between Munchkin and Scottish Fold cats, it is unclear if novel skeletal abnormalities other than osteochondrodysplasia would develop in the American Curl and Scottish Fold



cross-breed cats. Although no clinical signs of skeletal diseases other than osteochondrodysplasia were observed by 13 months of age, careful observation is required throughout the life of the Case 2 cat.

The genotype of c.1024G>T in *TRPV4* revealed dominant homozygosity in both cases. This mutation has not been identified other than in the Scottish Fold cat [3]. Homozygosity of c.1024G>T in *TRPV4* in the cases described here indicates that both cats were derived from parental cats which are heterozygous for c.1024G>T. This is a concerning situation, and requires veterinary clinicians in Japan to notice the presence of a cross-breed with the Scottish Fold. Moreover, it is necessary to avoid breeding of the Scottish Fold cat with cat strains associated with skeletal abnormalities, so that a cat which might develop an unknown abnormality is not produced.

The limitation of this study is that there is no information available regarding the parents in each case. We could not determine the exact lineage of the breed in this study. Molecular biological markers for the Munchkin and American Curl cat are not available at present, therefore external appearance is the only genetic marker for both breeds. If appearance of the parents was clear, the present data would be more convincing. For lineage of the Scottish Fold cat, the ear pinna of the parents in both cases should be folded because the genotype of c.1024G>T of *TRPV4* was homozygous as described above. By genotyping or the pinna appearance of the parents, we could determine that both cases contain the Scottish Fold cat lineage.

POTENTIAL CONFLICTS OF INTEREST. The authors have nothing to disclose.

## REFERENCES

1. Chang, J., Jung, J., Oh, S., Lee, S., Kim, G., Kim, H., Kweon, O., Yoon, J. and Choi, M. 2007. Osteochondrodysplasia in three Scottish Fold cats. *J. Vet. Sci.* **8**: 307–309. [Medline] [CrossRef]
2. Fujiwara-Igarashi, A., Igarashi, H., Hasegawa, D. and Fujita, M. 2015. Efficacy and complications of palliative irradiation in three Scottish Fold cats with osteochondrodysplasia. *J. Vet. Intern. Med.* **29**: 1643–1647. [Medline] [CrossRef]
3. Gandolfi, B., Alamri, S., Darby, W. G., Adhikari, B., Lattimer, J. C., Malik, R., Wade, C. M., Lyons, L. A., Cheng, J., Bateman, J. F., McIntyre, P., Lamandé, S. R. and Haase, B. 2016. A dominant *TRPV4* variant underlies osteochondrodysplasia in Scottish fold cats. *Osteoarthritis Cartilage* **24**: 1441–1450. [Medline] [CrossRef]
4. Hubler, M., Volkert, M., Kaser-Hotz, B. and Arnold, S. 2004. Palliative irradiation of Scottish Fold osteochondrodysplasia. *Vet. Radiol. Ultrasound* **45**: 582–585. [Medline] [CrossRef]
5. Khungar, A., Mahajan, P., Gupte, G., Vasundhara, M., Kher, A. and Bharucha, B. A. 1993. Pseudoachondroplastic dysplasia. *J. Postgrad. Med.* **39**: 91–93. [Medline]
6. Linden, E. C., Dittmer, K. E. and Thompson, K. G. 2016. Bones and joints. pp. 16–163. Jubb, Kennedy & Palmer's Pathology of Domestic Animals: Volume 1, 6th ed. Elsevier, Amsterdam.
7. Malik, R., Allan, G. S., Howlett, C. R., Thompson, D. E., James, G., McWhirter, C. and Kendall, K. 1999. Osteochondrodysplasia in Scottish Fold cats. *Aust. Vet. J.* **77**: 85–92. [Medline] [CrossRef]
8. Melkonieni, M., Brunner, H. G., Manouvrier, S., Hennekam, R., Superti-Furga, A., Kääriäinen, H., Pauli, R. M., van Essen, T., Warman, M. L., Bonaventure, J., Miny, P. and Ala-Kokko, L. 2000. Autosomal recessive disorder otospondylomegapiphyseal dysplasia is associated with loss-of-function mutations in the *COL11A2* gene. *Am. J. Hum. Genet.* **66**: 368–377. [Medline] [CrossRef]
9. Robinson, R. 1989. The American curl cat. *J. Hered.* **80**: 474–475. [Medline] [CrossRef]
10. Takanosu, M., Takanosu, T., Suzuki, H. and Suzuki, K. 2008. Incomplete dominant osteochondrodysplasia in heterozygous Scottish Fold cats. *J. Small Anim. Pract.* **49**: 197–199. [Medline] [CrossRef]
11. Todd, N. B. Folded-ear cats: further observations. 1972. *Carn Genetic News* **2**: 64–65.