

# Trigeminal neurovascular contact in SUNCT and SUNA: a cross-sectional magnetic resonance study

Giorgio Lambru,<sup>1</sup> Khadija Rantell,<sup>2,†</sup> Emer O'Connor,<sup>1,†</sup> Andrew Levy,<sup>1</sup>  
Indran Davagnanam,<sup>3</sup> Ludvic Zrinzo<sup>4</sup> and Manjit Matharu<sup>1</sup>

<sup>†</sup>These authors contributed equally to this work.

Emerging data-points towards a possible aetiological and therapeutic relevance of trigeminal neurovascular contact in short lasting unilateral neuralgiform headache attacks with conjunctival injection and tearing (SUNCT) and perhaps in short lasting unilateral neuralgiform headache attacks with cranial autonomic symptoms (SUNA). We aimed to assess the prevalence and significance of trigeminal neurovascular contact in a large cohort of consecutive SUNCT and SUNA patients and evaluate the radiological differences between them. The standard imaging protocol included high spatial and nerve-cistern contrast resolution imaging acquisitions of the cisternal segments of the trigeminal nerves and vessels. MRI studies were evaluated blindly by two expert evaluators and graded according to the presence, location and degree of neurovascular contact. The degree of contact was graded as with or without morphological changes. Neurovascular contact with morphological changes was defined as contact with distortion and/or atrophy. A total of 159 patients (SUNCT = 80; SUNA = 79) were included. A total of 165 symptomatic and 153 asymptomatic trigeminal nerves were analysed. The proportion of neurovascular contact on the symptomatic trigeminal nerves was higher (80.0%) compared to the asymptomatic trigeminal nerves (56.9%). The odds on having neurovascular contact over the symptomatic nerves was significantly higher than on the asymptomatic nerves [odds ratio (OR): 3.03, 95% confidence interval (CI) 1.84–4.99;  $P < 0.0001$ ]. Neurovascular contact with morphological changes were considerably more prevalent on the symptomatic side (61.4%), compared to the asymptomatic side (31.0%) (OR 4.16, 95% CI 2.46–7.05;  $P < 0.0001$ ). On symptomatic nerves, neurovascular contact with morphological changes was caused by an artery in 95.0% ( $n = 77/81$ ). Moreover, the site of contact and the point of contact around the trigeminal root were respectively proximal in 82.7% (67/81) and superior in 59.3% (48/81). No significant radiological differences emerged between SUNCT and SUNA. The multivariate analysis of radiological predictors associated with the symptomatic side, indicated that the presence of neurovascular contact with morphological changes was strongly associated with the side of the pain (OR: 2.80, 95% CI 1.44–5.44;  $P = 0.002$ ) even when adjusted for diagnoses. Our findings suggest that neurovascular contact with morphological changes is involved in the aetiology of SUNCT and SUNA. Along with a similar clinical phenotype, SUNCT and SUNA also display a similar structural neuroimaging profile, providing further support for the concept that the separation between them should be abandoned. Furthermore, these findings suggest that vascular compression of the trigeminal sensory root, may be a common aetiological factor between SUNCT, SUNA and trigeminal neuralgia thereby further expanding the overlap between these disorders.

- 1 Headache and Facial Pain Group, UCL Queen Square Institute of Neurology and National Hospital for Neurology and Neurosurgery, London, UK
- 2 Biostatistician, Education Unit, UCL Queen Square Institute of Neurology, London UK
- 3 Lysholm Department of Neuroradiology, UCL Queen Square Institute of Neurology and National Hospital for Neurology and Neurosurgery, London, UK

Received April 16, 2020. Revised June 21, 2020. Accepted August 6, 2020. Advance access publication December 10, 2020

© The Author(s) (2020). Published by Oxford University Press on behalf of the Guarantors of Brain.

This is an Open Access article distributed under the terms of the Creative Commons Attribution Non-Commercial License (<http://creativecommons.org/licenses/by-nc/4.0/>), which permits non-commercial re-use, distribution, and reproduction in any medium, provided the original work is properly cited. For commercial re-use, please contact [journals.permissions@oup.com](mailto:journals.permissions@oup.com)

4 Functional Neurosurgery Unit, Department of Clinical and Motor Neurosciences, UCL Queen Square Institute of Neurology, University College London, London, UK

Correspondence to: Dr Manjit Matharu  
Associate Professor and Honorary Consultant Neurologist, Headache and Facial Pain Group  
University College London (UCL) Queen Square Institute of Neurology and The National Hospital  
for Neurology and Neurosurgery,  
Queen Square, London WC1N 3BG, UK  
E-mail: m.matharu@uclmail.net

**Keywords:** SUNCT; SUNA; trigeminal autonomic cephalalgia; cluster headache; trigeminal neuralgia

**Abbreviations:** NVC = neurovascular conflict; SUNA = short-lasting unilateral neuralgiform headache attacks with cranial autonomic symptoms; SUNCT = short-lasting unilateral neuralgiform headache attacks with conjunctival injection and tearing

## Introduction

Short-lasting unilateral neuralgiform headache attacks with conjunctival injection and tearing (SUNCT) and short-lasting unilateral neuralgiform headache attacks with cranial autonomic symptoms (SUNA) are considered separate clinical entities encompassed within the trigeminal autonomic cephalalgias (TACs) group. SUNCT and SUNA are characterized by episodes of moderate or severe, unilateral, stabbing or shooting pain in the trigeminal distribution, associated with ipsilateral cranial autonomic signs and symptoms. The head pain episodes generally last between 1 s and 600 s and can occur spontaneously or be triggered by innocuous cutaneous or intraoral ipsilateral trigeminal stimulation, with a daily frequency of occurrence of at least one a day, though often dozens or hundreds of attacks a day are reported when the disorder is active ([Headache Classification Subcommittee of the International Headache Society, 2018](#)). A recent study on the clinical phenotype of SUNCT and SUNA showed the absence of major clinical difference between these two conditions, suggesting that SUNCT and SUNA maybe considered the same clinical entity ([Lambru \*et al.\*, 2019](#)).

Functional neuroimaging studies during SUNCT/SUNA attacks have demonstrated posterior hypothalamic activation. The similarities in the clinical phenotype of the TACs taken together with the hypothalamic activation demonstrated in all these syndromes has led to the suggestion that the posterior hypothalamus plays a central role in the pathophysiology of these disorders. ([May \*et al.\*, 1999](#); [Matharu \*et al.\*, 2004, 2006](#); [Cohen, 2007](#)). However, SUNCT and SUNA display a broad demographic and clinical overlap with similar responses to medical treatments as trigeminal neuralgia. This overlap has led to growing interest in exploring the presence of shared pathophysiological mechanisms as the basis of these similarities ([Lambru and Matharu, 2014](#)). Emerging data points towards a possible aetiological and therapeutic relevance of trigeminal neurovascular contact (NVC) in SUNCT and perhaps in SUNA, similar to trigeminal neuralgia ([Barker \*et al.\*, 1996](#); [Williams and Broadley, 2008](#); [Williams \*et al.\*, 2010](#); [Antonini \*et al.\*, 2014](#); [Maarbjerg \*et al.\*, 2015](#)). Several case reports of trigeminal NVC on the symptomatic side in subjects with SUNCT have been described ([Favoni \*et al.\*, 2013](#)). A small case series of SUNCT and SUNA where

dedicated high-resolution MRI trigeminal sections were obtained, showed a much greater proportion of vessels contacting the symptomatic trigeminal nerve compared to the asymptomatic nerve ([Williams and Broadley, 2008](#)). Conversely, other series have reported a much lower prevalence of trigeminal NVC. However, in these studies it was not specified whether dedicated views of the trigeminal nerves were obtained ([Cohen \*et al.\*, 2006](#); [Weng \*et al.\*, 2017](#)).

The aims of this study were to explore the role of trigeminal NVC in SUNCT and SUNA by evaluating the presence, degree, type of vessel and localization of the vascular contact in these patients. We also sought to compare MRI NVC characteristics between the two groups of patients in order to evaluate the presence of any significant radiological differences between SUNCT and SUNA.

## Material and methods

Consecutive patients diagnosed by the headache team at the National Hospital for Neurology and Neurosurgery with SUNCT and SUNA between 2007 and 2018 were included. Diagnosis was made by two headache neurologists based on the criteria of the Second edition of International Classification of Headache Disorders (ICHD-2) and ICHD-3 beta ([Headache Classification Subcommittee of the International Headache Society, 2004, 2013](#)). With publication of the ICHD-3 criteria in 2018, we subsequently ensured that all patients included in the study fulfilled these criteria ([Headache Classification Subcommittee of the International Headache Society, 2018](#)). Exclusion criteria were patients with MRI brain without high-resolution cisternal imaging, patients with abnormal MRI scans other than a trigeminal NVC, patients who could not have the relevant MRI of the brain sequences because of implanted devices (i.e. occipital nerve stimulation) and patients who had an invasive trigeminal procedure prior to the MRI.

## MRI protocol and neurovascular conflict definitions

MRI examinations were performed on a 1.5-T GE Signa Excite (GE Medical Systems), 1.5-T Siemens Avanto

(Siemens) or 3.0-T Siemens Trio (Siemens) MRI scanner. The standard imaging protocol included high spatial and nerve-cistern contrast resolution imaging acquisitions of the cisternal segments of the trigeminal nerves and vessels, with 3D Fast Imaging Employing Steady-State Acquisition (FIESTA; echo time: 1.5 ms, repetition time: 4.9 ms, number of excitations: 4), 3D Constructive Interference in Steady State (CISS; echo time: 5.3 ms, repetition time: 10.6 ms, excitations: 1), or 3D Sampling Perfection with Application optimized Contrasts using different flip angle Evolution (SPACE; echo time: 132 ms, repetition time: 1000 ms, excitations: 2). The slice thickness of all examinations ranged from 0.5 mm to 1 mm. High resolution axial and coronal T<sub>2</sub>-weighted sequences through the trigeminal nerves were also obtained with acquisitions a slice thickness of 2 mm, in order to assess intrinsic signal hyperintensity. When present, Time-Of-Flight Magnetic Resonance Angiography (TOF MRA) was used to confirm the location of the cerebellar arteries and veins in close proximity to the cisternal segments of the trigeminal nerves on the high-resolution images; high signal within vessels on this sequence were considered arteries and the contrary, veins.

All MRI studies were reviewed and analysed on Corion high-resolution 3-megapixel monitors (Barco Inc) on IMPAX 6 Picture Archiving and Communication System (AGFA Healthcare NV, Belgium) by an experienced neuro-radiologist (I.D.) and a neurosurgeon specialized in performing microvascular decompression procedures (L.Z.) who were blinded to the diagnosis and the laterality of the headache. The inter-operator agreement on MRI evaluations was measured with *K*-score. The trigeminal nerve on the side of the pain was defined as the symptomatic nerve; the trigeminal nerve contralateral to the side of the pain was defined as the asymptomatic nerve. In patients with side alternating unilateral head pain, both trigeminal nerves were considered symptomatic. NVC with the cisternal segments of the trigeminal nerves was assessed on both sides on multiplanar reformats of the source high-resolution data. NVC was defined on the analysis of imaging by no perceptible cerebrospinal signal intervening between the vascular structure (arterial or venous) and the cisternal segment of the trigeminal nerve. In view of the ongoing debate upon the definition and boundaries of the zone where peripheral myelination transitions to central myelination ('root entry zone' or 'transition zone') (De Ridder *et al.*, 2002; Peker *et al.*, 2006), sites of NVC on the trigeminal nerve were divided into three segments, namely, proximal, middle and distal. If more than one site was contacted by the vessel, it was defined as mixed. The degree of NVC was graded as with or without morphological changes (Headache Classification Subcommittee of the International Headache Society, 2018). NVC without morphological changes was defined a simple contact. NVC with morphological changes was defined as a contact with distortion and/or atrophy (Fig. 1). Distortion was defined as indentation or displacement of the trigeminal nerve at the site of the neurovascular contact. Atrophy was defined as a reduced volume of the trigeminal nerve at the site of the

neurovascular contact. NVC with one or more arteries was defined as an arterial conflict; NVC with one or more veins was defined as a venous conflict; NVC with one artery and one vein was defined as a mixed conflict. Furthermore, the point of contact around the nerve diameter was evaluated and defined as superior, lateral, medial and inferior. If more than one point of contact was present, then the term 'mixed' was used.

The study was approved by Northwick Park Hospital Research Ethics Committee, London, UK (REC no: 11/LO/1709). Patients gave informed consent to participate in this study.

## Statistical analysis

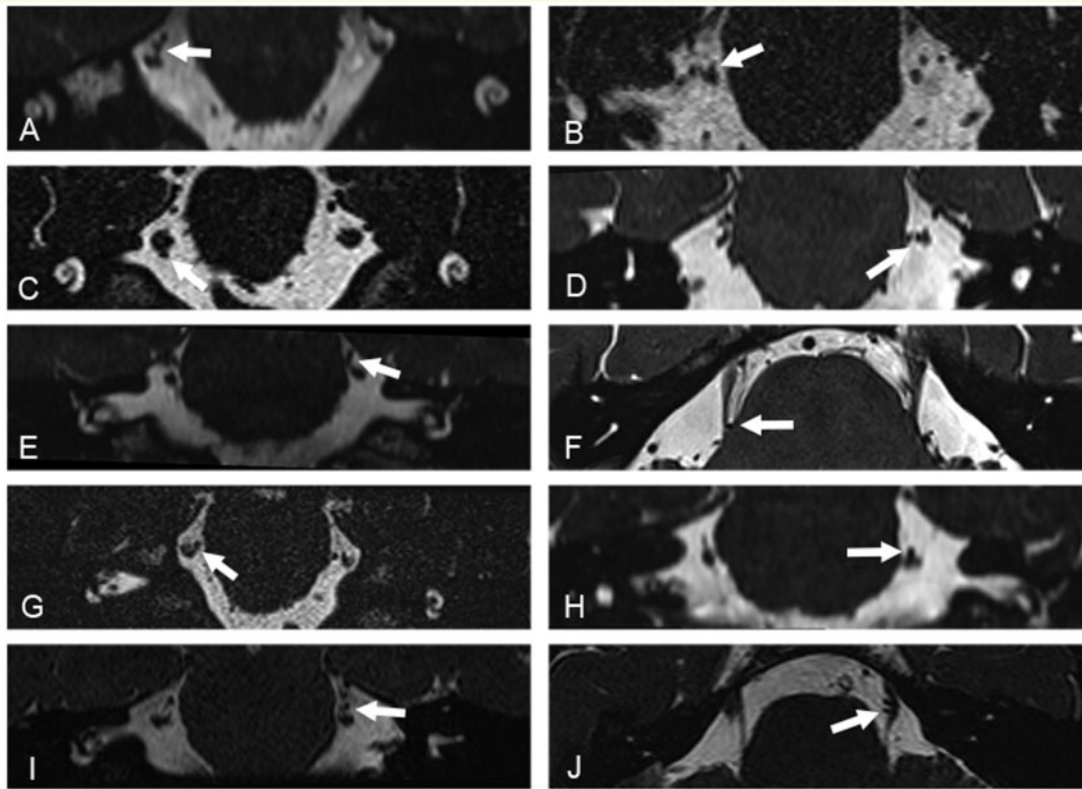
Continuous data were summarized by descriptive statistics. Categorical variables are presented with frequency distributions (*n*, %). We used the binomial approximation to the normal distribution to compare the proportions between symptomatic and asymptomatic nerves. Unadjusted and adjusted multilevel logistic regression models, to account for diagnoses, were used to investigate potential association between the presence of vascular contact, degree of contact, site of contact within the trigeminal sensory root and type of vessel involved, and the symptomatic as opposed to asymptomatic trigeminal nerves in SUNA and SUNCT. Statistical analyses were performed using STATA (Stata Corp. 2001. Stata Statistical Software: Version 12.1, College Station, Texas, USA). Statistical significance level was set to 5% two-sided. A Bonferroni adjustment was applied to *P*-values to control the type I error inflation as a result of multiple testing. Threshold for significance after Bonferroni correction was 0.003.

## Data availability

The data that support the findings of this study are available from the corresponding author.

## Results

A total of 224 SUNCT and SUNA patients were assessed within the study period. Of these, the following were excluded: 21 patients did not have high-resolution cisternal imaging MRI scans because of incorrect MRI protocol; 29 had not had trigeminal nerve imaging at our centre and either declined further imaging or were unable to have an MRI scan because of an occipital nerve stimulator *in situ*; 12 patients were excluded as they were assessed at our centre after a trigeminal procedure had been performed; and three were excluded because of abnormal MRI scans (one patient with mid-brain low grade astrocytoma, two patients with posterior fossa ischaemic strokes). The remaining 159 patients (SUNCT = 80, 50.3% and SUNA = 79, 49.7%) had high-resolution cisternal imaging MRI scans according to our protocol and were included in the study. Table 1 summarizes the demographic and clinical characteristics of the study group.



**Figure 1** High-resolution volumetric 3-D CISS and SPACE MRI acquisitions. Acquisitions were reconstructed in the coronal (A–E and G–I) and axial (F and J) planes, and demonstrate contact of a segment of the superior cerebellar artery with the cisternal segment of the trigeminal nerve (white arrows). Images in the left column show contact with no morphological changes of the corresponding segment of the trigeminal nerve. Images in the right column show contact with morphological changes, with deviation and distortion of the corresponding adjacent cisternal segment of the trigeminal nerve.

## MRI results: assessor concordance

There was good concordance in categorizing the trigeminal nerves between the two assessors (kappa coefficient = 0.91,  $P < 0.05$ ). When discrepancies existed, the two assessors arrived at a consensus view that was used for statistical analysis.

## Neurovascular contact on the symptomatic and asymptomatic side

Of the 159 patients, 90 (56.6%) had strictly unilateral right-sided attacks (SUNCT = 48; SUNA = 42), 63 (39.6%) had strictly unilateral left-sided attacks (SUNCT = 29; SUNA = 34) and six (3.8%) had unilateral side-alternating attacks (SUNCT = 3; SUNA = 3). A total of 165 symptomatic trigeminal nerves (SUNCT = 83, SUNA = 82) and 153 asymptomatic trigeminal nerves (SUNCT = 77, SUNA = 76) were analysed. The prevalence of NVC on the symptomatic trigeminal nerves was significantly higher (80.0%), compared to the asymptomatic trigeminal nerves (56.9%) ( $P < 0.0001$ ). The estimates of odds ratio indicated that the presence of an

NVC was associated with the symptomatic side [odds ratio (OR): 3.03, 95% confidence interval (CI) 1.84–4.99]. NVC with morphological changes was considerably more prevalent on the symptomatic side ( $n = 81$ , 61.4%), compared to the asymptomatic side (31.0%) ( $P < 0.0001$ ). The estimates of odds ratio indicate that the presence of NVC with morphological changes as opposed to NVC without morphological changes is strongly associated with the nerve being symptomatic rather than asymptomatic (OR: 4.50, 95% CI 2.69–7.54). There was a statistically greater proportion of arteries contacting the trigeminal nerves on the symptomatic side (65.9%) compared to the asymptomatic side (44.8%) ( $P < 0.0001$ ). The presence of an artery as opposed to a vein was a strong predictor for the trigeminal nerve being symptomatic. (OR: 3.51, 95% CI 2.21–5.58). The presence of vascular contacts over the proximal segments of the trigeminal nerves were significantly greater on symptomatic (48.5%) than asymptomatic nerves (43.7%) ( $P < 0.0001$ ). The estimates of odds ratio indicated that the presence of a proximal contact was associated with the nerve being symptomatic (OR: 2.90, 95% CI 1.82–4.62). Similarly, a superior point of contact of the vessel was more frequently found on symptomatic (34.1%) rather than asymptomatic nerves

**Table 1** Demographic and clinical characteristics of SUNCT and SUNA patients

Demographic/clinical characteristic	
Age, years, mean (SD) [range]	58.7 ( $\pm$ 15.4) [20–93]
Sex	
Male	78 (49%)
Female	81 (51%)
Diagnoses	
Chronic SUNCT	80 (50.3%)
Chronic SUNA	79 (49.7%)
Headache duration, years, mean (SD) [range]	14.9 ( $\pm$ 7.19) [3–44]
Headache laterality	
Right	90 (56.6%)
Left	63 (39.6%)
Unilateral side variable	6 (3.8%)
Headache distribution	
V1	36 (22.6%)
V2	23 (14.5%)
V1-V2	47 (29.6%)
V2-V3	22 (13.8%)
V1-C2	5 (3.1%)
V1-V2-V3	16 (10.1%)
V1-V2-C2	10 (6.3%)
Mean number of daily attacks, mean (SD) [range]	70.79 ( $\pm$ 102.16) [2–700]
Mean attack severity (0–10), mean (SD) [range]	9.42 ( $\pm$ 1.42) [6–10]
Mean attack duration, s, mean (SD) [range]	85.92 ( $\pm$ 127.16) [1–600]
Spontaneous and/or triggered attacks	
Spontaneous and triggered	105 (66.0%)
Spontaneous only	43 (27.0%)
Triggered only	11 (6.9%)
Refractory period	
No	75 (47.2%)
Yes	14 (8.8%)
Not applicable	43 (27.0%)
Patients not sure	27 (17.0%)
Personal history of migraine	
Yes	87 (54.7%)
No	72 (45.2%)

C2 = second cervical root; SD = standard deviation; V1 = first division of the trigeminal nerve; V2 = second division of the trigeminal nerve; V3 = third division of the trigeminal nerve.

(31.0%) ( $P = 0.001$ ). The estimates of odds ratio indicate that the presence of a superior point of contact was associated with the nerve being symptomatic (OR: 2.28, 95% CI 1.43–3.62) (Table 2).

## Neurovascular conflict in the SUNCT cohort

Amongst SUNCT patients' severe NVCs were considerably more prevalent on the symptomatic ( $n = 46$ , 64.8%) compared to the asymptomatic side ( $n = 19$ , 35.2%) ( $P < 0.0001$ ). NVC with morphological changes as opposed to NVC without morphological changes was a predictor for

the nerve being symptomatic (OR: 3.80, 95% CI 1.93–7.46). There was a statistically greater proportion of arteries contacting the trigeminal nerves on the symptomatic side (70.4%) compared to the asymptomatic side (44.4%) ( $P < 0.0001$ ). The presence of an artery as opposed to a vein was a strong predictor for the trigeminal nerve being symptomatic (OR: 4.06, 95% CI 2.10–7.86;  $P < 0.0001$ ). The vascular structures were found more often over the proximal segment of the symptomatic (54.9%) compared to the asymptomatic nerves (42.6%) ( $P = 0.002$ ). Proximal site of contact was associated with the nerve being symptomatic (OR: 2.83, 95% CI 1.49–5.38) (Table 3).

## Neurovascular contact in the SUNA cohort

Amongst SUNA patients there was a significantly greater proportion of neurovascular contacts on the symptomatic (74.4%) compared to the asymptomatic trigeminal nerves (43.4%) ( $P < 0.0001$ ). The estimates of odds ratio indicated that the presence of a vascular contact was a strong predictor for the nerve to be symptomatic rather than asymptomatic (OR: 3.79, 95% CI 1.93–7.41). NVC with morphological changes were considerably more prevalent on the symptomatic ( $n = 35$ , 57.4%) compared to the asymptomatic nerves ( $n = 8$ , 24.2%) ( $P < 0.0001$ ). The presence of severe NVC was linked to the nerve being symptomatic (OR: 6.33, 95% CI 2.70–14.86). There was a greater proportion of arteries contacting the trigeminal nerves on the symptomatic side (60.7%) compared to the asymptomatic side (45.5%) ( $P = 0.001$ ). Arterial conflicts as opposed to venous ones were associated with the trigeminal nerve being symptomatic (OR: 3.14, 95% CI 1.62–6.07) (Table 4).

## Neurovascular contact: comparison between SUNCT and SUNA cohorts

There was no statistically significant difference in the proportion of neurovascular contacts on the symptomatic nerves between SUNCT [71/83 (85.5%)] and SUNA [61/82 (74.4%)] ( $P = 0.073$ ). Similarly, there was no statistically significant difference in the proportion of NVC with morphological changes between SUNCT [46/71 (55.9%)] and SUNA [35/61 (42.4%)] ( $P = 0.102$ ). The comparison between arterial structures ( $P = 0.052$ ), proximal site of contact ( $P = 0.030$  threshold for significance after Bonferroni correction was 0.003) and superior point of contact ( $P = 0.824$ ) showed no significant differences between the two groups of patients.

## Radiological predictors for the symptomatic or asymptomatic side

The multivariate regression analysis adjusted for diagnosis demonstrated that, among the radiological variables that were associated with the symptomatic nerve in the univariate

**Table 2** Characteristics of trigeminal neurovascular contacts by symptomatic and asymptomatic nerves in all patients

	Symptomatic nerve (n = 165) n (%)	Asymptomatic nerve (n = 153) n (%)	OR (95% CI)*	P-value*
Any contact				
Yes	132 (80.0)	87 (56.9)	3.03 (1.84–4.99)	<0.0001
No	33 (20.0)	66 (43.1)	Reference	
Degree of contact				
Contact	51 (38.64)	60 (69.0)	0.97 (0.62–1.51)	0.891
Distortion	33 (25.0)	15 (17.2)	4.16 (2.46–7.05)	<0.0001
Atrophy	3 (2.3)	1 (1.2)	5.06 (2.27–11.28)	<0.0001
Mixed <sup>a</sup>	45 (34.1)	11 (12.6)	4.84 (2.40–9.77)	<0.0001
Type of vessel				
Vein	28 (21.2)	37 (42.5)	0.82 (0.51–1.33)	0.423
Artery	87 (65.9)	39 (44.8)	3.51 (2.21–5.58)	<0.0001
Mixed	17 (12.9)	11 (12.6)	1.48 (0.67–3.28)	0.330
Site of contact				
Proximal	64 (48.5)	38 (43.7)	2.90 (1.82–4.62)	<0.0001
Middle	20 (15.15)	18 (20.7)	1.81 (1.04–3.14)	0.036
Distal	17 (12.9)	21 (24.1)	1.15 (0.66–2.00)	0.616
Mixed	31 (23.5)	10 (11.5)	1.75 (1.01–3.04)	0.048
Point of contact				
Superior	45 (34.1)	24 (31.0)	2.28 (1.43–3.62)	0.001
Medial	30 (22.7)	17 (19.5)	1.92 (1.18–3.11)	0.008
Lateral	3 (2.3)	4 (4.6)	1.14 (0.46–2.84)	0.774
Inferior	12 (9.1)	17 (19.5)	0.91 (0.50–1.67)	0.771
Mixed	42 (31.8)	25 (28.7)	1.75 (1.01–3.04)	0.048

Odds ratio (OR) estimated from multilevel logistic regression with symptomatic status of the nerve as the outcome variable. Ref = reference.

<sup>a</sup>All mixed degrees of contact were severe contact.

\*The threshold for statistical significance based on Bonferroni adjustment is 0.003 (i.e. 0.05/17).

analysis, NVC with morphological changes remained a significant predictor for the nerve to be symptomatic rather than asymptomatic [OR: 2.80 95% CI 1.44–5.44,  $P = 0.002$ ]. The other variables that had emerged in the model as potential radiological predictors did not show any significant statistical difference between symptomatic and asymptomatic nerves (Table 5).

## Discussion

This is the first prospective, blinded MRI study, conducted in the largest cohort of consecutive radiologically evaluated SUNCT and SUNA patients, assessing the significance of trigeminal NVC. The findings demonstrate that trigeminal NVC is a highly prevalent neuroanatomical finding ipsilateral to the side of the pain in SUNCT and SUNA. Furthermore, other factors significantly more prevalent on the symptomatic side include severe degree of NVC, arterial conflict, NVC with the proximal segment of the trigeminal sensory root and NVC with the superior aspect of the nerve. There were no significant differences between SUNCT and SUNA in any of these MRI findings. Among these radiological outcomes, NVC with morphological changes was demonstrated to be a robust predictor of the symptomatic

side in SUNCT and SUNA. This finding is likely to explain the high prevalence of arterial NVC with morphological changes, the proximal site and superior point of contact found on the symptomatic side. A high proportion of superior only, supero-medial and supero-lateral points of contact on both symptomatic and asymptomatic sides in SUNCT/SUNA, was also shown in a recent study, which aimed to assess the relation between the location of vascular compression and the pain distribution in trigeminal neuralgia patients operated with trigeminal microvascular decompression (Sindou and Brinzeou, 2020). Most patients in the trigeminal neuralgia study displayed a superior compression (61.7%). In view of the infrequent location of the painful attacks in V1 in trigeminal neuralgia, this and our findings may suggest that a superior trigeminal conflict is a frequent normal neuroanatomical finding. However, in the trigeminal neuralgia study, patients with supero-medial conflict had an OR of 2.7 (95% CI: 1.66–4.41) of manifesting pain in V1 and inferior compression was more likely to manifest with V3 pain (OR: 2.6, 95% CI: 1.21–5.45), supporting the role of the point of conflict and pain in trigeminal neuralgia and indicating the need of evaluating this association in SUNCT/SUNA as well.

The association between NVC with morphological changes and the symptomatic side raises the possibility that

**Table 3** Characteristics of trigeminal NVCs by symptomatic and asymptomatic nerves in SUNCT patients

	Symptomatic nerve (n = 83) n (%)	Asymptomatic nerve (n = 77) n (%)	OR (95% CI)*	P-value*
Any contact				
Yes	71 (85.5)	54 (70.1)	2.52 (1.15–5.51)	0.021
No	12 (14.5)	23 (29.9)	Reference	
Degree of contact				
Contact	25 (35.2)	35 (64.8)	0.75 (0.40–1.39)	0.357
Distortion	19 (26.8)	11 (20.4)	3.45 (1.73–6.87)	<0.0001
Atrophy	3 (4.2)	1 (1.9)	4.57 (1.62–12.89)	0.004
Mixed <sup>a</sup>	24 (33.8)	7 (13.0)	4.07 (1.64–10.11)	0.003
Type of vessel				
Vein	13 (18.3)	26 (48.2)	0.54 (0.27–1.04)	0.065
Artery	50 (70.4)	24 (44.4)	4.06 (2.10–7.86)	<0.0001
Mixed	8 (11.3)	4 (7.4)	1.95 (0.56–6.75)	0.293
Site of contact				
Proximal	39 (54.9)	23 (42.6)	2.83 (1.49–5.38)	0.002
Middle	12 (16.9)	12 (22.2)	1.40 (0.66–2.97)	0.379
Distal	7 (9.9)	15 (27.8)	0.72 (0.33–1.57)	0.405
Mixed	13 (18.3)	4 (7.4)	1.44 (0.70–2.94)	0.323
Point of contact				
Superior	22 (31.0)	10 (18.5)	2.41 (1.25–4.610)	0.008
Medial	18 (25.4)	12 (22.2)	1.59 (0.84–3.04)	0.157
Lateral	1 (1.4)	2 (3.7)	0.76 (0.22–2.59)	0.660
Inferior	6 (8.5)	13 (24.1)	0.61 (0.28–1.35)	0.219
Mixed	24 (33.8)	17 (31.5)	1.44 (0.70–2.95)	0.323

Odds ratio (OR) estimated from multilevel logistic regression with symptomatic status of the nerve as the outcome variable.

<sup>a</sup>All mixed degrees of contact were severe contact.

\*The threshold for statistical significance based on Bonferroni adjustment is 0.003 (i.e. 0.05/17).

these neuroanatomical findings may be implicated in the pain mechanisms of SUNCT and SUNA. The majority of SUNCT cases are considered idiopathic, but a significant minority of them seem to be secondary to intracranial abnormalities. Similar to secondary cases of other TACs and trigeminal neuralgia, cases of SUNCT have been attributed to posterior fossa abnormalities and pituitary adenomas (Cittadini and Matharu, 2009; Chitsantikul and Becker, 2013). Furthermore, growing evidence supports the frequent occurrence of NVC of the trigeminal nerve close to the root entry zone ipsilateral to the side of the pain (Favoni *et al.*, 2013). In a series of 24 SUNCT/SUNA cases, 17 patients were studied with dedicated MRI of the trigeminal nerves. NVC was detected in 15 of 17 patients (88%). In 90% of cases, a vascular loop was impinging on the symptomatic trigeminal nerve, compared to only 7% in which the vascular loop was pressing on the asymptomatic nerve (Williams and Broadley, 2008). The high prevalence of NVC with morphological changes in their series could be explained by the small sample size. Moreover, the authors did not detail the scanning protocol and their definition included cases where only contact with a vascular loop was observed. It is therefore possible that the prevalence of NVC with morphological changes was overestimated. Nonetheless, the significantly greater proportion of NVC with morphological changes on the symptomatic side compared to the asymptomatic side in

both that and the current study suggests that this finding is more than a mere chance association.

It is widely accepted that NVC ipsilaterally to the pain side constitutes one of the pivotal neuroanatomical findings in trigeminal neuralgia (Devor *et al.*, 2002; Antonini *et al.*, 2014; Maarbjerg *et al.*, 2015). Trigeminal NVC on the symptomatic side is reported in 47–90% of trigeminal neuralgia cases and it often occurs at the root entry zone by an artery. However, the presence of trigeminal NVC without morphological changes seems not specific for trigeminal neuralgia as it is highly prevalent on both the symptomatic and the asymptomatic side (Love and Coakham, 2001; Antonini *et al.*, 2014; Maarbjerg *et al.*, 2015). Meta-analyses of MRI studies showed that NVC with morphological changes on the symptomatic side is strongly linked with trigeminal neuralgia compared to the control nerves (OR: 13.3; 95% CI 5.8–30.6;  $P < 0.0001$ ) (Antonini *et al.*, 2014; Maarbjerg *et al.*, 2015; Bendtsen *et al.*, 2019). Similarly, arterial NVC with morphological changes at the root entry zone on symptomatic nerves were found to be more prevalent on the symptomatic nerves compared to the asymptomatic nerves. It was concluded that the strong association between NVC with morphological changes and the symptomatic trigeminal nerve, could be considered a major aetiological factor in trigeminal neuralgia (Maarbjerg *et al.*, 2015). The aetiological importance of trigeminal NVC in trigeminal neuralgia is ultimately corroborated by the long-

**Table 4** Characteristics of trigeminal NVCs by symptomatic and asymptomatic nerves in SUNA patients

	Symptomatic nerve (n = 82) n (%)	Asymptomatic nerve (n = 76) n (%)	OR (95% CI)*	P-value*
Any contact				
Yes	61 (74.4)	33 (43.4)	3.79 (1.93–7.41)	<0.0001
No	21 (25.6)	43 (56.6)	Reference	
Degree of contact				
Contact	26 (42.6)	25 (75.8)	1.28 (0.67–2.42)	0.454
Distortion	14 (23.0)	4 (12.1)	5.72 (2.43–13.46)	<0.0001
Atrophy	0	0	5.90 (1.65–21.16)	0.006
Mixed <sup>a</sup>	21 (34.4)	4 (12.1)	6.20 (2.02–19.04)	0.001
Type of vessel				
Vein	15 (24.6)	11 (33.3)	1.34 (0.66–2.72)	0.428
Artery	37 (60.7)	15 (45.5)	3.14 (1.62–6.071)	0.001
Mixed	9 (14.8)	7 (21.2)	1.22 (0.43–3.44)	0.714
Site of contact				
Proximal	25 (41.0)	15 (45.5)	3.07 (1.55–6.08)	0.001
Middle	8 (13.1)	6 (18.2)	2.42 (1.06–5.53)	0.036
Distal	10 (16.4)	6 (18.2)	1.84 (0.83–4.05)	0.132
Mixed	18 (29.5)	6 (18.2)	2.39 (0.97–5.88)	0.058
Point of contact				
Superior	23 (37.7)	14 (42.4)	2.15 (1.11–4.187)	0.024
Medial	12 (19.7)	5 (15.2)	2.51 (1.19–5.33)	0.016
Lateral	2 (3.3)	2 (6.1)	1.92 (0.46–8.00)	0.368
Inferior	6 (9.8)	4 (12.1)	1.69 (0.63–4.55)	0.298
Mixed	18 (29.5)	8 (24.2)	2.39 (0.97–5.88)	0.058

Odds ratio (OR) estimated from multilevel logistic regression with symptomatic status of the nerve as the outcome variable.

<sup>a</sup>All mixed degrees of contact were severe contact.

\*The threshold for statistical significance based on Bonferroni adjustment is 0.003 (i.e. 0.05/17).

term efficacy of trigeminal microvascular decompression procedure, the gold standard surgical approach for this condition (Barker *et al.*, 1996). Although the odds ratio for the association between NVC with morphological changes and the symptomatic side in our study is considerable lower compared to those found in classical trigeminal neuralgia studies, our MRI and clinical findings, along with therapeutic similarities reported in previous studies between SUNCT, SUNA and trigeminal neuralgia, support the concept that these conditions share pain generating mechanisms. A focal demyelination of the sensory trigeminal root ipsilaterally to the side of the pain caused by NVC with morphological changes maybe one of the key aetiological mechanisms that explain SUNCT, SUNA and trigeminal neuralgia overlap. Initial encouraging evidence from single case reports and a small case series suggest that trigeminal microvascular decompression in SUNCT and SUNA patients with NVC on the symptomatic nerve, could lead to pain freedom (Sebastian *et al.*, 2013). Our findings may indicate that trigeminal microvascular decompression could be carefully considered in chronic SUNCT/SUNA patients with MRI evidence of ipsilateral NVC with morphological changes. However, in order to explore the aetiological significance of trigeminal NVC, further studies may need to evaluate the efficacy of trigeminal microvascular decompression in patients with MRI evidence of ipsilateral NVC with and without morphological changes, follow them up long term and assess

the presence of any surgical outcome differences between those with and without MRI evidence of morphological changes.

In both this and the Maarbjerg *et al.* (2015) studies, only about half of the patients displayed severe NVC on the symptomatic side. Since studies in trigeminal neuralgia patients have shown a high prevalence of NVC in non-trigeminal neuralgia individuals (Peker *et al.*, 2006), this neuroanatomical finding may not be the only relevant aetiological factor for these disorders. Other mechanisms may also play a role in the aetiology of pain and associated symptoms for SUNCT and SUNA. Derangement of central trigeminal nociceptive and autonomic modulating structures such as the posterior hypothalamic region have been postulated after functional neuroimaging studies have shown activation of the posterior hypothalamus bilaterally as well as ipsi- and contralateral to the pain in SUNCT and SUNA patients during painful attacks (May *et al.*, 1999; Cohen, 2007). Although the exact meaning of these neuroimaging changes is unknown, the pivotal role of this brain region in the pathophysiology of SUNCT and SUNA is supported by the efficacy of deep brain stimulation of the ventral tegmental area reported in chronic refractory subtypes of these disorders (Miller *et al.*, 2016). Additionally, the efficacy of sodium channels modulators in the prevention of SUNCT and SUNA, along with the described co-



**Table 5 Multivariate logistic regression analysis radiological predictors for symptomatic compared to asymptomatic nerves in SUNCT and SUNA**

	<b>Symptomatic nerves OR (95% CI)*</b>	<b>P-value</b>
Presence of neurovascular contact		0.800
Yes	1.10 (0.53–2.28)	
No	Reference	
Degree of contact		0.002
With morphological changes	2.80 (1.44–5.44)	
Without morphological changes	Reference	
Type of vessel		0.360
Artery	1.42 (0.67–2.98)	
Not artery	Reference	
Site of contact		0.413
Proximal	1.30 (0.69–2.43)	
Not proximal	Reference	
Point of contact		0.407
Superior	1.31 (0.70–2.45)	
Not superior	Reference	

\*Odds ratios (OR) and P-values obtained from a multilevel regression model with symptomatic status of the nerve as outcome variable and radiological predictors as explanatory variables.

occurrence between SUNCT/SUNA and hemiplegic migraine, raises the possibility of ion channel dysfunction being implicated in the pathogenesis of SUNCT and SUNA (Lambru *et al.*, 2012). It is likely that the pathophysiology of these disorders is multifactorial, involving impaired posterior hypothalamic region function, sodium channel dysfunction and pathological processes within the trigeminal sensory root (demyelination and axonal injury) due to NVC.

SUNCT and SUNA are listed separately in the International Classification of Headache Disorders under the umbrella term ‘short-lasting unilateral neuralgiform headache attacks’ (Headache Classification Subcommittee of the International Headache Society, 2018). A recent comparison of the clinical characteristics of SUNA and SUNCT phenotype in a large series of patients found no significant differences between the two phenotypes. This suggests that SUNCT and SUNA may represent a single clinical entity (Lambru *et al.*, 2019). The current study shows similar prevalence and neurovascular contacts characteristics between SUNCT and SUNA, providing structural neuroimaging evidence that these two conditions maybe the same entity, not only on a clinical, but also on a neuroradiological basis.

The study has some limitations, namely the lack of a healthy control group; to obviate this problem and given the prominent unilaterality of these headache disorders, the contralateral side was used as control. The MRI evaluators were not blinded to the diagnosis of short-lasting unilateral neuralgiform headache attacks, albeit that they were blinded to the subclassification of SUNCT or SUNA; this could potentially have induced them to report mostly one NVC per

patient. However, a high proportion of bilateral NVC was reported in this series, confirming the accuracy of the MRI evaluations. The strengths of this study include its prospective nature, the large number of patients included for such a rare condition and the presence of two MRI evaluators blinded to the laterality of symptoms.

In conclusion, this study demonstrated that NVC is highly prevalent on the symptomatic side in SUNCT and SUNA. In particular, our findings indicated a robust association between NVC with morphological changes and the symptomatic side, suggesting an important aetiological role of this neuroimaging characteristic in SUNCT/SUNA, similarly to trigeminal neuralgia. Ultimately, long-term evidence of headache freedom after trigeminal microvascular decompression would confirm the clinical value of our findings. The study also demonstrated the absence of any significant radiological differences between SUNCT and SUNA. These findings, along with the absence of clinical differences, support the notion that SUNCT and SUNA may be the same clinical entity and that their separation should be abandoned.

## Acknowledgements

The authors thank our headache specialist nurses for their involvement with the patients, as well as the patients and their families for their help with this project.

## Funding

No targeted funding was received towards this work. L.Z. and the Unit of Functional Neurosurgery are supported by the National Institute for Health Research, University College London Hospitals, Biomedical Research Centre. I.D. is supported by the National Institute for Health Research, University College London Hospitals, Biomedical Research Centre.

## Competing interests

G.L. has received speaker honoraria, funding for travel and has received honoraria for participation in advisory boards sponsored by Allergan, Novartis, Eli Lilly and TEVA. He has received speaker honoraria, funding for travel from electroCore, Nevro Corp. and Autonomic Technologies. L.Z. has received speaker honoraria from Medtronic and Boston Scientific. M.S.M. serves on the advisory board for Allergan, St Jude Medical and Medtronic and has received payment for the development of educational presentations from Allergan, Merck Sharpe and Dohme Ltd., Medtronic and electroCore. All other authors report no competing interests.

## References

- Antonini G, Di Pasquale A, Cruccu G, Truini A, Morino S, Saltelli G, et al. MRI contribution for diagnosing symptomatic neurovascular contact in classic trigeminal neuralgia. A blinded case-control study and meta-analysis. *Pain* 2014; 155: 1464–71.
- Barker FG 2nd, Jannetta PJ, Bissonette DJ, et al. The long-term outcome of microvascular decompression for trigeminal neuralgia. *N Engl J Med* 1996; 334: 1077–83.
- Bendtsen L, Zakrzewska JM, Abbott J, Braschinsky M, Di Stefano G, Donnet A. European Academy of Neurology guideline on trigeminal neuralgia. *Eur J Neurol* 2019; 26: 831–49.
- Cittadini E, Matharu MS. Symptomatic trigeminal autonomic cephalalgias. *Neurologist* 2009; 15: 305–12.
- Chitsantikul P, Becker WJ. SUNCT SUNA and pituitary tumors: clinical and characteristics and treatment. *Cephalalgia* 2013; 33: 160–70.
- Cohen AS, Matharu MS, Goadsby PJ. Short-lasting unilateral neuralgiform headache attacks with conjunctival injection and tearing (SUNCT) or cranial autonomic features (SUNA)-a prospective clinical study of SUNCT and SUNA. *Brain* 2006; 129: 2746–60.
- Cohen AS. Short-lasting unilateral neuralgiform headache attacks with conjunctival injection and tearing. *Cephalalgia* 2007; 27: 824–32.
- De Ridder D, Møller A, Verlooy J, Cornelissen M, De Ridder L. Is the root entry/exit zone important in microvascular compression syndromes? *Neurosurgery* 2002; 51: 427–33.
- Devor M, Amir R, Rappaport ZH. Pathophysiology of trigeminal neuralgia: the ignition hypothesis. *Clin J Pain* 2002; 18: 4–13.
- Favoni V, Grimaldi D, Pierangeli G, Cortelli P, Cevoli S. SUNCT, SUNA and neurovascular compression: new cases and critical review of the literature. *Cephalalgia* 2013; 33: 1337–48.
- Headache Classification Subcommittee of the International Headache Society. The International Classification of Headache Disorders 2nd edition. *Cephalalgia* 2004; 24: 1–195.
- Headache Classification Subcommittee of the International Headache Society. The International Classification of Headache Disorders 3rd edition (beta version). *Cephalalgia* 2013; 33: 629–808.
- Headache Classification Subcommittee of the International Headache Society. The International Classification of Headache Disorders 3rd edition. *Cephalalgia* 2018; 38: 1–211.
- Lambru G, Matharu MS. SUNCT, SUNA and trigeminal neuralgia: different disorders or variants of the same disorder? *Curr Opin Neurol* 2014; 325–31.
- Lambru G, Nesbitt A, Shanahan P, Matharu MS. Coexistence of hemiplegic migraine with SUNCT or SUNA: a case series. *Cephalalgia* 2012; 32: 258–62.
- Lambru G, Rantell K, Levy A, Matharu MS. A prospective comparative study and analysis of predictors of SUNA and SUNCT. *Neurology* 2019; 93: e1127–e1137.
- Love S, Coakham HB. Trigeminal neuralgia: a pathology and pathogenesis. *Brain* 2001; 124: 2347–60.
- Maarbjerg S, Wolfram F, Gozalov A, Olesen J, Bendtsen L. Significance of neurovascular contact in classical trigeminal neuralgia. *Brain* 2015; 138: 311–9.
- Matharu MS, Cohen AS, McGonigle DJ, Ward N, Frackowiak RS, Goadsby PJ. Posterior hypothalamic and brainstem activation in hemicrania continua. *Headache* 2004; 44: 747–61.
- Matharu MS, Cohen AS, Frackowiak RS, Goadsby PJ. Posterior hypothalamic activation in paroxysmal hemicrania. *Ann Neurol* 2006; 59: 535–45.
- May A, Bahra A, Buchel C, et al. Functional magnetic resonance imaging in spontaneous attacks of SUNCT: short-lasting neuralgiform headache with conjunctival injection and tearing. *Ann Neurol* 1999; 46: 791–4.
- Miller S, Akram H, Lagrata S, Hariz M, Zrinzo L, Matharu M. Ventral tegmental area deep brain stimulation in refractory short-lasting unilateral neuralgiform headache attacks. *Brain* 2016; 139: 2631–40.
- Peker S, Kurtkaya O, Uzun I, Pamir MN. Microanatomy of the central myelin-peripheral myelin transition zone of the trigeminal nerve. *Neurosurgery* 2006; 59: 354–9.
- Sebastian S, Schweitzer D, Tan L, Broadley SA. Role of trigeminal microvascular decompression in the treatment of SUNCT and SUNA. *Curr Pain Headache Rep* 2013; 17: 332.
- Sindou M, Brinzeou A. Topography of pain in classical trigeminal neuralgia: insights into somatotopic organization. *Brain* 2020; 143: 531–40.
- Weng H-Y, Cohen AS, Schankin C, Goadsby PJ. Phenotypic and treatment outcome data on SUNCT and SUNA, including a randomised placebo-controlled trial. *Cephalalgia* 2017; 38: 1554–63.
- Williams M, Bazina R, Tan L, Rice H, Broadley SA. Microvascular decompression of the trigeminal nerve in the treatment of SUNCT and SUNA. *J Neurol Neurosurg Psychiatry* 2010; 81: 992–6.
- Williams MH, Broadley SA. SUNCT and SUNA: clinical features and medical treatment. *J Clin Neurosci* 2008; 15: 526–34.