

## Late-onset non-islet cell tumor hypoglycemia: A case report

Shunichi Matsumoto, Eijiro Yamada, Yasuyo Nakajima, Naoki Yamaguchi, Takashi Okamura, Toshiki Yajima, Satoshi Yoshino, Kazuhiko Horiguchi, Emi Ishida, Masashi Yoshikawa, Jun Nagaoka, Sho Sekiguchi, Mai Sue, Shuichi Okada, Izumi Fukuda, Ken Shirabe, Masanobu Yamada

**ORCID number:** Shunichi Matsumoto 0000-0002-3726-9105; Eijiro Yamada 0000-0002-0332-8605; Yasuyo Nakajima 0000-0003-2630-2579; Naoki Yamaguchi 0000-0002-6046-7150; Takashi Okamura 0000-0001-7812-7034; Toshiki Yajima 0000-0003-0574-9558; Satoshi Yoshino 0000-0001-9111-0632; Kazuhiko Horiguchi 0000-0001-6844-6082; Emi Ishida 0000-0002-2610-9093; Masashi Yoshikawa 0000-0002-0364-7462; Jun Nagaoka 0000-0002-1433-6686; Sho Sekiguchi 0000-0003-1897-0307; Mai Sue 0000-0003-2747-4110; Shuichi Okada 0000-0003-1403-6840; Izumi Fukuda 0000-0003-0772-3837; Ken Shirabe 0000-0002-7173-7945; Masanobu Yamada 0000-0003-4426-2670.

**Author contributions:** Yamada E contributed to the care of the patient, data collection, the literature review, and drafting the manuscript; Matsumoto S contributed to the care of the patient, data collection and the literature review; Nakajima Y, Yamaguchi N, Okamura T and Yajima T contributed to the care of the patient; Yoshino S, Horiguchi K and Ishida E contributed to drafting the manuscript; Yoshikawa M, Nagaoka J, Sekiguchi S and Sue M contributed to the care of the patient; Okada S contributed to the drafting of the manuscript; Fukuda I contributed data on performing the procedure;

Shunichi Matsumoto, Eijiro Yamada, Yasuyo Nakajima, Naoki Yamaguchi, Takashi Okamura, Satoshi Yoshino, Kazuhiko Horiguchi, Emi Ishida, Masashi Yoshikawa, Jun Nagaoka, Sho Sekiguchi, Mai Sue, Shuichi Okada, Masanobu Yamada, Department of Medicine and Molecular Science, Gunma University Graduate School of Medicine, Maebashi 371-8511, Gunma, Japan

Toshiki Yajima, Ken Shirabe, Division of General Thoracic Surgery, Integrative Center of General Surgery, Gunma University Hospital, Maebashi 371-8511, Gunma, Japan

Izumi Fukuda, Department of Endocrinology, Diabetes and Metabolism, Graduate School of Medicine Nippon Medical School, Tokyo 1138602, Japan

**Corresponding author:** Eijiro Yamada, MD, PhD, Senior Lecturer, Department of Medicine and Molecular Science, Gunma University Graduate School of Medicine, 3-39-15 Showa-machi, Maebashi 371-8511, Gunma, Japan. [eijiro.yamada@gunma-u.ac.jp](mailto:eijiro.yamada@gunma-u.ac.jp)

### Abstract

#### BACKGROUND

Hypoglycemia due to non-insulin-producing tumors is referred to as non-islet cell tumor hypoglycemia (NICTH). As NICTH is a rare lesion, the natural course of NICTH is not well understood. We report a case of NICTH that was observed 30 years before the onset of hypoglycemia.

#### CASE SUMMARY

A 50-year-old man was diagnosed with an abnormal right chest shadow during a routine X-ray examination, but no further examination was undertaken because the lesion appeared benign. Thirty years after the tumor discovery, the patient was admitted to the hospital with symptoms of severe hypoglycemia, which was diagnosed as NICTH based on a complete examination. The tumor was resected and found to be a solitary fibrous mass (15.6 cm × 13.7 cm × 10.4 cm); thereafter, the patient's blood glucose levels normalized and he completely recovered.

#### CONCLUSION

NICTH can have an acute onset, even if the tumor has been present and asymptomatic over a long time period.

**Key Words:** Hypoglycemia; Non-islet cell tumor hypoglycemia; Blood glucose; Solitary tumor; Late onset; Case report; Insulin-like growth factor II

Shirabe K and Yamada M did critical revisions to the manuscript; all authors issued final approval for the version to be submitted.

#### Informed consent statement:

Informed written consent was obtained from the patient for publication of this report and any accompanying images.

**Conflict-of-interest statement:** The authors declare that they have no conflict of interest.

#### CARE Checklist (2016) statement:

The authors have read the CARE Checklist (2016), and the manuscript was prepared and revised according to the CARE Checklist (2016).

**Open-Access:** This article is an open-access article that was selected by an in-house editor and fully peer-reviewed by external reviewers. It is distributed in accordance with the Creative Commons Attribution NonCommercial (CC BY-NC 4.0) license, which permits others to distribute, remix, adapt, build upon this work non-commercially, and license their derivative works on different terms, provided the original work is properly cited and the use is non-commercial. See: <http://creativecommons.org/licenses/by-nc/4.0/>

**Manuscript source:** Unsolicited manuscript

**Specialty type:** Medicine, research and experimental

**Country/Territory of origin:** Japan

#### Peer-review report's scientific quality classification

Grade A (Excellent): 0  
Grade B (Very good): 0  
Grade C (Good): 0  
Grade D (Fair): 0  
Grade E (Poor): 0

**Received:** April 2, 2020

**Peer-review started:** April 2, 2020

**First decision:** November 3, 2020

**Revised:** November 13, 2020

**Accepted:** November 29, 2020

**Article in press:** November 29, 2020

©The Author(s) 2021. Published by Baishideng Publishing Group Inc. All rights reserved.

**Core Tip:** Since hypoglycemia due to non-insulin-producing tumors is a rare lesion, so the natural course of non-islet cell tumor hypoglycemia (NICTH) is not well understood. Here we describe a rare case of NICTH that was caused by a tumor that had been asymptomatic for 30 years. To our knowledge, this is the longest reported latency period before the onset of severe hypoglycemia. The sudden-onset of severe hypoglycemia in the patient described in this report indicates that NICTH can have an acute onset even when the tumor has been present for a longer time.

**Citation:** Matsumoto S, Yamada E, Nakajima Y, Yamaguchi N, Okamura T, Yajima T, Yoshino S, Horiguchi K, Ishida E, Yoshikawa M, Nagaoka J, Sekiguchi S, Sue M, Okada S, Fukuda I, Shirabe K, Yamada M. Late-onset non-islet cell tumor hypoglycemia: A case report. *World J Clin Cases* 2021; 9(1): 163-169

**URL:** <https://www.wjgnet.com/2307-8960/full/v9/i1/163.htm>

**DOI:** <https://dx.doi.org/10.12998/wjcc.v9.i1.163>

## INTRODUCTION

Hypoglycemia due to non-insulin-producing tumors is referred to as non-islet cell tumor hypoglycemia (NICTH)<sup>[1,2]</sup>. NICTH is a rare lesion, but constitutes the second commonest cause of hypoglycemia after insulinoma; approximately 25% of hypoglycemic cases occur due to NICTH<sup>[3,4]</sup>. Moreover, NICTH is typically induced due to the overconsumption of glucose or overexpression of insulin-like growth factor II (IGF-II) by tumors<sup>[5-7]</sup>. Moreover, high-molecular-weight IGF-II, known as big IGF-II, has potent insulin-like activity that leads to hypoglycemia<sup>[8]</sup>. However, big IGF-II fails to build a complex with both IGF-binding protein-3 (IGFBP-3) and its acid-labile subunit, whereas it binds easily to insulin receptors to induce glucose uptake in muscles and adipose tissues, thus leading to hypoglycemia<sup>[9]</sup>. Tumors of mesenchymal or hepatic origin are usually described as NICTH. Solitary fibrous tumor (SFT) is another rare mesenchymal tumor, wherein approximately 4%-6% of SFT cases develop NICTH<sup>[2]</sup>.

## CASE PRESENTATION

### Chief complaints

During a routine chest X-ray examination, a 50-year-old man was diagnosed with an abnormal shadow in the right chest. As there were no signs to suggest the mass was malignant, the patient decided to forego further examination or treatment.

### History of present illness

Ten years after the initial discovery, a routine chest X-ray revealed an increase in the size of the previously detected shadow, and the patient was advised a biopsy and tumor removal. However, the patient refused further examination or treatment in the absence of any symptoms. Thirty years after the initial discovery, the patient was hospitalized with symptoms of severe hypoglycemia. Prior to the acute episode necessitating hospitalization, the patient had no history of hypoglycemic symptoms, such as sweating, palpitations, and loss of consciousness. Moreover, there was no history of an increase in weight for the preceding 6 mo. As the patient's hypoglycemia was resistant to treatment by frequent oral glucose supplementation, he was hospitalized for further management.

### History of past illness

The patient had no medical records or family history of hypoglycemia.

### Personal and family history

The patient was on treatment with azelnidipine for hypertension and rosuvastatin for

Published online: January 6, 2021

P-Reviewer: Avtanski D

S-Editor: Gao CC

L-Editor: A

P-Editor: Liu JH



hyperlipidemia.

### Physical examination

Clinical examination revealed no signs, except attenuation of respiratory sounds over the right chest.

### Laboratory examinations

Laboratory test results (Table 1) after hospitalization showed a slight increase in C-reactive protein (CRP) levels to 2.11 mg/dL. The anti-insulin antibody test result was negative, and fasting blood glucose was 48 mg/dL, accompanied by a low immunoreactive insulin (IRI) level of < 5.0 μU/mL. Interestingly, there was no change in the levels of insulin-counterregulatory hormones, such as cortisol, growth hormone (GH), and norepinephrine (Table 2).

### Imaging examinations

Chest X-ray and computed tomography (CT) scanning showed a giant solid tumor (11 cm × 14 cm × 15 cm) in the right lower chest region (Figure 1A and B). A fluorine-18 fluoro-2-deoxy-D-glucose (FDG) positron emission tomography showed uneven accumulation of the maximum standardized uptake value (SUVmax 3.1) indicating possible characteristics of a malignancy (Figure 1D). Interestingly, the mass showed a propensity for accumulation by octreotide scintigraphy, which was characteristic of a neuroendocrine tumor (Figure 1E).

### Further diagnostic work-up

From the biochemical and histological findings, we suspected an NICTH. To confirm this diagnosis, we undertook a core biopsy of the tumor. Immunoblots of serum IGF-II and tumoral tissue IGF-II from tumor biopsies were conducted<sup>[10]</sup>, and a high-molecular-weight form of IGF-II was identified in both types of samples on Western blotting (Figure 2A). Furthermore, immunohistochemical staining for IGF-II in tumoral tissue showed numerous immunopositive tumor cells (Figure 2B).

---

## FINAL DIAGNOSIS

---

Based on the findings from the examination and investigations, the patient was diagnosed with NICTH.

---

## TREATMENT

---

Because of problematic symptoms that were refractory to clinical treatment, we obtained written informed consent to carry out tumor resection. The resected mass was shown to be an SFT (15.6 cm × 13.7 cm × 10.4 cm; Figure 2C).

---

## OUTCOME AND FOLLOW-UP

---

Postoperatively, the patient's blood glucose levels quickly normalized, and the patient recovered completely.

---

## DISCUSSION

---

Hypoglycemia is a usual feature that is observed during the treatment of NICTH. However, in the present case, NICTH was mainly diagnosed on the basis of a hypoglycemic attack<sup>[8]</sup>. Another symptom that implicated the tumor as an NICTH was its size, which exceeded 10 cm<sup>[2,8]</sup>. There are no reports in the literature whether an increase in the tumor size induces hypoglycemia; however, in our case, the size of a tumor could be related to the occurrence of hypoglycemia. Moreover, this assumption is supported by the theory that partial resection of the tumor could reduce the incidence of hypoglycemic episodes<sup>[11]</sup>. In the present case, we observed the progression of the tumor over 30 years, wherein the increase in tumor size eventually caused hypoglycemia. Interestingly, the initial phenomenon of a hypoglycemic attack

**Table 1 Laboratory values at admission (post glucose infusion)**

	Clinical values (normal range)
WBC (/μL)	6800 (4000-9600)
Hb (g/dL)	14.7 (13.2-17.3)
Platelets × 10 <sup>4</sup> (/μL)	21.9 (16-35)
Total protein (g/dL)	7.3 (6.3-7.9)
Albumin (g/dL)	3.7 (3.9-5.0)
Total bilirubin (mg/dL)	0.6 (0.3-1.2)
AST (U/L)	18 (13-33)
ALT (U/L)	10 (8-42)
LDH (U/L)	221 (119-229)
ALP (U/L)	229 (115-359)
γ-GTP (U/L)	16 (10-47)
ChE (U/L)	257 (213-501)
AMY (U/L)	78 (49-136)
Blood urea nitrogen (mg/dL)	5 (8-20)
Creatinine (mg/dL)	0.60 (0.65-1.07)
Na (mEq/L)	144 (137-145)
K (mEq/L)	4.0 (3.5-4.8)
Cl (mEq/L)	107 (100-107)
T-Cho (mg/dL)	206 (128-219)
TG (mg/dL)	44 (30-149)
HbA1c (%)	5.4 (4.6-6.2)
Glycoalbumin (%)	15.8 (11.0-16.0)
Insulin antibody	Negative
CEA (ng/mL)	2.2 (0-5.0)
SCC (ng/mL)	1.0 (0-1.5)
NSE (ng/mL)	10.6 (0-12)
CYFRA (ng/mL)	2.1 (< 3.5)
ProGRP (pg/mL)	51.8 (< 80)
SLX (U/mL)	19.4 (0-38.0)
Blood glucose (mg/dL)	130 (80-110)
Immunoreactive insulin (μg/mL)	6.8 (1.0-21.74)
Serum C-peptide (ng/mL)	1.50 (1.1-3.3)
Free T3 (pg/mL)	2.30 (1.88-3.18)
Free T4 (ng/dL)	0.93 (0.70-1.48)
Adrenocorticotrophic hormone (pg/mL)	77.0 (7.2-63.3)
Cortisol (μg/dL)	11.0 (3.0-19.6)
Human growth hormone (ng/mL)	< 0.07 (< 2.10)
IGF-1 (ng/mL)	92

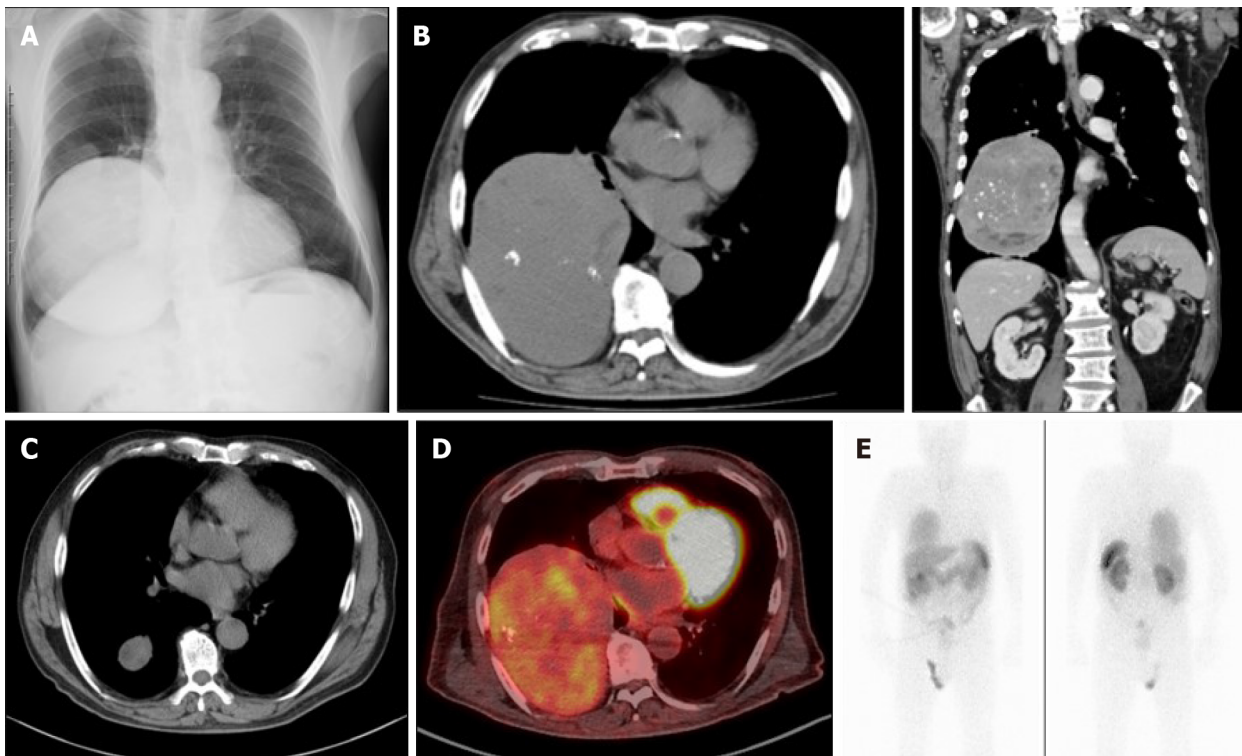
WBC: White blood cell; Hb: Hemoglobin; AST: Aspartate aminotransferase; ALT: Alanine aminotransferase; LDH: Lactate dehydrogenase; ALP: Alkaline phosphatase; γ-GTP: gamma-glutamyl transpeptidase; ChE: Cholinesterase; AMY: Alpha-amylase; T-Cho: Total cholesterol; TG: Total triglyceride; HbA1c: Hemoglobin A1c; SCC: Squamous cell carcinoma-related antigen; CEA: Carcinoembryonic antigen; NSE: Neuron-specific enolase; CYFRA: Cytokeratin-19

fragment; ProGRP: Progastrin releasing peptide; SLX: Siaryl Lewis X; T3: Triiodothyronine; T4: Tetraiodothyronine; IGF: Insulin-like growth factor.

**Table 2** Laboratory values in the fasting blood glucose test sample

	Clinical values (normal range)
Blood glucose (mg/dL)	48 (80-110)
Immunoreactive insulin ( $\mu$ g/mL)	< 5.0 (1.0-21.74)
Serum C-peptide (ng/mL)	0.02 (1.1-3.3)
Free T3 (pg/mL)	2.48 (1.88-3.18)
Free T4 (ng/dL)	1.16 (0.70-1.48)
Adrenocorticotrophic hormone (pg/mL)	36.9 (7.2-63.3)
Cortisol ( $\mu$ g/dL)	11.0 (3.0-19.6)
Human growth hormone (ng/mL)	0.49 (< 2.10)
Glucagon (pg/mL)	188 (71-174)
Epinephrine (ng/mL)	0.18 (< 0.10)
Norepinephrine (ng/mL)	0.78 (0.1-0.5)
Dopamine (ng/mL)	0.02 (< 0.03)

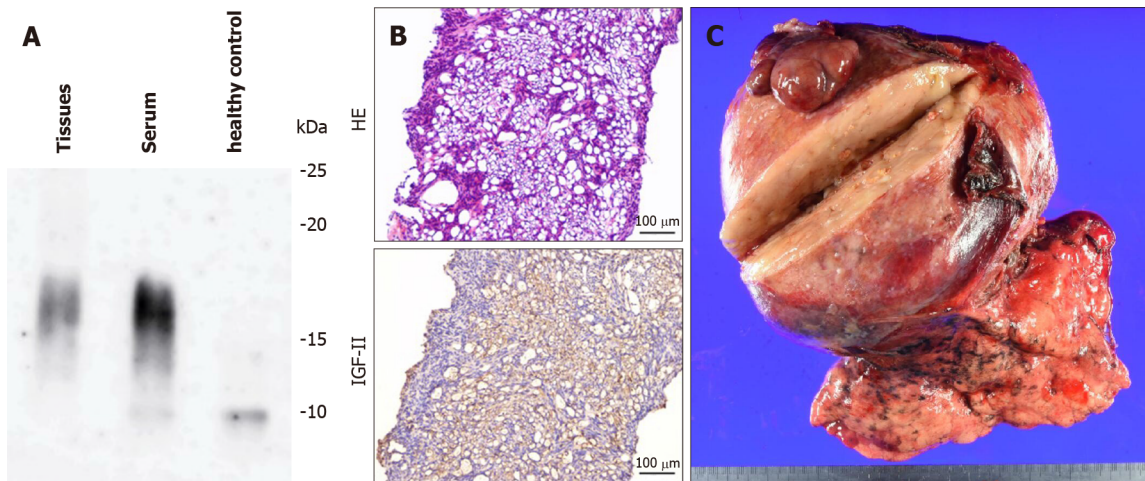
T3: Triiodothyronine; T4: Tetraiodothyronine.



**Figure 1** Imaging findings. A and B: Chest X-ray (A) and computed tomography (B) (left-hand side is transverse plane; right-hand side is coronal plane) showed a heterogenous giant mass measuring 11 cm  $\times$  14 cm  $\times$  15 cm in size on the right lower chest; C: Computed tomography from ten years ago showed the tumor's growth in the past decade; D and E: Positron emission tomography (D) and octreotide scintigraphy (E) showed the tumor's accumulation.

without any increase of body weight possibly implies that sudden-onset NICTH could occur during the tumor progression.

Besides the overexpression of big IGF-II, NICTH of hepatic origin could be attributed to irregular of gluconeogenesis<sup>[2]</sup>, or an increase of glucose consumption by



**Figure 2 Pathological findings.** A: Western blot analysis of high-molecular-weight insulin-like growth factor II (IGF-II). High molecular weight form of IGF-II was detected, both in the tumor tissue and in the serum; B: Histopathological examination of biopsy specimens. The tumor cells were immunopositive for IGF-II. The upper panel shows macroscopic findings of the surgical specimen. HE, hematoxylin and eosin staining; IGF-II, immunohistochemical staining for IGF-II; C: The tumor size was 15.6 cm × 13.7 cm × 10.4 cm. The histological diagnosis was of a solitary fibrous tumor. Histopathological characteristics were as follows: CD34(-), STAT6(+), c-kit(-), S-100(-), desmin(-), αSMA(-), p53(±), and MIB-1: 3.6%. HE: Hematoxylin and eosin; IGF-II: Insulin-like growth factor II.

big tumors<sup>[2]</sup>. Notably, the tumor, in the present case, showed an increase in the FDG uptake, indicating glucose uptake by the tumor. The histopathological examination diagnosed the tumor as an SFT with no evidence of malignancy; therefore, the sign of FDG uptake could indicate the possible development of malignancy, and increased glucose uptake by the tumor may have induced hypoglycemia through big IGF-II. Indeed, insulin-like effects of big IGF-II are reported to lead to increased glucose uptake in insulin-sensitive tissues, especially muscle and fat<sup>[8]</sup>, although they may induce glucose uptake in the tumor itself<sup>[1]</sup>.

NICTH is supposed to be induced by big IGF-II insulin-like activity; however, there are reports that IGF-II might regulate other insulin-counterregulatory hormones, such as GH and IGF-II, which could lead to hypoglycemia<sup>[2]</sup>. Furthermore, IGF-II could downregulate the expression of IGF-II<sup>[1]</sup>. Interestingly, the initial pathological phenomenon of a hypoglycemic attack without previous weight gain and potentially implies the sudden-onset occurrence of NICTH, to immediately exceed the threshold during tumor progression.

The complete treatment of NICTH is total resection of tumor, which could be difficult because of the characteristics of the tumor itself, metastasis, location, size, and so on<sup>[1,2,7]</sup>. In the present case, the total resection of the tumor could be undertaken despite the inconveniences of the patient's age and treatment preference. Therefore, we considered other treatment options: Introduction of intravenous hyperalimentation, enteral tube feeds, local therapies (*e.g.*, embolization, radiation), systemic therapies (*e.g.*, chemotherapy, targeted antitumor therapy such as imatinib), glucocorticoids, rh GH, glucagon, octreotide, diazoxide, or bendrofluzide<sup>[2,3]</sup>. However, we found none of the options to be sustainable for self-management. This was especially because the patient showed an accumulation of octreotide, demonstrating tumor characteristics typical of a neuroendocrine tumor. Nonetheless, a high concentration of octreotide is not a definitive indicator for NICTH even if octreotide is accumulated within the tumor<sup>[13]</sup>. Considering all of these factors, we finally obtained informed consent from the patient to undertake lung resection.

## CONCLUSION

In conclusion, we describe a case of NICTH that was observed for 30 years, which is most likely the longest reported duration up to the onset of severe hypoglycemia thus far. The sudden-onset severe hypoglycemia in the present case indicates that NICTH could occur immediately with IGF-II levels above threshold during the tumor progression even over a longer time course.

## REFERENCES

- 1 **Schutt RC**, Gordon TA, Bhabhra R, Cathro HP, Cook SL, McCartney CR, Weiss GR. Doege-Potter syndrome presenting with hypoinsulinemic hypoglycemia in a patient with a malignant extrapleural solitary fibrous tumor: a case report. *J Med Case Rep* 2013; **7**: 11 [PMID: [23302323](#) DOI: [10.1186/1752-1947-7-11](#)]
- 2 **Bodnar TW**, Acevedo MJ, Pietropaolo M. Management of non-islet-cell tumor hypoglycemia: a clinical review. *J Clin Endocrinol Metab* 2014; **99**: 713-722 [PMID: [24423303](#) DOI: [10.1210/jc.2013-3382](#)]
- 3 **de Groot JW**, Rikhof B, van Doorn J, Bilo HJ, Alleman MA, Honkoop AH, van der Graaf WT. Non-islet cell tumour-induced hypoglycaemia: a review of the literature including two new cases. *Endocr Relat Cancer* 2007; **14**: 979-993 [PMID: [18045950](#) DOI: [10.1677/ERC-07-0161](#)]
- 4 **Takayama S**, Nagai N, Hirata Y. Incidence of insulin autoimmune syndrome in Japan during the three-year period from 1979 to 1981. *J Jap Diab Soc* 1983; **26**: 143-146 [DOI: [10.11213/tonyobyoy1958.26.143](#)]
- 5 **Daughaday WH**, Emanuele MA, Brooks MH, Barbato AL, Kapadia M, Rotwein P. Synthesis and secretion of insulin-like growth factor II by a leiomyosarcoma with associated hypoglycemia. *N Engl J Med* 1988; **319**: 1434-1440 [PMID: [3185662](#) DOI: [10.1056/NEJM198812013192202](#)]
- 6 **Ma RC**, Tong PC, Chan JC, Cockram CS, Chan MH. A 67-year-old woman with recurrent hypoglycemia: non-islet cell tumour hypoglycemia. *CMAJ* 2005; **173**: 359-361 [PMID: [16103505](#) DOI: [10.1503/cmaj.050422](#)]
- 7 **Han G**, Zhang Z, Shen X, Wang K, Zhao Y, He J, Gao Y, Shan X, Xin G, Li C, Liu X. Doege-Potter syndrome: A review of the literature including a new case report. *Medicine (Baltimore)* 2017; **96**: e7417 [PMID: [28682900](#) DOI: [10.1097/MD.0000000000007417](#)]
- 8 **Fukuda I**, Hizuka N, Ishikawa Y, Yasumoto K, Murakami Y, Sata A, Morita J, Kurimoto M, Okubo Y, Takano K. Clinical features of insulin-like growth factor-II producing non-islet-cell tumor hypoglycemia. *Growth Horm IGF Res* 2006; **16**: 211-216 [PMID: [16860583](#) DOI: [10.1016/j.ghir.2006.05.003](#)]
- 9 **Phillips LS**, Robertson DG. Insulin-like growth factors and non-islet cell tumor hypoglycemia. *Metabolism* 1993; **42**: 1093-1101 [PMID: [8412760](#) DOI: [10.1016/0026-0495\(93\)90265-p](#)]
- 10 **Hikichi M**, Kiriya Y, Hayashi T, Ushimado K, Kobayashi N, Urano M, Kuroda M, Utsumi T. A Hypoglycemia-inducing Giant Borderline Phyllodes Tumor Secreting High-molecular-weight Insulin-Like Growth Factor II: Immunohistochemistry and a Western Blot Analysis. *Intern Med* 2018; **57**: 237-241 [PMID: [29021486](#) DOI: [10.2169/internalmedicine.9287-17](#)]
- 11 **Takeuchi S**, Goda T, Taguchi J, Douhata Y, Honma R, Ariga S, Ohhara Y, Shimizu Y, Kinoshita I, Fukuda I, Nagashima Y, Akita H. Late Onset of Non-islet Cell Tumor Hypoglycemia Managed via Multidisciplinary Treatment in a Patient with a Solitary Fibrous Tumor. *Intern Med* 2018; **57**: 2431-2436 [PMID: [29526941](#) DOI: [10.2169/internalmedicine.0231-17](#)]
- 12 **Unger RH**. The riddle of tumor hypoglycemia. *Am J Med* 1966; **40**: 325-330 [PMID: [5326198](#) DOI: [10.1016/0002-9343\(66\)90127-6](#)]
- 13 **Perros P**, Simpson J, Innes JA, Teale JD, McKnight JA. Non-islet cell tumour-associated hypoglycaemia: 111In-octreotide imaging and efficacy of octreotide, growth hormone and glucocorticosteroids. *Clin Endocrinol (Oxf)* 1996; **44**: 727-731 [PMID: [8759187](#) DOI: [10.1046/j.1365-2265.1996.721542.x](#)]



Published by **Baishideng Publishing Group Inc**  
7041 Koll Center Parkway, Suite 160, Pleasanton, CA 94566, USA

**Telephone:** +1-925-3991568

**E-mail:** [bpgoffice@wjgnet.com](mailto:bpgoffice@wjgnet.com)

**Help Desk:** <https://www.f6publishing.com/helpdesk>

<https://www.wjgnet.com>

