

## OPEN

# Liver Transplantation in Locally Unresectable, Undifferentiated Embryonal Cell Sarcoma

Benoy I. Babu, FRCS,<sup>1</sup> David L. Bigam, FRCSC,<sup>1</sup> Susan M. Gilmour, FRCPC,<sup>2</sup> Khaled Z. Dajani, FRCS,<sup>1</sup> A.M. James Shapiro, FRCSC,<sup>1</sup> and Norman M. Kneteman, FRCSC<sup>1</sup>

**Background.** Undifferentiated embryonal cell sarcoma (UESL) of the liver is the third most common malignant liver disease of childhood presenting as a rapidly enlarging intraabdominal mass. This systematic review explores the practicality of liver transplantation as a viable option in the treatment armamentarium for locally advanced undifferentiated embryonal cell sarcoma. **Methods.** A systematic review of the literature was performed using Medline and Embase, from inception of databases to December 31, 2018. Keywords and MeSH headings used were embryonal sarcoma, mesenchymal sarcoma, and liver transplant. Reviews and manuscripts with incomplete data were excluded. **Results.** Twenty-eight patients had orthotopic liver transplantation (OLT) as a curative treatment option. The median age at presentation was 8 and 27 years in the pediatric and adult population, respectively, with a similar male to female ratio. A majority of the patients presented with abdominal pain, palpable mass, and a normal alpha-feto-protein. The median tumor size was 15 cm mainly affecting the right lobe (62%) of the liver. Eighty-two percent of the patients underwent primary OLT and 5 patients had salvage OLT. One death (3.6%) was due to initial misdiagnosis and management for hepatoblastoma. Recurrence was noted in 7.1% of the population. The median follow-up was noted to be 28.5 months. The documented survival rate post-liver transplant for UESL was 96%. **Conclusions.** Based on available data and the very positive results therein, liver transplantation is a practical and justifiable use of a scarce resource as a treatment option for locally unresectable, undifferentiated embryonal cell sarcoma. The authors propose (accepting existence of different proposals) neoadjuvant therapy before curative resection, and if not achievable, then liver transplantation followed by adjuvant chemotherapy is an option for suitable candidates. For recurrent tumors after surgical resection, adjuvant therapy with salvage liver transplantation is an option.

(*Transplantation Direct* 2021;7: e654; doi: 10.1097/TXD.0000000000001106. Published online 15 January, 2021.)

## INTRODUCTION

Undifferentiated embryonal cell sarcoma (UESL) of the liver is the third most common malignant liver disease of childhood accounting for 9%–13% of pediatric liver malignancies.<sup>1,2</sup> Although commonly found in children,

with a peak incidence between the age group of 6–10 years,<sup>3</sup> there are reports of its presence in the adult population<sup>4</sup> with no sex predilection.<sup>2</sup>

It presents as a rapidly growing palpable intraabdominal mass and abdominal pain,<sup>5</sup> occasionally associated with fever and anorexia in the more advanced cases.<sup>6</sup> First reported by Stocker and Ishak in 1978, these tumors arise from the malignant transformation of embryonal cells of the liver.<sup>7</sup> Because of their internal myxoid nature with cystic and solid components, they are prone to rupture on biopsies.<sup>6</sup>

Historically, the prognosis of UESL was considered to be dismal.<sup>7</sup> With the advent of curative surgical resection or a combination of liver resection and chemotherapy, improvement in the 5-year survival was noted.<sup>2</sup> Shi et al felt that surgical resection with or without chemotherapy was associated with better outcomes and negative surgical margin was not associated with improved survival.<sup>8</sup>

In patients where a curative resection is not attainable, liver transplantation has been attempted as an option for a better prognosis. Donor scarcity has been one of the rate-limiting factors in this option.

This systematic review and our experience explore the practicality of liver transplantation, as a viable option in the treatment armamentarium for locally advanced undifferentiated embryonal cell sarcoma.

Received 10 August 2020. Revision received 26 October 2020.

Accepted 11 November 2020.

<sup>1</sup> Department of Surgery, Section of Hepatobiliary, Pancreatic and Transplant Surgery, University of Alberta Hospital, Edmonton, AB, Canada.

<sup>2</sup> Department of Pediatrics, Division of Pediatric Gastroenterology & Nutrition, Stollery Children's Hospital, Edmonton, AB, Canada.

The authors declare no funding and conflicts of interest.

B.I.B. and N.M.K. participated in review design. B.I.B., N.M.K., D.L.B., A.M.J.S., K.Z.D., and S.M.G. participated in the writing of the article. B.I.B. participated in the performance of the review. B.I.B. participated in data analysis.

Correspondence: Benoy I. Babu, 2D4.44 Walter C. MacKenzie Health Sciences Centre, University of Alberta Hospital, Edmonton, AB T6G 2B7, Canada. (idicula@ualberta.ca).

Copyright © 2021 The Author(s). *Transplantation Direct*. Published by Wolters Kluwer Health, Inc. This is an open-access article distributed under the terms of the Creative Commons Attribution-Non Commercial-No Derivatives License 4.0 (CCBY-NC-ND), where it is permissible to download and share the work provided it is properly cited. The work cannot be changed in any way or used commercially without permission from the journal.

ISSN: 2373-8731

DOI: 10.1097/TXD.0000000000001106

## MATERIALS AND METHODS

### Study Design and Search Strategies

The systematic review was structured on the methodology of the Cochrane systematic review protocol<sup>9</sup> and the Preferred Reporting Items for Systematic Reviews and Meta-Analyses (PRISMA) guidelines for data reporting.<sup>10</sup>

A comprehensive and extensive computerized search of the English literature using the OVID search engine<sup>11</sup> was performed.

The Medical Subject Headings (MeSH) headings used were “embryonal sarcoma,” “mesenchymal sarcoma,” and “liver transplant.” The headings were truncated to broaden the search and combined with Boolean operators to focus and connect the MeSH headings.

### Eligibility Criteria

The PICO structure was used within the research question when the selection criteria were performed.<sup>12</sup> All studies mentioning the use of liver transplant in the treatment of embryonal cell sarcoma were examined.

Observational reports, multicenter reports, single-center series, case reports, and case series were involved. No randomized control studies were found to have been performed on this topic.

Studies were limited to manuscripts in the English language and pertaining to human beings. Reviews and manuscripts containing incomplete data for the study were excluded.

### Information Sources

The bibliographic databases searched were Excerpta Medica database (EMBASE) and Ovid MEDLINE. The time frames for the respective bibliographic databases were from inception of the databases till December 31, 2018. The search string was first designed for PubMed and then translated to other databases (Figure 1).

### Study Selection

The bibliographic reference manager software EndNote X9.1.1 was used to manage the references emerging from the database searches.

Titles and abstracts of references were screened, and the potentially relevant references were assessed for eligibility. The full manuscripts were obtained and screened against the inclusion and exclusion criteria. Reference lists of eligible manuscripts were screened to pick missed relevant articles. If similar or follow-up results were reported in different papers especially by the same institution, the manuscript containing the complete and latest dataset was selected.

### Data Extraction and Analysis

A code-book was created on Microsoft Excel database. The data extracted were based on the following sections: (a) general information on the manuscript (eg, year of publication, country of origin, type of study, and time period); (b) demographics of the dataset (eg, study design, sample size and characteristics, age, and gender); (c) morphology and staging of tumor; (d) type and cycles of chemotherapy used; (e) follow-up period; and (f) retransplant and recurrence.

Data are presented as median (range) and nonparametric tests are used for comparisons unless otherwise specified.

### Case Report

A retrospective review of the charts of 2 patients treated for UESL at the University of Alberta Hospital, Edmonton, Alberta, Canada, was carried out (Figure 2). The data extraction and analysis were carried out as mentioned in the previous paragraph (Table 1). This was with the approval of the Local Health Research Ethics Board and in compliance with the appropriate Health Information Act (Pro00097398). For the purpose of this review, our data has been combined with data gleaned from the manuscripts.

## RESULTS

### Demographics of Study Population

A total of 28 patients have undergone orthotopic liver transplant (OLT) for undifferentiated embryonal cell sarcoma reported in 13 articles and including *our unreported* experience. The manuscripts were all retrospective in nature. The time frame of the selected manuscripts was from 1981 to 2016.

The median age of pediatric patients who were transplanted for UESL was 8 years (range: 4 mo–15 y). The median age for adults (>18 y) who required liver transplant for UESL was 27 years (range: 21–54 y).

The male to female ratio of the patients undergoing OLT was similar.

### Presenting Symptoms

Presenting symptoms were described in 12 patients who underwent liver transplant. The most common presenting symptoms were epigastric and right upper quadrant pain with a palpable mass.<sup>2,3,13,14</sup> Two patients described abdominal distention as part of their presenting symptom.<sup>4</sup> One patient presented with jaundice before transplant.<sup>15</sup>

### Investigations Used

A majority of patients had a computerized tomography and MRI for diagnosis and staging. Tumor staging using the PRE-TEXT classification<sup>16</sup> was reported in 2 patients. The tumor marker, alpha-feto-protein (AFP) was reported in 10 patients, 90% had normal or negative results. Only 1 patient was found to have a raised AFP, and this patient was initially misdiagnosed as hepatoblastoma.<sup>17</sup>

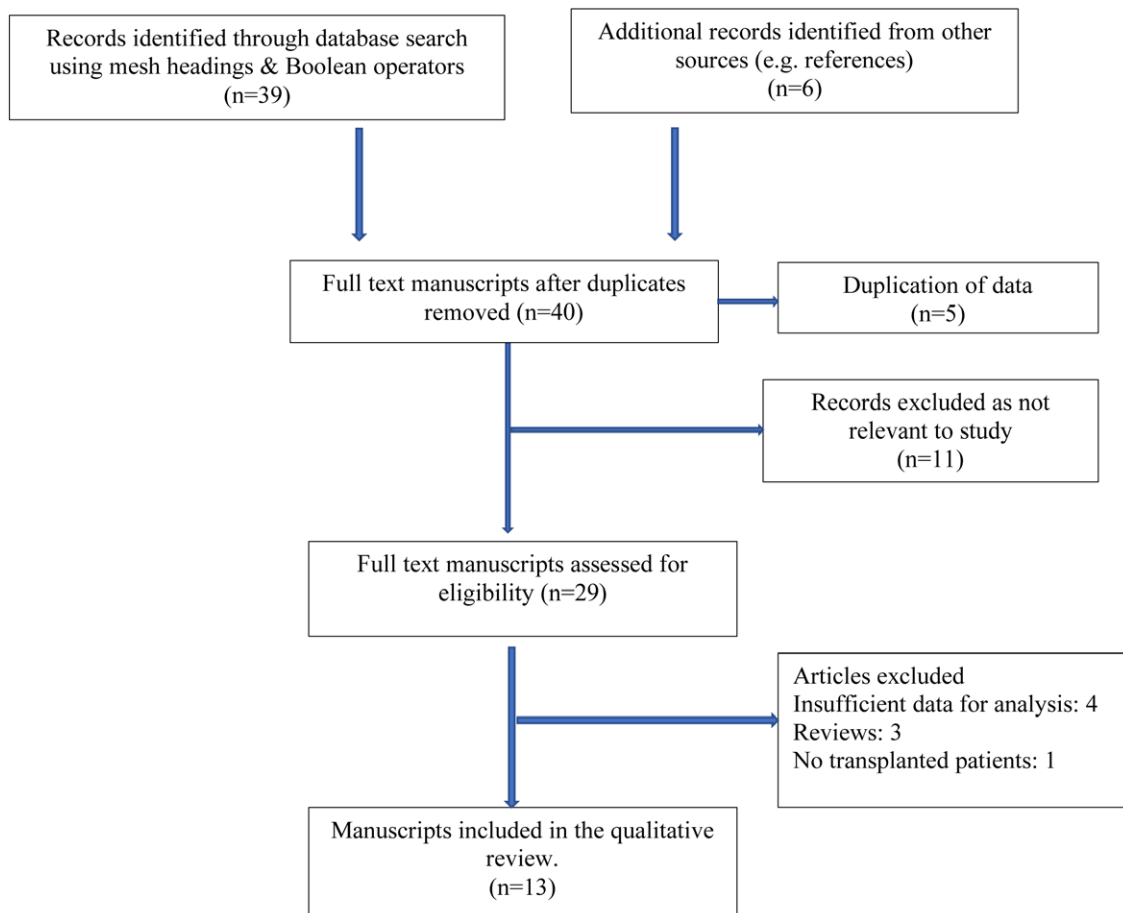
### Tumor Morphology

The median diameter of the tumor on imaging was 15 cm (range: 8–25 cm).

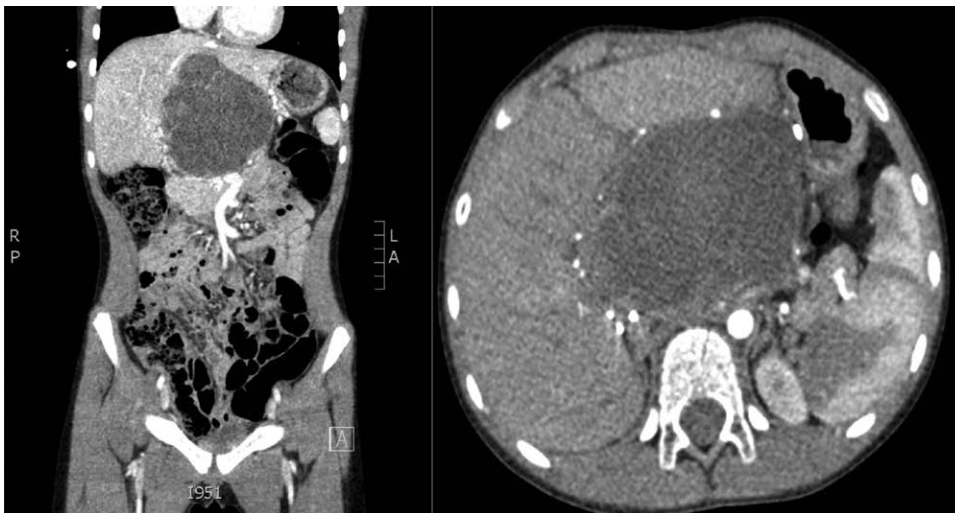
Thirteen patients had descriptions about the site of their tumor in the liver. Eight (62%) of those patients predominantly had tumors involving the right lobe of the liver, some of which were extending in to the left lobe. Three patients had tumors originating in the left lobe. One of the patients had tumors in the hilar region of the liver and another had tumor involving the entire liver.

Characterization of the tumor was mentioned in 8 patients and all of them had a solid and cystic component. One of those patients had hemorrhaged in to the tumor. Two patients were initially diagnosed to have undifferentiated mesenchymal hamartomas but were found to have UESL in the resected specimen.<sup>18</sup>

Only 1 patient had a distant lung metastasis; this was resected before liver transplant.<sup>3</sup>



**FIGURE 1.** Flow chart of search strategy and exclusion criteria.



**FIGURE 2.** Cross-sectional imaging of UESL tumor treated at University of Alberta Hospital, Edmonton, Canada.

### **Chemotherapy** Preoperative and Postoperative Chemotherapy With Curative Resection in Patients Undergoing Salvage OLT

Four of the 6 patients who underwent curative resection had preoperative chemotherapy. This involved alkylating agents (ifosfamide, cisplatin) and anthracyclines. The median number of cycles was 9 (range: 5–10).

Similar chemotherapeutic agents were used postoperatively, and the median number of cycles was 4 (range: 2–10) (Table 2).

### **Preoperative and Postoperative Chemotherapy in Patients Undergoing Primary OLT**

The main chemotherapeutic agents are similar to the ones used in patients for salvage OLT, which include alkylating

**TABLE 1.****Patients with UESL treated at University of Alberta Hospital, Edmonton, Canada**

Name	sLTx	Age	Sex	Symptoms	Site	Solid/cystic component	AFP	Size (mean)	Curative resection before OLT	Postsurgery chemo	Chemo after liver surgery	Post sLTx chemo	Major complications	Follow-up period in remission (mo)	Death
1	1	120	F	Distension, pain and mass	Right → left	Y	N	15 × 7 cm	Rt trisegmentectomy	ARST 0332 protocol	VAC chemo (1 dose)	Cyclophosphamide and vinorelbine		12	0
2	1	372	F	Recurrence after surgery	Seg: 2, 3, 4	Y	N	10.3 × 8.5 × 7.7 cm	Resected twice: (left lobe, segment 6)	Cyclophosphamide and vincristine			Rejection due to noncompliance	120	0

ARST (0332 protocol), ifosfamide and doxorubicin; F, female; age in mo; N, normal; OLT, orthotopic liver transplantation; Rt, right; sLTx, salvage liver transplant; UESL, undifferentiated embryonal cell sarcoma; VAC chemo, temozolomide and irinotecan; Y, yes.

**TABLE 2.****Patients undergoing salvage LTx with chemotherapy**

Author, y	Age (mo)	Preresection chemo	Preresection chemo cycles	Postresection chemo	Postsurgery chemo cycles	Presalvage liver Tx chemo	Post-LTx chemo cycles	Post-LTx chemo
Walther, 2014	84	Vincristine, actinomycin D, ifosfamide doxorubicin	9	Vincristine, actinomycin, ifosfamide doxorubicin	10	Etoposide, carboplatinum	None	None
Plant A., 2013	156	Cisplatin, doxorubicin	5	None	None	Ifosfamide, etoposide, carboplatin	2	Ifosfamide, carboplatin, paclitaxel
Castrillon GA, 2009	30	NA	NA	NA	NA	NA	NA	NA
AHS PT 1, 2018	120	Ifosfamide, doxorubicin	10	Ifosfamide, doxorubicin	4	VAC chemo temozolomide irinotecan	None	Cyclophosphamide vinorelbine
AHS PT 2, 2005	372	None	None	Cyclophosphamide, vincristine	NA	None	None	None

LTx, liver transplant; NA, data not available; none, did not have chemotherapy.

agents and anthracyclines with a median number of 4 cycles (range: 1–6) (Table 3).

### Surgical Resection With Curative Intent, Before Liver Transplant

Five patients had surgical resection with curative intent before liver transplantation. Of the patients who underwent surgery before their OLT, 2 (including 1 of our patients) had a right trisegmentectomy.<sup>3</sup> One patient had a right lobe resection. Another patient underwent an exploratory laparotomy and cyst drainage of a multiloculated cystic tumor.<sup>13</sup>

One of our patients had a left lobe resection. She developed recurrence 4 years later and underwent segment 4 resection. The patient developed a second recurrence in the remnant liver a further 6 years later and required a salvage OLT.

### Orthotopic Liver Transplantation

Two modalities of a surgical approach have been used for patients who presented with UESL tumors. Depending on the initial presentation, primary OLT (Table 4) and salvage OLT

(Table 5) have been the available options. Primary OLT was performed in patients in which the tumor was contained in the liver, but a curative resection was not a practical option because of either insufficient remnant volume or involvement/proximity to major vascular structures.<sup>1,18</sup> Salvage liver transplant was resorted to in cases wherein the tumor was treated with chemotherapy and curative resection was achieved, but the tumor recurred.

Twenty-three patients (82%) underwent primary OLT, and five patients (18%) had salvage OLT. The type of donor liver was documented in 8 patients. Six patients received deceased donor livers, and 2 patients received live related<sup>15</sup> and unrelated donors.

Three patients (11%) were documented to have rejection after OLT.<sup>4,19</sup> One patient had cardiac dysfunction.<sup>18</sup> One patient has a bile duct anastomotic leak<sup>3</sup> and another had developed a diaphragmatic hernia.<sup>18</sup> The majority of the patients had tacrolimus as 1 of their immunosuppressive medications.

Two patients (7.1%) required retransplant because of rejection.<sup>4,19</sup>

**TABLE 3.**  
Patients undergoing primary LTx with chemotherapy

Author, y	Primary LTx	Age (mo)	Pre-LTx chemo	Pre-LTx chemo cycles	Post-LTx chemo cycles	Post-LTx chemo
Schluckebier D, 2016	1	120	Ifosfamide, vincristine, dactinomycin	4	9	Ifosfamide, vincristine, dactinomycin
Shi Y, 2017	10	108	NA	NA	NA	NA
Techavichit P, 2016	1	264	Ifosfamide doxorubicin	5	None	None
Walther, 2014	1	156	Ifosfamide doxorubicin	6	4	Vincristine, actinomycin D, cyclophosphamide
Walther, 2014	1	132	Ifosfamide doxorubicin.	5	1	Ifosfamide
Ismail, 2013	1	4	Cisplatin doxorubicin	2	NA	Cyclophosphamide, doxorubicin vincristine
Rohan V, 2014	2	32	NA	NA	NA	NA
Chen LE, 2006	1	73	Cisplatin, adriamycin, vincristine, Ifosfamide	4	None	None
Chen LE, 2006	1	60	Cisplatin, adriamycin, vincristine	1	None	None
Okajima H, 2009	1	180	Vincristine, actinomycin cyclophosphamide	Stopped early: side effects	NA	Vincristine, actinomycin, cyclophosphamide
Dower NA, 2000	1	72	Ifosfamide, carboplatin, etoposide	2	None	None
Khan Z, 2017	1	252	Ifosfamide doxorubicin	5	None	None
Dhanasekaran R, 2012	1	648	Adriamycin ifosfamide dacarbazine	10 mo	None	None

LTx, liver transplant; NA, data not available; none, did not have chemotherapy.

**TABLE 4.**  
Patients undergoing primary OLT

Name, y	Age	Sex	Symptoms	Tumor site	Solid/cystic	Size of tumor	Preop chemo	P-OLT chemo	Remission period	Recurrence after OLT	Re-OLT	Death
Schluckebier D, 2016	120	M	Abdominal pain	Entire	Y	NA	Y	Y		No	No	0
Shi Y, 2017	108 (m)				NA	13.7 (m)	N	N	60.9 (m)	No	No	0
Techavichit P, 2016	264		RUQ mass and pain	NA	Y+He	23	Y	N	28	No	No	0
Walther 1, 2014	156	F	RUQ mass and pain	Rt	NA	NA	Y	Y	24	No	No	0
Walther 2, 2014	132	M	Pain, weight loss	Rt	Y	17×, 12×, 14	Y	Y	24	No	No	0
Ismail, 2013	4	F	Abdominal pain	Rt→Lt	NA	NA	Y	Y	8	Yes	No	1
Rohan V	32		NA	NA	NA	NA	N	NA	NA	No	No	0
Chen LE, 2006	73	F	NA	NA	NA	NA	Y	N	45	No	No	0
Chen LE, 2006	60	F	NA	NA	NA	NA	Y	N	29	No	No	0
Okajima H, 2009	180	M	Jaundice	Hilar	NA	15	Y	Y	24	Yes		0
Dower NA, 2000	72	M	RUQ pain, anemia	Rt→Lt	Y	12×11×14	Y	N	79	No	Yes	0
Khan Z, 2017	252	M	RUQ mass and pain	Rt lobe	Y	14×10×10	Y	None	18	No	No	0
Dhanasekaran R, 2012	648	M	Distension	Lt lobe	NA	25	Y	None	123	No	Yes	0

Period of remission and age in mo, size of tumor in centimeter.

F, female; He, hemorrhage; Lt, left; (m), mean; M, male; N, no; NA, not available; OLT, orthotopic liver transplantation; P-OLT chemo, post-OLT chemo; Rt, right; Y, yes.

**TABLE 5.**  
Patients undergoing salvage OLT

Name	Age	Sex	Symptoms	Tumor site	Solid/cystic component	Size of tumor (mean)	Preop chemo	Curative resection before LTx	Postsurgery chemo	Donor type	Post-LTx chemo	Period in remission	Recurrence after-LTx	Death
Walthier, 2014	84	M	Shoulder tip pain	Right → left	Y	8 cm	Y	RT trisegmentectomy	Y	Cadaveric whole liver		168	0	0
Plant A, 2013	156			Right	NA	N	Y	Resection	N	NA	Y	37	37	0
Castrillon GA, 2009	30	M	Large nontender mass	Left → rt	Y	18 × 15 × 20 cm	None	Exploratory laparotomy and cyst drainage	N	Cadaveric whole liver	N	12	0	0
UAH 1 2018	120	F	Abdo distension, pain, and mass	Rt → left	Y	15 × 7 cm	Y	Rt trisegmentectomy	Y	Live unrelated left lateral seg	Y	3	0	0
UAH 2 2005	372	F	Recurrence after surgery	Left and seg4	Y	10.3 × 8.5 × 7.7 cm		Left lobe → seg6 resect	Y	NA	NA	120	0	0

Age, period in remission, recurrence in mo.

F, female; LTx, liver transplant; M, male; N, no; NA, not available; OLT, orthotopic liver transplant; rt, right; Y, yes.

## Pathology

All the explanted pathology was suggestive of UESL. Patients, who had description of the histology of their explanted liver, had between 90% and 100% necrosis of their tumor. These patients had undergone chemotherapy before liver transplantation.

## Survival and Recurrence

The median survival was 28.5 months (range: 8–123 mo). This is influenced by the bias in the timeline of reporting. Eleven patients were documented to have survived the 5-year period.

One patient (3.6%) died after OLT.<sup>17</sup> This particular patient was misdiagnosed as hepatoblastoma initially and had preoperative chemotherapy but did not respond and underwent an OLT.

Only 2 (7.1%) of the 28 patients had recurrence after liver transplant.<sup>1,15,17</sup> One of the patients had recurrent hilar tumor in the transplanted liver, which was resected and treated with chemotherapy.<sup>15</sup> The patient was disease free 18 months after resection. The other patient had a misdiagnosis of primary tumor, had an OLT, and relapsed.<sup>17</sup>

Two (7.1%) patients had to undergo retransplant for rejection.<sup>4,19</sup>

## DISCUSSION

Management strategies have evolved in the treatment of locally unresectable UESL. This systematic review has examined the available literature on the use of liver transplantation as a potential treatment option in both the pediatric and adult population, wherein the tumor is unresectable and as salvage therapy in patients with recurrence.

Our systematic review along with our clinical experience has analyzed the data presently available on the utilization of OLT for the treatment of UESL. The data have been pooled based on the demographics, presenting symptoms, investigation used, tumor morphology, chemotherapy, and outcomes on liver transplantation.

Interpretation of data for the purpose of this systematic review must accept that data pooling has inherent limitations in sensitivity, clinical heterogeneity, and publication bias. Nevertheless, this is the largest reported series of patients treated with OLT for this rare tumor.

A total of 28 patients had liver transplantation as a curative treatment option. The median age at presentation of the tumor was 8 and 27 years in the pediatric and the adult population, respectively, with a similar male to female ratio. The majority of the patients presented with upper abdominal pain and a palpable mass. A majority of the patients had a normal AFP, and the median tumor size was 15 cm mainly affecting the right lobe of the liver (62%).

Eighty-two percent (23) of the patients underwent primary OLT, and 5 patients (18%) had salvage OLT.

One death (3.6%) was noted because of an initial misdiagnosis and management for hepatoblastoma. Recurrence was noted in 7.1% of the population, and retransplantation was required for 2 patients with rejection. All the patients were alive till the point of publication of the respective articles except for 1 patient, and the median recorded survival was noted to be 28.5 months. The documented survival rate postliver transplant for UESL was 96%.

From our review, a standardized chemotherapeutic regimen was not used universally for UESL.

In conclusion, based on the available data, and the very positive results therein, liver transplantation is a practical and justifiable use of a scarce resource as a treatment option for locally unresectable, undifferentiated embryonal cell sarcoma. The authors propose (accepting existence of different proposals) neoadjuvant therapy before curative resection, and if not achievable, then liver transplantation followed by adjuvant chemotherapy is an option for suitable candidates.” For recurrent tumors after surgical resection, adjuvant therapy with salvage liver transplantation is an option.

## REFERENCES

- Plant AS, Busuttill RW, Rana A, et al. A single-institution retrospective cases series of childhood undifferentiated embryonal liver sarcoma (UELS): success of combined therapy and the use of orthotopic liver transplant. *J Pediatr Hematol Oncol*. 2013;35:451–455.
- Techavichit P, Masand PM, Himes RW, et al. Undifferentiated embryonal sarcoma of the liver (UESL): a single-center experience and review of the literature. *J Pediatr Hematol Oncol*. 2016;38:261–268.
- Walther A, Geller J, Coots A, et al. Multimodal therapy including liver transplantation for hepatic undifferentiated embryonal sarcoma. *Liver Transpl*. 2014;20:191–199.
- Dhanasekaran R, Hemming A, Salazar E, et al. Rare case of adult undifferentiated (embryonal) sarcoma of the liver treated with liver transplantation: excellent long-term survival. *Case Reports Hepatol*. 2012;2012:519741.
- Walterhouse DO, Cohn SL, eds. *Diagnostic and Therapeutic Advances in Pediatric Oncology*. Kluwer Academic Publishers; 1997.
- Aronson DC, Meyers RL. Malignant tumors of the liver in children. *Semin Pediatr Surg*. 2016;25:265–275.
- Stocker JT, Ishak KG. Undifferentiated (embryonal) sarcoma of the liver: report of 31 cases. *Cancer*. 1978;42:336–348.
- Shi Y, Rojas Y, Zhang W, et al. Characteristics and outcomes in children with undifferentiated embryonal sarcoma of the liver: a report from the National Cancer Database. *Pediatr Blood Cancer*. 2017;64:e26272.
- Briscoe S. A review of the reporting of web searching to identify studies for cochrane systematic reviews. *Res Synth Methods*. 2018;9:89–99.
- Moher D, Liberati A, Tetzlaff J, et al; PRISMA Group. Preferred reporting items for systematic reviews and meta-analyses: the PRISMA statement. *BMJ*. 2009;339:b2535.
- Gall C, Brahmi FA. Retrieval comparison of EndNote to search MEDLINE (Ovid and PubMed) versus searching them directly. *Med Ref Serv Q*. 2004;23:25–32.
- Wallace BC, Kuiper J, Sharma A, et al. Extracting PICO sentences from clinical trial reports using supervised distant supervision. *J Mach Learn Res*. 2016;17:132.
- Castrillon GA, Sepúlveda E, Yezpe NL, et al. Hepatic transplantation in a child with giant multicystic tumor: pathological and imaging findings. *Pediatr Transplant*. 2010;14:e58–e61.
- Khan ZH, Ilyas K, Khan HH, et al. Unresectable undifferentiated embryonal sarcoma of the liver in an adult male treated with chemotherapy and orthotopic liver transplantation. *Cureus*. 2017;9:e1759.
- Okajima H, Ohya Y, Lee KJ, et al. Management of undifferentiated sarcoma of the liver including living donor liver transplantation as a backup procedure. *J Pediatr Surg*. 2009;44:e33–e38.
- MacKinlay GA, Pritchard J. A common language for childhood liver tumors. *Pediatr Surg Int*. 1992;7:325–326.
- Ismail H, Dembowska-Bagińska B, Broniszczak D, et al. Treatment of undifferentiated embryonal sarcoma of the liver in children—single center experience. *J Pediatr Surg*. 2013;48:2202–2206.
- Chen LE, Shepherd RW, Nadler ML, et al. Liver transplantation and chemotherapy in children with unresectable primary hepatic malignancies: development of a management algorithm. *J Pediatr Gastroenterol Nutr*. 2006;43:487–493.
- Dower NA, Smith LJ, Lees G, et al. Experience with aggressive therapy in three children with unresectable malignant liver tumors. *Med Pediatr Oncol*. 2000;34:132–135.