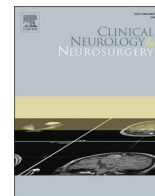




Since January 2020 Elsevier has created a COVID-19 resource centre with free information in English and Mandarin on the novel coronavirus COVID-19. The COVID-19 resource centre is hosted on Elsevier Connect, the company's public news and information website.

Elsevier hereby grants permission to make all its COVID-19-related research that is available on the COVID-19 resource centre - including this research content - immediately available in PubMed Central and other publicly funded repositories, such as the WHO COVID database with rights for unrestricted research re-use and analyses in any form or by any means with acknowledgement of the original source. These permissions are granted for free by Elsevier for as long as the COVID-19 resource centre remains active.



SARS-CoV-2/COVID-19 in multiple sclerosis patients receiving disease-modifying therapy

Monika Adamczyk-Sowa^a, Hubert Mado^{a,*}, Katarzyna Kubicka-Bączyk^a, Jerzy Jaroszewicz^b, Barbara Sobala-Szczygieł^b, Wojciech Bartman^a, Paweł Sowa^c

^a Department of Neurology, Faculty of Medical Sciences in Zabrze, Medical University of Silesia in Katowice, Poland

^b Department of Infectious Diseases and Hepatology, Medical University of Silesia, Katowice, Poland

^c Department of Otorhinolaryngology and Oncological Laryngology, Faculty of Medical Sciences in Zabrze, Medical University of Silesia in Katowice, Poland

ARTICLE INFO

Keywords:

COVID-19
Disease-modifying therapy
Multiple sclerosis
MS
SARS-CoV-2

ABSTRACT

At the end of 2019, the COVID-19 pandemic began, which at the time of writing continues to be a serious problem for many areas of medicine, including neurology. Since patients with multiple sclerosis (MS) often exhibit motor disability and receive disease-modifying therapy (DMT), which has an immunosuppressive effect, it is plausible that this will affect the susceptibility of MS patients to COVID-19, as well as the course of this disease. However, current data indicate that the use of DMT does not cause negative prognosis in COVID-19 sufferers, but the motor disability progression associated with MS does. In this study, we present the case reports of 4 patients with relapsing-remitting MS, who developed COVID-19, and despite the use of DMT the course of the disease was mild. Two patients were treated with dimethyl fumarate, one with Interferon β 1b and one with glatiramer acetate. One of the patients using dimethyl fumarate had lymphopenia. All patients had symptoms of COVID-19 from the nervous system, the most frequent being headache, which occurred in all patients. The aim of this article is to present a case series of four patients with MS and COVID-19, and to discuss the available literature on COVID-19 in patients with MS, with particular consideration of the impact of DMT.

1. Introduction

In December 2019, an epidemic of Coronavirus Disease 2019 (COVID-19), caused by severe acute respiratory coronavirus 2 syndrome (SARS-CoV-2), broke out in Wuhan, China. The disease spread rapidly all over the world, and as a result, on 11 March 2020, the COVID-19 epidemic was declared a global pandemic by the World Health Organization (WHO) [1–3]. SARS-CoV-2 infection can be asymptomatic or symptomatic with varying degrees of severity – from a mild cold to severe pneumonia. The prognosis of COVID-19 also varies from full recovery to acute respiratory failure and death [4,5]. Some patients have neurological symptoms: headaches and dizziness, olfactory and taste disorders, quantitative and qualitative impairment of consciousness, or symptoms of polyneuropathy or muscle injury. There are reported cases of acute vascular events, meningitis and encephalitis, acute transverse myelitis, and epileptic seizures. In addition, it should be noted that sometimes neurological symptoms may precede typical symptoms such as fever and coughing, but may also occur after the cure of a pulmonary

infection, which is particularly relevant for olfactory and taste disorders [6–9]. The elderly are more vulnerable to a severe course of the disease, complications, and death during SARS-CoV-2 infection, especially in case of comorbidities such as cardiovascular diseases, arterial hypertension, diabetes mellitus, or chronic obstructive pulmonary disease [4]. According to the current state of knowledge, autoimmune diseases, including multiple sclerosis (MS), are not commonly considered to be conducive to SARS-CoV-2 infection. However, it should be remembered that in contrast to the general population, the course of COVID-19 in patients with MS is modified by many factors. MS is a chronic disease accompanied by motor insufficiency, generally an increased susceptibility to infection, and an additional factor is the modification of the immune response by disease-modifying therapy (DMT), i.e., immunomodulating and immunosuppressive drugs. Of particular concern may be those DMTs that can lead to lymphopenia and a reduction in the number of B lymphocytes, such as alemtuzumab and cladribine, which could possibly lead to a higher risk of SARS-CoV-2 infection, as well as a more severe course of the disease. Currently, there is intensive collection

* Corresponding author at: Department of Neurology, Faculty of Medical Sciences in Zabrze, Medical University of Silesia in Katowice, 3 Maja Street 13/15, 41-800, Zabrze, Poland.

E-mail address: hubert.mado@med.sum.edu.pl (H. Mado).

<https://doi.org/10.1016/j.clineuro.2020.106451>

Received 23 November 2020; Received in revised form 17 December 2020; Accepted 22 December 2020

Available online 29 December 2020

0303-8467/© 2020 Elsevier B.V. All rights reserved.

of data on MS patients diagnosed with COVID-19 in order to draw clearer and more convincing conclusions [10–15].

2. Description of the examined group

We present the cases of four patients with the relapsing-remitting form of MS treated with DMT, residents of the Silesian province, who developed the COVID-19 infection in the period from March to May 2020. The diagnosis of SARS-CoV-2 infection was based on the typical symptoms of infection (cough, fever, weakness, osteoarticular pain) (Table 1) associated with contact with persons with confirmed COVID-19 (100 % of cases). All patients were tested for SARS-CoV-2 with positive results. The patients were women (100 %), who on average: were 42 years old, had the disease for 6 years, and had a degree of motor disability of 4.1 points, according to the EDSS scale. Only one patient was not affected by accompanying diseases. In the history, two patients had thyroid diseases, one overweight with lower limb thrombosis. All patients in the described group had COVID-19 symptoms from the nervous system; headaches occurred in 4 patients and dizziness in 2. Neurological symptoms were preceded for 1–2 days by symptoms of airway infections. Two people complained about olfactory and taste disorders, in one the symptoms occurred on the first day of the disease, whilst in the second and third, the disorders lasted two days. One of the patients had attention deficit disorder, which persisted only during the infection. One patient reported paraesthesias of the left upper limb, which appeared as the body temperature increased, lasted several hours, and disappeared spontaneously; this was interpreted as a pseudo-relapse. The duration of immunomodulatory treatment in the described group was 3 years on average. One of the patients had moderate lymphopenia ($0.86 \times 10^3/\mu\text{l}$). DMT therapy was stopped in two patients during COVID-19 infection. The average duration of infection was 9 days, and none of the patients required hospitalization and specialist treatment. In this group, there were no disease relapses and no progression of motor disability on the EDSS scale. One patient had persistent lymphopenia ($0.82 \times 10^3/\mu\text{l}$). Contrast magnetic resonance imaging (MRI) of the brain after infection did not show the progression of demyelinating lesions and signs of disease activity. Visual evoked potentials (VEP) in all cases showed prolonged latency of P-100 waves. The results of brainstem auditory evoked potentials (BAEP), nerve conduction study (NCS) and colour-coded Duplex Doppler (CDD) of extracranial vessels in all cases were normal. No seizure-type lesions were recorded in electroencephalography (EEG). Through psychological

consultations, increased anxiety rates were noted in 3 out of 4 subjects (Table 2).

3. Discussion

The course of COVID-19 infection is mild in most patients [16,17]. Despite the published case reports, both the risk of infection and the course of COVID-19 in patients with MS are still unclear [15,18–36]. It is known that patients with MS are generally more susceptible to infections [11,37], especially those with a higher degree of disability or serious comorbidities. On the other hand, existing reports indicate that the prevalence of COVID-19 in the MS population is similar to the general population [38]. The diagnosis of COVID-19 in all the presented cases was based on clinical symptoms and was confirmed by positive SARS-CoV-2 tests. Some of the case reports of patients with MS in the literature did not contain confirmation in virological tests, rather were based on clinical symptoms alone. Among the described cases, as well as in all our patients, the infection was most often caused by close contact with a confirmed case [39]. Our observations of patients with MS showed that the course of SARS-CoV-2 infection in all patients was mild, and symptoms typical of upper respiratory tract infections, such as osteoarticular pain and elevated body temperature, were present. Patients did not require any specialist treatment or hospitalization. Similar observations were made by Maghzi et al. and Mantero et al., who described groups of patients with MS, in whom the infection was also self-limiting. Patients from the Province of Lecco, in the Lombardy region of Italy, were of similar age, and with a comparable degree of motor disability according to the EDSS scale [40,41], to those in our study. It is also worth noting that in the report of Sormani et al., 222 out of 232 patients with MS (96 %) had benign COVID-19 [34]. The mild course of the infection was also described by Suwanwongse et al. in a young patient with relapsing-remitting MS, who nevertheless required hospitalization for pneumonia [18]. Similarly, Montero-Escribano et al. presented cases which, despite the mild course of the infection, required hospital treatment [19]. It is worth noting that in some cases the course of infection was mild or moderate, despite the occurrence of comorbidities other than MS [27]. There are also known descriptions of severe and critical courses, which in the study of Sormani et al. constituted 2 and 3% respectively, and single fatalities were reported [17,22,31,34]. In patients with SARS-CoV-2 infection, in addition to symptoms typical of respiratory tract infections, symptoms from the nervous system are also observed. More than 36 % of hospitalised COVID-19 patients in

Table 1
Clinical characteristics of patients.

Patient	1	2	3	4
Age (years)	30	38	41	57
Sex	Female	Female	Female	Female
MS type	RRSM	RRSM	RRSM	RRSM
Duration of MS disease (years)	1	1	14	6
EDSS	4.0	3.5	4.5	4.5
Applied DMT	Dimethyl fumarate	Dimethyl fumarate	Interferon β 1b	Glatiramer acetate
Lymphocyte count [$10^3/\mu\text{l}$] (N: 1–3.3)	0.86	1.1	2.5	2.75
Comorbidities	Hypothyroidism, lower limb varicose veins, overweight (BMI 29.06)	None	Hashimoto's thyroiditis	Dyslipidaemia, migraine headaches
PCR-confirmed COVID-19 infection	Yes	Yes	Yes	Yes
Symptoms and duration of COVID-19	Osteoarticular pains, fever up to 38 °C, diarrhoea, general weakness, headaches, paraesthesias of the left upper limb, 7 days	Headaches and dizziness, rhinitis, fever up to 38 °C, olfactory and taste disorders, attention deficit disorder, 10 days	Osteoarticular pains, fever up to 38 °C, headaches, olfactory and taste disorders, 6 days	Osteoarticular pains, headaches and dizziness, coughing, fever > 38 °C 12 days
DMT treatment during COVID-19 infection	Yes	No	Yes	No

MS – multiple sclerosis; RRSM – relapsing-remitting MS; EDSS – Expanded Disability Status Scale; DMT – disease modifying therapies; PCR – polymerase chain reaction; COVID-19 – Coronavirus Disease 2019.

Table 2
Tests performed after SARS-CoV-2 infection.

Patient	1	2	3	4
EDSS	4.0	3.5	4.5	4.5
Lymphocyte count [10 ³ /μl] (N: 1–3.3)	0.82	1.47	2.25	2.82
Neutrophil count [10 ³ /μl] (N: 1.6–6)	4.58	4.18	6.39	3.08
WBC [10 ³ /μl] (N: 4–10.5)	6.33	6.22	10.08	5.42
Monocyte count [10 ³ /μl] (N: 0.15–0.6)	0.55	0.46	0.7	0.33
Eosinophil count [10 ³ /μl] (N: 0.2–0.5)	0.26	0.08	0.1	0.24
Basophil count [10 ³ /μl] (N: 0.01–0.1)	0.01	0.01	0.01	0.02
HCT [%] (N: 37–47)	38.9	37.6	37.1	40.7
RBC [10 ³ /μl] (N: 4.2–5.4)	4.42	4.46	4.39	4.54
Hb [g/dL] (N: 12.5–16)	13.2	12.5	12.4	14.3
MCV [fL] (N: 78–100)	88	84.3	84.5	89.6
MCH [pg] (N: 27–31)	29.9	28	28.2	31.5
MCHC [g/dL] (N: 32–36)	33.9	33.2	33.4	35.1
RDW-CV [%] (N: 11.5–14.5)	13	12.9	13.3	12.3
RDW-SD [fL]	42.1	39	41.1	–
PLT [10 ³ /μl] (N: 150–450)	244	250	356	229
MPV [fL] (N: 6–9.5)	10.4	11.3	10	10.6
PDW [fL] (N: 9.8–16.2)	11.6	13.5	10.8	–
P-LCR [%] (N: 19.1–47)	27	35.6	24.3	29.2
PCT [%] (N: 0.15–0.5)	0.25	0.28	0.35	–
CRP [mg/L] (N: 0–5)	1.38	–	9.01	–
IG [10 ³ /μl] (N: 0–0.015)	0.01	0.02	0.03	–
NRBC [10 ³ /μl] (N: 0–0.03)	0	0	0	–
MICROR [%] (N: 0.14–5.79)	1.7	3.4	2.9	–
MACROR [%] (N: 3.3–5.56)	3.5	3.9	3.9	–
ALT [U/L] (N: 0–41)	14.8	24.1	15	19
AST [U/L] (N: 0–40)	18.4	21.5	13.9	16
Total bilirubin [μmol/L] (N: 5–21)	–	–	<2.5	8.9
Direct bilirubin [μmol/L] (N: 0–3.4)	4.7	3.2	–	–
Creatine kinase [U/ L] (N: 10–200)	74	–	77	–
Serum creatinine [μmol/L] (N: 44–80)	53	50	55	66
GFR [ml/min/1.73 m ²]	125.73	–	–	80
Blood sodium [mmol/L] (N: 136–146)	–	–	–	139
	–	–	–	4.3

(continued on next page)

Table 2 (continued)

Patient	1	2	3	4
Blood potassium [mmol/L] (N: 3.5–5)				
TSH [μ U/mL] (N: 0.27–4.2)	–	2.54	0.839	1.160
General urine test (only abnormal results)	No abnormal results	–	–	pH = 5; 6–8 leukocytes per high-power field; 2–4 erythrocytes per high-power field
Head MRI with contrast	Number and size of demyelination lesions with an image similar to the previous examination, without activity signs	Number and size of demyelination lesions with an image similar to the previous examination, without activity signs	Number and size of demyelination lesions with an image similar to the previous examination, without activity signs	Number and size of demyelination lesions with an image similar to the previous examination, without activity signs
VEP	Abnormal	Abnormal	Abnormal	Abnormal
BAEP	Normal	Normal	normal	Normal
NCS	Normal	Normal	Normal	normal
EEG	Record with focal lesions bilaterally in the parasagittal region	Normal record	Normal record	Record with focal lesions in the left frontotemporal region
CDD of extracranial vessels	Normal	Normal	Normal	Normal
Psychological test	Increased anxiety rate	Increased anxiety rate	Normal emotional state	Increased anxiety rate

EDSS – Expanded Disability Status Scale; N – normal result; ; WBC – white blood cells count; HCT – haematocrit; RBC – red blood cells count; Hb – haemoglobin; MCV – mean corpuscular volume; MCH – mean corpuscular haemoglobin; MCHC – mean corpuscular haemoglobin concentration; PLT – platelets count; MPV – mean platelet volume; PDW – platelet distribution width; P-LCR – platelet large cell ratio; PCT – procalcitonin; CRP – C-reactive protein; IG – immature granulocyte count; NRBC – nucleated red blood cells; MICROR – microcytes (micro red blood cells); MACROR – macrocytes (macro red blood cells); ALT – alanine transaminase; AST – aspartate transaminase; LDH – Lactate dehydrogenase; TSH – thyroid-stimulating hormone; MRI – magnetic resonance imaging; VEP – visual evoked potential; BAEP – brainstem auditory evoked potential; NCS – nerve conduction study; EEG – electroencephalography; CDD – Color-Coded Duplex Doppler. Deviations from the normal results are bold.

Wuhan, China, developed neurological symptoms, mostly related to central manifestations (dizziness and headaches). In a smaller percentage of cases, symptoms from the peripheral nervous system (most often olfactory and taste disorders) were reported [42]. In all our patients in the course of COVID-19, neurological symptoms from the CNS and peripheral nervous system occurred, which disappeared spontaneously. Mantero et al. also described similar symptoms, which occurred in 75 % of patients [40]. A recently published Spanish study, investigating a group of 60 patients with MS and COVID-19, coexisting neurological symptoms were also frequently observed [19]. In patients presented by Gemcioglu, Novi, Bollo or Suwanwongse [18,21,43,44] there were no neurological symptoms in single cases. In the available literature there are no reports of increased frequency of MS relapses in the course of COVID-19, which is in line with the observations of our patients. Due to the well-known suppressing effect on the immune system of DMT, it seems puzzling how these drugs affect the risk of SARS-CoV-2 infection, as well as its course in patients with MS. Some DMTs, i.e., interferon- β and glatiramer acetate, have an immunomodulating effect, although they do not increase the risk of systemic infections. However, other drugs used to treat MS have an immunosuppressive effect, which is associated with alterations in the number, proliferation, trafficking and function of lymphocytes, leading to an increased risk of infections, including viral and respiratory infections [11–13,45]. In our own observations, both in patients who did not continue their treatment and those whose treatment was continuous, the course of SARS-CoV-2 infection was similar. Mild symptoms of infection also occurred in a patient with moderate lymphopenia while using dimethyl fumarate, so similarly to Loonstra et al., we did not find any association between low lymphocyte levels and severity of SARS-CoV-2 infection [31]. Dersch et al. also described a case of a patient in whom the course of COVID-19 was moderate, even despite severe lymphopenia induced by cladribine [25]. Similar observations were also made by Maghzi et al. and Mantero et al., who described groups of patients with mild COVID-19 who received ongoing DMT, which is in line with other case descriptions in the literature, and the results of the Italian pilot phase of investigation of COVID-19 in patients with MS [24,28–34,36,39,40]. In March and April 2020, a group of experts from the Section of MS and Neuroimmunology of the Polish Neurological Society (PTN) developed a position on the

management of patients with MS using treatment affecting the natural course of the disease in case of the COVID-19 pandemic. The recommendations were based on the currently available knowledge and understanding of the disease, and are constantly being updated [46,47]. In two of the patients we described in March 2020, for the period of SARS-CoV-2 infection, the treatment of MS was stopped, based on the then binding guidelines of the expert group of the Section of MS and Neuroimmunology of the PTN. Further patients continued to use DMT, which did not affect the severity of COVID-19. At the end of June 2020, a study involving 347 patients with MS with SARS-CoV-2 infection was published [35]. It showed that DMT did not affect the severity of COVID-19, although it should be noted that cladribine and alemtuzumab were not commonly used in this cohort. This study also showed that disability related to MS, as well as age and obesity, were independent risk factors for the severity of SARS-CoV-2 infection in patients with MS. However, there is some concern that DMT, which causes lymphopenia and depletion of the B lymphocyte count (e.g., cladribine, alemtuzumab, ocrelizumab, rituximab, and others), may contribute to the morbidity and more severe course of COVID-19, which should suggest an individual approach to the use of individual drugs in individual patients [15, 29,45,48]. Nevertheless, in view of the reassuring data and recommendations to date, it appears that the majority of patients who have been treated with DMT should continue this therapy, and that an adequate DMT should be initiated in the majority of patients who have just been diagnosed with MS [21,34,35,49]. Due to the lack of information on the consequences that may occur after SARS-CoV-2 infection in patients with MS [10], we have performed both neurological and additional control tests in our patients. In the neurological examination we did not observe the progression of the neurological deficit and the state of motor disability on the EDSS scale. In the performed neuroimaging study, we did not describe the progression of demyelinating changes. In June of this year, there were published the results of a retrospective, multi-centre study of French patients with COVID-19 and neurological symptoms, in whom brain MRI was performed. In MRI the most frequent findings were: intracerebral haemorrhages (54 %), involvement of medial temporal lobe (43 %), hyperintensive lesions in the white matter (30 %), microhaemorrhages in the white matter (24 %) [50]. Similarly, in a multicentre, randomised study conducted in Italy,

MRI was dominated by acute ischaemic strokes and intracerebral haemorrhages, and 29 % of patients did not have an internal cardio-vascular risk profile. According to Mahammedi's observations in patients with COVID-19, brain MRI also shows posterior reversible encephalopathy syndrome (PRES), hypoxic ischaemic encephalopathy, cerebral venous thrombosis, Guillian-Barre syndrome, and Miller-Fisher syndrome [51]. Initially, ischaemic and haemorrhagic complications were reported in COVID-19 patients [52,53]. At present, there are also described the uneven demyelinating lesions in the brain and spinal cord, which are considered complications of SARS-CoV-2 infection [54,55]. It is also worth noting that Palao et al. presented the first case of MS shortly after possible COVID-19 infection (PCR analysis was negative, although the authors assumed an infection history based on positive IgM and IgG in immunological tests, clinical symptoms, and a shared place of residence with a person with a confirmed infection). In this publication, the authors considered the cause-related relationship between the infection and the onset of MS and thus suggested that SARS-CoV-2 may, like some other viruses, play a role in causing demyelinating diseases [56]. There are currently no reports of lesions in neuroimaging studies in patients with MS and COVID-19 in the available literature. In the NCS performed in our study, no motor or sensory conduction disorders were found. Evoked potential abnormalities were reported in the VEP with values similar to those prior to COVID-19 infection. In the CDD examination of extracranial vessels, no blood flow abnormalities were observed, which are described in SARS-CoV-2 infected patients in computed tomography (CT) angiography and MR angiography [57,58]. EEG records in 50 % of the described subjects were normal, while in the remaining cases no seizure changes were found. There are known cases of epileptic seizures in the course of SARS-CoV-2 infection (including status epilepticus) [59–62]. EEG records have described the slowing of basic activities, but it is worth adding that the authors of some publications suggest the possibility of a specific pattern of EEG recording in patients with COVID-19 [63–65]. Moreover, neurocognitive dysfunction and psychiatric symptoms have been described in patients with COVID-19 [66,67]. Also, in patients with MS and SARS-CoV-2 infection, cases of changed mental state have been reported [22]. There are indications that the very awareness of the prevailing COVID-19 pandemic, even without the infection, may have a negative impact on stress and anxiety levels, as well as cognitive and neuropsychiatric functions of patients with MS, and SARS-CoV-2 infection could therefore cause even greater anxiety in these patients than in the general population, which may be related to patients' knowledge of the therapies used and their impact on the immune system [68]. A psychological assessment was carried out on our patients, in which the majority of subjects (75 %) showed an increased rate of anxiety, but no neurocognitive dysfunction was observed.

4. Conclusions

In view of the current COVID-19 pandemic and the lack of information on the consequences of SARS-CoV-2 infection in patients with MS, it is necessary to constantly monitor the course of the infection itself and to perform follow-up examinations upon recovery in order to assess possible complications.

CRedit (contributor roles taxonomy) author statement

Monika Adamczyk-Sowa: conceptualization, review of literature, review of the manuscript in terms of intellectual content, approval of the final manuscript.

Hubert Mado: review of literature, analysis of results, writing - original draft, writing - review & editing, corresponding author.

Katarzyna Kubicka-Bączyk: evaluation and interpretation of the results, review of a part of the literature, participation in the writing – original draft.

Jerzy Jaroszewicz: participation in the conceptualization and planning of the project, participation in the analysis and interpretation of the

results.

Barbara Sobala-Szczygiel: participation in the analysis and interpretation of results.

Wojciech Bartman: review of a part of the literature, participation in the writing – original draft.

Paweł Sowa: participation in the conceptualization and planning of the project, participation in the analysis and interpretation of the results, review of the manuscript in terms of intellectual content.

Funding

This research received no grant from any funding agency in the public, commercial, or not-for-profit sectors.

Declaration of Competing Interest

The authors declare that there is no conflict of interest.

References

- [1] S. Perlman, Another Decade, Another Coronavirus, *N. Engl. J. Med.* 382 (8) (2020) 760–762, <https://doi.org/10.1056/NEJMe2001126>. Feb 20 Epub 2020 Jan 24. PMID: 31978944; PMCID: PMC7121143.
- [2] P. Zhou, X.L. Yang, X.G. Wang, B. Hu, L. Zhang, W. Zhang, H.R. Si, Y. Zhu, B. Li, C. L. Huang, H.D. Chen, J. Chen, Y. Luo, H. Guo, R.D. Jiang, M.Q. Liu, Y. Chen, X. R. Shen, X.G. Wang, X.S. Zheng, K. Zhao, Q.J. Chen, F. Deng, L.L. Liu, B. Yan, F. X. Zhan, Y.Y. Wang, G.F. Xiao, Z.L. Shi, A pneumonia outbreak associated with a new coronavirus of probable bat origin, *Nature*. 579 (March 7798) (2020) 270–273, <https://doi.org/10.1038/s41586-020-2012-7>. Epub 2020 Feb 3. PMID: 32015507; PMCID: PMC7095418.
- [3] E. Mahase, Covid-19: WHO declares pandemic because of “alarming levels” of spread, severity, and inaction, *BMJ*. 12 (March 368) (2020), <https://doi.org/10.1136/bmj.m1036> PMID: 32165426.
- [4] Z. Wu, J.M. McGoogan, Characteristics of and important lessons from the coronavirus disease 2019 (COVID-19) outbreak in China: summary of a report of 72 314 cases from the chinese center for disease control and prevention, *JAMA* 323 (13) (2020) 1239–1242, <https://doi.org/10.1001/jama.2020.2648>. Apr 7 PMID: 32091533.
- [5] C. Huang, Y. Wang, X. Li, L. Ren, J. Zhao, Y. Hu, L. Zhang, G. Fan, J. Xu, X. Gu, Z. Cheng, T. Yu, J. Xia, Y. Wei, W. Wu, X. Xie, W. Yin, H. Li, M. Liu, Y. Xiao, H. Gao, L. Guo, J. Xie, G. Wang, R. Jiang, Z. Gao, Q. Jin, J. Wang, B. Cao, Clinical features of patients infected with 2019 novel coronavirus in Wuhan, China, *Lancet* 395 (10223) (2020) 497–506, [https://doi.org/10.1016/S0140-6736\(20\)30183-5](https://doi.org/10.1016/S0140-6736(20)30183-5). Feb 15 Epub 2020 Jan 24. Erratum in: *Lancet*. 2020 Jan 30; PMID: 31986264; PMCID: PMC7159299.
- [6] M. Adamczyk-Sowa, N. Niedziela, K. Kubicka-Bączyk, K. Wierzbicki, J. Jaroszewicz, P. Sowa, Neurological symptoms as a clinical manifestation of COVID-19: implications for internists, *Pol Arch Intern Med.* (August 21) (2020), <https://doi.org/10.20452/pamw.15575>. Epub ahead of print. PMID: 32820884.
- [7] R. Bridwell, B. Long, M. Gottlieb, Neurologic complications of COVID-19, *Am. J. Emerg. Med.* 38 (July 7) (2020) 1549, <https://doi.org/10.1016/j.ajem.2020.05.024>, e3-1549.e7 Epub 2020 May 16. PMID: 32425321; PMCID: PMC7229718.
- [8] P. Gklinos, Neurological manifestations of COVID-19: a review of what we know so far, *J. Neurol.* 267 (September 9) (2020) 2485–2489, <https://doi.org/10.1007/s00415-020-09939-5>. Epub 2020 May 26. PMID: 32458197; PMCID: PMC7250266.
- [9] D. Orsucci, E.C. Jenco, G. Nocita, A. Napolitano, M. Vista, Neurological features of COVID-19 and their treatment: a review, *Drugs Context* 11 (June 9) (2020) doi: 10.7573/dic.2020-5-1. 2020-5-1 PMID: 32587625; PMCID: PMC7295105.
- [10] J. Mares, H.P. Hartung, Multiple sclerosis and COVID-19, *Biomed. Pap. Med. Fac. Univ. Palacky Olomouc Czech.* 164 (September 3) (2020) 217–225, <https://doi.org/10.5507/bp.2020.033>. Epub 2020 Jul 17. PMID: 32686774.
- [11] G. Luna, P. Alping, J. Burman, K. Fink, A. Fogdell-Hahn, M. Gunnarsson, J. Hillert, A. Langer-Gould, J. Lycke, P. Nilsson, J. Salzer, A. Svenningsson, M. Vrethem, T. Olsson, F. Piehl, Frisell T. Infection risks among patients with multiple sclerosis treated with fingolimod, Natalizumab, rituximab, and injectable therapies, *JAMA Neurol.* 77 (2) (2020) 184–191, <https://doi.org/10.1001/jamaneurol.2019.3365>. Feb 1 PMID: 31589278; PMCID: PMC6784753.
- [12] R. Persson, S. Lee, M. Ulcickas Yood, C.M. Wagner Usn Mc, N. Minton, S. Niemcryk, A. Lindholm, A.M. Evans, S.S. Jick, Infections in patients diagnosed with multiple sclerosis: a multi-database study, *Mult. Scler. Relat. Disord.* 41 (June) (2020), 101982, <https://doi.org/10.1016/j.msard.2020.101982>. Epub 2020 Feb 4. PMID: 32070858.
- [13] M.D. Willis, N.P. Robertson, Multiple sclerosis and the risk of infection: considerations in the threat of the novel coronavirus, COVID-19/SARS-CoV-2, *J. Neurol.* 267 (May 5) (2020) 1567–1569, <https://doi.org/10.1007/s00415-020-09822-3>. PMID: 32303837; PMCID: PMC7163169.
- [14] H. Yavarpour-Bali, M. Ghasemi-Kasman, Update on neurological manifestations of COVID-19, *Life Sci.* 15 (September 257) (2020), 118063, <https://doi.org/10.1016/j.lfs.2020.118063>. Epub 2020 Jul 9. PMID: 32652139; PMCID: PMC7346808.

- [15] F. Safavi, B. Nourbakhsh, A.R. Azimi, B-cell depleting therapies may affect susceptibility to acute respiratory illness among patients with multiple sclerosis during the early COVID-19 epidemic in Iran, *Mult. Scler. Relat. Disord.* 43 (August) (2020), 102195, <https://doi.org/10.1016/j.msard.2020.102195>. Epub 2020 May 13. PMID: 32460086; PMCID: PMC7219389.
- [16] W.J. Guan, Z.Y. Ni, Y. Hu, W.H. Liang, C.Q. Ou, J.X. He, L. Liu, H. Shan, C.L. Lei, D. S.C. Hui, B. Du, L.J. Li, G. Zeng, K.Y. Yuen, R.C. Chen, C.L. Tang, T. Wang, P. Y. Chen, J. Xiang, S.Y. Li, J.L. Wang, Z.J. Liang, Y.X. Peng, L. Wei, Y. Liu, Y.H. Hu, P. Peng, J.L.M. Wang, J.Y. Liu, Z. Chen, G. Li, Z.J. Zheng, S.Q. Qiu, J. Luo, C.J. Ye, S.Y. Zhu, N.S. Zhong, China Medical Treatment Expert Group for Covid-19. Clinical Characteristics of Coronavirus Disease 2019 in China, *N. Engl. J. Med.* 382 (18) (2020) 1708–1720, <https://doi.org/10.1056/NEJMoa2002032>. Apr 30Epub 2020 Feb 28. PMID: 32109013; PMCID: PMC7092819.
- [17] F. Zhou, T. Yu, R. Du, G. Fan, Y. Liu, Z. Liu, J. Xiang, Y. Wang, B. Song, X. Gu, L. Guan, Y. Wei, H. Li, X. Wu, J. Xu, S. Tu, Y. Zhang, H. Chen, B. Cao, Clinical course and risk factors for mortality of adult inpatients with COVID-19 in Wuhan, China: a retrospective cohort study, *Lancet.* 395 (10229) (2020) 1054–1062, [https://doi.org/10.1016/S0140-6736\(20\)30566-3](https://doi.org/10.1016/S0140-6736(20)30566-3). Epub 2020 Mar 11. Erratum in: *Lancet.* 2020 Mar 28;395(10229):1038. Erratum in: *Lancet.* 2020 Mar 28;395(10229): Mar 28. PMID: 32171076; PMCID: PMC7270627.
- [18] C. Foerch, L. Friedauer, B. Bauer, T. Wolf, Eh. Adam, Severe COVID-19 infection in a patient with multiple sclerosis treated with fingolimod, *Mult. Scler. Relat. Disord.* 42 (July) (2020), 102180, <https://doi.org/10.1016/j.msard.2020.102180>. Epub 2020 May 6. PMID: 32408155; PMCID: PMC7202802.
- [19] K. Suwanwongse, N. Shabarek, Benign course of COVID-19 in a multiple sclerosis patient treated with Ocrelizumab, *Mult. Scler. Relat. Disord.* 42 (July) (2020), 102201, <https://doi.org/10.1016/j.msard.2020.102201>. Epub 2020 May 15. PMID: 32480327; PMCID: PMC7227515.
- [20] P. Montero-Escribano, J. Matias-Guiu, P. Gómez-Iglesias, J. Porta-Etessam, V. Pytel, J.A. Matias-Guiu, Anti-CD20 and COVID-19 in multiple sclerosis and related disorders: a case series of 60 patients from Madrid, Spain, *Mult. Scler. Relat. Disord.* 42 (July) (2020), 102185, <https://doi.org/10.1016/j.msard.2020.102185>. Epub 2020 May 7. PMID: 32408147; PMCID: PMC7204643.
- [21] G. Novi, M. Mikulska, F. Briano, F. Toscanini, F. Tazza, A. Uccelli, M. Inglese, COVID-19 in a MS patient treated with ocrelizumab: does immunosuppression have a protective role? *Mult. Scler. Relat. Disord.* 42 (July) (2020), 102120 <https://doi.org/10.1016/j.msard.2020.102120>. Epub 2020 Apr 15. PMID: 32315980; PMCID: PMC7156942.
- [22] J.D. Bowen, J. Brink, T.R. Brown, E.B. Lucassen, K. Smoot, A. Wundes, P. Repovic, COVID-19 in MS: initial observations from the Pacific Northwest, *Neurol. Neuroimmunol. Neuroinflamm.* 7 (5) (2020) e783, <https://doi.org/10.1212/NXI.0000000000000783>. May 26PMID: 32457226; PMCID: PMC7286653.
- [23] M. Ghajarzadeh, O. Mirmosayyeb, M. Barzegar, N. Nehzat, S. Vaheb, V. Shaygannejad, Ah. Maghzi, Favorable outcome after COVID-19 infection in a multiple sclerosis patient initiated on ocrelizumab during the pandemic, *Mult. Scler. Relat. Disord.* 43 (August) (2020), 102222, <https://doi.org/10.1016/j.msard.2020.102222>. Epub 2020 May 23. PMID: 32464586; PMCID: PMC7245286.
- [24] M. Chiarini, S. Paghera, D. Moratto, N. Rossi, M. Giacomelli, R. Badolato, R. Capra, L. Imberti, Immunologic characterization of an immunosuppressed multiple sclerosis patient that recovered from SARS-CoV-2 infection, *J. Neuroimmunol.* (345) (2020), 577282, <https://doi.org/10.1016/j.jneuroim.2020.577282>. Aug 15Epub 2020 May 29. PMID: 32505908; PMCID: PMC7256606.
- [25] R. Dersch, T. Wehrum, S. Fährndrich, M. Engelhardt, S. Rauer, B. Berger, COVID-19 pneumonia in a multiple sclerosis patient with severe lymphopenia due to recent cladribine treatment, *Mult. Scler.* 26 (September10) (2020) 1264–1266, <https://doi.org/10.1177/1352458520943783>. Epub 2020 Aug 7. PMID: 32762488.
- [26] C. Louapre, E. Maillart, T. Roux, V. Pouchere, G. Bussone, C. Lubetzki, C. Papeix, Patients with MS treated with immunosuppressive agents: across the COVID-19 spectrum, *Rev Neurol (Paris)*. 176 (June 6) (2020) 523–525, <https://doi.org/10.1016/j.neuro.2020.04.009>. Epub 2020 Apr 27. PMID: 32362357; PMCID: PMC7184008.
- [27] M. Barzegar, O. Mirmosayyeb, N. Nehzat, R. Sarrafi, F. Khorvash, Ah Maghzi, V. Shaygannejad, COVID-19 infection in a patient with multiple sclerosis treated with fingolimod, *Neurol. Neuroimmunol. Neuroinflamm.* 7 (4) (2020) e753, <https://doi.org/10.1212/NXI.0000000000000753>. May 5PMID: 32371550; PMCID: PMC7217655.
- [28] T. Carandini, A.M. Pietroboni, L. Sacchi, M.A. De Riz, M. Pozzato, A. Arighi, G. G. Fumagalli, F. Martinelli Boneschi, D. Galimberti, E. Scarpini, Alemtuzumab infection during the COVID-19 pandemic: a mild uncomplicated infection despite intense immunosuppression, *Mult. Scler.* 26 (September 10) (2020) 1268–1269, <https://doi.org/10.1177/1352458520926459>. Epub 2020 May 28. PMID: 32463329.
- [29] V. Mantero, D. Baroncini, R. Balgera, C. Guaschino, P. Basilio, P. Annovazzi, M. Zaffaroni, A. Salmaggi, C. Cordano, Mild COVID-19 infection in a group of teriflunomide-treated patients with multiple sclerosis, *J. Neurol.* (2020) 1–2, <https://doi.org/10.1007/s00415-020-10196-9>. Aug 31Epub ahead of print. PMID: 32865629; PMCID: PMC7457441.
- [30] M. Iannetta, N. Cesta, C. Stingone, V. Malagnino, E. Teti, P. Vitale, G. De Simone, B. Rossi, L. Ansaldo, M. Compagno, I. Spalliera, A. Di Lorenzo, D. Landi, C. G. Nicoletti, G.A. Marfia, M. Andreoni, L. Sarmati, Mild clinical manifestations of SARS-CoV-2 related pneumonia in two patients with multiple sclerosis under treatment with ocrelizumab, *Mult. Scler. Relat. Disord.* (45) (2020), 102442, <https://doi.org/10.1016/j.msard.2020.102442>. Aug 4Epub ahead of print. PMID: 32777745; PMCID: PMC7399651.
- [31] F.C. Loonstra, E. Hoitsma, Z.L. van Kempen, J. Killestein, J.P. Mostert, COVID-19 in multiple sclerosis: the Dutch experience, *Mult. Scler.* 26 (September 10) (2020) 1256–1260, <https://doi.org/10.1177/1352458520942198>. Epub 2020 Jul 14. PMID: 32662742; PMCID: PMC7493197.
- [32] G. Mallucci, A. Zito, B.D. Fabbro, R. Bergamaschi, Asymptomatic SARS-CoV-2 infection in two patients with multiple sclerosis treated with fingolimod, *Mult. Scler. Relat. Disord.* (45) (2020), 102414, <https://doi.org/10.1016/j.msard.2020.102414>. July 19Epub ahead of print. PMID: 32711296; PMCID: PMC7369008.
- [33] N. Möhn, F. Saker, V. Bonda, G. Respondek, M. Bachmann, M. Stoll, M.P. Wattjes, M. Stangel, T. Skripuletz, Mild COVID-19 symptoms despite treatment with teriflunomide and high-dose methylprednisolone due to multiple sclerosis relapse, *J. Neurol.* 267 (October 10) (2020) 2803–2805, <https://doi.org/10.1007/s00415-020-09921-1>. Epub 2020 May 28. PMID: 32494855; PMCID: PMC7268187.
- [34] M.P. Sormani, Italian Study Group on COVID-19 infection in multiple sclerosis. An Italian programme for COVID-19 infection in multiple sclerosis, *Lancet Neurol.* 19 (June 6) (2020) 481–482, [https://doi.org/10.1016/S1474-4422\(20\)30147-2](https://doi.org/10.1016/S1474-4422(20)30147-2). Epub 2020 Apr 30. Erratum in: *Lancet Neurol.* 2020 May 28;; PMID: 32359409; PMCID: PMC7191287.
- [35] C. Louapre, N. Collongues, B. Stankoff, C. Giannesini, C. Papeix, C. Bensa, R. Deschamps, A. Créange, A. Wahab, J. Pelletier, O. Heinzl, P. Labauge, L. Guilloton, G. Ahle, M. Goudot, K. Bigaut, D.A. Laplaud, S. Vukusic, C. Lubetzki, J. De Sèze, Covisep investigators. Clinical Characteristics and Outcomes in Patients With Coronavirus Disease 2019 and Multiple Sclerosis, *JAMA Neurol.* 77 (9) (2020) 1–10, <https://doi.org/10.1001/jamaneuro.2020.2581>. Jun 26Epub ahead of print. PMID: 32589189; PMCID: PMC7320356.
- [36] M. De Angelis, M. Petracca, R. Lanzillo, V. Brescia Morra, M. Moccia, Mild or no COVID-19 symptoms in cladribine-treated multiple sclerosis: two cases and implications for clinical practice, *Mult. Scler. Relat. Disord.* (45) (2020), 102452, <https://doi.org/10.1016/j.msard.2020.102452>. Aug 16Epub ahead of print. PMID: 32823148; PMCID: PMC7428688.
- [37] A. Czarnowska, K. Kapica-Topczewska, O. Zajkowska, R. Świerzbńska, M. Chorąży, J. Tarasiuk, J. Zajkowska, J. Kochanowicz, A. Kulakowska, Herpesviridae seropositivity in patients with multiple sclerosis: first polish study, *Eur. Neurol.* 80 (5–6) (2018) 229–235, <https://doi.org/10.1159/000496402>. Epub 2019 Jan 18. PMID: 30661064.
- [38] V. Mantero, L. Abate, R. Balgera, P. Basilio, A. Salmaggi, C. Cordano, Assessing the susceptibility to acute respiratory illness COVID-19-related in a cohort of multiple sclerosis patients, *Mult. Scler. Relat. Disord.* (46) (2020), 102453, <https://doi.org/10.1016/j.msard.2020.102453>. Aug 19Epub ahead of print. PMID: 32835900; PMCID: PMC7434623.
- [39] J.F. Chan, S. Yuan, K.H. Kok, K.K. To, H. Chu, J. Yang, F. Xing, J. Liu, C.C. Yip, R. W. Poon, H.W. Tsoi, S.K. Lo, K.H. Chan, V.K. Poon, W.M. Chan, J.D. Ip, J.P. Cai, V. C. Cheng, H. Chen, C.K. Hui, K.Y. Yuen, A familial cluster of pneumonia associated with the 2019 novel coronavirus indicating person-to-person transmission: a study of a family cluster, *Lancet* 395 (10223) (2020) 514–523, [https://doi.org/10.1016/S0140-6736\(20\)30154-9](https://doi.org/10.1016/S0140-6736(20)30154-9). Feb 15Epub 2020 Jan 24. PMID: 31986261; PMCID: PMC7159286.
- [40] V. Mantero, L. Abate, P. Basilio, R. Balgera, A. Salmaggi, B. Nourbakhsh, C. Cordano, COVID-19 in dimethyl fumarate-treated patients with multiple sclerosis, *J. Neurol.* (2020) 1–3, <https://doi.org/10.1007/s00415-020-10015-1>. Jun 25Epub ahead of print. PMID: 32588182; PMCID: PMC7314911.
- [41] A.H. Maghzi, M.K. Houtchens, P. Preziosa, C. Ionete, B.D. Beretich, J. M. Stankiewicz, S. Tauhid, A. Cabot, I. Berriosmorales, T.H.W. Schwartz, J. A. Sloane, M.S. Freedman, M. Filippi, H.L. Weiner, R. Bakshi, COVID-19 in teriflunomide-treated patients with multiple sclerosis, *J. Neurol.* 267 (October10) (2020) 2790–2796, <https://doi.org/10.1007/s00415-020-09944-8>. Epub 2020 Jun 3. PMID: 32494856; PMCID: PMC7268971.
- [42] L. Mao, H. Jin, M. Wang, Y. Hu, S. Chen, Q. He, J. Chang, C. Hong, Y. Zhou, D. Wang, X. Miao, Y. Li, B. Hu, Neurologic Manifestations of Hospitalized Patients With Coronavirus Disease 2019 in Wuhan, China, *JAMA Neurol.* 77 (6) (2020) 683–690, <https://doi.org/10.1001/jamaneuro.2020.1127>. Jun 1PMID: 32275288; PMCID: PMC7149362.
- [43] L. Bollo, T. Guerra, D.F. Bavaro, L. Monno, A. Saracino, G. Angarano, D. Paolicelli, M. Trojano, P. Iaffaldano, Seroconversion and indolent course of COVID-19 in patients with multiple sclerosis treated with fingolimod and teriflunomide, *J. Neurol. Sci.* (416) (2020), 117011, <https://doi.org/10.1016/j.jns.2020.117011>. Jul 4Epub ahead of print. PMID: 32650143; PMCID: PMC7339938.
- [44] E. Gemcioglu, M. Davutoglu, E.E. Ozdemir, A. Erden, Are type 1 interferons treatment in Multiple Sclerosis as a potential therapy against COVID-19? *Mult. Scler. Relat. Disord.* 42 (July) (2020), 102196 <https://doi.org/10.1016/j.msard.2020.102196>. Epub 2020 May 16. PMID: 32480326; PMCID: PMC7228888.
- [45] W. Brownlee, D. Bourdette, S. Broadley, J. Killestein, O. Ciccarelli, Treating multiple sclerosis and neuromyelitis optica spectrum disorder during the COVID-19 pandemic, *Neurology.* 94 (22) (2020) 949–952, <https://doi.org/10.1212/WNL.00000000000009507>. Jun 2Epub 2020 Apr 2. PMID: 323241953.
- [46] H. Bartosik-Psujek, M. Adamczyk-Sowa, A. Kalinowska, A. Kulakowska, Stanowisko Dotyczące Leczenia Stwardnienia Rozsianego W Przypadku Ryzyka Zakazenia Koronawirusem Wywołującym COVID-19 [Internet] [cited 21 October 2020]. Mp.pl.Available from: 2020 <https://www.mp.pl/neurologia/stwardnienie-rozsiane/231795,leczenie-sm-w-przypadku-ryzyka-zakazenia-koronawirusem>.
- [47] H. Bartosik-Psujek, M. Adamczyk-Sowa, A. Kalinowska, A. Kulakowska, B. Zakrzewska-Pnievska, J. Zaborski, Stanowisko Dot. Leczenia SM W Przypadku Ryzyka Zakazenia Koronawirusem Wywołującym COVID-19 [Internet], *Ptneuro.pl*. [cited 21 October 2020]. Available from: 2020 https://ptneuro.pl/pl/o_ptn/aktua-lnosci/stanowisko_dot_leczenia_sm_w_przypadku_ryzyka_zakazenia_koronawirusem_wywołujacy_covid_192.

- [48] S. Amor, D. Baker, S.J. Khoury, K. Schmierer, G. Giovanonni, SARS-CoV-2 and multiple sclerosis: not all immune depleting DMTs are equal or bad, *Ann. Neurol.* 87 (June 6) (2020) 794–797, <https://doi.org/10.1002/ana.25770>. PMID: 32383812; PMCID: PMC7273059.
- [49] H. Abboud, A. Serra, The pressing questions in multiple sclerosis Care in the era of COVID-19, *J. Neurol. Sci.* 23 (June 416) (2020), 117005, <https://doi.org/10.1016/j.jns.2020.117005>. Epub ahead of print. PMID: 32599294; PMCID: PMC7308765.
- [50] S. Kremer, F. Lersy, J. de Sèze, J.C. Ferré, A. Maamar, B. Carsin-Nicol, O. Collange, F. Bonneville, G. Adam, G. Martin-Blondel, M. Rafiq, T. Geeraerts, L. Delamarre, S. Grand, A. Krainik, SFNR-COVID Group, Brain MRI Findings in Severe COVID-19: A Retrospective Observational Study, *Radiology.* 297 (November 2) (2020) E242–E251, <https://doi.org/10.1148/radiol.2020202222>. Epub 2020 Jun 16. PMID: 32544034; PMCID: PMC7301613.
- [51] A. Mahammed, L. Saba, A. Vagal, M. Leali, A. Rossi, M. Gaskill, S. Sengupta, B. Zhang, A. Carriero, S. Bachir, P. Crivelli, A. Paschè, E. Premi, A. Padovani, R. Gasparotti, Imaging of neurologic disease in hospitalized patients with COVID-19: an italian multicenter retrospective observational study, *Radiology.* 297 (November 2) (2020) E270–E273, <https://doi.org/10.1148/radiol.2020201933>. Epub 2020 May 21. PMID: 32437313.
- [52] Y. Li, M. Li, M. Wang, Y. Zhou, J. Chang, Y. Xian, D. Wang, L. Mao, H. Jin, B. Hu, Acute cerebrovascular disease following COVID-19: a single center, retrospective, observational study, *Stroke Vasc. Neurol.* 5 (September 3) (2020) 279–284, <https://doi.org/10.1136/svn-2020-000431>. Epub 2020 Jul 2. PMID: 32616524; PMCID: PMC7371480.
- [53] E. Keller, G. Brandi, S. Winkhofer, L.L. Imbach, D. Kirschenbaum, K. Frontzek, P. Steiger, S. Dietler, M. Haeblerlin, J. Willms, F. Porta, A. Waeckerlin, M. Huber, I. A. Abela, A. Lutterotti, C. Stippich, C. Globas, Z. Varga, I. Jelcic, Large and small cerebral vessel involvement in severe COVID-19: detailed clinical workup of a case series, *Stroke.* (2020), <https://doi.org/10.1161/STROKEAHA.120.031224>. Oct 15: STROKEAHA120031224Epub ahead of print. PMID: 33054673.
- [54] L. Zanin, G. Saraceno, P.P. Panciani, G. Renisi, L. Signorini, K. Migliorati, M. M. Fontanella, SARS-CoV-2 can induce brain and spine demyelinating lesions, *Acta Neurochir. (Wien).* 162 (July 7) (2020) 1491–1494, <https://doi.org/10.1007/s00701-020-04374-x>. Epub 2020 May 4. PMID: 32367205; PMCID: PMC7197630.
- [55] A. Zoghi, M. Ramezani, M. Roozbeh, I.A. Darazam, M.A. Sahraian, A case of possible atypical demyelinating event of the central nervous system following COVID-19, *Mult. Scler. Relat. Disord.* (44) (2020), 102324, <https://doi.org/10.1016/j.msard.2020.102324>. June 24Epub ahead of print. PMID: 32615528; PMCID: PMC7311915.
- [56] M. Palao, E. Fernández-Díaz, J. Gracia-Gil, C.M. Romero-Sánchez, I. Díaz-Maroto, T. Segura, Multiple sclerosis following SARS-CoV-2 infection, *Mult. Scler. Relat. Disord.* (45) (2020), 102377, <https://doi.org/10.1016/j.msard.2020.102377>. Jul 7Epub ahead of print. PMID: 32698095; PMCID: PMC7340057.
- [57] T.J. Oxley, J. Mocco, S. Majidi, C.P. Kellner, H. Shoirah, I.P. Singh, R.A. De Leacy, T. Shigematsu, T.R. Ladner, K.A. Yaeger, M. Skliut, J. Weinberger, N.S. Dangayach, J.B. Bederson, S. Tuhim, J.T. Fifi, Large-vessel stroke as a presenting feature of Covid-19 in the young, *N. Engl. J. Med.* 382 (20) (2020) e60, <https://doi.org/10.1056/NEJMc2009787>. May 14Epub 2020 Apr 28. PMID: 32343504; PMCID: PMC7207073.
- [58] M.F. Goldberg, M.F. Goldberg, Neuroradiologic manifestations of COVID-19: what the emergency radiologist needs to know, *Emerg Radiol.* (August 21) (2020) 1–9, <https://doi.org/10.1007/s10140-020-01840-y>. Epub ahead of print. PMID: 32822060; PMCID: PMC7441306.
- [59] S. Yasri, V. Wiwanikit, COVID-19 and epilepsy, *Ann. Indian Acad. Neurol.* 23 (Suppl 1) (2020) S43, https://doi.org/10.4103/aian.AIAN_254_20. Apr Epub 2020 Apr 11. PMID: 32419755; PMCID: PMC7213031.
- [60] Y. Wu, X. Xu, Z. Chen, J. Duan, K. Hashimoto, L. Yang, C. Liu, C. Yang, Nervous system involvement after infection with COVID-19 and other coronaviruses, *Brain Behav. Immun.* 87 (July) (2020) 18–22, <https://doi.org/10.1016/j.bbi.2020.03.031>. Epub 2020 Mar 30. PMID: 32240762; PMCID: PMC7146689.
- [61] G. Balloy, L. Leclair-Visonneau, Y. Péron, A. Magot, A. Peyre, P. Mahé, P. Derkinderen, Non-lesional status epilepticus in a patient with coronavirus disease 2019, *Clin. Neurophysiol.* 131 (August 8) (2020) 2059–2061, <https://doi.org/10.1016/j.clinph.2020.05.005>. Epub 2020 May 13. PMID: 32405258; PMCID: PMC7217773.
- [62] G.N. McAbee, Y. Brosgol, S. Pavlakis, R. Agha, M. Gaffoor, Encephalitis associated with COVID-19 infection in an 11-Year-Old child, *Pediatr. Neurol.* 109 (August 94) (2020), <https://doi.org/10.1016/j.pediatrneurol.2020.04.013>. Epub 2020 Apr 24. PMID: 32586676; PMCID: PMC7180343.
- [63] L. Duong, P. Xu, A. Liu, Meningoencephalitis without respiratory failure in a young female patient with COVID-19 infection in Downtown Los Angeles, early April 2020, *Brain Behav. Immun.* 87 (July 33) (2020), <https://doi.org/10.1016/j.bbi.2020.04.024>. Epub 2020 Apr 17. PMID: 32305574; PMCID: PMC7162766.
- [64] M. Flamand, A. Perron, Y. Buron, W. Szurhaj, Pay more attention to EEG in COVID-19 pandemic, *Clin. Neurophysiol.* 131 (August 8) (2020) 2062–2064, <https://doi.org/10.1016/j.clinph.2020.05.011>. Epub 2020 May 22. PMID: 32482439; PMCID: PMC7242207.
- [65] G. Vellieux, A. Rouvel-Tallec, P. Jaquet, A. Grinea, R. Sonnevill, M.P. d'Ortho, COVID-19 associated encephalopathy: is there a specific EEG pattern? *Clin. Neurophysiol.* 131 (August 8) (2020) 1928–1930, <https://doi.org/10.1016/j.clinph.2020.06.005>. Epub 2020 Jun 24. PMID: 32615526; PMCID: PMC7311351.
- [66] J. Helms, S. Kremer, H. Merdji, R. Clere-Jehl, M. Schenck, C. Kummerlen, O. Collange, C. Boulay, S. Fafi-Kremer, M. Ohana, M. Anheim, F. Meziani, Neurologic features in severe SARS-CoV-2 infection, *N. Engl. J. Med.* 382 (23) (2020) 2268–2270, <https://doi.org/10.1056/NEJMc2008597>. Jun 4Epub 2020 Apr 15. PMID: 32294339; PMCID: PMC7179967.
- [67] M. Jasti, K. Nalleballe, V. Dandu, S. Onteddu, A review of pathophysiology and neuropsychiatric manifestations of COVID-19, *J. Neurol.* (2020) 1–6, <https://doi.org/10.1007/s00415-020-09950-w>. Jun 3Epub ahead of print. PMID: 32494854; PMCID: PMC7268182.
- [68] F. Haji Akhoundi, M.A. Sahraian, A. Naser Moghadasi, Neuropsychiatric and cognitive effects of the COVID-19 outbreak on multiple sclerosis patients, *Mult. Scler. Relat. Disord.* 41 (June) (2020), 102164, <https://doi.org/10.1016/j.msard.2020.102164>. Epub 2020 Apr 29. PMID: 32388452; PMCID: PMC7194705.