



Since January 2020 Elsevier has created a COVID-19 resource centre with free information in English and Mandarin on the novel coronavirus COVID-19. The COVID-19 resource centre is hosted on Elsevier Connect, the company's public news and information website.

Elsevier hereby grants permission to make all its COVID-19-related research that is available on the COVID-19 resource centre - including this research content - immediately available in PubMed Central and other publicly funded repositories, such as the WHO COVID database with rights for unrestricted research re-use and analyses in any form or by any means with acknowledgement of the original source. These permissions are granted for free by Elsevier for as long as the COVID-19 resource centre remains active.

this reason, the EM in our report was done by a professor with more than 30 years of experience in ultrastructural analysis.^{3,4} Figure 3B in our case report² does show a rough endoplasmic reticulum, as suggested by Dittmayer and colleagues, but it also shows a particular aspect of viral particle assembly (a section through a spherical cluster of viral nucleocapsids apposed on the membrane of the rough endoplasmic reticulum), which is probably a viral translation centre.⁵

The presence of SARS-CoV-2 particles within membrane compartments, as shown by Dittmayer and colleagues,¹ is typical of preserved non-necrotic cells in which there is viral replication. In our Case Report, cells were undergoing necrotic degeneration (corroborated by C4d staining on figure 2D),² which led to cardiac failure and death. In this situation, viral particles might not appear in clusters within membranes but free in the cytosol, intermingled with organelle membranes undergoing fragmentation—much harder to recognise.

Although the criticism of one of the figures in our report does not affect the main message—that SARS-CoV-2 infection of cardiac tissue was probably a major contributor to the child's myocarditis and heart failure²—in our opinion, criticism of peer-reviewed published data should be more careful and preferentially addressed directly to the authors to avoid the spread of misleading information, clouding the scientific literature.

We declare no competing interests.

*Marisa Dolhnikoff,
Amaro N Duarte-Neto,
Paulo H N Saldiva, Elia G Caldini
maridol@usp.br

Departamento de Patologia, Faculdade de Medicina da Universidade de São Paulo, São Paulo 01246-903, Brazil

- 1 Dittmayer C, Meinhardt J, Radbruch H, et al. Why misinterpretation of electron micrographs in SARS-CoV-2-infected tissue goes viral. *Lancet* 2020; **396**: e64-65.
- 2 Dolhnikoff M, Ferreira Ferrantij, de Almeida Monteiro RA, et al. SARS-CoV-2 in cardiac tissue of a child with COVID-19-related multisystem inflammatory syndrome. *Lancet Child Adolesc Health* 2020; **4**: 790-94.

- 3 Mauad T, Hajjar LA, Callegari GD, et al. Lung pathology in fatal novel human influenza A (H1N1) infection. *Am J Respir Crit Care Med* 2010; **181**: 72-79.
- 4 Ono SK, Bassit L, Van Vaisberg V, et al. Acute acalculous cholecystitis during zika virus infection in an immunocompromised patient. *Hepatology* 2018; **67**: 2051-54.
- 5 Goldsmith CS, Tatti KM, Ksiazek TG, et al. Ultrastructural characterization of SARS coronavirus. *Emerg Infect Dis* 2004; **10**: 320-26.

Authors' reply

We fully agree with Marisa Dolhnikoff and colleagues that we should aim to understand COVID-19 pathophysiology. However, their arguments

directed at our Correspondence,¹ which should support their Case Report² on ultrastructural identification of severe acute respiratory syndrome coronavirus 2 (SARS-CoV-2) in patient tissue, are not convincing. As in other fields of ultrastructural research, identification of subcellular structures is made on the basis of ultrastructural features, which are characteristic for each structure. The putative virus particles in the publication by Dolhnikoff and colleagues² lack essential and distinct ultrastructural features, such as biomembranes and surface

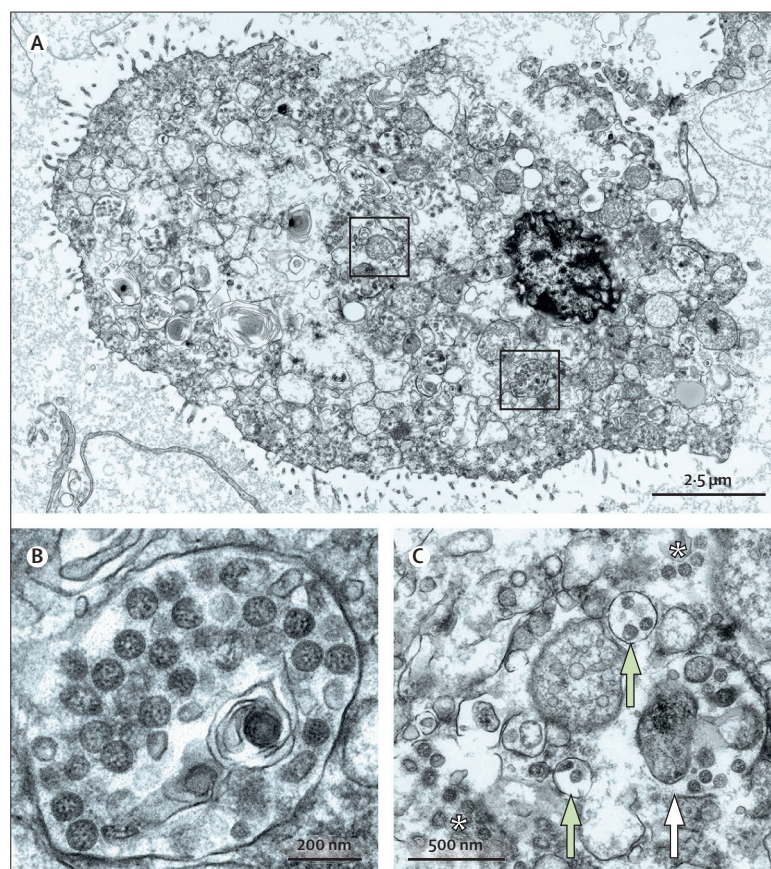


Figure: SARS-CoV-2 ultrastructural morphology in autolytic autopsy lung

In lung autopsy tissue showing marked autolysis, we found single cells with numerous well preserved SARS-CoV-2 particles. (A) The ultrastructure of the cell is severely affected and does not clearly identify the cell type. Boxed regions are magnified in panels B and C, in which many of the round and oval particles show characteristic morphological features of SARS-CoV-2. (C) The white asterisks show well preserved viral particles that appeared free within the cytoplasm, probably due to rupture of membrane compartments. The white arrow points to well preserved viral particles within ruptured membrane compartments, and the green arrows point to viral particles within intact membrane compartments. These images were acquired with a scanning electron microscope in transmission mode. A high-resolution dataset of the cell (A, C), digitised at 1 nm pixel size, is available online for open access pan-and-zoom analysis, also allowing for measurements of structures of interest to provide a positive control of coronavirus identification in autopsy tissue. SARS-CoV-2=severe acute respiratory syndrome coronavirus 2.

For the high-resolution dataset see www.nanotomy.org

structures, for an unambiguous identification of SARS-CoV-2. Their electron micrographs suggest poor structural preservation (eg, biomembranes are not detectable), for an unknown reason. Hence, the identification of enveloped viruses is very difficult and most likely impossible. We acknowledge the application of complementary techniques for viral detection, but their RT-PCR indicated a low viral load and immunohistochemistry was not directed to viral components.²

Detection of SARS-CoV-2 by electron microscopy might be impossible if there is an insufficient concentration of viral particles, which is further complicated in cases of focal infections. Thus, it cannot be generally expected to find many and evenly distributed locations in RT-PCR-positive samples, which show a significant number of viral particles. The localisation of hot spots of virus particle assembly in tissue might be guided by immunohistochemistry or in-situ hybridisation.^{3,4} Identification of SARS-CoV-2 at the ultrastructural level requires characteristic morphological features (figure). Autolysis and necrosis might negatively affect these features¹ but even in suboptimal samples, including formalin-fixed and paraffin-embedded tissue, coronavirus particle identification is possible if the characteristic ultrastructure is preserved.^{3,4} Generally, coronavirus particle profiles should show the characteristic size (~60–160 nm without spikes), shape (round to oval), biomembrane (at least partly visible), granular or dense interior space, and surface projections (at least partly visible), whereas additional features such as grouped or regular localisation within membrane compartments or in the extracellular space might help to identify SARS-CoV-2.

At least 30 publications, many also peer-reviewed, showed putative coronavirus, which lacked either sufficient image quality or ultrastructural features for clear identification as

SARS-CoV-2. We only discussed two in our Correspondence¹ as examples to precisely address our concerns. The extent of misinterpretations or insufficiently founded interpretations of putative coronavirus particles was recently shown in a detailed review.⁵ Similarly, we believe that electron micrographs that were published during the SARS pandemic in the early 2000s require further discussion.

We agree with Dolhnikoff and colleagues that some concerns could be directly addressed to the authors. However, disputable publications spread very quickly, which can flaw the basis for a precise ultrastructural characterisation of SARS-CoV-2; thus, we are convinced that this crucial discussion required publication.

We declare no competing interests. We thank the Core Facility for Electron Microscopy of the Charité for support in acquisition of the data.

*Carsten Dittmayer, Jenny Meinhardt, Helena Radbruch, Josefine Radke, Barbara Ingold Heppner, Frank L Heppner, Werner Stenzel, Gudrun Holland, Michael Laue
carsten.dittmayer@charite.de

Department of Neuropathology, Charité–Universitätsmedizin Berlin, 10117 Berlin, Germany (CD, JM, HR, JR, FLH, WS); Berlin Institute of Health, Berlin, Germany (JR); German Cancer Consortium, Partner Site Berlin, CCCC Campus Mitte, Berlin, Germany (JR); Institute of Pathology, DRK Kliniken Berlin, Berlin, Germany (BIH); Cluster of Excellence, NeuroCure, Berlin, Germany (FLH); German Center for Neurodegenerative Diseases Berlin, Berlin, Germany (FLH); Centre for Biological Threats and Special Pathogens, Robert Koch Institute, Berlin, Germany (GH, ML)

- 1 Dittmayer C, Meinhardt J, Radbruch H, et al. Why misinterpretation of electron micrographs in SARS-CoV-2-infected tissue goes viral. *Lancet* 2020; **396**: e64–65.
- 2 Dolhnikoff M, Ferreira Ferranti J, de Almeida Monteiro RA, et al. SARS-CoV-2 in cardiac tissue of a child with COVID-19-related multisystem inflammatory syndrome. *Lancet Child Adolesc Health* 2020; **4**: 790–94.
- 3 Meinhardt J, Radke J, Dittmayer C, et al. Olfactory transmucosal SARS-CoV-2 invasion as a port of central nervous system entry in individuals with COVID-19. *Nat Neurosci* 2020; published online Nov 30. <https://doi.org/10.1038/s41593-020-00758-5>.
- 4 Shieh WJ, Hsiao CH, Paddock CD, et al. Immunohistochemical, in situ hybridization, and ultrastructural localization of SARS-associated coronavirus in lung of a fatal case of severe acute respiratory syndrome in Taiwan. *Hum Pathol* 2005; **36**: 303–09.

- 5 Hopfer H, Herzig MC, Gosert R, et al. Hunting coronavirus by transmission electron microscopy—a guide to SARS-CoV-2-associated ultrastructural pathology in COVID-19 tissues. *Histopathology* 2020; published online Sept 27. <https://doi.org/10.1111/his.14264>.



Published Online
December 4, 2020
[https://doi.org/10.1016/S0140-6736\(20\)32592-7](https://doi.org/10.1016/S0140-6736(20)32592-7)

Department of Error

Cieza A, Causey K, Kamenov K, Hanson SW, Chatterji S, Vos T. Global estimates of the need for rehabilitation based on the Global Burden of Disease study 2019: a systematic analysis for the Global Burden of Disease Study 2019. *Lancet* 2020; **396**: 2006–17. In this Article, in the Findings section of the Summary and in the Results and Discussion sections, low back pain has been corrected to the most prevalent condition in 160 of the 204 countries analysed. In the Findings section of the Summary, the prevalence of musculoskeletal disorders has been corrected to 1.71 billion people (1.63–1.80). In the Research in context panel and the Discussion section, the estimated number of people with conditions that could benefit from rehabilitation has been corrected to 2.41 billion. These corrections have been made to the online version as of Dec 4, 2020.