

Piriformis syndrome: pain response outcomes following CT-guided injection and incremental value of botulinum toxin injection

Kevin Yan 

Yin Xi 

Rocco Hlis 

Avneesh Chhabra 

PURPOSE

Piriformis syndrome is a common pain condition affecting the buttock and posterior hip with or without radiation to the leg, and management of the condition involves many treatments. In this study, we hypothesize that a CT-guided injection with botulinum toxin is more effective in providing pain relief than a CT-guided injection without Botox.

METHODS

Overall, 97 consecutive patients with piriformis syndrome presented for a CT-guided injection of the piriformis muscle and perineural injection of the sciatic nerve. After the injection, the patients received a visual analog scale pain log to record their pain level until the follow-up appointment. Values of $p < 0.2$ were considered as confounder and adjusted by inverse probability of treatment weighting (IPTW) via propensity score. The effect of botulinum toxin on 48-hour response and duration of response was tested using weighted chi-square test and weighted Kaplan-Meier analysis.

RESULTS

There was a total of 97 patients in the study, and 111 injections, as some patients had bilateral injections. Patients in the Botox group had more 48-hour response than patients in the non-botulinum toxin group ($p < 0.001$ with IPTW, $p = 0.005$ without IPTW). Median pain-free survival was 30 days for Botox group and 1 day for non-Botox group ($p = 0.059$ with IPTW, $p = 0.10$ without IPTW).

CONCLUSION

CT-guided injections with botulinum toxin for patients with piriformis syndrome are more likely to lead to a positive response and a longer duration of response than patients who receive a CT-guided injection without botulinum toxin. We hope that this study facilitates future prospective randomized blind trials for patients with suspected piriformis syndrome.

Piriformis syndrome is a common pain condition affecting the buttock and posterior hip with or without radiation to the leg. It is thought to be caused by prolonged contraction (spasm) or hypertrophy of the piriformis muscle, and it can account for up to 6% of sciatica-like symptoms (1, 2). The most common presentation of piriformis syndrome is buttock pain overlying the wallet area that increases with sitting, which is frequently unilateral or less commonly bilateral (3). This pain can significantly impact a patient's quality of life. Suggested pathophysiology includes anatomical variations of the piriformis with or without hypertrophy or spasm, trauma, or pinching of the sciatic nerve caused by intramuscular course through the piriformis muscle or adjacent fibrous bands / accessory muscle slips (4, 5).

Piriformis syndrome is diagnosed on the basis of clinical findings of buttock pain, sciatica symptoms and wallet area anesthesia and/or tenderness. The findings can be confirmed with cross-sectional techniques, particularly magnetic resonance imaging (6, 7). Piriformis syndrome is also diagnosed presumptively after workup has revealed no other sources of pain in the buttock, hip, and back. Magnetic resonance neurography (MRN) of the lumbosacral plexus and pelvis has become an important tool for the diagnosis and evaluation of sciatic neuralgia and in guiding management with image-guided nerve blocks and muscle injections (8). Recent studies using MRN for chronic lumbosacral and pelvic pain have shown impact of MRN in diagnostic thinking, management, and outcomes of such patients

From the Department of Radiology (K.Y., Y.X., R.H., A.C. ✉ Avneesh.Chhabra@UTSouthwestern.edu), and Department of Orthopedics (A.C.), UT Southwestern Medical Center, Dallas, Texas, USA.

Received 09 September 2019; revision requested 10 November 2019; last revision received 22 February 2020; accepted 31 March 2020.

Published online 25 November 2020.

DOI 10.5152/dir.2020.19444

You may cite this article as: Yan K, Xi Y, Hlis R, Chhabra A. Piriformis syndrome: pain response outcomes following CT-guided injection and incremental value of botulinum toxin injection. *Diagn Interv Radiol* 2021; 27: 126–133.

(9, 10). In piriformis syndrome, the common findings on MRN include hypertrophied or atrophied piriformis muscles, accessory muscle slips, split sciatic nerve, and increased signal or flattening / prominence of the sciatic nerve at the sciatic notch with or without increased signal in L5 and/or S1 nerve roots (9).

Initial management of piriformis syndrome includes physical therapy, heat, massage, anti-inflammatory medications, and behavioral modifications. However, if the pain remains uncontrolled, local anesthetic with steroid injection, surgery, or epidural injection have been reported to be effective in treatment (11–13). Onabotulinum toxin A (Botox, Allergan) has been used historically for many disorders of excessive muscle contraction, spasticity, dystonia, muscle pain, myofascial pain, and sacroiliac joint injections (14, 15). The use of Botox for injections in patients with piriformis syndrome has shown positive results. Many small studies and case reports using ultrasound-guided injections have reported pain reduction and improvement in the quality of life after patients received Botox injections to the piriformis muscle (16, 17). Recently, CT-guided injections with Botox for piriformis syndrome has also shown pain reduction compared with baseline (6, 18). However, these studies were not comparative studies evaluating the efficacy of the injection with Botox versus without Botox. In addition, perineural injections of the sciatic nerve and how that may contribute to pain reduction in patients with piriformis syndrome have not been evaluated.

The aim of the study in patients with piriformis syndrome was to determine whether a CT-guided injection of the piriformis

muscle with Botox and a perineural injection of the sciatic nerve affect the patients differently than the injections without the administration of Botox. We hypothesized that a CT-guided injection with Botox is more effective in providing pain relief than a CT-guided injection without Botox, resulting in a positive incremental value.

Methods

This is a retrospective cohort study performed following institutional review board approval, protocol number (STU 072013-057). Patient inclusion was not randomized in two different groups and they received the two types of injections as part of their standard care management. For this retrospective evaluation, the informed consent was waived.

Patients

A consecutive series of patients who presented from January 2014 to October 2018 for a CT-guided injection of the piriformis muscle and perineural injection of the sciatic nerve were included. All patients must have had a diagnosis of piriformis syndrome on the basis of clinical findings

and/or MRN imaging. Patients must have had both perineural injections of the sciatic nerve and piriformis muscle. Patients were excluded if they did not have clinic follow-up to evaluate symptoms after the injection (Fig. 1). Patient demographic data included sex, age, body mass index (BMI), presenting symptoms, physical examination findings, surgical history, and injection history. The final diagnosis of piriformis syndrome was made by history, physical examination, and MRN findings if they had undergone imaging. Prior clinic injections and other follow-up treatments like surgery and/or radiofrequency ablation (RFA) were also recorded.

MRN lumbosacral plexus protocol

The MRN lumbosacral plexus protocol was performed on a 3 T scanner (Achieva, Ingenia, Philips) using torso XL coil coupled with spine coil elements (Table 1). It included two-dimensional, three-dimensional anatomic, and diffusion imaging sequences, and encompassed evaluation of the lumbosacral spine, lumbosacral plexus and peripheral nerves in the abdomen and pelvis. All included MRNs were read by mul-

Main points

- CT-guided injections with botulinum toxin (Botox, Allergan) for patients with piriformis syndrome are more likely to lead to a positive response than CT-guided injections without Botox.
- CT-guided injections with Botox for patients with piriformis syndrome are more likely to lead to a longer duration of response than patients who receive a CT-guided injection without Botox.
- We showed that median pain-free survival for the non-Botox group was 1 day versus 30 days for the Botox group.

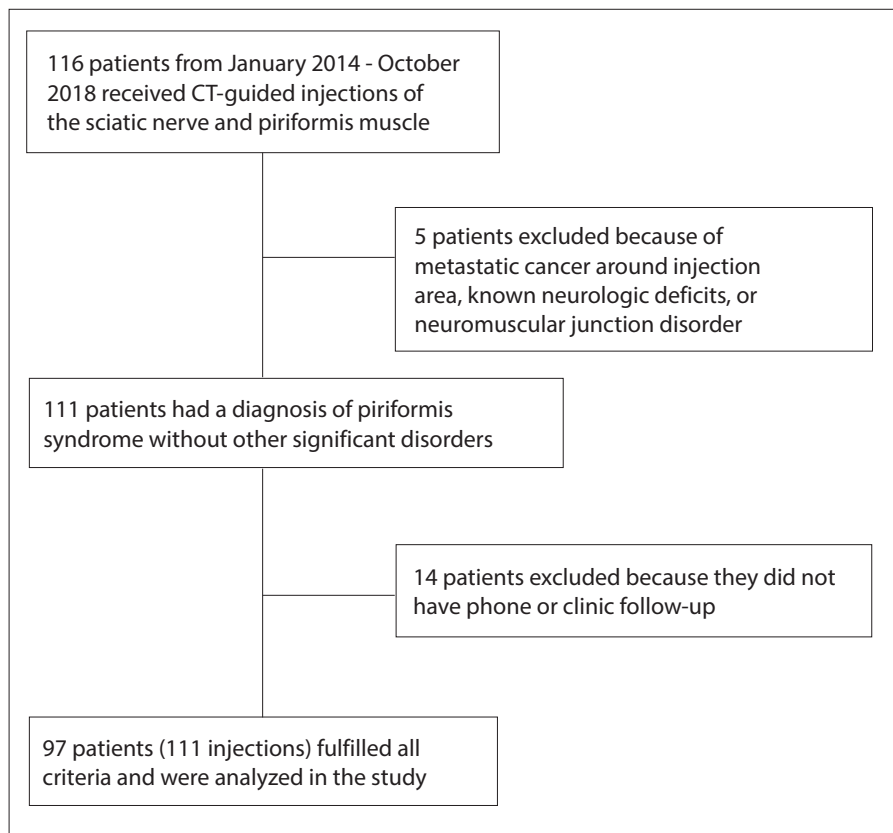


Figure 1. Patient selection flowchart detailing inclusion and exclusion criteria.

Table 1. Imaging protocol and parameters for 3 T MRN of the lumbosacral plexus

Sequence	TR (ms)	TE (ms)	Gap	Turbo factor	Acquisition time	Voxel (mm)	FOV (mm)
Axial T1W	500	8	10%	8	4 min 39 s	0.6×0.6×4.0	330
Axial T2W SPAIR	4000	60	10%	7	6 min 13 s	1.0×1.0×4.0	330
3D coronal STIR	2000	78	0	100	8 min	1.5×1.5×1.5	380
Sagittal T2W spine	3500	120	10%	19	4 min 18 s	0.9×1.1×4.0	280
Axial T2W spine	3000	120	10%	27	4 min 19 s	1.0×1.0×5.0	110
Axial DTI	16100	54	0	b-values=0.600	5 min	3.5×3.5×5.0	331

MRN, magnetic resonance neurography; TR, repetition time; TE, echo time; FOV, field of view; T1W, T1-weighted; T2W, T2-weighted; SPAIR, spectral adiabatic inversion recovery; 3D, three-dimensional; STIR, short T1 inversion recovery; DTI, diffusion tensor imaging.

CT-guided injection technique and follow-up

The injections were performed by musculoskeletal fellows with direct supervision from a musculoskeletal radiologist or by the musculoskeletal radiologists themselves using a standardized template of procedure as described in a previous article by Wadhwa et al. (19). The risks of the procedure were explained in detail to the patient, and informed consent was obtained. The patient was placed on the CT gantry in the prone position. The piriformis muscle and the sciatic nerve were localized using CT guidance. The patient was then prepped and draped in the typical sterile fashion. Under intermittent CT guidance, a 22-gauge needle was directed towards the course of the sciatic nerve and a 20-gauge needle was directed into the piriformis muscle. Dilute non-ionic contrast (1–2 cc) was injected to confirm needle tip position. A 4:6:1 mixture of 1% lidocaine, 0.5% bupivacaine, and 100 units of Botox was injected into the piriformis muscle. The patients without Botox only received 4:6 mixture of 1% lidocaine, 0.5% bupivacaine into the piriformis muscle. Both groups of patients received a 2:2:1 mixture of 1% lidocaine, 0.5% bupivacaine, and 4 mg dexamethasone around the sciatic nerve.

After the injection, the patients received a visual analog scale (VAS) pain log to record their pain level until they had a follow-up appointment with either the referring clinician or with the radiologist (Fig. 2). Patients received a telephone call from the staff 48 hours after the injection to follow up on their symptoms and any complications they may have had related to the procedure. At the clinic follow-up, the pain logs were reviewed by the clinician and scanned into the electronic health records. Clinic follow-ups occurred at 1-month, 3-month, and 6-month intervals, or as per the patient's discretion if the pain returned earlier. At each clinic follow-up, patients self-reported the time when their pain recurred and this was documented in the electronic medical record. Some patients were lost during the clinic follow-up period.

Patient identification sticker

CT-guided injection or nerve block: pain record -

Instructions: please fill out for whichever side you had injected. Rate pain from 0-10 on a 10 point scale. If you had both sides injected, fill out for each side independently (pain scores may be different side to side). If you have the tailbone or something else in the midline injected, simply fill out one side.

Left side	Right side
Pre-procedure pain level: 0 1 2 3 4 5 6 7 8 9 10	Pre-procedure pain level: 0 1 2 3 4 5 6 7 8 9 10
Post-procedure pain level:	Post-procedure pain level:
30 min: 0 1 2 3 4 5 6 7 8 9 10	30 min: 0 1 2 3 4 5 6 7 8 9 10
1 hours: 0 1 2 3 4 5 6 7 8 9 10	1 hours: 0 1 2 3 4 5 6 7 8 9 10
2 hours: 0 1 2 3 4 5 6 7 8 9 10	2 hours: 0 1 2 3 4 5 6 7 8 9 10
4 hours: 0 1 2 3 4 5 6 7 8 9 10	4 hours: 0 1 2 3 4 5 6 7 8 9 10
8 hours: 0 1 2 3 4 5 6 7 8 9 10	8 hours: 0 1 2 3 4 5 6 7 8 9 10
24 hours: 0 1 2 3 4 5 6 7 8 9 10	24 hours: 0 1 2 3 4 5 6 7 8 9 10
48 hours: 0 1 2 3 4 5 6 7 8 9 10	48 hours: 0 1 2 3 4 5 6 7 8 9 10

Figure 2. Patient visual analog scale for CT-guided injection.

multiple fellowship-trained musculoskeletal radiologists with 2–8 years' experience with MRN techniques and reporting. A systematic documentation of the findings had been

performed in all the reports as a standard of care, which included findings of bone, spine, muscle, peripheral nerves, masses, and other visceral lesions.

Data evaluation

Responses to the CT-guided injections were defined based on published criteria and shown in Table 2 (20, 21). Responses were categorized into three groups: positive block, negative block, and possible

Table 2. Definition of responses to the CT-guided injection of sciatic nerve and piriformis muscle.

Positive block – must meet all 3 criteria	<ul style="list-style-type: none"> • Decrease in pain score of 50% within the first 24 hours after the injection • Response sustained at 48 hours after the injection • No increase in pain over the first 48 hours
Negative block	<ul style="list-style-type: none"> • Decrease in pain of less than 2 points on the VAS scale • Pain worsened after the injection
Possible positive block	<ul style="list-style-type: none"> • Does not meet all 3 criteria of “positive block” • Delayed pain relief starting more than 24 hours after injection • Decrease in pain level not sustained for 48 hours, but there was an initial drop in pain score • Not a significant drop in pain score, but there was a decrease of more than 2 points

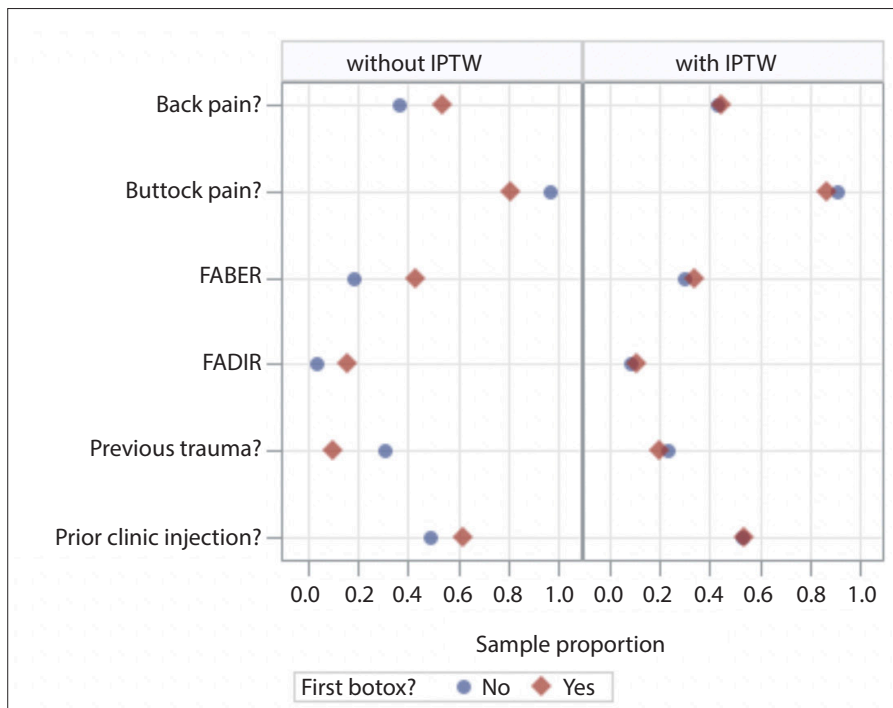


Figure 3. Proportion of patients having Botox injection for their first CT-guided injection before and after propensity score weighting (IPTW, inverse probability of treatment weighting; FABER, flexion, abduction, external rotation test; FADIR, flexion, adduction, internal rotation test).

positive block. Patient responses at 48 hours were recorded as “positive” and “negative”. Follow-up time to pain-return or the last follow-up without pain were recorded.

Statistical analysis

Age, BMI, pain level, duration of pain, sex, presence of buttock pain and back pain, pain meds, radiculopathy, FABER (flexion, abduction, external rotation test), FADIR (flexion, adduction, internal rotation test), previous trauma, prior clinic injection, prior imaging for problem muscle change, nerve change, split sciatic, number of CT injection, laterality were all recorded. Continuous variables

and categorical variables were represented as median (Q1, Q3) (Q1, 25th percentile; Q3, 75th percentile) and count (percentage) respectively. Wilcoxon-Mann-Whitney tests and chi-square tests were used to test the difference between Botox to identify potential confounders. When testing categorical variables, levels with too few counts were combined when appropriate. p values < 0.2 were considered as confounder and adjusted by inverse probability of treatment weighting (IPTW) via propensity score.

The effect of Botox on 48-hour response and duration of response was tested using weighted chi-square test and weighted Ka-

plan-Meier analysis. For the pain-free survival analysis, all patients who were not initially pain-free were excluded. P value < 0.05 was considered statistically significant. All analyses were done under SAS 9.4 (SAS institute).

Results

There was a total of 97 patients in the study, and 111 injections, as some patients had bilateral injections. Table 3 summarizes the patient characteristics, history, physical exam findings, and imaging findings. In the study, 84 patients (87%) presented with buttock pain, 56 patients (58%) presented with back pain, and 83 patients (86%) had symptoms of radiculopathy. Also, 55 patients (57%) had prior clinic injections, and 82 patients (85%) received an MRN prior to the CT-guided injections. Of the 82 patients who received an MRN, 18 (22%) showed ipsilateral piriformis hypertrophy (asymmetrical enlargement relative to the unaffected side) and 35 (43%) showed ipsilateral piriformis atrophy (asymmetrically smaller on the affected side with or without fatty infiltration). Finally, 67 patients (82%) had ipsilateral sciatic nerve hyperintensity and 14 patients (17%) showed ipsilateral split sciatic. Proportion of having Botox before and after propensity score weighting are shown in Fig. 3.

All variables were comparable between Botox and non-Botox group, back pain, buttock pain, FABER, FADIR, previous trauma and prior clinic injection had $p < 0.2$ and were considered as possible confounders.

The response to injection after the first CT-guided injection was evaluated. Figs. 4 and 5 show MRN and CT-guided injection images of two patients in the study. Patients in the Botox group had more 48-hour response than patients in the non-Botox group ($p < 0.001$ with IPTW, $p = 0.005$ without IPTW) (Table 4). Median pain-free survival for Botox group was 30 days (95% CI: 4–90 days) and was 1 day (95% CI, 1–14 days) for non-Botox group ($p = 0.059$ with IPTW, $p = 0.10$ without IPTW). Fig. 6 shows the graph for the pain-free survival analysis.

None of the patients had any complications from the procedure documented at their last follow-up.

Discussion

Piriformis syndrome is a common pain condition involving the buttock and posterior hip that frequently affects a patient’s quality of life. Symptoms are aggravat-

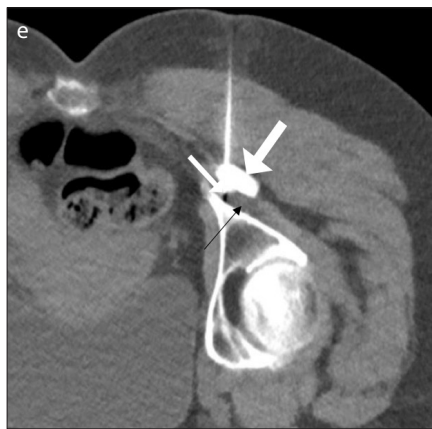
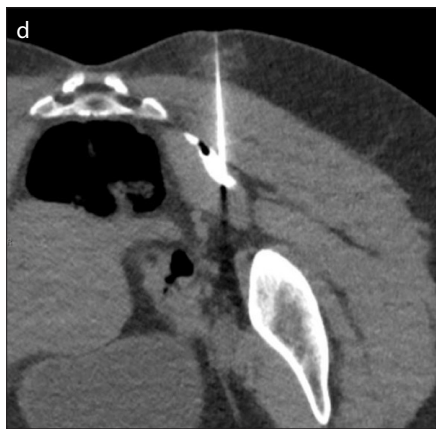
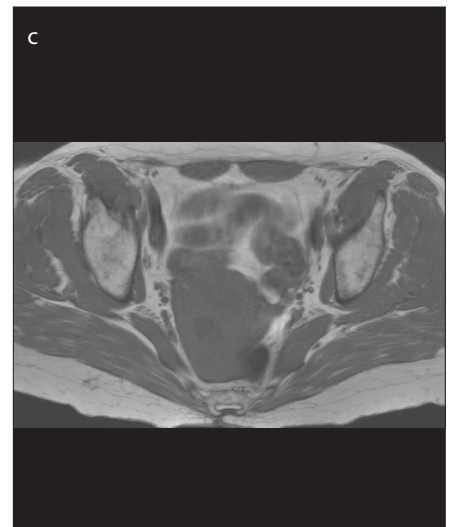
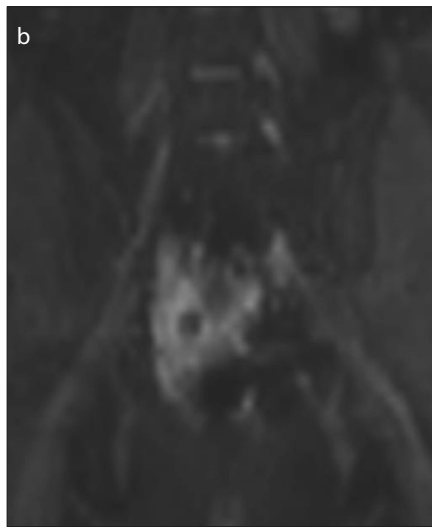
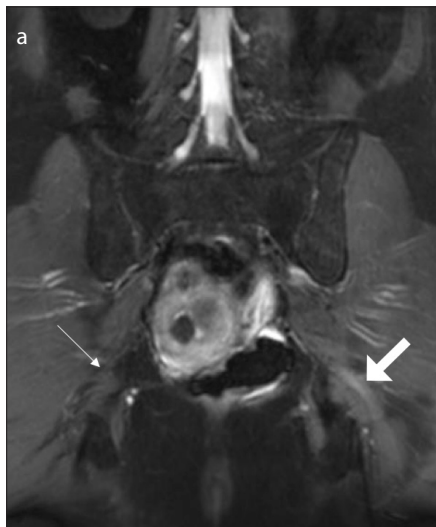


Figure 4. a–e. A 57-year-old female presenting with buttock pain and back pain and diagnosed with left piriformis syndrome. She received an injection with Botox and had a positive response. Coronal 3D inversion recovery turbo spin-echo (IR TSE) image (a) shows asymmetrically hyperintense left sciatic nerve (*thick arrow*) at the sciatic notch compared to normal right sciatic nerve (*thin arrow*). Coronal maximum intensity projection (MIP) DTI image ($b=600 \text{ s/mm}^2$) (b) shows hyperintense left sciatic nerve. Axial T1-weighted image (c) shows left piriformis hypertrophy. CT-guided injection (d) with Botox and contrast of the left piriformis muscle. CT-guided injection (e) into the sciatic nerve (*black arrow*) showing the needle tip (*thin white arrow*), and the contrast (*thick white arrow*).

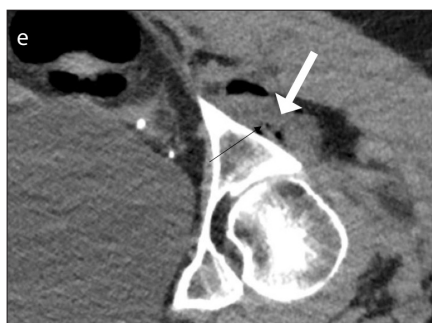
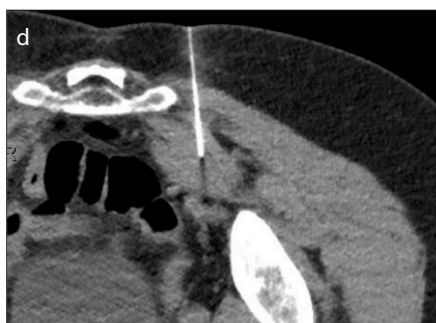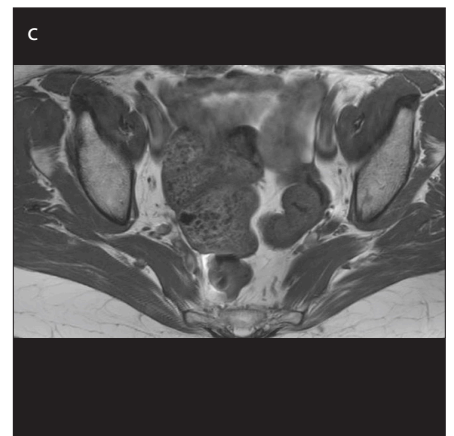
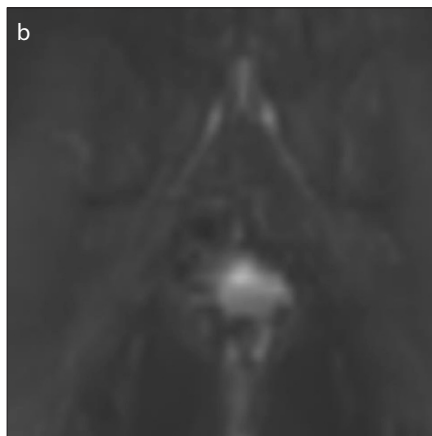
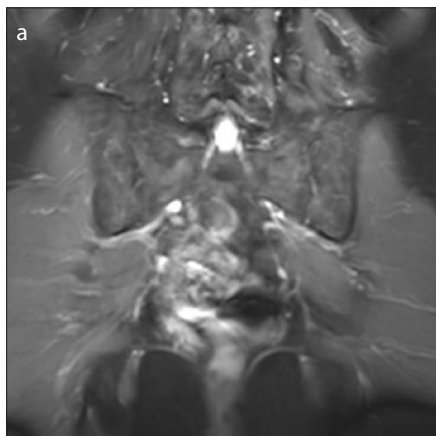


Figure 5. a–e. A 78-year-old female presenting with buttock pain and back pain and diagnosed with left piriformis syndrome. She received an injection without Botox and had a negative response. Coronal 3D IR TSE image (a) shows normal signal of the sciatic nerves. Coronal MIP DTI image ($b=600 \text{ s/mm}^2$) (b) shows no enhancement of the sciatic nerves. Axial T1-weighted image (c) shows left piriformis hypertrophy. CT-guided injection (d) without Botox of the left piriformis muscle. Post-injection image (e) of the sciatic nerve (*black arrow*) and medication mixture (*white arrow*).

Table 3. Patient characteristics separated based on whether or not they received an injection with Botox

	Without Botox (n=41)	With Botox (n=70)	p
First injection age (years), median (IQR)	54 (44–63)	53 (41–65)	0.71
BMI (kg/m ²), median (IQR)	25 (22–27)	25 (22–28)	0.92
Pain level, median (IQR)	8 (7–9)	8 (7–9)	0.80
Duration of pain (years), median (IQR)	2.5 (1–4)	2 (1.5–3)	0.69
Sex, n (%)			0.95
Female	26 (63.41)	44 (62.86)	
Male	15 (36.59)	26 (37.14)	
Buttock pain, n (%)			0.060
No	2 (4.88)	12 (17.14)	
Yes	39 (95.12)	58 (82.86)	
Back pain, n (%)			0.073
No	23 (56.1)	27 (38.57)	
Yes	18 (43.9)	43 (61.43)	
On pain medications, n (%)			0.73
No	25 (60.98)	45 (64.29)	
Yes	16 (39.02)	25 (35.71)	
Radiculopathy, n (%)			0.69
No	7 (17.07)	10 (14.29)	
Yes	34 (82.93)	60 (85.71)	
FABER positive, n (%)			0.13
No	32 (78.05)	45 (64.29)	
Yes	9 (21.95)	25 (35.71)	
FADIR positive, n (%)			0.19
No	38 (92.68)	59 (84.29)	
Yes	3 (7.32)	11 (15.71)	
Previous trauma, n (%)			0.064
No	30 (73.17)	61 (87.14)	
Fall	7 (17.07)	7 (10)	
Motor vehicle accident	3 (7.32)	2 (2.86)	
Cancer	1 (2.44)	0 (0)	
Prior clinic injection, n (%)			0.19
No	21 (51.22)	27 (38.57)	
Yes	20 (48.78)	43 (61.43)	
Muscle changes, n (%)			0.58
No	21 (51.22)	32 (45.71)	
Hypertrophy	12 (29.27)	26 (37.14)	
Atrophy	8 (19.51)	12 (17.14)	
Nerve changes, n (%)			0.95
No	15 (36.59)	26 (37.14)	
Yes	26 (63.41)	44 (62.86)	
Split sciatic, n (%)			0.62
No	35 (85.37)	62 (88.57)	
Yes	6 (14.63)	8 (11.43)	

IQR, interquartile range; BMI, body mass index; FABER, flexion, abduction, external rotation test; FADIR, flexion, adduction, internal rotation test.

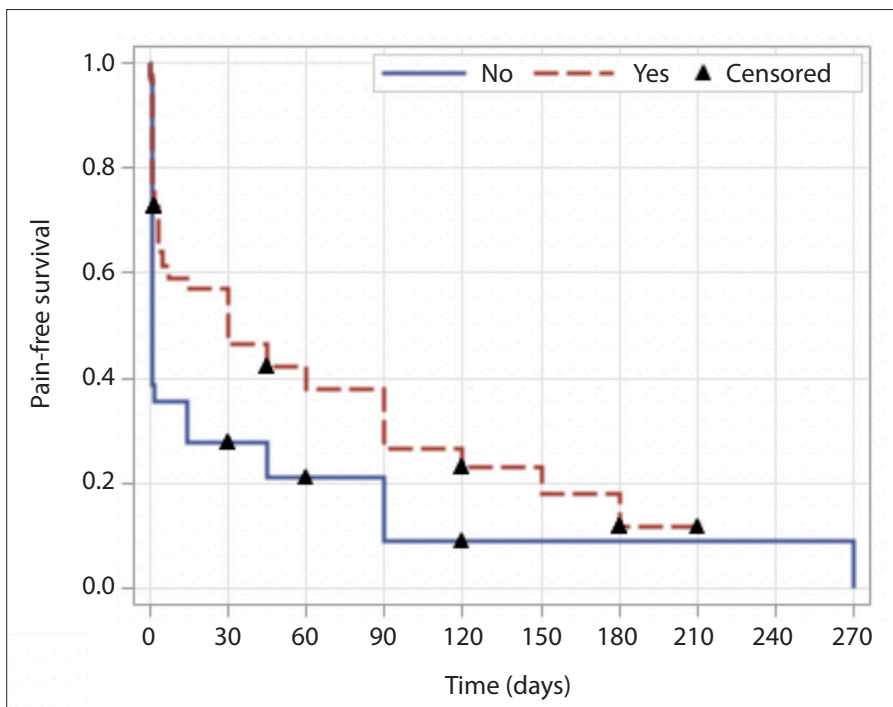
ed when in the sitting position with hip flexion, adduction, and internal rotation. Piriformis syndrome is a diagnosis of exclusion, and a combination of history, physical examination, and imaging findings are needed before the diagnosis can be made. In our study, the majority of patients presented with buttock pain (87%), back pain (58%), and radiculopathy (86%). As noted in a review article by Hopayian et al. (22), these frequencies fall within the range documented by many other studies regarding piriformis syndrome. MRN imaging was performed in 85% of patients before they received the CT-guided injection. Of the patients who had an MRN, only 4 did not have any nerve or muscle changes as noted in the report. Previous studies have reported abnormal imaging in the setting of piriformis syndrome (23, 24) and our results validate such findings.

Initial therapy for piriformis syndrome involves conservative options like physical therapy, massages, heat therapy, and anti-inflammatory medications. In our study, all of our patients had undergone conservative treatment options before receiving CT-guided injections. About 43% of the patients had received prior clinic injections through various pain clinics with no success. We had more success as our injections were done under CT guidance and presumably since, we also injected the perineural area around the sciatic nerve in all cases. At our institution, we perform the injections for piriformis syndrome under CT guidance, because it offers soft tissue contrast, which assists in differentiating vessels from nerves (19). In addition, it is less operator dependent than ultrasound. Even though patients are exposed to ionizing radiation during a CT-guided injection as opposed to an MRI-guided injection, the use of the MRI is limited by availability, time, and cost constraints.

This retrospective study confirms our hypothesis that a CT-guided injection using Botox is more effective for pain relief. In our study, 61% of injections with Botox led to a positive response while only 32% of injections without Botox led to a positive response, which meant a reduction in pain score of 50% within the first 24 hours after the injection, sustained response 48 hours later, and no increase in pain over the first 48 hours. A prior study has shown that CT-guided injection of the piriformis muscle with Botox improved pain in 35% of patients at 4 weeks and in 65% of at 8 weeks

Table 4. Response of the CT-guided piriformis muscle injection with or without Botox

	Without Botox (n=41), n (%)	With Botox (n=70), n (%)	p
First injection response			
Negative	8 (19.51)	12 (17.14)	0.005
Possible positive	20 (48.78)	15 (21.43)	
Positive	13 (31.71)	43 (61.43)	

**Figure 6.** Pain-free survival analysis comparing patients who received Botox to patients who did not receive Botox in the injection.

while there was no response in any of the patients who received only dexamethasone and lidocaine (18). In that study by Yoon et al. (18), the injection was directed solely to the piriformis muscle, and there was no injection to the perineural area of the sciatic nerve. Another study showed no difference in patients who received only local anesthetics versus local anesthetic plus corticosteroids (23). Fanucci et al. (6) showed a 87% rate of pain relief in patients with piriformis syndrome who received a CT-guided injection with Botox; however, they did not compare with patients who received an injection without Botox.

In our study, we showed that median pain-free survival for the non-Botox group was 1 day versus 30 days for the Botox group, a significant difference. Many other studies have shown sustained effects of Botox for many weeks after the piriformis muscle injection (6, 12, 18). Due to the retrospective nature of our study, many pa-

tients were lost after the 48 hours follow-up and did not return to clinic. We were unable to serially follow many patients and could only record their last follow-up results. In addition, chronic pain syndromes are multifactorial and since many of them had failed prior injections in clinic, these were complex patients and a psychological component cannot be denied. Comprehensive evaluation of psychological component in a prospective study could shed greater light on these patients with piriformis syndrome.

Some limitations of the study include its retrospective nature. The prescription of Botox was not randomized, which could have introduced potential confounders. While we were not able to identify any confounding variables through our data collection, it is still possible that they exist, so causation is not available. In addition, patients self-reported the response, so it is subject to reporting bias. The patients did have knowledge of whether Botox was ad-

ministered to them which can further bias the result. Our study can only draw correlations and will facilitate further prospective randomized blinded trials. Finally, piriformis syndrome is a multifactorial diagnosis and difficult to say with certainty that a patient has piriformis syndrome. Our diagnosis was based on clinical history, physical exam, and imaging findings.

In future, prospective randomized blind trials for patients with suspected piriformis syndrome could compare the pain response, range of motion and overall quality of life improvements to injections with and without Botox. There is a significant need to conduct this trial as piriformis syndrome is a debilitating disease greatly affecting patients' quality of life and ability to perform everyday activities. We hope that our study will facilitate future trials for piriformis syndrome.

Conflict of interest disclosure

The authors declared no conflicts of interest.

References

- Hopayian K, Song F, Riera R, Sambandan S. The clinical features of the piriformis syndrome: A systematic review. *Eur Spine J* 2010; 19:2095–2109. [Crossref]
- Miller TA, White KP, Ross DC. The diagnosis and management of piriformis syndrome: Myths and facts. *Can J Neurol Sci* 2012; 39:577–583. [Crossref]
- Cass SP. Piriformis syndrome: A cause of non-discogenic sciatica. *Curr Sports Med Rep* 2015; 14:41–44. [Crossref]
- Natsis K, Totlis T, Konstantinidis GA, Paraskevas G, Piagkou M, Koebeke J. Anatomical variations between the sciatic nerve and the piriformis muscle: A contribution to surgical anatomy in piriformis syndrome. *Surg Radiol Anat* 2014; 36:273–280. [Crossref]
- Hernando MF, Cerezal L, Perez-Carro L, Abascal F, Canga A. Deep gluteal syndrome: Anatomy, imaging, and management of sciatic nerve entrapments in the subgluteal space. *Skeletal Radiol* 2015; 44:919–934. [Crossref]
- Fanucci E, Masala S, Sodani G, et al. CT-guided injection of botulinic toxin for percutaneous therapy of piriformis muscle syndrome with preliminary MRI results about denervative process. *Eur Radiol* 2001; 11:2543–2548. [Crossref]
- Filler AG, Haynes J, Jordan SE, et al. Sciatica of nondisc origin and piriformis syndrome: Diagnosis by magnetic resonance neurography and interventional magnetic resonance imaging with outcome study of resulting treatment. *J Neurosurg Spine* 2005; 2:99–115. [Crossref]
- Delaney H, Bencardino J, Rosenberg ZS. Magnetic resonance neurography of the pelvis and lumbosacral plexus. *Neuroimaging Clin N Am* 2014; 24:127–150. [Crossref]
- Dessouky R, Xi Y, Scott KM, et al. Magnetic resonance neurography in chronic lumbosacral and pelvic pain: Diagnostic and management impact-institutional audit. *World Neurosurg* 2018; 114:e77–e113. [Crossref]

10. Petrasic JR, Chhabra A, Scott KM. Impact of mr neurography in patients with chronic cauda equina syndrome presenting as chronic pelvic pain and dysfunction. *AJNR Am J Neuroradiol* 2017; 38:418–422. [\[Crossref\]](#)
11. Kirschner JS, Foye PM, Cole JL. Piriformis syndrome, diagnosis and treatment. *Muscle Nerve* 2009; 40:10–18. [\[Crossref\]](#)
12. Benzon HT, Katz JA, Benzon HA, Iqbal MS. Piriformis syndrome: Anatomic considerations, a new injection technique, and a review of the literature. *Anesthesiology* 2003; 98:1442–1448. [\[Crossref\]](#)
13. Hanania M, Kitain E. Perisciatic injection of steroid for the treatment of sciatica due to piriformis syndrome. *Reg Anesth Pain Med* 1998; 23:223–228. [\[Crossref\]](#)
14. Soares A, Andriolo RB, Atallah AN, da Silva EM. Botulinum toxin for myofascial pain syndromes in adults. *Cochrane Database Syst Rev* 2014:CD007533. [\[Crossref\]](#)
15. Armstrong MW, Mountain RE, Murray JA. Treatment of facial synkinesis and facial asymmetry with botulinum toxin type a following facial nerve palsy. *Clin Otolaryngol Allied Sci* 1996; 21:15–20. [\[Crossref\]](#)
16. Santamato A, Micello MF, Valeno G, et al. Ultrasound-guided injection of botulinum toxin type a for piriformis muscle syndrome: A case report and review of the literature. *Toxins (Basel)* 2015; 7:3045–3056. [\[Crossref\]](#)
17. Fabregat G, Rosello M, Asensio-Samper JM, et al. Computer-tomographic verification of ultrasound-guided piriformis muscle injection: A feasibility study. *Pain Physician* 2014; 17:507–513.
18. Yoon SJ, Ho J, Kang HY, et al. Low-dose botulinum toxin type a for the treatment of refractory piriformis syndrome. *Pharmacotherapy* 2007; 27:657–665. [\[Crossref\]](#)
19. Wadhwa V, Scott KM, Rozen S, Starr AJ, Chhabra A. CT-guided perineural injections for chronic pelvic pain. *Radiographics* 2016; 36:1408–1425. [\[Crossref\]](#)
20. Giraudeau B, Rozenberg S, Valat JP. Assessment of the clinically relevant change in pain for patients with sciatica. *Ann Rheum Dis* 2004; 63:1180–1181. [\[Crossref\]](#)
21. Dessouky R, Khaleel M, Khalifa DN, Tantawy HI, Chhabra A. Magnetic resonance neurography of the lumbosacral plexus in failed back surgery syndrome. *Spine (Phila Pa 1976)* 2018; 43:839–847. [\[Crossref\]](#)
22. Hopayian K, Danielyan A. Four symptoms define the piriformis syndrome: An updated systematic review of its clinical features. *Eur J Orthop Surg Traumatol* 2018; 28:155–164. [\[Crossref\]](#)
23. Lewis AM, Layzer R, Engstrom JW, Barbaro NM, Chin CT. Magnetic resonance neurography in extraspinal sciatica. *Arch Neurol* 2006; 63:1469–1472. [\[Crossref\]](#)
24. Arooj S, Azeemuddin M. Piriformis syndrome—a rare cause of extraspinal sciatica. *J Pak Med Assoc* 2014; 64:949–951.