

Evaluation of lung volume loss with 3D CT volumetry in COVID-19 patients

Recep Savaş 

Ayşegül Öz Özcan 

From the Department of Radiology (R.S. ✉ receptasavas@gmail.com), Ege University Faculty of Medicine, İzmir, Turkey; Era Radyoloji Merkezi (A.Ö.Ö.), İzmir, Turkey.

Dear Editor,

The standard test for the assessment of coronavirus disease 2019 (COVID-19) is the reverse-transcription polymerase chain reaction (RT-PCR) testing. Chest computed tomography (CT) is recommended for severe cases as a complementary diagnostic tool for staging COVID-19 pneumonia in progressive disease or if any complication is suspected during the follow-up (1, 2).

Most common CT findings of COVID-19 pneumonia include multifocal and bilateral ground-glass opacities (GGOs) and/or consolidation in the peripheral, posterior, and lower lobes of the lungs. Halo or reverse halo sign, vascular enlargement, crazy-paving pattern, pleural thickenings, pleural effusion, and subpleural lines are less common CT findings (3, 4). In most cases, the disease and CT findings are mild and moderate and heal completely, but severe cases may develop acute respiratory distress syndrome or pulmonary fibrosis, and lung volume loss (5–7).

In particular, lung volume is determined by the elastic forces of the lung parenchyma and surrounding tissues, alveolar surface tension, respiratory muscle strength, lung reflexes, and airway structure (8). The etiology of lung volume loss can be listed as follows: airway obstruction or compression, obesity, scoliosis, restrictive diseases such as pulmonary fibrosis and interstitial lung disease, tuberculosis, sarcoidosis, pleural effusions, rib injury (fractures or diaphragm paralysis), and heart failure, among others (9). The volume loss findings in COVID-19 cases have begun to emerge with the recent literature data. Notably, consolidated and/or collapsed parts of the lungs lead to a reduction in lung volume, which is considered to be one of the pneumonic presentations of COVID-19 (10).

In our opinion, the loss of volume in patients with COVID-19 may be explained as follows: a) destruction of type II epithelial

cells by the virus resulting in a decrease of surfactant that keeps alveoli open; b) as part of the immune response, the blood vessels around the air sacs leak in response to the inflammatory chemicals released by white blood cells, and this fluid exerts pressure on the alveoli from the outside causing them to collapse; c) occurrence of microvascular thrombi, which have been detected as one of the lung autopsy findings in patients with COVID-19 (11). Inflammatory microthrombosis causes vasoconstriction in alveolar capillaries. While ventilation is normal in this region, perfusion deteriorates (ventilation/perfusion (V/Q) mismatch) and increases dead space ventilation. Consequently, reduced compliance causes alveolar collapse (11, 12). The etiology of the volume loss due to COVID-19 pneumonia, its clinical correlation, and its value in the prognosis need further evaluation.

We show an example of volume loss by analysis of lung volumes with follow-up CT scans in a patient with severe clinical findings in Figs. 1 and 2. We suggest that CT measurement of volume loss may provide objective data for both progression and long-term follow-up in COVID-19 patients. Three-dimensional (3D) CT lung volumetry method on the postprocessing workstation gives an estimate of the total lung volume using the CT density thresholds with mathematical algorithms that are available at the workstation. Although it is a very practical method, the most important limitation of 3D CT volumetry is that the volume of the scanned lung varies according to the amount of air inhaled before the scan, therefore, it is directly linked to the inspiratory capacity of the individual. However, patients may be provided with breathing training before the CT examination to minimize the variation (13). In our experience, it is possible to calculate 3D volume with standard or low-dose CT scan, but it is recommended to use the same breathing instruction protocols for the follow-up scans in order to achieve a high precision. Another important point for minimizing the lung volumetric errors is the choice of slice thickness of the CT scan protocol, which should be performed with 1 mm or thinner sections and spiral volume scanning.

In conclusion, we suggest that diseases that cause volume loss, including pulmonary fibrosis, which may develop in the follow-up of COVID-19, can be easily detected with 3D CT volumetry.

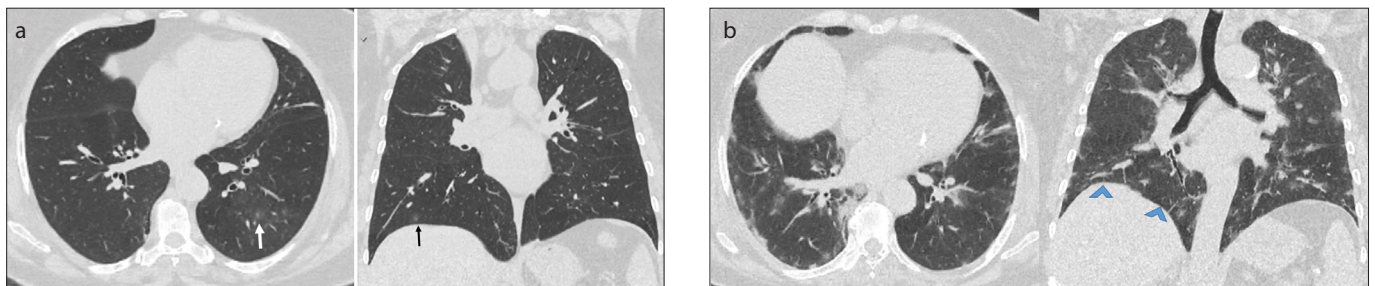


Figure 1. a, b. Lung CT of a COVID-19 patient. Axial and coronal multiplanar reconstruction images (a) show peripheral GGOs in the lower lobes of the lung (arrows). Two weeks later, axial and coronal multiplanar reconstruction images (b) of the same patient show that the disease has progressed. Peripheral GGOs are evident in the same lung zones of both lungs and the diaphragm is elevated due to the volume loss (arrowheads).

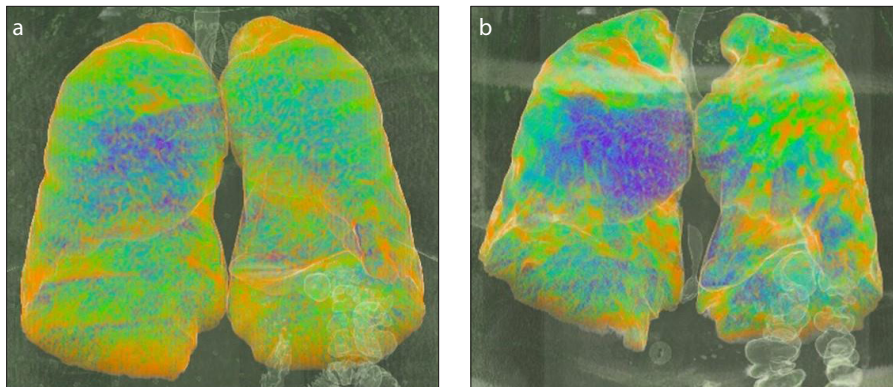


Figure 2. a, b. Three-dimensional volumetric chest CT images (a, b) show decrease in lung volume with the progression of pneumonia. On the first scan (a), total lung volume was 4352 cm³; on the follow-up scan (b) two weeks later, the volume was decreased to 2963 cm³.

Conflict of interest disclosure

The authors declared no conflicts of interest.

References

1. Rubin GD, Ryerson CJ, Haramati LB, et al. The role of chest imaging in patient management during the COVID-19 pandemic: a multinational consensus statement from the Fleischner Society. *Radiology*. 2020 Apr 7;201365. [Crossref]
2. <https://www.bsti.org.uk/standards-clinical-guidelines/clinical-guidelines/covid-19-bsti-statement-and-guidance/>.
3. Pan Y, Guan H, Zhou S, et al. Initial CT findings and temporal changes in patients with the novel coronavirus pneumonia (2019-nCoV): a study of 63 patients in Wuhan, China. *Eur Radiol* 2020 Feb 13. [Epub ahead of print] [Crossref]
4. Çinkooğlu A, Hepdurgun A, Bayraktaroğlu S, Ceylan N, Savaş R. CT imaging features of COVID-19 pneumonia: initial experience from Turkey. *Diagn Interv Radiol* 2020 Jun 19. [Epub ahead of print] [Crossref]
5. Albarello F, Pianura E, Di Stefano F, et al. 2019-novel coronavirus severe adult respiratory distress syndrome in two cases in Italy: an uncommon radiological presentation. *Int J Infect Dis* 2020; 93:192–197. [Crossref]
6. Spagnolo P, Balestro E, Aliberti S et al. Pulmonary fibrosis secondary to COVID-19: a call to arms? *Lancet Respir Med* 2020 May 15; S2213–2600(20)30222–8. [Epub ahead of print] [Crossref]
7. Sahetya SK, Goligher EC, Brower RG. Fifty years of research in ARDS. Setting positive end-expiratory pressure in acute respiratory distress syndrome. *Am J Respir Crit Care Med* 2017; 195:1429–1438. [Crossref]
8. <https://thoracickey.com/elastic-forces-and-lung-volumes/>
9. Lu Q, Rouby JJ. Measurement of pressure-volume curves in patients on mechanical ventilation: methods and significance. *Crit Care* 2000; 4:91–100. [Crossref]

10. Iwasawa T, Sato M, Yamaya T, et al. Ultra-high-resolution computed tomography can demonstrate alveolar collapse in novel coronavirus (COVID-19) pneumonia. *Jpn J Radiol* 2020; 38:394–398. [Crossref]
11. Deshpande C. Thromboembolic findings in COVID-19 autopsies: pulmonary thrombosis or embolism? *Ann Intern Med* 2020 May 6; M20-2003. [Epub ahead of print] [Crossref]
12. Mirastschijski U, Rolf Dembinski R and Kathrin Maedler K. Lung surfactant for pulmonary barrier restoration in patients with COVID-19 pneumonia. *Front Med* 2020; 7:254. [Crossref]
13. Jungmann F, Brodehl S, Buhl R. Workflow-centred open-source fully automated lung volumetry in chest CT. *Clin Radiol* 2020; 75:78.e1–78.e7. [Crossref]

Received 16 June 2020; revision requested 27 June 2020; last revision received 9 July 2020; accepted 16 July 2020.

Published online 31 August 2020.

DOI 10.5152/dir.2020.20451

You may cite this article as: Savaş R, Öz Özcan A. Evaluation of lung volume loss with 3D CT volumetry in COVID-19 patients. *Diagn Interv Radiol* 2021; 27: 155-156.