



Since January 2020 Elsevier has created a COVID-19 resource centre with free information in English and Mandarin on the novel coronavirus COVID-19. The COVID-19 resource centre is hosted on Elsevier Connect, the company's public news and information website.

Elsevier hereby grants permission to make all its COVID-19-related research that is available on the COVID-19 resource centre - including this research content - immediately available in PubMed Central and other publicly funded repositories, such as the WHO COVID database with rights for unrestricted research re-use and analyses in any form or by any means with acknowledgement of the original source. These permissions are granted for free by Elsevier for as long as the COVID-19 resource centre remains active.

Atypical Takotsubo Cardiomyopathy in COVID-19

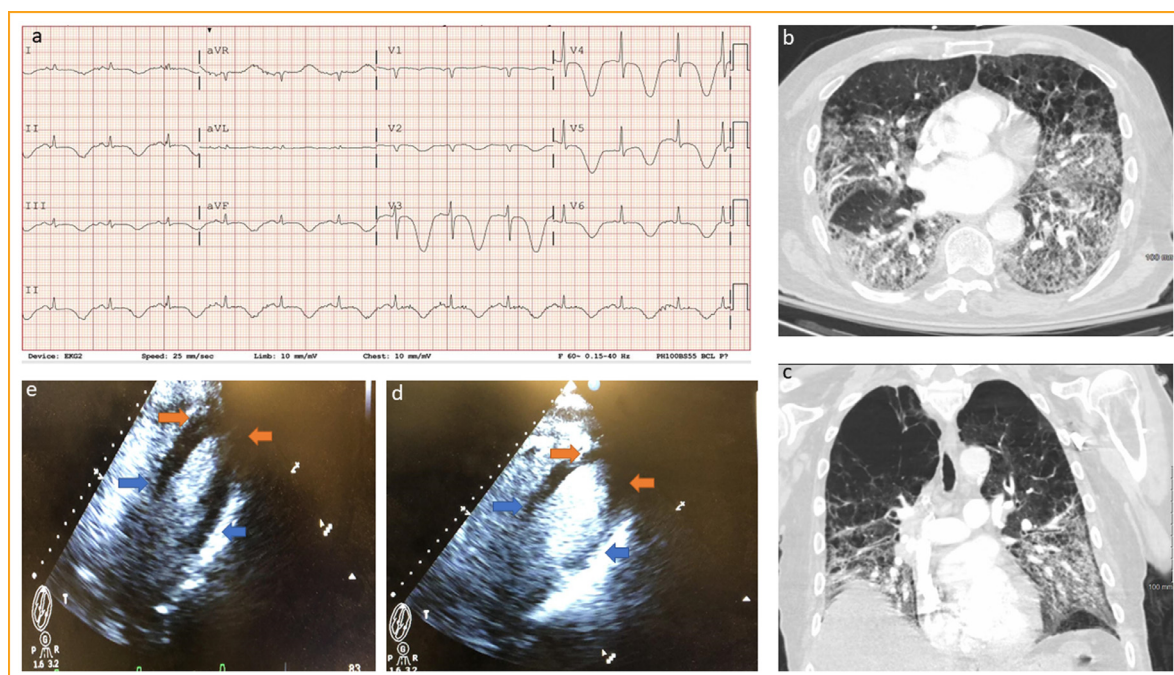


Ajay Kumar Mishra, MD^{1,*}, Qiying Dai, MD, FACC²,
Kamal Kant Sahu, MD¹ and Amr EIMeligy, MD, FACC²

¹Department of Internal Medicine, St Vincent Hospital, Worcester, MA, USA; ²Division of Cardiovascular Medicine, St Vincent Hospital, Worcester, MA, USA *(E-mail: Ajay.Mishra@stvincenthospital.com).

Declaration of Competing Interest: Authors have no conflicts of interest to declare.

Funding: None



FIGURE

A 70-year-old man with hypertension; hyperlipidemia, type 2 diabetes, chronic obstructive pulmonary disease, atrial fibrillation, status post cardioversion, and ablation, currently in sinus rhythm, presented to the hospital with insidious onset, gradually progressive shortness of breath, and a low-grade, intermittent fever of one-week duration. On the day of the presentation, he was in moderate respiratory distress. His oxygen saturation was 85% on supplemental O₂ at 6 l/min. Initial vital signs were blood pressure of 146/64 mmHg, respiratory rate of 28/minute, and pulse rate of 88/minute. Respiratory exam demonstrated reduced breath sounds bilaterally, along with mild infrascapular crackles. The electrocardiogram showed new onset T wave inversion across V1 to V6

[Figure 1a]. Chest imaging showed bilateral ground glass opacities and infiltrates. [Figure 1b, 1c].

Echocardiography showed hypokinesis of the basal region of the left ventricle with hyperkinesis of the apical

region of the left ventricle consistent with a reverse Takotsubo cardiomyopathy [Figure 1d, 1e]. A diagnosis of COVID-19 was made on the basis of polymerase chain reaction (PCR) testing. The patient's clinical condition deteriorated over the next two days, and the patient eventually succumbed to COVID-19.

Takotsubo cardiomyopathy (also known as broken heart syndrome, transient apical ballooning syndrome, and stress cardiomyopathy) is a form of reversible cardiomyopathy. It mimics the clinical syndrome of acute myocardial infarction in the absence of coronary artery stenosis or spasm. It derives its name from the Japanese octopus fishing pot called 'takotsubo' to which the involved heart resembles in shape. This syndrome is most commonly seen in postmenopausal women in the presence of extreme physical or emotional stress. It is diagnosed with a typical finding of transient, reversible apical hypokinesia and associated basal hyperkinesia. Reverse Takotsubo cardiomyopathy is its variant

characterized by reversible, basal akinesia/hypokinesia and associated apical hyperkinesia.¹

Patients with severe COVID-19 disease most commonly present with the involvement of the respiratory system. Cardiovascular involvement, including acute myocardial injury and stress-induced cardiomyopathy, has also been commonly reported in 5% of these patients.² To date, 9 patients with stress-induced cardiomyopathy secondary to COVID-19 have been reported.^{1,3} We report the first male patient with reverse Takotsubo cardiomyopathy secondary to COVID-19 infection. The physiologic cause of this broken heart syndrome could either have been

the initial stress of acute lung injury from COVID-19 or subsequent deterioration secondary to cytokine storm.

REFERENCES

1. **Sala S, Peretto G, Gramegna M, et al.** Acute myocarditis presenting as a reverse Tako-Tsubo syndrome in a patient with SARS-CoV-2 respiratory infection. *Eur Heart J.* 2020;41(19):1861–1862.
2. **Mishra AK, Sahu KK, George AA, et al.** A review of cardiac manifestations and predictors of outcome in patients with COVID-19 [e-pub ahead of print]. *Heart Lung.* 2020. <https://doi.org/10.1016/j.hrtlng.2020.04.019>, accessed August 20, 2021.
3. **Pasqualetto MC, Secco E, Nizzetto M, et al.** Stress cardiomyopathy in COVID-19 disease. *Eur J Case Rep Intern Med.* 2020;7:(6) 001718. https://doi.org/10.12890/2020_001718.