

## CASE REPORTS

# TECPR2 mutation–associated respiratory dysregulation: more than central apnea

Pallavi P. Patwari, MD<sup>1</sup>; Lisa F. Wolfe, MD<sup>2</sup>; Girish D. Sharma, MD<sup>1</sup>; Elizabeth Berry-Kravis, MD, PhD<sup>1</sup>

<sup>1</sup>Rush University Children's Hospital, Rush University Medical Center, Chicago, Illinois; <sup>2</sup>Northwestern University, Northwestern Memorial Hospital, Chicago, Illinois

Children with rare genetic diseases that cause respiratory dysregulation are at particularly high mortality risk due to development of respiratory failure. The tectonin  $\beta$ -propeller–containing protein 2 (*TECPR2*) mutations are proposed to cause autophagy defect affecting axonal integrity and development of progressive neurodegenerative and neuromuscular disease. Published *TECPR2* mutation cases have described a high prevalence of respiratory failure. We review respiratory pathology in previously published cases and a new case of a 5-year-old girl with previously undescribed *TECPR2* mutation demonstrating progressive central apnea due to respiratory cycle dysregulation. This is the first *TECPR2* mutation case to demonstrate an ataxic (Biot's) breathing pattern with consistently inconsistent inspiratory and expiratory times and with relatively intact chemoreception during sleep. Therefore, we propose that the central apnea index alone may not be the appropriate marker for mortality risk. Rather, the morbidity and mortality associated with *TECPR2* mutations are multisystem in nature and this burden complicates the ultimate needs for ventilation support and prognosis.

**Keywords:** central apnea, circadian rhythm disturbance, Biot's breathing, ataxic breathing, respiratory and autonomic dysregulation

**Citation:** Patwari PP, Wolfe LF, Sharma GD, Berry-Kravis E. *TECPR2* mutation–associated respiratory dysregulation: more than central apnea. *J Clin Sleep Med.* 2020;16(6):977–982.

## INTRODUCTION

Children affected by rare genetic diseases that cause respiratory and autonomic dysregulation are at particularly high mortality risk due to development of respiratory failure. Therefore, close attention to the respiratory phenotype is essential. Rare genetic disorders with altered control of breathing include Rett syndrome, Joubert syndrome, familial dysautonomia (aka hereditary sensory and autonomic neuropathy type 3),<sup>1</sup> central congenital hypoventilation syndrome, rapid-onset obesity with hypothalamic dysfunction, hypoventilation and autonomic dysregulation,<sup>2</sup> and Prader-Willi syndrome. Hereditary sensory autonomic neuropathies (HSANs), which also have partial overlap with hereditary spastic paraplegia (HSP), have a broad phenotypic spectrum and have generally not included respiratory pathology as a primary concern. One relatively recently proposed subtype of HSAN involves mutation of tectonin  $\beta$ -propeller–containing protein 2 (*TECPR2*).<sup>3</sup> The *TECPR2* mutations have also been included as a subtype 49 of familial spastic paraplegia (SPG49).<sup>4</sup> While the respiratory phenotype has been described as progressive central apnea (CA), our case is the first to demonstrate an ataxic (Biot's) breathing pattern with relatively intact chemoreception during sleep.

Control of breathing is a complex process that involves input and output from central and peripheral signals (Figure 1). Chemoreception based on partial pressures of oxygen and carbon dioxide values will send signals to the controller/integration area (central pattern generator) of the brainstem that will then send signals to affect motor response to adjust minute ventilation.<sup>5</sup> The differences in respiratory pattern based on state can be attributed to absence or presence of other neuromodulatory factors. Dissection of

control of breathing networks becomes more difficult as there are layers of redundancy as fail-safes to ensure life-sustaining gas exchange, such that respiratory load meets physiologic demand. In pathologic conditions, respiratory insufficiency may only become apparent with a change of state (exercise, resting, awake, versus sleep) or with acute challenge (pneumonia, sepsis, sedation). This failure of respiratory regulation often overlaps with other components of autonomic nervous system dysregulation.

Limited information exists regarding the respiratory phenotype for individuals affected by *TECPR2* mutations (Table 1). The majority of cases are affected by hypotonia, progressive CA, and recurrent pulmonary infections with mortality due to respiratory failure.<sup>3,6–8</sup> Therefore, attention to respiratory status and progression is paramount. We present the first detailed evaluation of respiratory dysregulation and progression in a child with *TECPR2* mutations.

## REPORT OF CASE

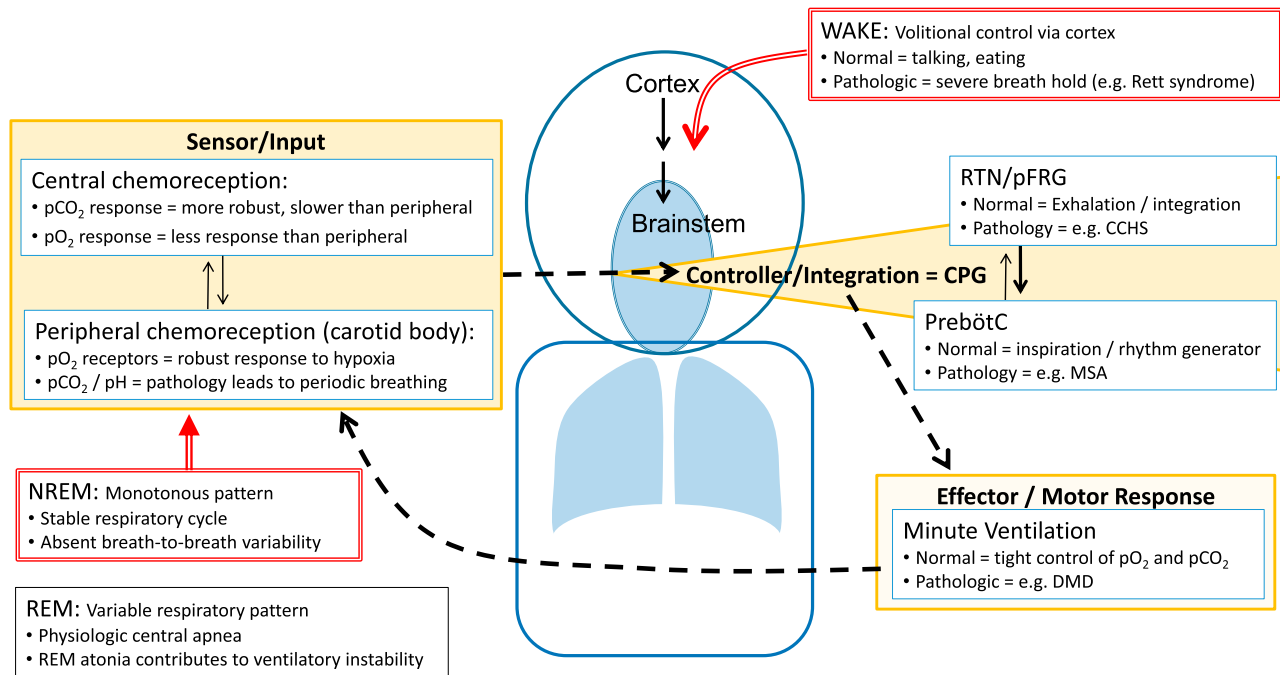
### Birth and family history

The patient was born full term after an unremarkable pregnancy and newborn course. The mother has hypothyroidism, the father has Crohn's disease, and 2 younger siblings are healthy.

### Presentation

The patient was noted to have hypotonia around 5–6 months of age and subsequent mild gross motor delays that included pulling to stand at 11 months, crawling at 16 months, and walking at 22 months of age. She was prescribed glasses by 16 months of age for strabismus. She received appropriate therapies

**Figure 1**—Simplified pathway for respiratory control.



In the midbrain, the pre-Bötzinger complex is considered the pacemaker responsible for rhythm generation (setting breathing frequency) and a proposed pattern generator is responsible for the respiratory cycle (duration of breath and tidal volume); together, this is referred to as the CPG. Input to the CPG comes from central chemoreceptors (in response to hypercarbia), peripheral chemoreceptors (in response to hypoxia), and other peripheral sensory receptors. The integration of this input also occurs at multiple levels. The output then drives the motor response that manifests as minute ventilation (alveolar ventilation). To further fine-tune control of breathing, multiple feedback loops are simultaneously in play, of which some are well established (chemoreflex or loop gain) and others are yet to be defined. During wakefulness, simplistically, volitional control of breathing can override CPG to allow for speaking and eating (although, in normal conditions, also maintaining appropriate gas exchange). During NREM sleep, breathing drive is predominantly influenced by chemoreception and absent behavioral influences, resulting in a stable (monotonous) respiratory pattern. CCHS = congenital central hypoventilation syndrome; CPG = central pattern generator; DMD = Duchenne muscular dystrophy; MSA = multiple system atrophy; NREM = non-rapid eye movement; pCO<sub>2</sub> = partial pressure of carbon dioxide; pFRG = parafacial respiratory group; pO<sub>2</sub> = partial pressure of oxygen; PreBötC = pre-Bötzinger complex; REM = rapid eye movement; RTN = retrotrapezoid nucleus.

for motor and speech/language delay. The initial neurology evaluation at 23 months of age included magnetic resonance imaging of the brain, which showed scattered areas of relative T2 hyperintensity predominantly in the peri-atrial and subcortical white matter, read as nonspecific gliosis with suspicion for myoneural disorder causing hypotonia. Dysphagia was found on a swallow study at 2.5 years of age with improvement with paced eating. The patient was also noted to have possible signs of autonomic dysregulation, such as photophobia (without an overt pupil abnormality), decreased pain sensitivity, and chronic constipation. She was also noted to have hand flapping without other rhythmic/repetitive behaviors. Video electroencephalography at 34 months of age demonstrated mild background slowing and excess fast activity diffusely, rare bursts of delta activity, and multifocal epileptiform discharges without clinical correlate. The patient showed slow progress of motor and language development. By 3.5 years of age, she was able to speak about 50 words but had articulation difficulties that made her difficult to understand. By 5 years of age, she was treated with intensive cognitive-behavioral therapy. She has had no clinical seizures.

**Physical examination**

At 4 years of age, height and weight were at the fifth percentile for age. The patient was very social, with appropriate eye contact,

and engaging (excessively friendly). She was normocephalic without dysmorphic features. She had prominent strabismus with difficulty abducting either eye. Cardiac examination revealed normal heart sounds without murmurs and appropriate peripheral perfusion. Lungs were clear to auscultation with regular respiratory pattern (no breath-holding or hyperpneic episodes). The abdomen was soft without organomegaly. The neurologic examination including cranial nerves, motor tone and strength, deep tendon reflexes, sensory examination, and cerebellar functions was unremarkable with the exception of low axial tone and motor coordinational immaturity with a poorly coordinated gait and foot pronation and eversion. The patient showed near-constant activity requiring frequent redirection by her parents.

**Genetic testing**

At 3.5 years of age, she had whole-exome sequencing and was found to be a compound heterozygote for pathogenic mutations in *TECPR2* anticipated to result in large protein truncation (Table 1).

**Respiratory course**

The patient had lingual frenulectomy at 6 weeks of age (reportedly to facilitate feeding). At 28 months, adenoidectomy

**Table 1**—Summary of reported *TECPR2* mutations and associated phenotype.

Case	Mutation	Presentation	Neuro/Ophth	Autonomic	Behavior	Sleep	Respiratory
1–5 (Oz-Levi 2012) <sup>6</sup>	c.3416delT (frameshift, p.Leu1139Argfs*75)	Hypotonia and developmental delay at 2 years old	Developmental delay, motor delay, hypotonia. In 4 of 5 who walked, later developed spastic rigid ataxic gait. Areflexia. Four of 5 with episodes of decreased alertness with exacerbation of hypotonia. One with transient severe encephalopathy.	—	Friendly disposition	—	Recurrent pulmonary infections. Severe CA initially during sleep, later evolving to wake state. Four of 5 required MV (3 with spontaneous remission, 1 with chronic MV at 20 years). PSG with CAs (>90/h) and hypoxia.
	Homozygous						
	4 of 5 with genetic testing						
	Premature truncation of protein						
6 (Heimer 2015) <sup>3</sup>	p.Leu440/p.Thr1891le	Developmental delay, GERD	Hypotonia, decreased reflexes, global developmental delay, astigmatism, myopia	Decreased pain sensitivity, delayed gastric emptying	Cheerful, hyperactive	Frequent arousals at 9 months	Postoperative ARDS, breath holding, PSG at 4 years with AHI 12 events/h, SpO <sub>2</sub> nadir 80%, ETCO <sub>2</sub> peak 55 mmHg, pneumonia and shock at 6 years leading to death
7 (Heimer 2015) <sup>3</sup>	p.Leu440/p.Leu440Arfs*19	Floppy infant, dysphagia, and GERD	Developmental delay, areflexia, abrupt somnia with EEG encephalopathy, esotropia, ataxic gait	Decreased pain sensitivity, temperature dysregulation, episodes of bradycardia with hypertension, sodium/ water dysregulation	Friendly, violent mood changes	Arousals on PSG	Tonsillectomy, recurrent aspiration and pneumonia, chronic lung disease, tracheostomy with mechanical ventilator, “apnea” with elevated CO <sub>2</sub> (>100 mmHg).
8 (Heimer 2015) <sup>3</sup>	p.Leu440/p.Leu1139Arfs*75	Dysphagia and GERD in infancy	Developmental delay, areflexia, axial hypotonia	Decreased pain sensitivity, temperature dysregulation, postural hypotension, sodium/ water dysregulation	Apathy alternating with restlessness and hyperactivity	Recurrent awakenings	Aspiration, desaturation, recurrent intubation, CA
9 (Covone 2016) <sup>8</sup>	p.Leu684Val/p.Thr903Met	Gait instability at 4 years	Normal intelligence, brisk reflexes at knee and upper extremities, areflexia at ankles, muscle atrophy, strabismus, ocular apraxia	—	—	—	Respiratory failure at 13 years of age, tracheostomy and mechanical ventilator
	Compound heterozygous missense mutation						

(continued on following page)

**Table 1**—Summary of reported *TECPR2* mutations and associated phenotype. (continued)

Case	Mutation	Presentation	Neuro/Ophth	Autonomic	Behavior	Sleep	Respiratory
10 (Zhu 2015) <sup>7</sup>	p.Leu440ArgfsTer19	—	Developmental delay, areflexia, severe hypotonia	—	—	—	“Breathing abnormalities”
	Homozygous						
	Frameshift mutation						
11 (CASE)	p.D259MfsX44c.774delA	Hypotonia at 6 months	Developmental delay, low axial tone, motor coordination immaturity, strabismus	Photophobia, decreased pain sensitivity, chronic constipation	Friendly, hyperactive	Circadian disturbance with advanced sleep phase	Progressive CA, Biot’s breathing
	p.K343RfsX2c.1028_1032delAAGGA						
	Compound heterozygous mutation						
	Large truncation of the protein						

AHI = apnea-hypopnea index; ARDS = acute respiratory distress syndrome; CA = central apnea; EEG, electroencephalogram; ETCO<sub>2</sub> = end-tidal carbon dioxide; GERD = gastroesophageal reflux disease; MV = mechanical ventilation; PSG = polysomnogram; SpO<sub>2</sub> = oxygen saturation; *TECPR2*, tectonin β-propeller-containing protein 2.

**Table 2**—Summary of polysomnographic findings by age.

	Age at Study			
	2 Years, 8 Months	3 Years, 9 Months	4 Years, 7 Months	5 Years
TST, minutes	363.5	314.5	308.5	410.5
Sleep efficiency, %	70	65.9	64.7	78.2
AHI, events/h	9.3	36.4	55.2	45.7
REM AHI, events/h	23.6	9.1	44.4	30.5
Obstructive AHI, events/h	?	9.9	1.4	3.2
Obstructive apnea index, events/h	0	0	0	0
Central apnea index, events/h	?	13.7	47.1	28.9
*Hypopneas (obstructive + central), count of events	57	52 + 67	7 + 35	22 + 93
SpO <sub>2</sub> nadir, %	85	83	89	89
SpO <sub>2</sub> <90%, minutes	1.2	7.9	1.9	0.5
ETCO <sub>2</sub> average, peak, mmHg	38, 46	36, 48	37, 48	41, 54
Average RR, breaths/minute	8–14	8–14	6–10	6–10

\*Hypopnea events are listed as total count. In this case of central respiratory dysregulation and in the absence of scoring criteria for Biot’s breathing, the apnea-hypopnea indices are not necessarily meaningful markers of disease severity or progression. AHI = apnea-hypopnea index; ETCO<sub>2</sub> = end-tidal carbon dioxide; REM = rapid eye movement; RR = respiratory rate; SpO<sub>2</sub> = oxygen saturation; TST = total sleep time.

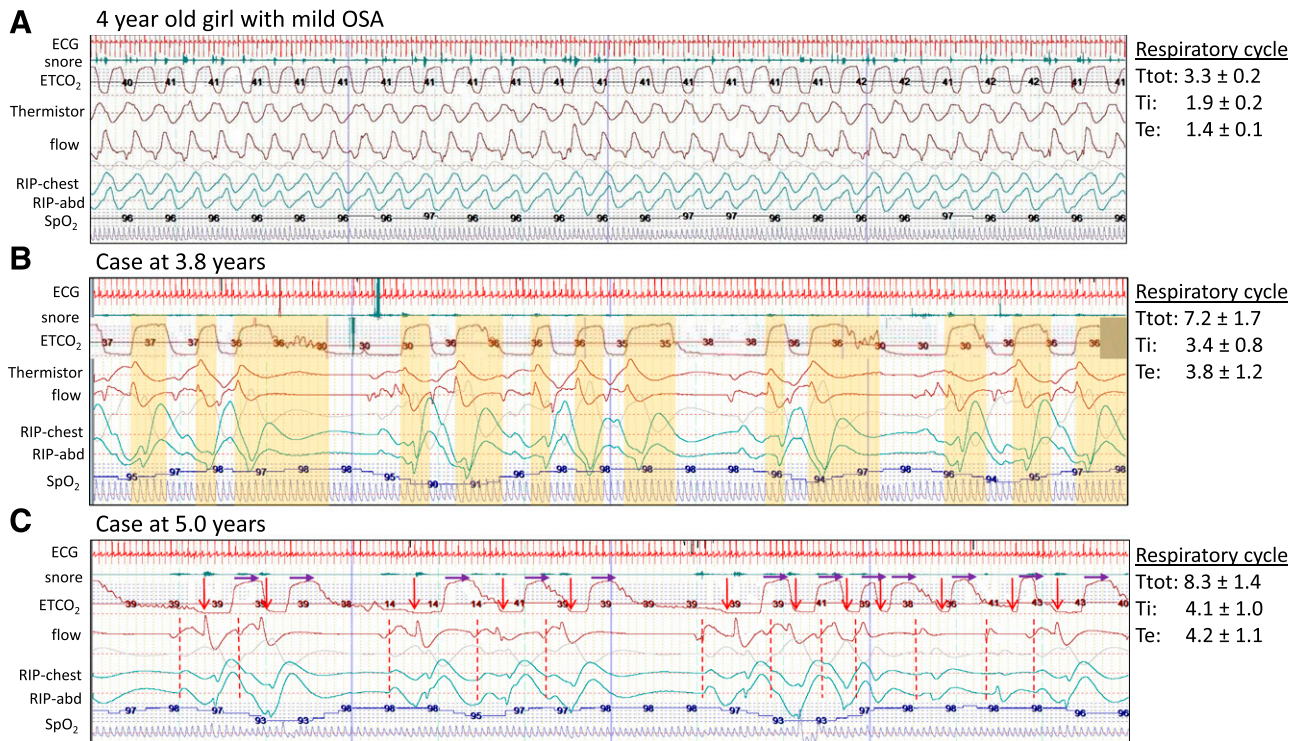
was performed due to report of snoring without apnea and difficulty sleeping. She had subsequent improvement in snoring, restless sleep, and speech (although continued with advanced sleep phase and fragmented sleep). Due to the persistence of occasional snoring, frequent arousals, and increased irritability, her first polysomnogram was completed at 32 months of age to evaluate for residual obstructive sleep apnea. This was reported to show “a complex respiratory pattern consisting of expiratory hypopneas, central appearing apneas, and questionable apneustic breathing.” On repeat polysomnograms (Table 2), the obstructive component improved, CA progressed, and Biot’s pattern persisted (Figure 2). Furthermore, decreased heart rate variability was noted on review of a Poincaré plot indicating progression of autonomic dysregulation. Noninvasive ventilation (NIV) was well tolerated during the titration study and for at least 1 week at home; then, the patient developed significant resistance to continued use of NIV despite desensitization attempts, which has been attributed to behavioral and sensory issues. Her continued

difficulty with tolerance has been attributed to behavior and sensory issues. Sleep endoscopy at 4.3 years of age demonstrated absence of airway obstruction. Notable CAs were observed during sedation by the pediatric anesthesiologist requiring prolonged postprocedure observation. By 5 years of age, the patient continues without NIV support.

**DISCUSSION**

This is the first detailed report of the evolving respiratory changes in a patient with *TECPR2* mutations including the unique pattern of breathing. Specifically, the “central sleep apnea” found with ataxic breathing is distinct from periodic breathing, Cheyne-Stokes breathing, postarousal respiratory events, and apneustic breathing and not necessarily associated with hypoventilation. Both periodic breathing and Cheyne-Stokes breathing pattern include alternating episodes of hyperpnea followed by apnea (Cheyne-Stokes



**Figure 2**—Polysomnogram demonstrating respiratory cycle variability in NREM sleep.

Images are of a 2-minute segment from baseline polysomnogram comparing an age-matched, relatively healthy child with the patient at 3.8 years and 5 years of age. The respiratory cycle values to the right note the average and standard deviation of total cycle time, inspiratory time, and expiratory time for the breaths in the first 30 seconds of the 2-minute segment. **(A)** A 4-year-old girl with mild pediatric OSA. Note the normal (monotonous) respiratory pattern and stable respiratory cycle times. **(B)** Our patient at 3.8 years of age. The ETCO<sub>2</sub> waveform is manually shifted 3 seconds earlier to account for recording delay compared to flow and respiratory effort bands (RIP). The vertical yellow bars indicate the expiratory component of each respiratory cycle. Note the wide variability and absent pattern. **(C)** Our patient at 5 years of age. The start of inhalation is noted by a red arrow and dashed line. The purple arrows are of fixed length and indicate the start of exhalation. Again, note the absence of distinct pattern and wide variability in both inspiratory time and expiratory time with slower respiratory rate at 6–10 breaths per minute. ETCO<sub>2</sub> = end-tidal carbon dioxide; NREM = non-rapid eye movement; OSA = obstructive sleep apnea; RIP = respiratory inductance plethysmography.

with a characteristic crescendo-decrescendo pattern between apneic periods). Postarousal respiratory events are of questionable clinical relevance.<sup>9</sup> The characteristic feature of apneustic breathing is a gasp with inspiratory hold that is classically found with injury to the pons. Another form of erratic breathing is Biot's breathing, which is characterized by irregular cycles of breathing without distinct clusters of breathing,<sup>10</sup> such as is found with this case and as demonstrated by waveforms recorded during baseline polysomnograms (**Figure 2**).

*TECPR2* encodes a 1411-amino acid protein with 3 WD<sup>11</sup> (tryptophan-aspartic acid) repeat domains located at the N-terminal region of the protein and 6 *TECPR* domains concentrated around amino acid 1000 and 1250. The p.Leu1139Argfs, which has already been demonstrated as pathogenic,<sup>12</sup> would result in a loss of 4 out of 6 *TECPR* domains. The p.D259MfsX44 and *TECPR2* p.K343RfsX2 mutations in this patient would be expected to cause a large truncation of the protein and loss of all 6 *TECPR* domains, leading to non-sense-mediated decay, as would be expected for multiple other mutations described in previous patients with *TECPR2* mutations (**Table 1**), and these are expected to function as null mutations. The null mutations in *TECPR2* have been linked to abnormalities of autophagy with decreased accumulation of the autophagy initiation protein

MAP1LCII/LC3II and attenuation of activity of both LC3II and the cargo recruiting protein SQSTM1/p62 in patient fibroblasts.<sup>13</sup> An autophagy defect was proposed to affect axonal integrity and function in the nervous system through secondary effects on endoplasmic reticulum shaping, endosomal trafficking and microtubule stability,<sup>3</sup> although definitive identification of specific mechanisms involved in *TECPR2* deficiency has not been clarified.

In general, a disruption in cellular autophagy is particularly devastating to neurons and has been shown to cause progressive neurodegenerative and neuromuscular disease (lysosomal storage diseases, Huntington disease, amyotrophic lateral sclerosis) with a wide phenotypic spectrum. With *TECPR2* mutations, neuromuscular dysfunction appears to be a key feature in all reported cases based on hypotonia and recurrent pneumonia. In this case, there is altered respiratory cycle timing (Biot's breathing pattern) while maintaining sufficient ventilatory response to maintain normal oxygen saturation and carbon dioxide values (intact chemoreception). Hypoventilation appears to be a component of previously reported cases based on development of hypoxia and need for chronic mechanical ventilation.

The respiratory management of this patient is in line with standard of care for patients with neuromuscular weakness,

requiring aggressive airway clearance, screening for dysphagia and aspiration, repeated polysomnograms (with end-tidal carbon dioxide monitoring to provide breath-to-breath waveform and values to identify prolonged exhalations and hypoventilation) to track progression, and institution of supported ventilation at the first signs of hypoventilation. In this case, the CA index alone may not be the appropriate marker for mortality risk. Rather, mortality is more likely due to the multisystem nature of the disease, which complicates the ultimate needs for ventilation support. Therefore, the CA index and total apnea-hypopnea index do not predict the need for supported ventilation.

Future studies should examine genotype–phenotype relationships in patients with *TECPR2* mutations with respect to respiratory functioning, so that the potential effects of these patients' mutations can be used to identify high-risk patients. In addition to implementation of appropriate treatment strategies due to respiratory dysfunction, further clarification of *TECPR2* cellular pathways is needed to design mechanism-based treatments.

## ABBREVIATIONS

CA, central apnea  
 HSNAN, hereditary sensory autonomic neuropathy  
 HSP, hereditary spastic paraplegia  
*TECPR2*, tectonin  $\beta$ -propeller-containing protein 2

## REFERENCES

- Palma J-A, Gileles-Hillel A, Norcliffe-Kaufmann L, Kaufmann H. Chemoreflex failure and sleep-disordered breathing in familial dysautonomia: implications for sudden death during sleep. *Auton Neurosci*. 2019;218:10–15.
- Patwari PP, Wolfe LF. Rapid-onset obesity with hypothalamic dysfunction, hypoventilation, and autonomic dysregulation: review and update. *Curr Opin Pediatr*. 2014;26(4):487–492.
- Heimer G, Oz-Levi D, Eyal E, et al. *TECPR2* mutations cause a new subtype of familial dysautonomia like hereditary sensory autonomic neuropathy with intellectual disability. *Eur J Paediatr Neurol*. 2016;20(1):69–79.
- Spastic Paraplegia 49, Autosomal Recessive; SPG49, OMIM®. Johns Hopkins University, Baltimore, MD. MIM Number: 615031. <https://omim.org/>. Updated February 9, 2018. Accessed November 27, 2019.

- Ramirez JM, Baertsch N. Defining the rhythmogenic elements of mammalian breathing. *Physiology*. 2018;33:302–316.
- Oz-Levi D, Ben-Seev B, Ruzzo EK, et al. Mutation in *TECPR2* reveals a role for autophagy in hereditary spastic paraparesis. *Am J Hum Genet*. 2012;91(6):1065–1072.
- Zhu X, Petrovski S, Xie P, et al. Whole-exome sequencing in undiagnosed genetic disease: interpreting 119 trios. *Genet Med*. 2015;17(10):774–781.
- Covone AE, Fiorillo C, Acquaviva M, et al. WES in a family trio suggests involvement of *TECPR2* in a complex form of progressive motor neuron disease. *Clin Genet*. 2016;90(2):182–185.
- Haupt ME, Goodman DM, Sheldon SH. Sleep related expiratory obstructive apnea in children. *J Clin Sleep Med*. 2012;8(6):673–679.
- Wijdicks EFM. Biot's breathing. *J Neurol Neurosurg Psychiatry*. 2007;78(5):512–513.
- WD Repeats. In: Schwab M, ed. *Encyclopedia of Cancer*. Berlin, Heidelberg: Springer; 2011.
- Oz-Levi D, Gelman A, Elazar Z, Lancet D. *TECPR2*: a new autophagy link for neurodegeneration. *Autophagy*. 2013;9(5):801–802.
- Stadel D, Millarte V, Tillmann KD, et al. *TECPR2* cooperates with LC3C to regulate COPII-Dependent ER export. *Mol Cell*. 2015;60(1):89–104.

## ACKNOWLEDGMENTS

Author contributions: Drs. Patwari and Berry-Kravis conceptualized and drafted the initial manuscript, contributed to data collection and data analysis, and revised the manuscript. Drs. Wolfe and Sharma contributed to data interpretation, critically reviewed the manuscript for important intellectual content, and reviewed and revised the manuscript.

## SUBMISSION & CORRESPONDENCE INFORMATION

Submitted for publication November 27, 2019

Submitted in final revised form March 9, 2020

Accepted for publication March 19, 2020

Address correspondence to: Pallavi P. Patwari, MD, Department of Pediatrics, Rush University Children's Hospital, 1620 West Harrison Street, Chicago, IL 60612; Tel: (312) 942-3034; Fax: (312)942-3193; Email: pallavi\_patwari@rush.edu

## DISCLOSURE STATEMENT

All authors approved the final manuscript as submitted and agree to be accountable for all aspects of the work. The patient's parents provided written consent to publication of this de-identified case report. The authors report no conflicts of interest.