

Low PRRX1 expression and high ZEB1 expression are significantly correlated with epithelial-mesenchymal transition and tumor angiogenesis in non-small cell lung cancer

Ruixue Yang, MD^{a,b}, Yuanqun Liu, MD^{a,b}, Yufei Wang, MD^{a,b}, Xiaolin Wang, MD^{a,b}, Hongfei Ci, MD^{a,b}, Chao Song, MD^c, Shiwu Wu, MD^{a,b,*}

Abstract

Background: Paired related homeobox 1 (PRRX1) and zinc finger E-box binding homeobox 1 (ZEB1) have been observed to play a vital role in the epithelial-mesenchymal transition (EMT) process in different types of cancer. The microvessel density (MVD) is the most common indicator used to quantify angiogenesis. This study aimed to investigate expression of PRRX1 and ZEB1 in non-small cell lung cancer (NSCLC) and to explore associations between these factors and tumor prognosis, EMT markers and angiogenesis.

Methods: Data for a total of 111 surgically resected NSCLC cases from January 2013 to December 2014 were collected. We used an immunohistochemical method to detect expression levels of PRRX1, ZEB1, and E-cadherin, and to assess MVD (marked by CD34 staining). SPSS 26.0 was employed to evaluate the connection between these factors and clinical and histopathological features, overall survival (OS) and tumor angiogenesis.

Results: PRRX1 expression was obviously lower in tumor samples than in control samples. Low expression of PRRX1, which was more common in the high-MVD group than in the low-MVD group ($P = .009$), correlated positively with E-cadherin expression ($P < .001$). Additionally, we showed that ZEB1 was expressed at higher levels in tumor samples than in normal samples. High expression of ZEB1 was associated negatively with E-cadherin expression ($P < .001$) and positively associated with high MVD ($P = .001$). Based on Kaplan-Meier and multivariate survival analyses, we found that PRRX1, ZEB1, E-cadherin and the MVD had predictive value for OS in NSCLC patients.

Conclusions: These findings suggest that PRRX1 and ZEB1 may serve as novel prognostic biomarkers and potential therapeutic targets.

Abbreviations: AJCC = American Joint Committee on Cancer, DM = distant metastasis, EMT = Epithelial-mesenchymal transition, KM = Kaplan-Meier, LNM = lymph node metastasis, MVD = microvessel density, NSCLC = non-small cell lung cancer, OS = overall survival, PBS = phosphate buffered saline, PRRX1 = paired related homeobox 1, TNM = tumor-node-metastasis, WHO = World Health Organization, ZEB1 = zinc finger E-box binding homeobox 1.

Keywords: EMT, MVD, NSCLC, PRRX1, tumor angiogenesis, ZEB1

Editor: Lanjing Zhang.

RY, YL, and YM contributed equally to this work.

The study was approved by the ethics committee of the First Affiliated Hospital of Bengbu Medical College (2020KY035), and the informed consents had been obtained from all patients.

This study was supported by the Postgraduate Research Innovation Program of Bengbu Medical College (No. Byycxz1984) and the Nature Science Key Program of Bengbu Medical College (No. BYKY1815ZD).

The authors declare that they have no competing interests in this work.

All data generated or analyzed during this study are included in this published article [and its supplementary information files].

Data sharing not applicable to this article as no datasets were generated or analyzed during the current study.

^a Department of Pathology, the First Affiliated Hospital of Bengbu Medical College, ^b Department of Pathology, ^c Department of Thoracic Surgery, Bengbu Medical College, Bengbu, Anhui Province, China.

* Correspondence: Shiwu Wu, Department of Pathology, the First Affiliated Hospital of Bengbu Medical College, Bengbu Medical College, No.287, Changhuai Road, Bengbu 233003, Anhui Province, China (e-mail: 13705523357@163.com).

Copyright © 2021 the Author(s). Published by Wolters Kluwer Health, Inc.

This is an open access article distributed under the terms of the Creative Commons Attribution-Non Commercial License 4.0 (CCBY-NC), where it is permissible to download, share, remix, transform, and buildup the work provided it is properly cited. The work cannot be used commercially without permission from the journal.

How to cite this article: Yang R, Liu Y, Wang Y, Wang X, Ci H, Song C, Wu S. Low PRRX1 expression and high ZEB1 expression are significantly correlated with epithelial-mesenchymal transition and tumor angiogenesis in non-small cell lung cancer. *Medicine* 2021;100:4(e24472).

Received: 14 June 2020 / Received in final form: 2 January 2021 / Accepted: 4 January 2021

<http://dx.doi.org/10.1097/MD.00000000000024472>

1. Introduction

On the basis of recent global tumor data, lung cancer is still ranked first among malignant tumors in terms of incidence (11.6%) and mortality (18.4%) rates.^[1] Approximately 85% of lung cancer patients are diagnosed with non-small cell lung cancer (NSCLC), which mainly falls into two categories: adenocarcinoma (Ade) and squamous cell carcinoma (SCC).^[2] Despite great developments in early screening, surgery and chemoradiotherapy, the 5-year survival rate of NSCLC is still approximately 20%.^[3] Thus, it is necessary to explore novel diagnostic biomarkers for improving the therapeutic strategies of NSCLC.

Metastasis and invasion are the chief characteristics of tumor cells and the main reasons for tumor-related deaths.^[4] The epithelial-mesenchymal transition (EMT) is associated with dissemination steps in the processes of cancer growth that enables carcinoma cells to lose epithelial properties, gain invasive capacity and acquire stem cell properties.^[5] Moreover, epithelial markers, including E-cadherin, maintain the tight junctions of epithelial cells, and the absence of E-cadherin symbolizes the occurrence of EMT.^[5,6] Zinc finger E-box binding homeobox 1 (ZEB1) is one of the main EMT inducers and has an essential impact on the suppression of E-cadherin.^[7–9] Paired related homeobox 1 (PRRX1) is regarded as a newly identified transcription factor that regulates the expression of many genes, and is connected with the metastasis and prognosis of multiple malignancies.^[10,11] In breast and liver carcinoma, the negative expression of PRRX1 is reported to be tightly linked to promote EMT progression and the poor prognosis of patients.^[11,12] Conversely, PRRX1 over expression indicates a poor prognosis and enhances tumor metastasis in pancreatic cancer, colorectal cancer, papillary thyroid carcinoma and gastric carcinoma.^[13–16] Interestingly, PRRX1 seems to have different roles in different tumors, and in addition to carcinogenic functions, it may also have tumor-suppressive properties. Few reports have illuminated PRRX1 expression and its association with the EMT in primary NSCLC tissues from a histological perspective.

Angiogenesis involves the growth of new capillary blood vessels derived from existing capillaries and venules behind the capillaries, which provides oxygen and nutrients that cancer can use to promote its growth and migration.^[17] The microvessel density (MVD) is the most commonly used parameter for evaluating tumor angiogenesis.^[18] Notably, Ihida-Stansbury et al showed that PRRX1 is required for healthy lung vascular development.^[19] However, it is not clear whether PRRX1 is associated with the MVD in NSCLC.

In the current study, we observed the expression levels of PRRX1, ZEB1 and E-cadherin, and the MVD in NSCLC tissues, and aimed to evaluate the correlations among PRRX1 expression, tumor prognosis and angiogenesis.

2. Materials and methods

2.1. Patients and tissue samples

Between January 2013 and December 2014, a total of 111 patients who were diagnosed with NSCLC and underwent pulmonary lobectomy and lymph node dissection at the First Affiliated Hospital of Bengbu Medical College (Anhui, China) were enrolled in this study. NSCLC tissues and corresponding adjacent normal alveolar epithelium tissues from these patients were removed. The patients involved in this research did not receive chemotherapy and targeted therapy before surgery. We collected complete clinico-

Table 1

Patients characteristics.

Patients characteristics	Frequency, n	Percentage, %
Age, years		
<60	39	35.1
≥60	72	64.9
Gender		
Male	85	76.6
Female	26	23.4
Smoking		
No	39	35.1
Yes	72	64.9
Location		
Left	50	45.0
Right	61	55.0
Gross type		
Central	65	58.6
Peripheral	46	41.4
Histological type		
SCC	70	63.1
Ade	41	36.9
Grade		
Well	9	8.1
Moderate	73	65.8
Poor	29	26.1
Size		
<3.0cm	25	22.5
≥3.0cm	86	77.5
LNM		
No	53	47.7
Yes	58	52.3
DM		
No	103	92.8
Yes	8	7.2
TNM stage		
I+II	69	62.2
III+IV	42	37.8

Ade = adenocarcinoma, SCC = squamous cell carcinoma, LNM = lymph node metastasis, DM = distant metastasis, TNM = tumor-node-metastasis.

pathological and follow-up data for all patients by phone every six months. Additionally, the overall survival (OS) time was measured from the initial surgery time to death or December 2019. We performed tumor-node-metastasis (TNM) staging based on the 8th Edition of the American Joint Committee on Cancer (AJCC) lung cancer staging standard. This study was approved by the ethics committee of the First Affiliated Hospital of Bengbu Medical College. Written informed consent was acquired from all patients. The relevant clinicopathological statistics are shown in Table 1. According to the 2015 World Health Organization (WHO) classification of lung tumors, 70 cases of squamous cell carcinoma were mainly keratinized, 41 cases of adenocarcinoma were mostly acinar and papillary, and other types are rare in this study.

2.2. Immunohistochemistry

All surgical specimens were fixed in 4% neutral formaldehyde and liquid paraffin-embedded samples were placed in the mold. Representative wax blocks were cut into 4 μm thick continuous sections, and all pathological tissue sections were dewaxed with xylene and a gradient alcohol series. Then these sections were rinsed for 10 minutes with distilled water. The tissue slides were immersed in sodium citrate buffer (pH 6.0), boiled in a pressure cooker and cooled to 37°C for antigen retrieval. To inhibit

endogenous peroxidase and perform tissue antigen repair, we added 3% hydrogen peroxide solution was added to all sections in a dropwise manner, and then incubated the sections at room temperature for 15 minutes. The slides were washed 3 times with phosphate buffered saline (PBS, pH 7.2) for 3 minutes each time. We placed the slices in an incubation box, added a few drops of mouse monoclonal anti- PRRX1 (1:150, TA803116, OriGene, USA) and rabbit monoclonal anti-ZEB1 (1:100, ab87280, Abcam, UK), anti-E-cadherin (1:200, ab1416, Abcam, UK), and anti-CD34 (1:200, ab762, Abcam, UK) antibodies and then placed them in a 37°C incubator for 1 hour. After that, the sections were washed with PBS 3 times for 9 minutes, and the secondary antibody goat anti-rabbit/mouse IgG-HRP was added dropwise and left at room temperature for 30 minutes. All slices were immersed in a newly prepared DAB solution, counterstained with hematoxylin, rinsed with distilled water, dehydrated with gradient alcohol and sealed with neutral resin.

2.3. Immunostaining evaluation and count of MVD

The judgment of immunohistochemical results was conducted by 2 independent and double-blind histopathologists. We classified the staining results in terms of intensity (0: no staining; 1: faint-yellow staining; 2: tan staining; 3: dark-brown staining) and extent (1: <11% positive cells; 2: 11%–15% positive cells; 3: 51%–75% positive cells; 4: >75% positive cells). The final score was obtained by multiplying the intensity and extent scores, with a final score ≥ 3 indicating positive expression and < 3 indicating negative expression. The MVD value was measured by the method of Weidner et al.^[20] We used CD34 immunostaining to label endothelial cells. The pathologists first selected the 3 fields with the highest vascularization under a low-power microscope (100 \times) and then counted the number of capillaries and small veins in tumor tissues at high magnification (400 \times). The MVD value was calculated as the average number of microvessels in these 3 fields. Additionally, when counting, blood vessels containing more than 8 red blood cells and blood vessels with relatively thick muscle layers were excluded.

2.4. Statistical analysis

All data were analyzed with SPSS software version 26.0 and denoted by the mean \pm standard deviation (SD). The relationships between clinicopathological data and PRRX1, ZEB1, E-cadherin and MVD status were assessed by the Chi-Squared test. The correlation between PRRX1, ZEB1, E-cadherin and the MVD were analyzed by the Spearman rank correlation method. We used univariate and multivariate analyses to explore the impact of PRRX1, ZEB1, E-cadherin and the MVD on the survival time. Univariate OS analysis was performed using the KM test. The multivariate Cox hazard regression model was used to investigate independent predictors for OS. A *P* value $< .05$ was considered to be significantly different.

3. Results

3.1. Associations between PRRX1, ZEB1, E-cadherin, the MVD and the clinicopathological factors of patients with NSCLC

The roles of PRRX1, ZEB1, E-cadherin and the MVD in the NSCLC and control groups were explored by immunohistochemistry and the clinical characteristics and experimental data

obtained in the study were analyzed. PRRX1 was mainly distributed in the nucleus, with lower expression in NSCLC tissues (38.7%, 43/111) than in corresponding normal lung tissues (90.1%, 100/111; *P* $< .001$; Fig. 1A and 1B). PRRX1 expression was inversely proportional to tumor size (*P* = .013), LNM (*P* = .001), and TNM stage (*P* = .012; Table 2), but its expression did not correlate significantly with other clinicopathological characteristics (Table 2).

ZEB1 expression was restricted to the nucleus and cytoplasm. Its expression was higher in NSCLC (55.0%, 61/111) than in adjacent healthy tissues (13.5%, 15/111; *P* $< .001$; Fig. 1C and 1D). Immunostaining demonstrated that ZEB1 expression was positively related to tumor size (*P* = .030), LNM (*P* = .002), distant metastasis (DM) (*P* = .022), and TNM stage (*P* $< .001$; Table 2), while it did not correlate with age (*P* = .821), sex (*P* = .749), smoking status (*P* = .567), location (*P* = .841), gross type (*P* = .914), histological type (*P* = .562) or grade (*P* = .376; Table 2).

E-cadherin was more highly expressed in the cytoplasm and membrane of normal alveolar epithelial tissues (93.7%, 104/111), than in NSCLC tissues (44.1%, 49/111; *P* $< .001$; Fig. 1E and 1F). E-cadherin expression correlated inversely with tumor size (*P* = .023), LNM (*P* $< .001$), DM (*P* = .025), and TNM stage (*P* $< .001$; Table 2). However, there were no apparent correlations between E-cadherin expression and other clinical features (Table 2).

The average MVD counts were 29.53 ± 8.43 in the NSCLC tissues and 16.39 ± 3.78 in the normal lung tissues (Fig. 1G and 1H). We divided these NSCLC patients into high-MVD (≥ 29.5) and the low-MVD (< 29.5) groups according to the mean MVD. As shown in Table 2, the MVD was connected to tumor size (*P* = .009), LNM (*P* $< .001$), DM (*P* = .022), and TNM stage (*P* $< .001$) in NSCLC.

3.2. Survival prognosis

The median follow-up time for the 111 patients was 35.0 months (range: 2.0 to 84.0 months). Of these patients, 25 survived 5 years after the operation. According to survival analysis, the 5-year OS rate was 22.5%. KM survival analysis implied that the OS (29.0 ± 15.9) of PRRX1– patients was lower than the OS (55.4 ± 16.9) of PRRX1+ patients (*P* $< .001$; Fig. 2A). In the ZEB1+ group, the OS (26.2 ± 13.0) was notably shorter than the OS (55.1 ± 17.1) in the ZEB1– group (*P* $< .001$; Fig. 2B). Similarly, the OS (26.1 ± 13.3) in the E-cadherin– group was markedly lower than the OS (55.8 ± 16.1) in the E-cadherin+ group (*P* $< .001$; Fig. 2C). The OS in high-MVD patients (29.4 ± 16.6) was obviously shorter than the OS (51.2 ± 19.1) in low-MVD patients (*P* $< .001$; Fig. 2D; Table 3). According to the multivariate analysis, the expression levels of PRRX1 (*P* $< .001$), ZEB1 (*P* $< .001$), and E-cadherin (*P* $< .001$) and the MVD (*P* = .001; Table 4) may act as independent predictors in NSCLC. Moreover, multivariate and univariate analyses of clinical features showed that tumor size, LNM, DM and TNM stage were closely related to the survival time of NSCLC (*P* $< .05$; Table 3, Table 4). Our multivariate Cox regression analyses revealed that age, gender, smoking, location, gross type, histological type and grade were not linked to the OS (Table 4).

3.3. Correlations between PRRX1, ZEB1, E-cadherin and the MVD

We found that the high MVD was negatively related to PRRX1 ($r = -0.246$, *P* = .009) and E-cadherin expression levels

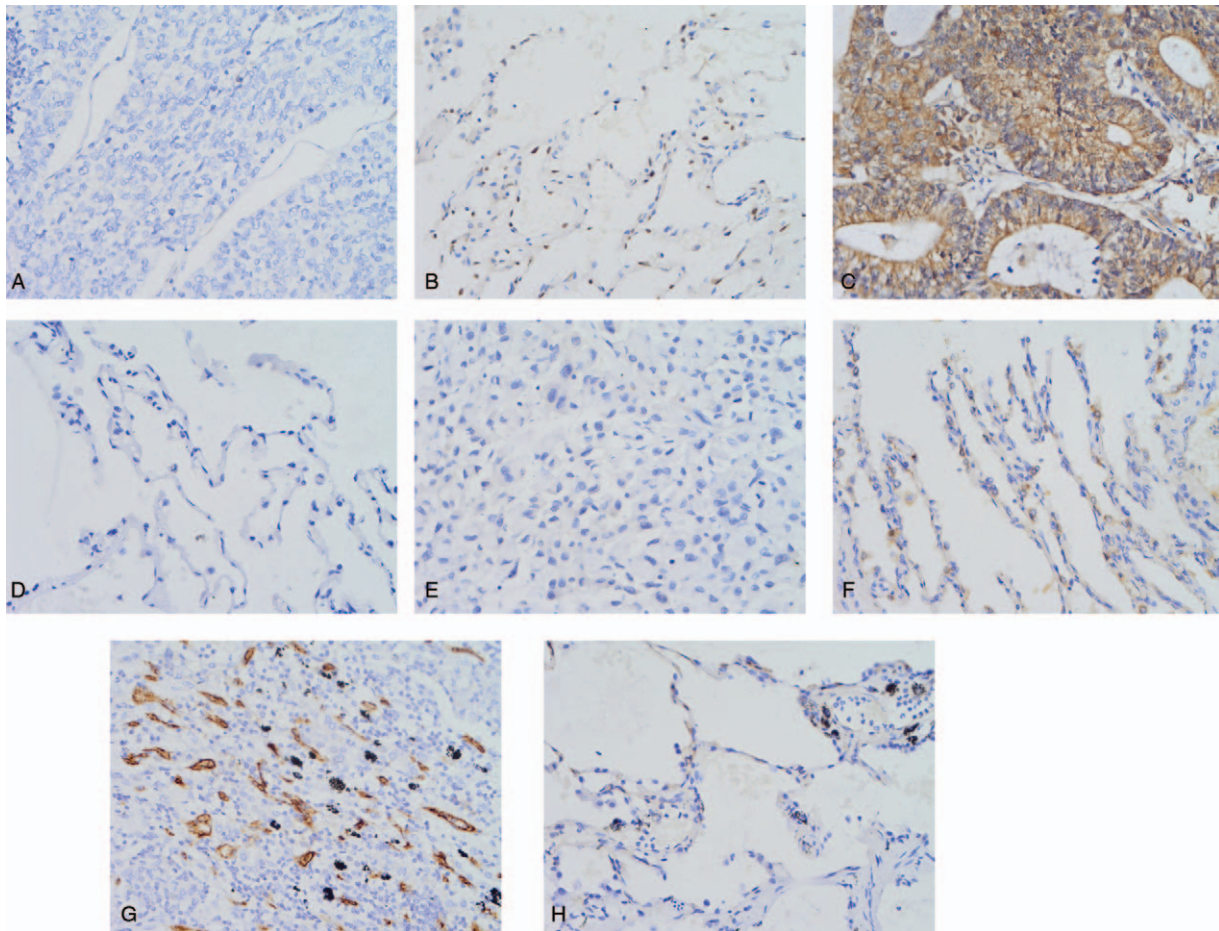


Figure 1. Positive staining of PRRX1, ZEB1, E-cadherin, and CD34 in NSCLC and control tissues ($\times 400$ magnification). (A) Negative staining of PRRX1 in NSCLC tumor cells; (B) Positive staining of PRRX1 in the nucleus of control tissues; (C) Positive staining of ZEB1 in the nucleus and cytoplasm of NSCLC tumor cells; (D) Negative staining of ZEB1 in control tissues; (E) Negative staining of E-cadherin in NSCLC tumor cells; (F) Positive staining of E-cadherin in the membrane and cytoplasm of control tissues; (G, H) Immunohistochemical staining of CD34, which was used to label vascular endothelial cells and to evaluate MVD values; (G) High MVD in NSCLC tissues; (H) Low MVD in control tissues.

($r = -0.289$, $P = .002$), but positively related to ZEB1 expression ($r = 0.309$, $P = .001$). The expression of PRRX1 was negatively related to the expression of ZEB1 ($r = -0.544$, $P < .001$) and positively related to the expression of E-cadherin ($r = 0.373$, $P < .001$). The expression levels of ZEB1 and E-cadherin correlated negatively ($r = -0.435$, $P < .001$) (Table 5).

4. Discussion

NSCLC is the most common primary tumor of the respiratory system. Even though the multidisciplinary diagnosis and treatment approaches for the disease have been significantly improved, the early diagnosis rates and the prognosis of NSCLC are still unsatisfactory. Recently, some scholars have employed a random forest algorithm to find that the top ten factors closely related to lung cancer death are gender, age, radiotherapy, LNM, primary tumor size, histological type, and tumor laterality.^[21] Shang et al. believed that lung adenocarcinoma histologic characteristics are related to oncogenic diver alterations.^[22] Moreover, angiogenesis and variations in biomarkers are closely related to tumor growth and metastasis. In this research, we surveyed the expression levels of PRRX1, ZEB1, and E-cadherin and the MVD to explore new targets for antiangiogenic therapy in NSCLC.

PRRX1, which belongs to the paired homeobox family, can be used as a transcription factor to regulate various genes. Expression of PRRX1 is stable in different tissues in the human body, including the lung, heart, bone, and so on.^[23] Melina et al. reported that PRRX1 in adipocytes inhibited fat metabolism and reduced the sensitivity to insulin by inhibiting PPAR γ 2 expression.^[24] Shimozaki et al showed that PRRX1 and SOX2 work together to facilitate the self-renewal of neural stem cells.^[25] Research by Lu et al suggested that tumor necrosis factor-induced high expression of PRRX1 and inhibited bone formation.^[10] PRRX1 was first discovered in 2012, and it was found that low expression of PRRX1 in tumor cells promoted of EMT occurrence.^[11] However, Takahashi et al transfected a PRRX1 plasmid into a colorectal cancer cell line. They found that in comparison to those of the control group, the cells of the PRRX1 over expression group showed a more interstitial cell-like morphology, and that E-cadherin expression was meaningfully reduced, indicating that high expression of PRRX1 can promote the EMT in colorectal cancer cells.^[14] To date, there have been only a few reports directly related to the function of PRRX1 in NSCLC. Ocaña et al analyzed public data sets and found that low-transcript levels of PRRX1 are related to a short survival time in lung SCC.^[11] Zhu et al. demonstrated that silencing

Table 2
The correlation between PRRX1, or ZEB1, or E-cadherin, or MVD and clinicopathological characteristics in NSCLC.

Variable	PRRX1		P	ZEB1		P	E-cadherin		P	MVD		P
	Negative	Positive		Negative	Positive		Negative	Positive		Low	High	
Age, years			.440			.821			.198			.567
<60	22	17		17	22		25	14		19	20	
≥60	46	26		33	39		37	35		31	41	
Gender			.340			.749			.814			.139
Male	50	35		39	46		48	37		35	50	
Female	18	8		11	15		14	12		15	11	
Smoking			.716			.567			.626			.077
No	23	16		19	20		23	16		22	17	
Yes	45	27		31	41		39	33		28	44	
Location			.353			.841			.261			.342
Left	33	17		22	28		25	25		25	25	
Right	35	26		28	33		37	24		25	36	
Gross type			.943			.914			.612			.620
Central	40	25		29	36		35	30		28	37	
Peripheral	28	18		21	25		27	19		22	24	
Histological type			.245			.562			.663			.163
SCC	40	30		33	37		38	32		28	42	
Ade	28	13		17	24		24	17		22	19	
Grade			.355			.376			.618			.198
Well	5	4		5	4		4	5		5	4	
Moderate	42	31		35	38		40	33		36	37	
Poor	21	8		10	19		18	11		9	20	
Size			.013			.030			.023			.009
<3.0cm	10	15		16	9		9	16		17	8	
≥3.0cm	58	28		34	52		53	33		33	53	
LNМ			.001			.002			<.001			<.001
No	24	29		32	21		15	38		33	20	
Yes	44	14		18	40		47	11		17	41	
DM			.050			.022			.025			.022
No	60	43		50	53		54	49		50	53	
Yes	8	0		0	8		8	0		0	8	
TNM stage			.012			<.001			<.001			<.001
I+II	36	33		41	28		28	41		45	24	
III+IV	32	10		9	33		34	8		5	37	

Ade = adenocarcinoma, SCC = squamous cell carcinoma, LNМ = lymph node metastasis, DM = distant metastasis, TNM = tumor-node-metastasis, PRRX1 = paired related homeobox 1, ZEB1 = zinc finger E-box binding homeobox 1, MVD = microvessel density, NSCLC = non-small cell lung cancer.

PRRX1 in A549 cells promoted the EMT.^[26] In addition, over expressed PRRX1A was found to have critical roles in regulating the stemness and metastatic potential of lung cancer.^[27] For the first time, we used immunohistochemistry to investigate PRRX1 protein expression in NSCLC patients and its relationship with angiogenesis from the perspective of histology. In our study, PRRX1+ expression was visibly abated in NSCLC tissues compared with adjacent healthy tissues and correlated negatively with tumor size, LNМ, and TNM stage. KM analysis revealed that negative PRRX1 expression was related to a shorter OS time than positive PRRX1 expression. PRRX1 expression was an independent predictor of NSCLC prognosis. The results were consistent with previous research.^[11,12,26]

The EMT promotes the tumorigenic progression of epithelial cells and plays an essential role in tumor metastasis.^[28] By observing E-cadherin expression, a classic EMT marker, we analyzed the role of PRRX1 in the EMT and detected that expression of PRRX1 in NSCLC specimens was favorably linked to the loss of E-cadherin. Hence, low PRRX1 protein levels promoted the EMT in NSCLC. Common inducers of EMT mainly include the TWIST, ZEB, and SNAIL families.^[29] Reports have shown that PRRX1 and TWIST1 might cooperate during

the progression of EMT.^[11] Fazilaty et al described a gene regulatory network through which Snail1 directly inhibits PRRX1 transcription.^[30] In addition, our experimental results indicated a significant inverse correlation between PRRX1 and ZEB1 expression. ZEB1 is generally regarded as a vital driver of cancer invasion and orchestrates the EMT by repressing E-cadherin.^[31-33] ZEB1 is abnormally expressed in various human tumors, and it is believed to promote cancer migration, invasion and metastasis.^[33-36] In previous reports, some factors affected NSCLC tumor development and progression by the regulation of ZEB1.^[37,38] Nevertheless, the mechanism of ZEB1 as an activator remains unclear. In this study, ZEB1+ expression was higher in the NSCLC group than in the control group, and it was positively associated with tumor size, LNМ, DM, and TNM stage. KM analysis further revealed that the ZEB1+ group of NSCLC patients had shorter survival times than the ZEB1- group. These results were in accordance with those of previous studies.^[35-39]

Many researchers believe that the establishment of fresh microvessels in tumors plays an important role in tumor development and metastasis.^[40,41] Previous studies have shown that the regular expression of PRRX1 is essential for the

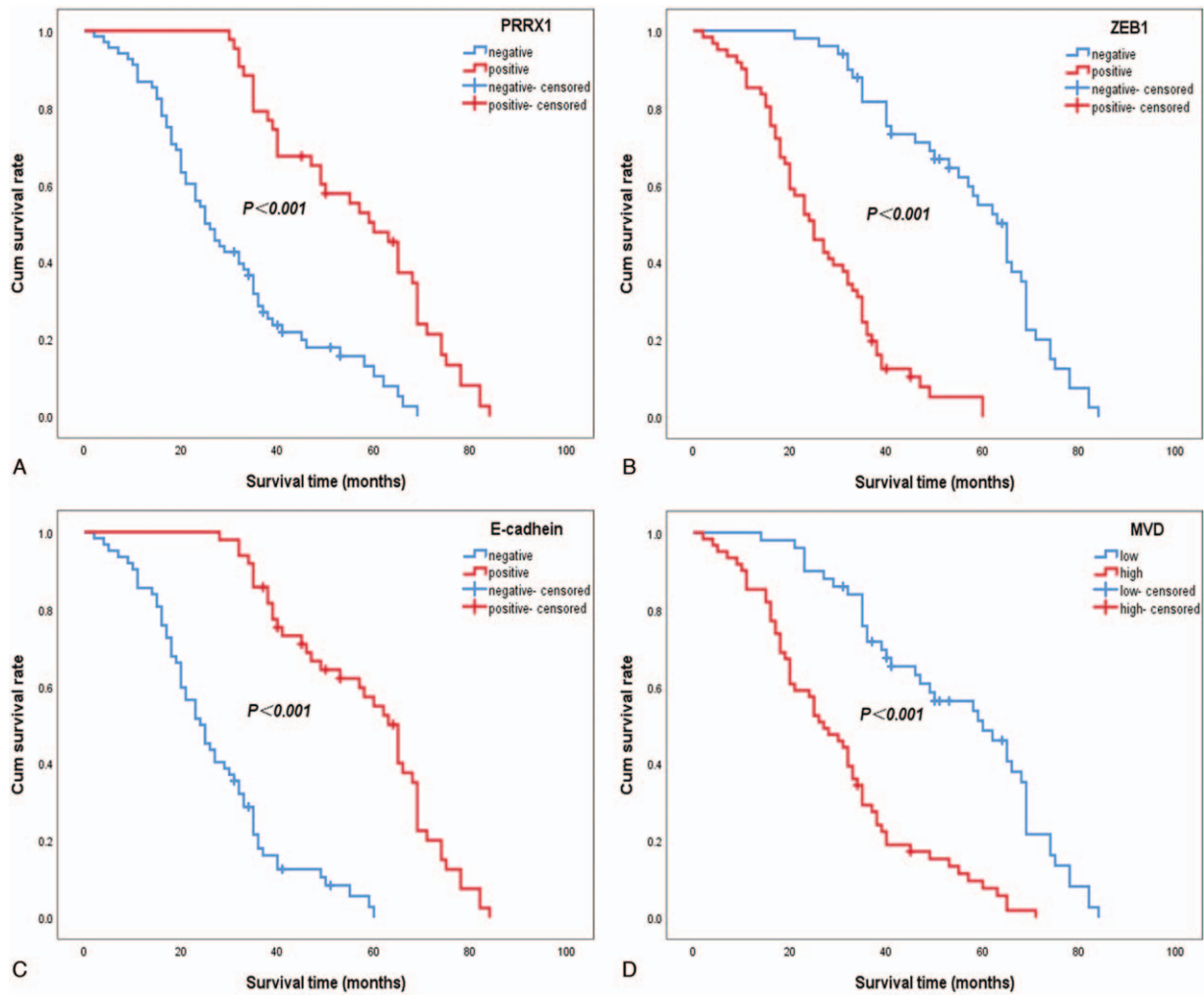


Figure 2. Kaplan–Meier analysis of the survival rates of patients with NSCLC. (A) Overall survival of all patients in relation to PRRX1 (log-rank=36.077, $P < .001$). (B) Overall survival of all patients in relation to ZEB1 (log-rank=65.217, $P < .001$). (C) Overall survival of all patients in relation to E-cadherin (log-rank=65.629, $P < .001$). (D) Overall survival of all patients in relation to MVD (log-rank=38.889, $P < .001$).

Table 3

Results of univariate analyses of OS time.

Variable	n	Mean OS, months	Log-rank	P value
PRRX1			36.077	<.001
Negative	68	29.0 ± 15.9		
Positive	43	55.4 ± 16.9		
ZEB1			65.217	<.001
Negative	50	55.1 ± 17.1		
Positive	61	26.2 ± 13.0		
E-cadherin			65.629	<.001
Negative	62	26.1 ± 13.3		
Positive	49	55.8 ± 16.1		
MVD			38.889	<.001
Low	50	51.2 ± 19.1		
High	61	29.4 ± 16.6		
Age (years)			2.710	.100
<60	39	35.5 ± 18.2		
≥60	72	41.2 ± 21.9		
Gender			0.148	.700
Male	85	38.7 ± 21.2		
Female	26	40.7 ± 19.4		

(continued)

Table 3
(continued).

Variable	n	Mean OS, months	Log-rank	P value
Smoking			0.940	.332
No	39	41.1 ± 20.4		
Yes	72	38.2 ± 21.0		
Location			1.225	.268
Left	50	40.9 ± 21.4		
Right	61	37.8 ± 20.3		
Gross type			0.386	.535
Central	65	37.4 ± 20.1		
Peripheral	46	41.8 ± 21.6		
Histological type			0.009	.924
SCC	70	38.9 ± 21.8		
Ade	41	39.6 ± 19.1		
Grade			5.551	.062
Well	9	39.7 ± 24.5		
Moderate	73	40.9 ± 20.7		
Poor	29	34.8 ± 19.8		
Size			16.176	<.001
<3.0 cm	25	56.3 ± 19.3		
≥3.0 cm	86	34.2 ± 18.5		
LNM			50.151	<.001
No	53	52.7 ± 19.6		
Yes	58	26.8 ± 12.4		
DM			81.426	<.001
No	103	41.4 ± 19.8		
Yes	8	10.4 ± 5.4		
TNM stage			71.648	<.001
I+II	69	49.5 ± 18.5		
III+IV	42	22.3 ± 10.8		

Ade = adenocarcinoma, SCC = squamous cell carcinoma, LNM = lymph node metastasis, DM = distant metastasis, TNM = tumor-node-metastasis, PRRX1 = paired related homeobox 1, ZEB1 = Zinc finger E-box binding homeobox 1, MVD = Microvessel density, OS = overall survival.

development and integrity of lung blood vessels.^[19,42] Our study indicated that the MVD value in NSCLC was obviously higher than that in the control group and was markedly connected with tumor size, LNM, DM, and TNM stage. The low-MVD group of NSCLC patients showed a longer OS time than the high-MVD group. Moreover, we observed that high MVD correlated negatively with PRRX1 expression, but positively with ZEB1

expression, suggesting that PRRX1 and ZEB1 may affect tumor metastasis by regulating angiogenesis. Consequently, PRRX1 and ZEB1 may become potential targets for antiangiogenic therapy. Tumor angiogenesis is a complicated process involving multiple steps and factors. Until now, the specific mechanisms by which PRRX1 and ZEB1 affect angiogenesis were unclear. Further molecular-level research is needed to clarify these mechanisms.

Table 4
Results of multivariate analyses of OS time.

Variable	B	SE	P	RR	95%CI
PRRX1	-1.362	0.316	<.001	0.256	0.138-0.476
ZEB1	1.430	0.342	<.001	4.180	2.140-8.165
E-cadherin	-1.847	0.345	<.001	0.158	0.080-0.310
MVD	0.910	0.285	.001	2.485	1.421-4.347
Size	0.943	0.311	.002	2.568	1.396-4.724
LNM	0.933	0.349	.008	2.541	1.282-5.039
DNM	2.354	0.556	<.001	10.533	3.542-31.317
TNM stage	0.781	0.356	.028	2.183	1.086-4.390
Age	-0.126	0.273	.644	0.882	0.517-1.505
Gender	-0.388	0.411	.344	0.678	0.303-1.517
Smoking	0.203	0.328	.537	1.225	0.644-2.330
Location	0.313	0.235	.183	1.368	0.863-2.168
Gross type	-0.362	0.258	.160	0.696	0.420-1.154
Histological type	-0.068	0.302	.822	0.934	0.517-1.688
Grade	-0.260	0.247	.294	0.771	0.475-1.252

PRRX1 = paired related homeobox 1, ZEB1 = zinc finger E-box binding homeobox 1, MVD = microvessel density, LNM = lymph node metastasis, DM = distant metastasis, TNM = tumor-node-metastasis, OS = overall survival.

Table 5
Correlation among PRRX1, ZEB1, E-cadherin, and MVD in NSCLC.

Variable	PRRX1		r	P	ZEB1		r	P	E-cadherin		r	P
	Negative	Positive			Negative	Positive			Negative	Positive		
MVD			-0.246	.009			0.309	.001			-0.289	.002
Low	24	26			31	19			20	30		
High	44	17			19	42			42	19		
PRRX1							-0.544	<.001			0.373	<.001
Negative					16	52			48	20		
Positive					34	9			14	29		
ZEB1											-0.435	<.001
Negative									16	34		
Positive									46	15		

PRRX1 = paired related homeobox 1, ZEB1 = zinc finger E-box binding homeobox 1, MVD = microvessel density.

5. Conclusions

In summary, we demonstrated that low PRRX1 expression and high ZEB1 expression are associated with the EMT, angiogenesis and adverse outcomes in NSCLC patients. We believe that PRRX1 and ZEB1 might serve as novel prognostic biomarkers and potential therapeutic targets.

Author contributions

Ruixue Yang, Shiwu Wu, Yuanqun Liu, and Yufei Wang carried out the study design and analysis of pathology and drafted the manuscript. Xiaolin Wang, Hongfei Ci carried out sample collection and coordination. Chao Song carried out collection of clinical data. All authors read and approved the manuscript.

Conceptualization: Xiaolin Wang.

Data curation: Yufei Wang.

Formal analysis: Yufei Wang.

Funding acquisition: Hongfei Ci.

Investigation: Yuanqun Liu, Chao Song.

Methodology: Chao Song.

Software: Yuanqun Liu.

Writing – original draft: Ruixue Yang.

Writing – review & editing: Ruixue Yang, Xiaolin Wang, Shiwu Wu.

References

- Bray F, Ferlay J, Soerjomataram I, et al. Global cancer statistics 2018: GLOBOCAN estimates of incidence and mortality worldwide for 36 cancers in 185 countries. *CA Cancer J Clin* 2018;68:394–424.
- Li C, Zhang S, Lu Y, et al. The roles of Notch3 on the cell proliferation and apoptosis induced by CHIR99021 in NSCLC cell lines: a functional link between Wnt and Notch signaling pathways. *PLoS One* 2013;8:e84659.
- Ferlay J, Soerjomataram I, Dikshit R, et al. Cancer incidence and mortality worldwide: sources, methods and major patterns in GLOBOCAN 2012. *Int J Cancer* 2015;136:E359–386.
- Gupta GP, Massague J. Cancer metastasis: building a framework. *Cell* 2006;127:679–95.
- Nieto MA. The ins and outs of the epithelial to mesenchymal transition in health and disease. *Annu Rev Cell Dev Biol* 2011;27:347–76.
- Busch EL, McGraw KA, Sandler RS. The potential for markers of epithelial-mesenchymal transition to improve colorectal cancer outcomes: a systematic review. *Cancer Epidemiol Biomarkers Prev* 2014;23:1164–75.
- Takeyama Y, Sato M, Horio M, et al. Knockdown of ZEB1, a master epithelial-to-mesenchymal transition (EMT) gene, suppresses anchorage-independent cell growth of lung cancer cells. *Cancer Lett* 2010;296:216–24.
- Gemmill RM, Roche J, Potiron VA, et al. ZEB1-responsive genes in non-small cell lung cancer. *Cancer Lett* 2011;300:66–78.
- Matsubara D, Kishaba Y, Yoshimoto T, et al. Immunohistochemical analysis of the expression of E-cadherin and ZEB1 in non-small cell lung cancer. *Pathol Int* 2014;64:560–8.
- Lu X, Beck GR Jr, Gilbert LC, et al. Identification of the homeobox protein Prx1 (MHox, Prx-1) as a regulator of osterix expression and mediator of tumor necrosis factor alpha action in osteoblast differentiation. *J Bone Miner Res* 2011;26:209–19.
- Ocana OH, Corcoles R, Fabra A, et al. Metastatic colonization requires the repression of the epithelial-mesenchymal transition inducer Prx1. *Cancer Cell* 2012;22:709–24.
- Hirata H, Sugimachi K, Takahashi Y, et al. Downregulation of PRRX1 confers cancer stem cell-like properties and predicts poor prognosis in hepatocellular carcinoma. *Ann Surg Oncol* 2015;22:S1402–1409.
- Reichert M, Takano S, von Burstin J, et al. The Prx1 homeodomain transcription factor plays a central role in pancreatic regeneration and carcinogenesis. *Genes Dev* 2013;27:288–300.
- Takahashi Y, Sawada G, Kurashige J, et al. Paired related homeobox 1, a new EMT inducer, is involved in metastasis and poor prognosis in colorectal cancer. *Br J Cancer* 2013;109:307–11.
- Hardin H, Guo Z, Shan W, et al. The roles of the epithelial-mesenchymal transition marker PRRX1 and miR-146b-5p in papillary thyroid carcinoma progression. *Am J Pathol* 2014;184:2342–54.
- Guo J, Fu Z, Wei J, et al. PRRX1 promotes epithelial-mesenchymal transition through the Wnt/beta-catenin pathway in gastric cancer. *Med Oncol* 2015;32:393.
- Viallard C, Larrivee B. Tumor angiogenesis and vascular normalization: alternative therapeutic targets. *Angiogenesis* 2017;20:409–26.
- Pathak AP, Hochfeld WE, Goodman SL, et al. Circulating and imaging markers for angiogenesis. *Angiogenesis* 2008;11:321–35.
- Ihida-Stansbury K, McKean DM, Gebb SA, et al. Paired-related homeobox gene Prx1 is required for pulmonary vascular development. *Circ Res* 2004;94:1507–14.
- Weidner N, Semple JP, Welch WR, et al. Tumor angiogenesis and metastasis—correlation in invasive breast carcinoma. *N Engl J Med* 1991;324:1–8.
- Deng F, Zhou H, Lin Y, et al. Predict multicategory causes of death in lung cancer patients using clinicopathologic factors. *Comput Biol Med* 2020;129:104161.
- Shang G, Jin Y, Zheng Q, et al. Histology and oncogenic driver alterations of lung adenocarcinoma in Chinese. *Am J Cancer Res* 2019;9:1212–23.
- Norris RA, Scott KK, Moore CS, et al. Human PRRX1 and PRRX2 genes: cloning, expression, genomic localization, and exclusion as disease genes for Nager syndrome. *Mamm Genome* 2000;11:1000–5.
- Claussnitzer M, Dankel SN, Klocke B, et al. Leveraging cross-species transcription factor binding site patterns: from diabetes risk loci to disease mechanisms. *Cell* 2014;156:343–58.
- Shimozaki K, Clemenson GD, Gage FH. Paired related homeobox protein 1 is a regulator of stemness in adult neural stem/progenitor cells. *J Neurosci* 2013;33:4066–75.
- Zhu H, Sun G. Loss of PRRX1 induces epithelial-mesenchymal transition and cancer stem cell-like properties in A549 cells. *Am J Transl Res* 2017;9:1641–50.
- Sun L, Han T, Zhang X, et al. PRRX1 isoform PRRX1A regulates the stemness phenotype and epithelial-mesenchymal transition (EMT) of cancer stem-like cells (CSCs) derived from non-small cell lung cancer (NSCLC). *Transl Lung Cancer Res* 2020;9:731–44.

- [28] Thiery JP, Acloque H, Huang RY, et al. Epithelial-mesenchymal transitions in development and disease. *Cell* 2009;139:871–90.
- [29] Scheel C, Eaton EN, Li SH, et al. Paracrine and autocrine signals induce and maintain mesenchymal and stem cell states in the breast. *Cell* 2011;145:926–40.
- [30] Fazilaty H, Rago L, Kass Youssef K, et al. A gene regulatory network to control EMT programs in development and disease. *Nat Commun* 2019;10:5115.
- [31] Zhang P, Sun Y, Ma L. ZEB1: at the crossroads of epithelial-mesenchymal transition, metastasis and therapy resistance. *Cell Cycle* 2015;14:481–7.
- [32] Larsen JE, Nathan V, Osborne JK, et al. ZEB1 drives epithelial-to-mesenchymal transition in lung cancer. *J Clin Invest* 2016;126:3219–35.
- [33] Krebs AM, Mitschke J, Lasierra Losada M, et al. The EMT-activator Zeb1 is a key factor for cell plasticity and promotes metastasis in pancreatic cancer. *Nat Cell Biol* 2017;19:518–29.
- [34] Voutsadakis IA. Epithelial-Mesenchymal Transition (EMT) and Regulation of EMT factors by steroid nuclear receptors in breast cancer: a review and in silico investigation. *J Clin Med* 2016;5:1–23.
- [35] Jia B, Liu H, Kong Q, et al. Overexpression of ZEB1 associated with metastasis and invasion in patients with gastric carcinoma. *Mol Cell Biochem* 2012;366:223–9.
- [36] Chen Z, Li S, Huang K, et al. The nuclear protein expression levels of SNAI1 and ZEB1 are involved in the progression and lymph node metastasis of cervical cancer via the epithelial-mesenchymal transition pathway. *Hum Pathol* 2013;44:2097–105.
- [37] Zhang M, Han Y, Zheng Y, et al. ZEB1-activated LINC01123 accelerates the malignancy in lung adenocarcinoma through NOTCH signaling pathway. *Cell Death Dis* 2020;11:981.
- [38] Zhao S, Gao X, Zhong C, et al. SNHG3 knockdown suppresses proliferation, migration and invasion, and promotes apoptosis in non-small cell lung cancer through regulating miR-216a/ZEB1 Axis. *Oncotargets Ther* 2020;13:11327–36.
- [39] Fu R, Li Y, Jiang N, et al. Inactivation of endothelial ZEB1 impedes tumor progression and sensitizes tumors to conventional therapies. *J Clin Invest* 2020;130:1252–70.
- [40] Li B, Xu WW, Han L, et al. MicroRNA-377 suppresses initiation and progression of esophageal cancer by inhibiting CD133 and VEGF. *Oncogene* 2017;36:3986–4000.
- [41] Zhu J, Wu G, Li Q, et al. Overexpression of suprabasin is associated with proliferation and tumorigenicity of esophageal squamous cell carcinoma. *Sci Rep* 2016;6:1–1.
- [42] Martin JF, Bradley A, Olson EN. The paired-like homeo box gene *MHox* is required for early events of skeletogenesis in multiple lineages. *Genes Dev* 1995;9:1237–49.