

ORIGINAL ARTICLE

Propofol versus midazolam for sedation during radiofrequency ablation in patients with hepatocellular carcinoma

Naoya Kanogawa,^{*†} Sadahisa Ogasawara,^{*,††} Yoshihiko Ooka,^{*†} Masanori Inoue,^{*†} Toru Wakamatsu,^{*†} Masayuki Yokoyama,^{*} Susumu Maruta,^{*} Hidemi Unozawa,^{*} Terunao Iwanaga,^{*} Takafumi Sakuma,^{*} Naoto Fujita,^{*} Keisuke Koroki,^{*} Hiroaki Kanzaki,^{*} Takahiro Maeda,^{*} Kazufumi Kobayashi,^{*} Soichiro Kiyono,^{*} Masato Nakamura,^{*} Takayuki Kondo,^{*} Tomoko Saito,^{*} Tenyu Motoyama,^{*} Eiichiro Suzuki,^{*} Shingo Nakamoto,^{*} Akinobu Tawada,^{*,‡} Tetsuhiro Chiba,^{*} Makoto Arai,^{*,‡} Tatsuo Kanda,^{*,§} Hitoshi Maruyama,^{*,||} Jun Kato,^{*} Ryo Takemura,^{||} Natsuko Nozaki-Taguchi,^{**} Isono Shiroh,^{**} Osamu Yokosuka^{*} and Naoya Kato^{*}

^{*}Department of Gastroenterology, Graduate School of Medicine, [‡]Department of Medical Oncology, Graduate School of Medicine, ^{**}Department of Anesthesiology, Graduate School of Medicine, Chiba University, [†]Translational Research and Development Center, Chiba University Hospital, Chiba, [§]Division of Gastroenterology and Hepatology, Department of Medicine, Nihon University School of Medicine, ^{||}Department of Gastroenterology, Juntendo University School of Medicine and ^{||}Clinical and Translational Research Center, Keio University Hospital, Tokyo, Japan

Key words

hepatocellular carcinoma, midazolam, propofol, radiofrequency ablation, sedation.

Accepted for publication 11 December 2020.

Correspondence

Sadahisa Ogasawara, Department of Gastroenterology, Graduate School of Medicine, Chiba University, 1-8-1 Inohana, Chuo-ku, Chiba 260-8670, Japan.
Email: ogasawaras@chiba-u.jp

Declaration of conflict of interest: None.

[†]These authors contributed equally to this work.

Abstract

Background and Aim: Standardization of the sedation protocol during radiofrequency ablation (RFA) in patients with hepatocellular carcinoma (HCC) is needed. This randomized, single-blind, investigator-initiated trial compared clinical outcomes during and after RFA using propofol and midazolam, respectively, in patients with HCC.

Methods: Few- and small-nodule HCC patients (≤ 3 nodules and ≤ 3 cm) were randomly assigned to either propofol or midazolam. Patient satisfaction was assessed using a 100-mm visual analog scale (VAS) (1 mm = not at all satisfied, 100 mm = completely satisfied). Sedation recovery rates 1, 2, 3, and 4 h after RFA were evaluated based on Modified Observer's Assessment of Alertness/Sedation (MOAA/S) scores; full recovery was defined as a MOAA/S score of 5.

Results: Between July 2013 and September 2017, 143 patients with HCC were enrolled, and 135 patients were randomly assigned to the treatment group. Compared with midazolam, propofol exhibited similar median procedural satisfaction (propofol: 73.1 mm, midazolam: 76.9 mm, $P = 0.574$). Recovery rates 1 and 2 h after RFA were higher in the propofol group than in the midazolam group. Meanwhile, recovery rates observed 3 and 4 h after RFA were similar in the two groups. The safety profiles during and after RFA were almost identical in the two groups.

Conclusion: Patient satisfaction was almost identical in patients receiving propofol and midazolam sedation during RFA. Propofol sedation resulted in reduced recovery time compared with midazolam sedation in patients with HCC. The safety profiles of both propofol and midazolam sedation during and after RFA were acceptable.

Introduction

Hepatocellular carcinoma (HCC) is a leading cause of cancer-related death, with 850 000 new cases reported annually worldwide.^{1,2} Most cases of HCC occur in patients with underlying liver disease, mostly as a result of hepatitis B or C virus infection or alcohol abuse.^{3,4} Over the past few decades, the importance of early detection of HCC by screening and triaging of high-risk population has been highlighted,⁵⁻⁷ and the number of patients with early-stage HCC receiving curative-intent treatment has been increasing.^{8,9}

Radiofrequency ablation (RFA) is one of the most common curative local ablation methods for HCC.^{8,10} Percutaneous

modalities using ultrasound guidance have been undergoing a process of refinement since the very beginning (around 2000).^{8,10-13} According to guidelines from both east and west, RFA is the best treatment alternative in patients with few and small HCC nodules (≤ 3 nodules measuring ≤ 3 cm) who are not eligible for surgical resection.⁵⁻⁷ Compared with surgical resection, RFA is less invasive, is associated with less morbidity, and requires shorter periods of hospitalization while providing comparable outcomes.¹⁴⁻¹⁹

RFA is generally performed with local anesthesia combined with sedation. Some patients experience severe pain and anxiety during RFA under local anesthesia, which may result in

lower patient satisfaction and insufficient tumor ablation.^{20,21} Sedation using midazolam, which is a traditional intravenous sedative used for percutaneous intervention procedures including RFA, is well known for its modest time to onset of action and modest clearance time.^{20,21} However, administration of midazolam tends to be associated with agitation, irregular breathing, respiratory depression, and thoracic movement, which may lead to inadequate needle placement and needle tracking and cause an insufficient tumor-free ablation margin.

With its short time to onset of action and short clearance time, propofol has become the standard intravenous sedative drug for short procedures in digestive and liver disease therapy.^{22–26} Several randomized controlled trials confirmed the safety and efficacy of propofol sedation compared with midazolam during gastrointestinal endoscopy.^{23–27} Some of these trials included patients with complicated advanced liver disease.^{26,27} Recently, the European Society of Gastrointestinal Endoscopy and the European Society of Gastroenterology and Endoscopy Nurses and Associates recommended the use of propofol by non-anesthesiologists for gastrointestinal endoscopy.²⁸

Standardization of sedation for percutaneous local ablation for HCC is required as it has become a common procedure all over the world. However, to the best of our knowledge, the currently available data are insufficient for generating a consensus on the guidelines of sedation during percutaneous local ablation. The aim of this study was to evaluate the comparative efficacies and safety of propofol and midazolam in HCC patients undergoing RFA.

Methods

Study design. The present investigator-initiated, randomized, single-blind trial was performed in accordance with the good clinical practice guidelines in place at the Chiba University Hospital. The investigators and supporting staff collected the data, and the Clinical Research Center at Chiba University Hospital monitored study conduct. The study was registered with the University Hospital Medical Information Network (UMIN000011443).

All patients receiving RFA were randomly assigned in a 1:1 ratio through a minimization method to either the propofol regimen or the midazolam regimen. The allocation coordinators at the Clinical Research Center enrolled the patients and assigned them to the two trial groups. Allocation factors were RFA history (absent/present), tumor location in nearby intrahepatic vessels (absent/present), and single tumor measuring ≤ 2 cm (absent/present). Subjects were blinded with regard to the group to which they were assigned.

Inclusion criteria. The inclusion criteria were as follows: age ≥ 20 years; presence of histologically confirmed or clinically diagnosed HCC (fulfilling the criteria on diagnostic imaging); number of intrahepatic tumors ≤ 3 and tumor size ≤ 3 cm; absence of benefit from a treatment of established efficacy (e.g., resection); and presence of Child–Pugh A or B classes, an Eastern Cooperative Oncology Group performance status (ECOG-PS) of 0 or 1, systolic blood pressure ≥ 90 mmHg, degree of oxygen saturation $\geq 95\%$, hemoglobin ≥ 8.5 g/dL, white blood cell count $\geq 2000/\text{mm}^3$, neutrophil count $\geq 1000/\text{mm}^3$, platelet count $\geq 50\,000/\text{mm}^3$, total bilirubin level ≤ 3.0 g/dL, aspartate aminotransferase (AST) and alanine aminotransferase (ALT) levels ≤ 10 times the upper limits

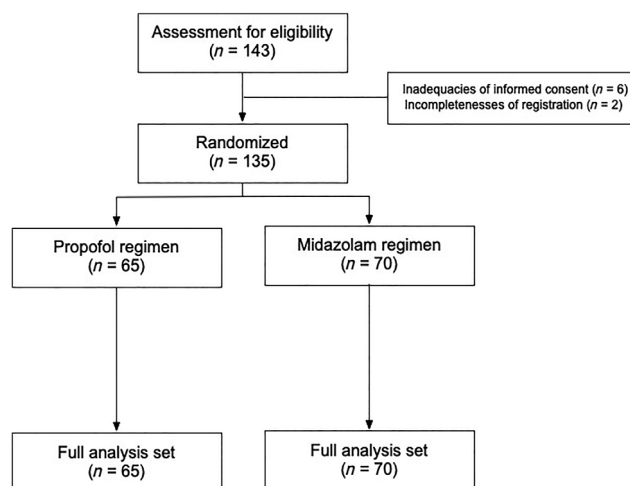


Figure 1 Diagram of consolidated standards of reporting trials.

of the normal (ULN), prothrombin time ≤ 2.3 (international normal ratio), serum albumin ≥ 2.5 g/dL, and serum-creatinine level ≤ 1.5 times the ULN.

Exclusion criteria. The key exclusion criteria were as follows: presence of macrovascular invasion and/or extrahepatic

Table 1 Baseline demographic data and patient characteristics

	Propofol regimen (n = 65)	Midazolam regimen (n = 70)	P
Gender, male [n (%)]	45 (69.2)	50 (71.4)	0.851
Age, ≥ 70 years [n (%)]	39 (60.0)	38 (54.3)	0.121
HBs-Ag, positive [n (%)]	11 (16.9)	10 (14.3)	0.813
HCV-Ab, positive [n (%)]	40 (61.5)	47 (67.1)	0.590
ECOG-PS 0 [n (%)]	58 (89.2)	64 (91.4)	0.774
Child–Pugh score [n (%)]			
5	48 (73.8)	51 (72.9)	0.795
6	14 (21.5)	15 (21.4)	
7	1 (1.5)	3 (4.3)	
8	2 (3.1)	1 (1.4)	
Tumor number [n (%)]			
1	45 (69.2)	49 (70.0)	0.834
2	17 (26.2)	16 (22.9)	
3	3 (4.6)	5 (7.1)	
Maximum tumor size in mm [mean (SD)]	17.4 (5.9)	16.4 (5.6)	0.319
Single nodule and ≤ 20 mm [n (%)]	30 (46.2)	34 (48.6)	0.863
AFP value, ng/mL [mean (SD)]	51.8 (175.4)	78.7 (332.1)	0.553
Tumor location, nearby vessels [n (%)]	41 (63.1)	44 (62.9)	1.000
Past history of RFA [n (%)]	30 (46.2)	35 (50.0)	0.864

Abbreviations: AFP, alpha-fetoprotein; ECOG-PS, Eastern Cooperative Oncology Group performance status; HBs-Ag, hepatitis B surface antigen; HCV-Ab, hepatitis C virus antibody; RFA, radiofrequency ablation.

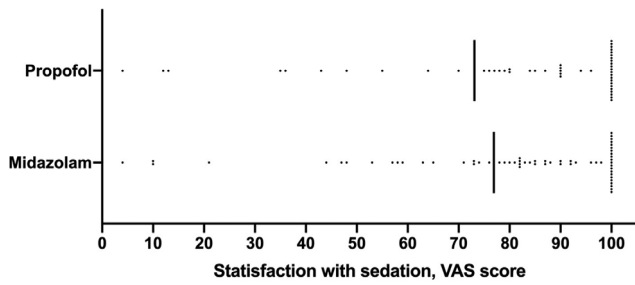


Figure 2 Satisfaction with sedations assessed by visual analog scale (VAS) score.

metastasis, presence of uncontrolled or significant cardiovascular disease, American Society of Anesthesiologist classification ≥ 4 , body mass index (BMI) ≥ 30 , presence of sleep apnea syndrome, active bacterial infection, and human immunodeficiency virus infection/adult immunodeficiency syndrome.

RFA procedure. The RFA procedure was performed under real-time ultrasound guidance using a 17-gauge cool-tip electrode (Cool-Tip; RF Ablation System, Covidien, Boulder, Colombia, CO, USA). Under conscious sedation, an electrode was inserted and radiofrequency delivered for 6–15 min for each lesion. As appropriate, intrapleural or intraperitoneal fluid infusion was performed before electrode insertion. A successful RFA was defined

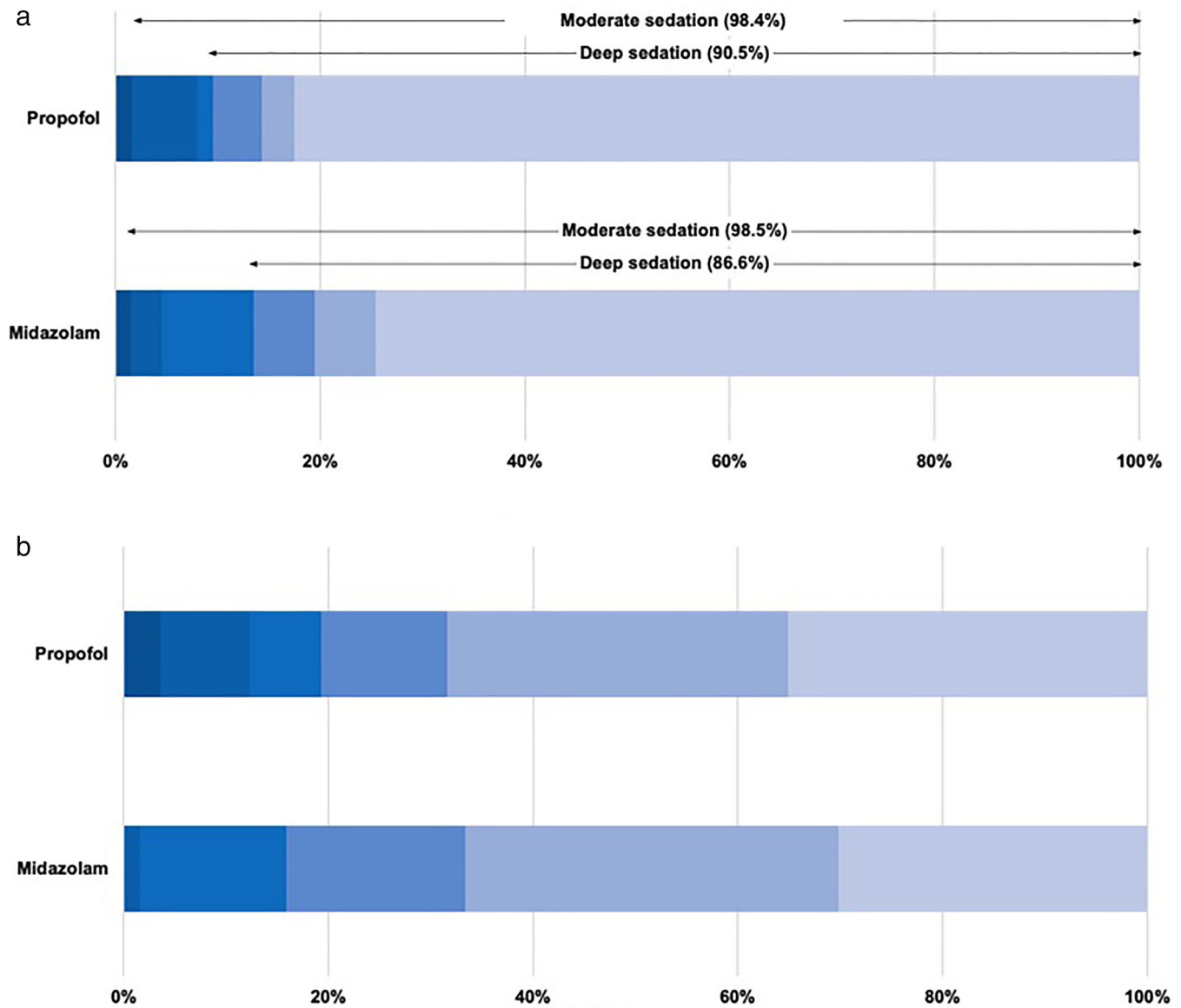


Figure 3 Depths of sedation (a) and pain assessments (b) during radiofrequency ablation. (a): (■), 5; (■), 4; (■), 3; (■), 2; (■), 1; (■), 0. (b): (■), 5; (■), 4; (■), 3; (■), 2; (■), 1; (■), 0.

as a target lesion—selected at the time of enrollment—confirmed as being completely ablated according to the radiological assessment.

Drug administration. Drug infusion was performed by the attending hepatologists who had been trained by anesthesiologists. The predefined light sedation protocol developed by two anesthesiologists (Natsuko Nozaki-Taguchi and Shiroh Isono) is shown in Figure S1, Supporting information. A dose of 0.6 mg/kg/h of propofol was administered intravenously when commencing the RFA procedure. After confirming that the needle had been inserted correctly into the tumor, 0.2 mg/kg of propofol was slowly injected intravenously, and the dose was increased to 1.0 mg/kg/h. During ablation, the depth of sedation was monitored using a bispectral index, and the dosage of propofol was adjusted to between 0.3 mg/kg/h and 1.0 mg/kg/h according to the bispectral index 60–80.²² A total of 0.06 mg/kg of midazolam was administered by intravenous injection directly after confirming correct introduction of the needle of RFA into the tumor. Additional intravenous injections of midazolam at a dose of 0.03 mg/kg were allowed under RFA ablation according to the bispectral index 60–80. After completion of the RFA procedure, 0.5 mg of flumazenil was injected intravenously for recovery from sedation in the midazolam group. To alleviate pain during the procedure, fentanyl was administered during the procedure in both groups. The protocol for fentanyl desensitization was predefined using a simulation program.

Primary and secondary end-points. The primary end-point of the present trial was patient satisfaction, which was assessed with a 100-mm visual analog scale (VAS) (0 mm = least

satisfied and 100 mm = most satisfied). The preplanned secondary end-points were as follows: achievement rates of sedation according to MOAA/S score (moderate sedation: MOAA/S score ≤ 4 , deep sedation: MOAA/S score ≤ 2),²⁵ treatment completion rate, subjective feeling of pain as assessed using a 5-point scale (0 = least pain and 5 = worst pain), recovery rates of sedation according to MOAA/S score as measured every hour for 4 h after RFA, safety of treatment during the RFA procedure, and safety of treatment after the RFA procedure. The Common Terminology Criteria for Adverse Events (CTCAE) version 4.0 protocol was used for the assessment of adverse events.

Sample size. Superiority of the propofol group over the midazolam group was defined as a 10-mm higher VAS score for patient satisfaction in the propofol group compared with the midazolam group. Assuming a 70-mm VAS score for patient satisfaction in the midazolam group, a sample size of 128 patients (propofol group, 64 patients; midazolam group, 64 patients) was required to detect a difference in VAS score of at least 10 mm, using an alpha error of 0.05 and a beta error of 0.20. A total of 140 patients (propofol group, 70 patients; midazolam group, 70 patients) were enrolled in anticipation of the ineligibility of some patients.

Statistical analysis. Pearson's chi-squared test or Fisher's exact test was used as appropriate. An unpaired *t*-test was used to compare means between independent groups. All statistical analyses were conducted using the SAS statistical software (version 9.4, SAS Institute Inc., Cary, NC, USA).

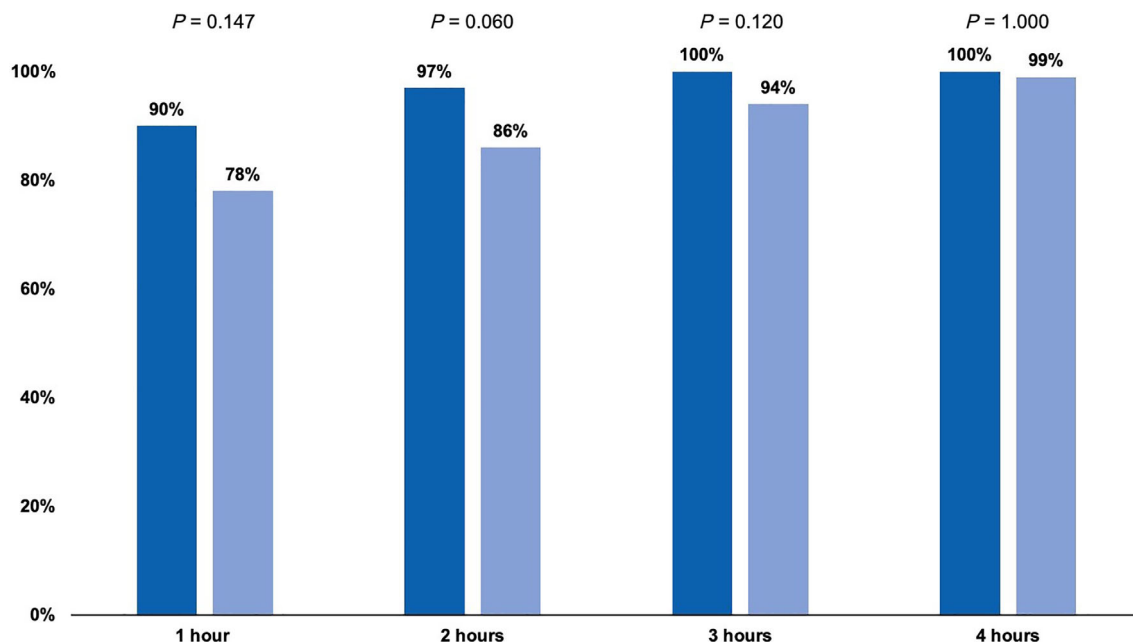


Figure 4 Frequencies of fully recover after radiofrequency ablation according to Modified Observer's Assessment of Alertness/Sedation score. (■), Propofol; (▨), midazolam.

Table 2 Vital signs during radiofrequency ablation

	Propofol regimen		Midazolam regimen		<i>P</i>
	Mean (SD)	Range	Mean (SD)	Range	
Systolic blood pressure (mmHg)					
Maximum	165 (25)	127–259	154 (22)	112–209	0.006
Minimum	94 (17)	64–158	90 (15)	53–131	0.237
Diastolic blood pressure (mmHg)					
Maximum	124 (24)	64–177	114 (22)	61–170	0.022
Minimum	75 (14)	42–107	69 (16)	19–107	0.034
Heart rate (/min)					
Maximum	83 (15)	52–122	85 (16)	56–130	0.631
Minimum	68 (13)	40–100	69 (13)	41–115	0.623
Oxygen saturation (%)					
Minimum	92 (6)	72–100	94 (3)	80–100	0.015
Oxygen flow rate, liter/min					
Maximum	2.1 (0.5)	2.0–5.0	2.1 (0.4)	2.0–5.0	0.928

Results

Patient characteristics. Figure 1 shows the CONSORT flow diagram for the patients included in the present clinical trial. Between July 2013 and September 2017, a total of 143 patients with HCC were enrolled, and 135 patients were randomly assigned to the two treatment groups. All 135 patients received RFA and were included in the final analysis. Thus, a total of 65 patients were randomly assigned to the propofol regimen, while 70 patients were assigned to the midazolam regimen.

The median age was 70 years (range, 49–85 years), and 70.4% (95 patients) were male (Table 1). The majority of the patients belonged to the Child–Pugh A category (score 5, 99

patients [73.3%]; score 6, 29 patients [21.5%]). Regarding tumor size and number, 64 patients (47.4%) had single lesions ≤ 2 cm in size, and 85 patients (63.0%) had tumors located in nearby vessels. More than half of patients (54.8%) had a previous history of RFA. Baseline demographic data and patient characteristics did not differ significantly between the propofol and midazolam regimens (Table 1).

VAS scores after RFA procedure. The results for the primary end-point are shown in Figure 2. Mean VAS scores in the propofol and midazolam arms were 73.1 (SD, 35.5) and 76.9 (SD, 29.1), respectively, with no significant difference between the two groups ($P = 0.574$). In addition, the proportion of VAS

Table 3 Adverse events during and after radiofrequency ablation

	Propofol regimen		Midazolam regimen		<i>P</i>	
	Any grade	Grade 3 \leq	Any grade	Grade 3 \leq	Any grade	Grade 3 \leq
During radiofrequency ablation [<i>n</i> (%)]						
Hypertension	50 (76.9)	35 (53.9)	50 (71.4)	25 (35.7)	0.557	0.039
Abdominal pain	10 (15.4)	0 (0)	14 (20.0)	2 (2.9)	0.509	0.497
Nausea	8 (12.3)	0 (0)	8 (11.4)	0 (0)	1.000	—
Vomiting	6 (9.2)	0 (0)	5 (7.1)	0 (0)	0.758	—
Vasovagal reaction	2 (3.1)	2 (3.1)	4 (5.7)	4 (5.7)	0.682	0.682
Apnea	4 (6.2)	4 (6.2)	2 (2.9)	2 (2.9)	0.428	0.428
Intra-abdominal hemorrhage	3 (4.6)	1 (1.5)	1 (1.5)	0 (0)	0.109	0.482
After radiofrequency ablation [<i>n</i> (%)]						
AST increase	58 (89.2)	22 (33.9)	60 (85.7)	25 (35.7)	0.610	0.858
Hypoalbuminemia	27 (41.5)	0 (0)	36 (51.4)	0 (0)	0.301	—
Anemia	25 (38.5)	2 (3.1)	33 (47.1)	0 (0)	0.385	0.230
Blood bilirubin increase	17 (26.2)	2 (3.1)	35 (50.0)	0 (0)	0.005	0.230
Platelet count decrease	22 (33.9)	6 (9.2)	22 (31.4)	5 (7.1)	0.855	0.758
White blood cell decrease	9 (13.9)	2 (3.1)	10 (14.3)	0 (0)	1.000	0.230
Anorexia	10 (15.4)	0 (0)	8 (11.4)	0 (0)	0.614	—
Fever	6 (9.2)	0 (0)	8 (11.4)	0 (0)	0.781	—
Abdominal pain	6 (9.2)	0 (0)	5 (7.1)	0 (0)	0.758	—
Hypertension	3 (4.6)	2 (3.1)	2 (2.9)	0 (0)	0.672	0.230

[†]Listed adverse events defined by the National Cancer Institution Common Terminology Criteria (version 4.0).

Abbreviations: ALP, alkaline phosphatase; ALT, alanine aminotransferase; AMY, amylase; AST, aspartate aminotransferase; GGT, gamma-glutamyl transpeptidase.

score ratings ≥ 70 mm in both groups did not differ significantly (propofol, 72.7%; midazolam, 75.4%; $P = 0.835$).

Procedure, depth of sedation, and recovery time.

Of the 65 patients in the propofol arm, 58 patients (89.2%) successfully completed treatment, with all target lesions being ablated. Likewise, successful RFA was achieved for 64 of the 70 patients (91.4%) in the midazolam arm. The achievement rates of moderate and deep sedation according to MOAA/S scores are displayed in Figure 3a. We observed high frequency rates of achieving moderate and deep sedation in both arms (moderate sedation, $P = 0.587$; deep sedation, $P = 1.000$). Figure 3b demonstrates the results of pain assessment during the RFA procedure according to the 5-point scale scores. There was no significant difference between the two groups ($P = 0.198$). After the RFA procedure, MOAA/S scores were assessed every hour for 4 h. The distribution of MOAA/S scores is shown in Figure 4. Recovery rates observed 1 and 2 h after RFA procedure were higher in the propofol group than in the midazolam group.

Safety evaluation under and after RFA treatment.

We monitored blood pressure, heart rate, and oxygen saturation every 2 min during the RFA procedure (Table 2). Maximum systolic and diastolic pressures were significantly higher in the propofol group than in the midazolam group. Table 3 displays data pertaining to adverse events according to the CTCAE v4.0 before and after RFA treatments. The most common adverse events during the RFA procedure were hypertension, abdominal pain, nausea, and vomiting. On the other hand, increased AST, hypoalbuminemia, anemia, increased blood bilirubin, and decreased platelet counts were the most common adverse events observed after RFA. The frequency of severe hypertension during the RFA procedure was significantly higher in the propofol group compared with the midazolam group. No significant differences in other adverse events were observed between the two groups.

Discussion

The present investigator-initiated, single-blind, randomized trial analyzed the clinical outcomes in HCC patients who received RFA with the use of either propofol or midazolam for gastroenterologist-administered moderate sedation. Faster recovery times after RFA were observed when propofol was used for sedation compared with midazolam; however, overall satisfaction, which was the primary end-point, did not differ between the two groups. Moreover, the safety profiles in both study arms were almost identical during and after RFA. We believe that our results can inform the development of a standard protocol for sedation during RFA in patients with HCC, which is highly warranted.^{20,21}

Full recovery rates as observed 1 and 2 h after RFA according to MOAA/S score were higher in the propofol arm compared with the midazolam arm. On the other hand, full recovery rates 3 and 4 h after RFA were almost identical between two groups. Our results thereby suggested that patients using propofol recovered earlier than those receiving midazolam. Although similar observations have been published in several studies in various treatment procedures related to endoscopy,^{25,29}

to the best of our knowledge, the present study is the first to identify faster recovery times using propofol compared with midazolam for RFA in HCC patients using a well-designed randomized controlled trial.

No significant superior overall satisfaction regarding sedation during RFA using propofol was observed when compared with the use of midazolam. Regarding other procedures, such as an upper gastrointestinal endoscopy, Levitzky *et al.* reported that propofol sedation by adequately trained endoscopists resulted in superior patient satisfaction compared with midazolam sedation during upper gastrointestinal endoscopy.²⁶ All patients included in their study were outpatients undergoing upper gastrointestinal endoscopy. On the other hand, all of the patients included in the present study were hospitalized. Taken together, outpatients who need to return home on the same day may feel satisfied about fast recovery. From the point of view of medical staff, achieving faster full recovery after RFA should be conducive to reducing the workload related to post-RFA patient monitoring.

The present study assessed complications during and after RFA separately. To the best of our knowledge, this article was the first to report on safety during RFA with moderate sedation. Our results showed that hypertension was the most common adverse event in both of the groups. Other common adverse events during RFA included abdominal pain, nausea, and vomiting. Meanwhile, we observed only a limited number of vasovagal reactions and cases of apnea, which are well-known adverse events related to the use of sedative agents.

In the present study, sedation by either propofol or midazolam was controlled by hepatologists. Deep sedation rates in the propofol and midazolam groups amounted to 88.5 and 90.5%, respectively. Rates of complete painlessness in the propofol and the midazolam groups were only 32.5 and 35.1%, respectively. Hence, for some patients in both groups, it was not possible to achieve successful sedation. Taken together, we judged that hepatologists, who are not specialists of anesthesiology, might have had some difficulties in controlling the sedation possibly due to fear of oversedation, although they had been trained by anesthesiologists before taking control of the sedative agents. As hepatologist-administered sedation has been widely used in several procedures, including RFA, standardization of education programs for nonspecialists in anesthesiology is strongly required.

According to the primary end-point and sample size calculation that we set up based on the data of the retrospective cohort in our institution, we were unable to prove the superiority of sedation by propofol compared with by midazolam. If the trial design is reconsidered by experts including biostatisticians, we may be able to show the result that shows the superiority of propofol to midazolam during RFA in patients with HCC.

In conclusion, propofol sedation during RFA by hepatologists resulted in faster full recovery time compared with midazolam sedation in patients with HCC; however, post-RFA patient satisfaction was similar in the two groups. As the safety profiles of propofol and midazolam sedation during and after RFA were acceptable, deep sedation during RFA should be considered a feasible option by hepatologists for patients with HCC. Therefore, a standard education program for hepatologists who perform sedation in daily practice is strongly required.

Acknowledgments

We thank the following people for their contributions to the data management: Michiko Hanawa, Yoko Hattori, Mayumi Negishi, and Makiko Matsui.

References

- Torre LA, Bray F, Siegel RL, Ferlay J, Lortet-Tieulent J, Jemal A. Global cancer statistics, 2012. *CA Cancer J. Clin.* 2015; **65**: 87–108.
- Llovet JM, Zucman-Rossi J, Pikarsky E, Sangro B, Schwartz M, Sherman M. Hepatocellular carcinoma. *Nat. Rev. Dis. Primers.* 2016; **14**: 16018.
- Bray F, Ferlay J, Soerjomataram I, Siegel RL, Torre LA, Jemal A. Global cancer statistics 2018: GLOBOCAN estimates of incidence and mortality worldwide for 36 cancers in 185 countries. *CA Cancer J. Clin.* 2018; **68**: 394–424.
- Forner A, Reig M, Bruix J. Hepatocellular carcinoma. *Lancet.* 2018; **391**: 1301–14.
- Kokudo N, Takemura N, Hasegawa K *et al.* Clinical practice guidelines for hepatocellular carcinoma: the Japan Society of Hepatology 2017 (4th JSH-HCC guidelines) 2019 update. *Hepatol. Res.* 2019; **49**: 1109–13.
- European Association for the Study of the Liver, European Association for the Study of the Liver. EASL clinical practice guidelines: management of hepatocellular carcinoma. *J. Hepatol.* 2018; **69**: 182–236.
- Omata M, Cheng AL, Kokudo N *et al.* Asia-Pacific clinical practice guidelines on the management of hepatocellular carcinoma: a 2017 update. *Hepatol. Int.* 2017; **11**: 317–70.
- Shiina S, Tateishi R, Arano T *et al.* Radiofrequency ablation for hepatocellular carcinoma: 10-year outcome and prognostic factors. *Am. J. Gastroenterol.* 2012; **107**: 569–77.
- Shindoh J, Makuuchi M, Matsuyama Y *et al.* Complete removal of the tumor-bearing portal territory decreases local tumor recurrence and improves disease-specific survival of patients with hepatocellular carcinoma. *J. Hepatol.* 2016; **64**: 594–600.
- Rossi S, Di Stasi M, Buscarini E *et al.* Percutaneous radio frequency interstitial thermal ablation in the treatment of small hepatocellular carcinoma. *Cancer J. Sci. Am.* 1995; **1**: 73–81.
- Livraghi T, Goldberg SN, Lazzaroni S, Meloni F, Solbiati L, Gazelle GS. Small hepatocellular carcinoma: treatment with radiofrequency ablation versus ethanol injection. *Radiology.* 1999; **210**: 655–61.
- Shiina S, Teratani T, Obi S *et al.* A randomized controlled trial of radiofrequency ablation with ethanol injection for small hepatocellular carcinoma. *Gastroenterology.* 2005; **129**: 122–30.
- Tateishi R, Shiina S, Teratani T. Percutaneous radiofrequency ablation for hepatocellular carcinoma. An analysis of 1000 cases. *Cancer.* 2005; **103**: 1201–9.
- Hasegawa K, Kokudo N, Makuuchi M *et al.* Comparison of resection and ablation for hepatocellular carcinoma: a cohort study based on a Japanese nationwide survey. *J. Hepatol.* 2013; **58**: 724–9.
- Chen MS, Li JQ, Zheng Y *et al.* A prospective randomized trial comparing percutaneous local ablative therapy and partial hepatectomy for small hepatocellular carcinoma. *Ann. Surg.* 2006; **243**: 321–8.
- Feng K, Yan J, Li X *et al.* A randomized controlled trial of radiofrequency ablation and surgical resection in the treatment of small hepatocellular carcinoma. *J. Hepatol.* 2012; **57**: 794–802.
- Fang Y, Chen W, Liang X *et al.* Comparison of long-term effectiveness and complications of radio-frequency ablation with hepatectomy for small hepatocellular carcinoma. *J. Gastroenterol. Hepatol.* 2014; **29**: 193–200.
- Huang J, Yan L, Cheng Z *et al.* A randomized trial comparing radiofrequency ablation and surgical resection for HCC conforming to the Milan criteria. *Ann. Surg.* 2010; **252**: 903–12.
- Izumi N, Hasegawa K, Nishioka Y *et al.* A multicenter randomized controlled trial to evaluate the efficacy of surgery vs. radiofrequency ablation for small hepatocellular carcinoma (SURF trial). *J. Clin. Oncol.* 2019; **37** (15_suppl): 4002.
- Sato K, Taniki N, Kanazawa R *et al.* Efficacy and safety of deep sedation in percutaneous radiofrequency ablation for hepatocellular carcinoma. *Adv. Ther.* 2019; **36**: 344–54.
- Joung KW, Choi SS, Jang DM *et al.* Comparative effects of dexmedetomidine and propofol on US-guided radiofrequency ablation of hepatic neoplasm under monitored anesthesia care: a randomized controlled study. *Medicine (Baltimore).* 2015; **94**: e1349.
- Lera dos Santos ME, Maluf-Filho F, Chaves DM *et al.* Deep sedation during gastrointestinal endoscopy: propofol-fentanyl and midazolam-fentanyl regimens. *World J. Gastroenterol.* 2013; **19**: 3439–46.
- Correia LM, Bonilha DQ, Gomes GF *et al.* Sedation during upper GI endoscopy in cirrhotic outpatients: a randomized, controlled trial comparing propofol and fentanyl with midazolam and fentanyl. *Gastrointest. Endosc.* 2011; **73**: 45–51.
- Akbulut UE, Saylan S, Sengu B, Akcali GE, Erturk E, Cakir M. A comparison of sedation with midazolam-ketamine versus propofol-fentanyl during endoscopy in children: a randomized trial. *Eur. J. Gastroenterol. Hepatol.* 2017; **29**: 112–8.
- Levitzy BE, Lopez R, Dumot JA, Vargo JJ. Moderate sedation for elective upper endoscopy with balanced propofol versus fentanyl and midazolam alone: a randomized clinical trial. *Endoscopy.* 2012; **44**: 13–20.
- Ahmed SA, Selim A, Hawash N *et al.* Randomized controlled study comparing use of propofol plus fentanyl versus midazolam plus fentanyl as sedation in diagnostic endoscopy in patients with advanced liver disease. *Int. J. Hepatol.* 2017; **2017**: 8462756.
- Watanabe K, Hikichi T, Takagi T *et al.* Propofol is a more effective and safer sedative agent than midazolam in endoscopic injection sclerotherapy for esophageal varices in patients with liver cirrhosis: a randomized controlled trial. *Fukushima J. Med. Sci.* 2018; **64**: 133–41.
- Dumonceau JM, Riphaus A, Schreiber F *et al.* Non-anesthesiologist administration of propofol for gastrointestinal endoscopy: European Society of Gastrointestinal Endoscopy, European Society of Gastroenterology and Endoscopy Nurses and Associates Guideline—updated June 2015. *Endoscopy.* 2015; **47**: 1175–89.
- Wang Z, Hu Z, Dai T. The comparison of propofol and midazolam for bronchoscopy: a meta-analysis of randomized controlled studies. *Medicine (Baltimore).* 2018; **97**: e12229.

Supporting information

Additional supporting information may be found in the online version of this article at the publisher's website:

Figure S1. Sedation protocols of this study.