



CASE REPORT

Coronavirus Disease (Covid-19) Associated Mucormycosis (CAM): Case Report and Systematic Review of Literature

Deepak Garg · Valliappan Muthu · Inderpaul Singh Sehgal · Raja Ramachandran ·
Harsimran Kaur · Ashish Bhalla · Goverdhan D. Puri · Arunaloke Chakrabarti ·
Ritesh Agarwal 

Received: 9 December 2020 / Accepted: 15 January 2021 / Published online: 5 February 2021
© The Author(s), under exclusive licence to Springer Nature B.V. part of Springer Nature 2021

Abstract Severe coronavirus disease (COVID-19) is currently managed with systemic glucocorticoids. Opportunistic fungal infections are of concern in such patients. While COVID-19 associated pulmonary aspergillosis is increasingly recognized, mucormycosis is rare. We describe a case of probable pulmonary mucormycosis in a 55-year-old man with diabetes, end-stage kidney disease, and COVID-19. The index case was diagnosed with pulmonary mucormycosis 21 days following admission for severe COVID-19.

He received 5 g of liposomal amphotericin B and was discharged after 54 days from the hospital. We also performed a systematic review of the literature and identified seven additional cases of COVID-19 associated mucormycosis (CAM). Of the eight cases included in our review, diabetes mellitus was the most common risk factor. Three subjects had no risk factor other than glucocorticoids for COVID-19. Mucormycosis usually developed 10–14 days after hospitalization. All except the index case died. In two subjects, CAM was diagnosed postmortem. Mucormycosis is an uncommon but serious infection that complicates the course of severe COVID-19. Subjects with diabetes mellitus and multiple risk factors may be at a higher

Handling Editor: Sanjay Haresh Chotirmall.

Deepak Garg and Valliappan Muthu contributed equally to the manuscript and are the joint first authors.

D. Garg · V. Muthu · I. S. Sehgal · R. Agarwal (✉)
Department of Pulmonary Medicine, Postgraduate
Institute of Medical Education and Research (PGIMER),
Sector-12, Chandigarh 160012, India
e-mail: agarwal.ritesh@outlook.in

R. Ramachandran
Department of Nephrology, Postgraduate Institute of
Medical Education and Research (PGIMER), Chandigarh,
India

H. Kaur · A. Chakrabarti
Department of Medical Microbiology, Postgraduate
Institute of Medical Education and Research (PGIMER),
Chandigarh, India

A. Bhalla
Department of Internal Medicine, Postgraduate Institute
of Medical Education and Research (PGIMER),
Chandigarh, India

G. D. Puri
Department of Anesthesia and Intensive Care,
Postgraduate Institute of Medical Education and Research
(PGIMER), Chandigarh, India

risk for developing mucormycosis. Concurrent glucocorticoid therapy probably heightens the risk of mucormycosis. A high index of suspicion and aggressive management is required to improve outcomes.

Keywords Zygomycosis · *Mucorales* · Tocilizumab · Dexamethasone · Diabetes · CAPA

Introduction

The pandemic coronavirus disease 2019 (COVID-19) continues to be a significant problem worldwide. While several treatment options have been evaluated, none except systemic glucocorticoids have been shown to improve survival in COVID-19. Unfortunately, the widespread use of glucocorticoids can lead to secondary bacterial or fungal infections. Invasive pulmonary aspergillosis complicating the course of COVID-19 is widely recognized; [1] however, mucormycosis is uncommonly suspected or diagnosed. Herein, we report a case of pulmonary mucormycosis in a patient with severe COVID-19. We also perform a systematic review of literature to identify cases of COVID-19 associated mucormycosis (CAM) and describe their clinical features, risk factors, and outcome.

Case Presentation

A 55-year-old man with long-standing diabetes mellitus, hypertension, and ischemic cardiomyopathy presented with fever, dry cough, and progressive breathlessness of three days duration. He was diagnosed with type 2 diabetes mellitus ten years before the current illness and was on irregular treatment with different oral hypoglycemic drugs. Blood sugar monitoring was infrequent. He also had end-stage renal disease and was receiving maintenance hemodialysis for the last one year. The patient was a never-smoker and denied any substance abuse. At admission, the respiratory rate was 26 breaths/minute, blood pressure 110/80 mmHg, and heart rate of 90 beats/minute. The oxygen saturation was 84% while breathing ambient air and improved to 95% with a venturi mask (fraction of inspired oxygen, 0.5). The patient was not obese (body mass index of 24 kg/m²).

Chest radiograph showed bilateral diffuse interstitial opacities and cardiomegaly (Fig. 1a). A nasopharyngeal swab was positive for SARS-CoV-2 by RT-PCR. The hemoglobin at admission was 7.8 g/dL, and glycated hemoglobin was 5.3% (Table 1). He was started on intravenous dexamethasone (6 mg once a day for 14 days) and remdesivir (200 mg on day 1 and 100 mg on days 2–5). Supportive care, including oxygen supplementation, thromboprophylaxis for venous thrombosis, and maintenance hemodialysis, were continued. His random plasma glucose at admission was 140 mg/dL and increased to a

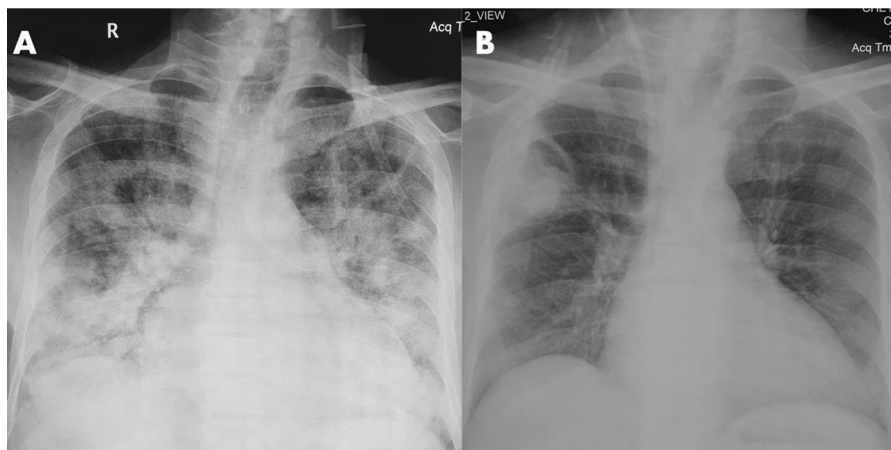
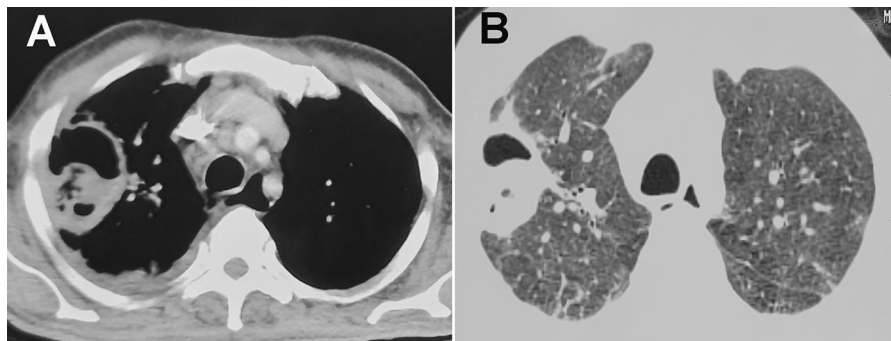


Fig. 1 Chest radiograph at admission **a** showing bilateral diffuse infiltrates and cardiomegaly. In the third week of hospitalization, a cavity with intracavitary content **b** can be seen in the right upper zone

Table 1 Partial list of investigations in the index patient with pulmonary mucormycosis (PM) following treatment for COVID-19

Investigations	At presentation	Day 21 (Diagnosis of PM)
Hemoglobin, g/dL	7.8	6.6
TLC, / μ L	6100	12,500
DLC (N/L/E), %	90/6/4	82/9/7.4
Absolute lymphocyte count, / μ L	366	1125
Absolute neutrophil count, / μ L	5490	10,250
Platelet count, / μ L	60,000	222,700
Blood urea, mg/dL	20	63
Serum creatinine, mg/dL	8.4	3
Total bilirubin, mg/dL	0.3	0.5
Alanine aminotransferase, U/L	48	15
Aspartate aminotransferase, U/L	8	3
Alkaline phosphatase, IU/L	144	100
Arterial pH	7.33	7.44
pCO ₂	22	29
HCO ₃	13	20
PO ₂	36.5	65
Glycated hemoglobin, %	5.3	-

DLC: differential leukocyte count; E: eosinophil; L: lymphocyte; N: neutrophil; TLC: total leukocyte count

**Fig. 2** Computed tomography showing thick-walled cavity in the right upper lobe in the corresponding mediastinal **A** and lung window **B** sections

maximum of 300 mg/dL during dexamethasone therapy. After 14 days of therapy, he had clinical improvement, hypoxemia improved, and radiological resolution.

Three days later, the patient complained of cough, expectoration, and burning micturition. There was no fever, and he was not catheterized during hospitalization. Urine culture showed the growth of *Escherichia coli*. He was treated with intravenous meropenem 1 g every day (dose modified for renal impairment) for 10 days. Chest radiograph performed 21 days after admission showed a cavity with intracavitary contents in the right upper zone (Fig. 1B). Computed tomography (CT) of the thorax confirmed a thick-walled

cavity in the right upper lobe (Fig. 2A, B). Minimal pleural effusion was also seen on the right side. Sputum examination with Gram stain, stain for acid-fast bacilli, and fungal smear was negative. The sputum culture on Sabouraud dextrose agar (SDA) at 25 °C and 37 °C grew a pure culture of cottony grayish white colony 6 days after incubation. Lactophenol cotton blue (LCB) mount from the growth revealed aseptate hyphae with nodal rhizoids and short sporangiophores with terminal spherical sporangia filled with brownish sporangiospores (Fig. 3), suggestive of *Rhizopus microsporus*. The identification was confirmed by matrix-assisted laser desorption/ionization time of flight (MALDI-TOF; Bruker Daltonics,

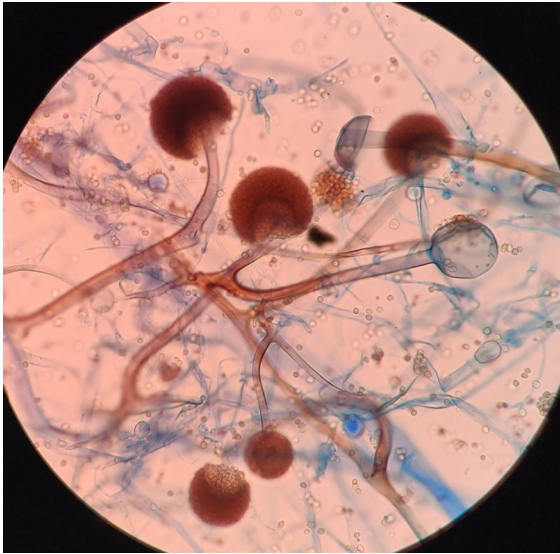


Fig. 3 Lactophenol cotton blue (LCB) mount from the growth revealed aseptate hyphae with nodal rhizoids and short sporangiophores with terminal spherical sporangia filled with brownish sporangiospores, suggestive of *Rhizopus microsporus*

Billerica, MA, USA), which gave a good discriminatory score of 2.1. The isolate was deposited in the National Culture Collection of Pathogenic Fungi (NCCPF), PGIMER, Chandigarh, India, with the accession number NCCPF 710,496. The in vitro antifungal susceptibility testing (AFST) of the isolate was performed by the microbroth dilution method as per the Clinical Laboratory Standards Institute (CLSI)-M38A2 guidelines.[2] The minimum inhibitory concentrations (MICs) of the isolate were as follows: amphotericin B, 0.5 $\mu\text{g}/\text{mL}$; itraconazole,

0.03 $\mu\text{g}/\text{mL}$; posaconazole, 2.0 $\mu\text{g}/\text{mL}$. Serum beta-D-glucan (Fungitell, Associates of Cape Cod, Inc, MA, USA) and serum galactomannan index were 189 pg/mL and 0.18 (Platelia *Aspergillus* galactomannan antigen, Bio-Rad, France), respectively. The patient was treated with liposomal amphotericin B (3 mg/kg) for probable pulmonary mucormycosis. His symptoms improved, and he was discharged 54 days after hospitalization (cumulative dose of amphotericin B, 5 gm). The patient received liposomal amphotericin (3 $\text{mg}/\text{kg}/\text{day}$) on an outpatient basis for 25 days after discharge and is scheduled for right upper lobectomy. At the time of discharge and after completion of amphotericin therapy, chest radiograph showed significant resolution of the right upper zone cavity (Fig. 4a, b).

Discussion

COVID-19 has already claimed more than one million lives worldwide. In the absence of an effective vaccine or antiviral therapy, supportive care plays a vital role in the management of COVID-19. Glucocorticoids and probably remdesivir are the only drugs proven to be beneficial in COVID-19. Glucocorticoids are inexpensive, widely available, and have been shown to reduce mortality in hypoxemic patients with COVID-19.[3] Nevertheless, glucocorticoids can increase the risk of secondary infections. Moreover, the immune dysregulation caused by the virus and the use of concurrent immunomodulatory drugs such as

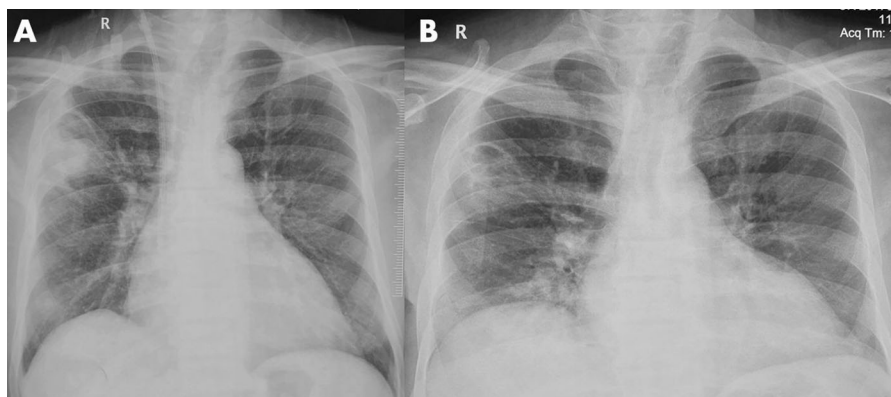


Fig. 4 Chest radiograph performed at discharge **A** and after completing amphotericin therapy **B** showed significant resolution of the right upper zone cavity

tocilizumab could further increase the risk of infections in COVID-19 patients.[4, 5].

We performed a systematic review of the PubMed and Embase databases till January 9, 2021, using the following free text terms: (“COVID” OR “SARS-CoV” OR “coronavirus”) AND (mucor* OR “zygomycosis”). We identified 21 citations, of which seven described mucormycosis in association with COVID-19 (Table 2)[6–11]. We excluded one study that described the detection of various respiratory pathogens in the throat swab of patients with SARS-CoV-2 infection (no invasive mucormycosis cases were reported).[12].

Of the eight cases reported thus far (including the index case), 3 and 2 cases were from the United States of America and India, respectively. One case each was reported from Brazil, Italy, and the United Kingdom.[6, 8, 13] The median (range) age was 57.5 (22–86) years, and seven were men. Diabetes mellitus ($n = 4$, 50%) was the most common predisposing condition; in one case, diabetes was previously undiagnosed. No traditional risk factors for mucormycosis were identified in three (37.5%) of the subjects.[6, 8, 13] Acute respiratory distress syndrome due to COVID-19 was present in seven cases. Elevated serum creatinine was seen in 5 cases, while the details were not available in the remaining three. Two subjects presented with symptoms suggesting mucormycosis (rhino-orbital mucormycosis), while the others developed mucormycosis following treatment for COVID-19 (usually between 10 and 14 days of hospitalization).[10, 11] The diagnosis was established postmortem in two subjects.[6, 8] The site of involvement by mucormycosis was rhino-orbito-cerebral ($n = 3$), pulmonary ($n = 3$), gastric ($n = 1$), and disseminated ($n = 1$). All except the index case died.

While COVID-19 associated pulmonary aspergillosis (CAPA) has received much attention, mucormycosis, another devastating disease, remains unrecognized.[1, 14] The diagnosis of CAPA relies on the presence of risk factors, consistent radiology, and demonstration of *Aspergillus* in tissue culture or microscopy.[14] While galactomannan in bronchoalveolar lavage is a useful marker of invasive pulmonary aspergillosis, its role in CAPA has not been confirmed. Invasive mold infections (invasive pulmonary aspergillosis and pulmonary mucormycosis) share similar risk factors, clinical presentation, and radiology. The diagnosis of CAM is thus even more

challenging. A lack of clinical suspicion and difficulty isolating the causative fungi might contribute to the underdiagnosis of mucormycosis. Two of the eight cases included in our review were diagnosed post-mortem. Further, biomarkers such as beta-d-glucan and galactomannan, which aid in diagnosing invasive aspergillosis, are not available for mucormycosis. To our knowledge, we report the first successfully managed case of probable pulmonary mucormycosis developing after treatment for COVID-19. Diabetes mellitus has been associated with severe COVID-19. Those with diabetes are at an increased risk of death than those without.[15] Further, poorly controlled diabetic patients may have overt or covert renal dysfunction. In our review, four and five subjects had diabetes mellitus and renal dysfunction (serum creatinine not provided in the remaining three cases), respectively (Table 2). The presence of multiple risk factors or comorbid illnesses in severe COVID-19 patients, along with the additional immunosuppression caused by glucocorticoids, increases the net state of immune suppression, thereby predisposing them to invasive mold infections.

The index patient had unmonitored blood sugar in the past and was recently diagnosed with end-stage kidney disease. Glycated hemoglobin becomes unreliable in the presence of severe anemia, especially in patients undergoing hemodialysis.[16] The favorable outcome in the current case was probably because of the better glycemic control in-hospital, and the timely initiation of liposomal amphotericin B. Previous studies have shown that amphotericin B is generally well-tolerated and can be safely administered in subjects undergoing dialysis (even with the older deoxycholate and colloidal dispersion formulations of amphotericin).[17, 18] The current guideline for the management of mucormycosis recommends liposomal amphotericin B at a dose of 5–10 mg/kg per day. In the absence of central nervous system involvement, a dose of 5 mg/kg is suggested.[19] In a randomized controlled trial of 201 patients with invasive mold disease, liposomal amphotericin used at 3 mg/kg/day was equally effective but safer and better tolerated than 10 mg/kg/day dose amphotericin.[20] Our patient had end-stage kidney disease and was on concurrent nephrotoxic medications, yet he tolerated liposomal amphotericin well. The optimal duration of therapy in mucormycosis is not clear and is guided by

Table 2 Summary of the COVID-19 associated mucormycosis (CAM) reported in the literature

Author/country	Age in years/sex	Comorbid illness	Clinical presentation	Treatment for COVID-19	Other treatments	Investigations	Antemortem diagnosis of CAM	Organs involved by CAM	Outcome	Remarks	
Hanley et al./UK[6]	22/male	Obesity (BMI 48.8)	COVID ARDS (mechanically ventilated)	None mentioned	Linezolid	Lymphocyte count and serum creatinine, not provided	No (Autopsy diagnosis)	Lungs	Died (D27)	No traditional risk factors	
Werthman-Ehrenreich/USA[10]	33/female	Hypothyroidism	Pulmonary emboli	Meropenem	Meropenem			Hilar lymph nodes			
		Hypertension	Altered mentation, proptosis	Remdesivir	Caspofungin			Heart and pericardium			
		Asthma	DKA and rhino-orbital mucormycosis	Convalescent plasma	Piperacilin tazobactam			Brain			
Mehta et al./India[7]	60/male	Diabetes mellitus	COVID ARDS requiring mechanical ventilation	Inj methylprednisolone 40 mg BD	Meropenem	Lymphopenia (5.9%)	Yes (suspected at presentation)	Rhino-orbital-cerebral	Died (D26)	-	
		Previously undiagnosed diabetes mellitus		No mention of glucocorticoids	Piperacilin tazobactam	Elevated serum creatinine (2.28 mg/dL)					
Mehta et al./India[7]	60/male	Diabetes mellitus	COVID ARDS requiring mechanical ventilation	Inj methylprednisolone 40 mg BD	Meropenem	Lymphopenia (9.60%)	Yes (Symptoms developed at D10)	Rhino-orbital	Died	-	
		Peripheral vascular disease due to diabetes		Dexamethasone 4 mg BD	Oseltamivir	Elevated serum creatinine (1.57 mg/dL)					
				Tocilizumab 400 mg	Amphotericin (0.5 mg/kg/day, conventional)						

Table 2 continued

Author/country	Age in years/sex	Comorbid illness	Clinical presentation	Treatment for COVID-19	Other treatments	Investigations	Antemortem diagnosis of CAM	Organs involved by CAM	Outcome	Remarks
Monte junior et al./Brazil[8]	86/male	Hypertension	COVID ARDS and diarrhea	Hydrocortisone	Ceftriaxone	Lymphopenia (5.3%)	No	Gastric (presentation with malena, drop in hemoglobin, and large ulcers identified on endoscopy)	Died (D5)	No traditional risk factors
Placik et al./USA[9]	49/male		COVID ARDS	Remdesivir	Azithromycin	Elevated serum creatinine (2.34 mg/dL)	Yes (D14 developed spontaneous pneumothorax)	Pulmonary mucormycosis with bronchopleural fistula and pneumothorax	Died (D21)	Surgery and amphotericin for mucormycosis (6 days)
					Oseltamivir					
Mekkonen et al./USA[11]	60/male	Diabetes mellitus (HbA1C 14%)	COVID ARDS (mechanically ventilated)	Tocilizumab	Azithromycin	Lymphocyte count and serum creatinine, not provided	Yes (D10 of hospitalization)	Rhino-orbital	Died (D31)	The patient had symptoms suggestive of mucormycosis on D2 of hospitalization (D8 of illness)
				Dexamethasone	Amphotericin B (formulation not mentioned)	NA				
		Asthma		Remdesivir	Cefepime					
		Hypertension		Dexamethasone (6 mg)	Vancomycin					
				Convalescent plasma therapy (single session)	Amphotericin B (liposomal)					
					Endoscopic surgical debridement					

Table 2 continued

Author/country	Age in years/sex	Comorbid illness	Clinical presentation	Treatment for COVID-19	Other treatments	Investigations	Antemortem diagnosis of CAM	Organs involved by CAM	Outcome	Remarks
Pasero et al./Italy [13]	66/male	Hypertension	COVID ARDS (mechanically ventilated)	Hydroxychloroquine	Meropenem	Lymphopenia (400/ μ L)	Yes (D14 after ICU admission)	Lung Maxillary sinus thickening on computed tomography (not proven to be mucormycosis)	Died (D62)	No traditional risk factors
				Lopinavir–ritonavir	Linezolid	Renal failure requiring dialysis (creatinine not provided)				
					Amphotericin B (20 days of liposomal preparation 5 mg/kg/d) Isavuconazole after stopping amphotericin					
Index case	55/male	Diabetes mellitus	COVID ARDS (not mechanically ventilated)	Dexamethasone	Meropenem	Lymphopenia (6%)	Yes (Suspected when worsened on D14, <i>Rhizopus microsporus</i> isolated in sputum)	Lung	Alive (D54)	Partial resolution of lung lesion Awaiting right upper lobectomy
					Amphotericin B (liposomal preparation 3 mg/kg/day; cumulative 5 g)	Elevated serum creatinine (range 3–8 mg/dL)				
		Ischemic cardiomyopathy								
		End-stage renal disease								

ARDS: acute respiratory distress syndrome; BMI—body mass index; COVID: coronavirus disease; *E.coli*: *Escherichia coli*; *HbA1c*: glycated hemoglobin

the treatment regimen's clinical response and tolerability.

Pulmonary mucormycosis is increasingly diagnosed, and the case fatality has improved over time.[21] Control of hyperglycemia, early treatment with liposomal amphotericin B, and surgery are essential for the successful management of mucormycosis.[19, 22, 23] However, COVID-19 has created a unique scenario where all three aspects of the management are compromised. Firstly, hyperglycemia is aggravated by the most effective therapy for severe COVID-19, namely glucocorticoids. Coexisting ARDS and multiorgan dysfunction preclude timely diagnostic imaging and testing.[13] Finally, the hospitals are overwhelmed by COVID-19 patients, and essential services, including diagnostics and surgeries, could be significantly curtailed.[24] Hence, the mortality in CAM (87.5% in the current series) maybe even higher than that observed in non-COVID patients.[21, 23, 25].

One alarming observation was the absence of traditional risk factors, such as diabetes mellitus, transplantation, or hematological malignancies, in three subjects with CAM. The development of mucormycosis can probably be attributed to the use of glucocorticoids and suggests a need for their judicious use. Thus, the use of glucocorticoids in mild COVID-19 cases (without hypoxemia) or the utilization of higher doses of glucocorticoids should be avoided. Further, in the absence of a clear benefit, drugs targeting immune pathways such as tocilizumab should be discouraged.[5].

In summary, physicians caring for critically ill COVID-19 patients must be aware of serious infections that can complicate the course of COVID-19. A high degree of clinical suspicion is required to diagnose pulmonary mucormycosis.[26] Early diagnosis and timely management are necessary to improve outcomes in pulmonary mucormycosis.

Compliance with ethical standards

Conflict of interest The authors declare that there is no conflict of interest.

References

1. Arastehfar A, Carvalho A, van de Veerdonk FL, Jenks JD, Koehler P, Krause R, et al. COVID-19 associated pulmonary aspergillosis (CAPA)-from immunology to treatment. *J Fungi (Basel)*. 2020;6(2):91.
2. Reference method for broth dilution antifungal susceptibility testing of filamentous fungi: approved standard-second edition. CLSI document M38-A2. Clinical and Laboratory Standards Institute, Wayne, PA: CLSI, 2008.
3. Group WHOEAfC-TW, Sterne JAC, Murthy S, Diaz JV, Slutsky AS, Villar J, et al. Association between administration of systemic corticosteroids and mortality among critically ill patients with COVID-19: a meta-analysis. *JAMA*. 2020;324(13):1330–13341.
4. Kumar G, Adams A, Herrera M, Rojas ER, Singh V, Sakhuja A, et al. Predictors and outcomes of hais in COVID-19 patients. *Int J Infect Dis*. 2020;104(3):287–92.
5. Kimmig LM, Wu D, Gold M, Pettit NN, Pittrak D, Mueller J, et al. IL-6 inhibition in critically ill COVID-19 patients is associated with increased secondary infections. *Front Med (Lausanne)*. 2020;7:583897.
6. Hanley B, Naresh KN, Roufousse C, Nicholson AG, Weir J, Cooke GS, et al. Histopathological findings and viral tropism in UK patients with severe fatal COVID-19: a post-mortem study. *Lancet Microbe*. 2020;1(6):e245–53.
7. Mehta S, Pandey A. Rhino-orbital mucormycosis associated with COVID-19. *Cureus*. 2020;12(9):e10726.
8. Monte Junior ESD, Santos M, Ribeiro IB, Luz GO, Baba ER, Hirsch BS, et al. Rare and fatal gastrointestinal mucormycosis (Zygomycosis) in a COVID-19 patient: a case report. *Clin Endosc*. 2020;53(6):746–9.
9. Placik DA, Taylor WL, Wnuk NM. Bronchopleural fistula development in the setting of novel therapies for acute respiratory distress syndrome in SARS-CoV-2 pneumonia. *Radiol Case Rep*. 2020;15(11):2378–81.
10. Werthman-Ehrenreich A. Mucormycosis with orbital compartment syndrome in a patient with COVID-19. *Am J Emerg Med*. 2020. <https://doi.org/10.1016/j.ajem.2020.09.032>.
11. Mekonnen ZK, Ashraf DC, Jankowski T, Grob SR, Vagefi MR, Kersten RC, et al. Acute Invasive Rhino-Orbital Mucormycosis in a Patient With COVID-19-Associated Acute Respiratory Distress Syndrome. *Ophthalmic Plast Reconstr Surg*. 2020. <https://doi.org/10.1097/IOP.0000000000001889>.
12. Zhu X, Ge Y, Wu T, Zhao K, Chen Y, Wu B, et al. Coinfection with respiratory pathogens among COVID-2019 cases. *Virus Res*. 2020;285:198005.
13. Pasero D, Sanna S, Liperi C, Piredda D, Branca GP, Casadio L, et al. A challenging complication following SARS-CoV-2 infection: a case of pulmonary mucormycosis. *Infection*. 2020. <https://doi.org/10.1007/s15010-020-01561-x>.
14. Koehler P, Bassetti M, Chakrabarti A, Chen SCA, Colombo AL, Hoenigl M, et al. Defining and managing COVID-19-associated pulmonary aspergillosis: the 2020 ECMM/ISHAM consensus criteria for research and clinical guidance. *Lancet Infect Dis*. 2020. [https://doi.org/10.1016/S1473-3099\(20\)30847-1](https://doi.org/10.1016/S1473-3099(20)30847-1).
15. Apicella M, Campopiano MC, Mantuano M, Mazoni L, Coppelli A, Del Prato S. COVID-19 in people with diabetes: understanding the reasons for worse outcomes. *Lancet Diabetes Endocrinol*. 2020;8(9):782–92.

16. Radin MS. Pitfalls in hemoglobin A1c measurement: when results may be misleading. *J Gen Intern Med.* 2014;29(2):388–94.
17. Wood JE, Mahnensmith MP, Mahnensmith RL, Perazella MA. Intradialytic administration of amphotericin B: clinical observations on efficacy and safety. *Am J Med Sci.* 2004;327(1):5–8.
18. Anaissie EJ, Mattiuzzi GN, Miller CB, Noskin GA, Gurwith MJ, Mamelok RD, et al. Treatment of invasive fungal infections in renally impaired patients with amphotericin B colloidal dispersion. *Antimicrob Agents Chemother.* 1998;42(3):606–11.
19. Cornely OA, Alastruey-Izquierdo A, Arenz D, Chen SCA, Dannaoui E, Hochhegger B, et al. Global guideline for the diagnosis and management of mucormycosis: an initiative of the european confederation of medical mycology in cooperation with the mycoses study group education and research consortium. *Lancet Infect Dis.* 2019;19(12):e405–21.
20. Cornely OA, Maertens J, Bresnik M, Ebrahimi R, Ullmann AJ, Bouza E, Heussel CP, Lortholary O, Rieger C, Boehme A, Aoun M, Horst H-A, Thiebaut A, Ruhnke M, Reichert D, Vianelli N, Krause SW, Olavarria E, Herbrecht R. Liposomal amphotericin B as initial therapy for invasive mold infection: A randomized trial comparing a high-loading dose regimen with standard dosing (AmBiLoad Trial). *Clin Infect Dis.* 2007;44(10):1289–1297
21. Muthu V, Agarwal R, Dhooria S, Sehgal IS, Prasad KT, Aggarwal AN, et al. Has the mortality from pulmonary mucormycosis changed over time? a systematic review and meta-analysis. *Clin Microbiol and Infect.* 2021. <https://doi.org/10.1016/j.cmi.2020.12.035>.
22. Chougule A, Muthu V, Bal A, Rudramurthy SM, Dhooria S, Das A, et al. Pulmonary gangrene due to rhizopus spp staphylococcus aureus klebsiella pneumoniae and probable sarcina organisms. *Mycopathologia.* 2015;180(12):131–6.
23. Patel A, Kaur H, Xess I, Michael JS, Savio J, Rudramurthy S, et al. A multicentre observational study on the epidemiology, risk factors, management and outcomes of mucormycosis in India. *Clin Microbiol Infect.* 2020;26(7):9–15.
24. Pandey N, Kaushal V, Puri GD, Taneja S, Biswal M, Mahajan P, et al. Transforming a general hospital to an infectious disease hospital for COVID-19 over 2 weeks. *Front Public Health.* 2020;8:382.
25. Jeong W, Keighley C, Wolfe R, Lee WL, Slavin MA, Chen SC, et al. Contemporary management and clinical outcomes of mucormycosis: a systematic review and meta-analysis of case reports. *Int J Antimicrob Agents.* 2019;53(5):589–97.
26. Muthu V, Dhooria S, Singh Sehgal I, Thurai Prasad K, Agarwal R. The reversed halo sign and the bronchus sign: the eyes see only what the mind knows. *Ann Am Thorac Soc.* 2019;16(9):1203.

Publisher's Note Springer Nature remains neutral with regard to jurisdictional claims in published maps and institutional affiliations.