

DERMATOLOGY

D I L E M M A S

Column Editor: Nicole Martinez, PhD, RN, FNP-BC, ENP-C, PHN



A New Rash Differential CoVID-19

Michael D. Gooch, DNP, APRN, ACNP-BC, FNP-BC, ENP-C

ABSTRACT

The CoVID-19 pandemic has impacted all areas of health care, especially emergency medicine. Most commonly, CoVID-19 is associated with respiratory and typical viral presentations. However, non-respiratory presentations are becoming more common. Reported CoVID-19 dermatological changes include maculopapular and urticarial rashes, chilblain-like and livedo reticularis discolorations, and less commonly vesicular and petechial rashes. As frontline clinicians, emergency nurse practitioners should be aware of these skin findings to recognize potentially infected and otherwise asymptomatic patients. Early recognition could potentially lead to an earlier diagnosis and limit the spread of severe acute respiratory syndrome coronavirus 2. **Key words:** chilblains, CoVID cutaneous manifestations, CoVID-19, CoVID rashes, CoVID toes

A MIDDLE-AGED adult woman presents to the emergency department with complaints of a rash. She states that the rash started 2 days ago and has continued to spread. She complains of intermittent pruritus, which is somewhat relieved with oral antihistamines. She states that it started on the left side of her abdomen and now

covers almost her entire abdomen and lower left arm. She is unaware of any triggers. She has not recently tried any new foods, medications, or household items. She denies changing any of her personal care products. She has not been working in the yard or been involved in any outdoor activities. She denies any previous history of rashes or skin problems.

She reports a past medical history of hypertension, which is currently controlled with lisinopril/hydrochlorothiazide daily. She denies any known drug allergies, and she is a nonsmoker. She drinks socially and denies illicit drug use. She has an intrauterine device and is unable to recall her last menstrual period. In obtaining a review of systems, she denies any fever, chills, weight changes, cough, congestion, shortness of breath, gastrointesti-

Author Affiliations: Vanderbilt University, Nashville, Tennessee; Middle Tennessee School of Anesthesia, Madison, Tennessee; Vanderbilt University Medical Center, Nashville, Tennessee; and TeamHealth, Columbia, Tennessee.

Disclosure: The author reports no conflicts of interest.

Corresponding Author: Michael D. Gooch, DNP, APRN, ACNP-BC, FNP-BC, ENP-C, Vanderbilt University School of Nursing, 461 21st Ave S, 312 Godchaux Hall, Nashville, TN 37240 (michael.gooch@vanderbilt.edu).

DOI: 10.1097/TME.000000000000336

nal symptoms, joint aches, or headache. She does endorse mild fatigue and a change in smell over the few days. The remainder of the review of systems is negative. Her physical examination is unremarkable except for a morbilliform rash on the abdomen and lower left forearm. There is no tenderness or lymphadenopathy associated with the rash. There are mild areas of excoriation around some of the rash consistent with scratching, which the patient reports due to the pruritus. As the emergency nurse practitioner, what is your diagnosis and treatment?

INTRODUCTION

The differentials for a rash are numerous. In addition to environmental exposures and medications, many viral infections are known to cause a viral exanthem. In the presence of fatigue and dysosmia, CoVID-19 should now be at the top of the list. CoVID-19 is the clinical disease associated with infection with the severe acute respiratory syndrome coronavirus 2 (SARS-CoV-2). In March 2020, the World Health Organization declared CoVID-19 a pandemic. The clinical course of CoVID-19 can vary greatly and may range from asymptomatic to typical viral signs and symptoms: fever, fatigue, malaise, congestion, and cough, to pneumonia, and even the development of a severe respiratory distress syndrome (Gisoni et al., 2020; Zhao et al., 2020). Since the start of the pandemic, several nonrespiratory complaints have been noted, which include anosmia or dysosmia and dysgeusia, diarrhea, along with some dermatological findings as well (AlSamman, Caggiula, Ganguli, Misak, & Pourmand 2020; Gisoni et al., 2020; Zhao et al., 2020).

PATHOPHYSIOLOGY

Severe acute respiratory syndrome coronavirus 2 enters the body when respiratory droplets come in contact with mucosal surfaces. This contact may be through inhalation or contaminated hands (Daneshgaran, Dubin, & Gould, 2020; Gisoni et al., 2020). Although other routes of transmission have

been proposed, none have yet been proven (AlSamman et al., 2020). Severe acute respiratory syndrome coronavirus 2 is an RNA virus that enters cells via the angiotensin converting enzyme 2 (ACE2) receptor (Bourgonje et al., 2020; Sachdeva et al., 2020; Zhao et al., 2020). Using a protein spike, the virus binds to ACE2 receptors and enters cells. This receptor is located throughout the body: lungs, kidneys, vascular endothelial cells, smooth muscle cells, and the basal epidermal layer of the skin and oral and nasal mucosal membranes, but the ones in the lungs are affected most by this virus (AlSamman et al., 2020; Bourgonje et al., 2020; Sachdeva et al., 2020; Zhao et al., 2020). The ACE2 receptor is also found in abdominal adipose tissue. Obesity is known to promote inflammation and SARS-CoV-2 may accelerate this inflammatory process (Bourgonje et al., 2020). This may be why obese patients with CoVID-19 often experience a more severe disease course and have a higher risk of mortality (Bourgonje et al., 2020).

The ACE2 receptor plays a significant role with homeostasis, including sodium and water balance, which influences blood pressure and electrolyte balance. In the lungs, ACE2 regulates angiotensin II and bradykinin breakdown. The ACE2 receptor has an integral role in the conversion of angiotensin II to angiotensin, which promotes vasodilation, and has antifibrotic and anti-inflammatory effects (Bourgonje et al., 2020). In the gastrointestinal tract, ACE2 is involved with amino acid activity, innate immunity, and gut microbe stability (Bourgonje et al., 2020). The presence of SARS-CoV-2 activates the immune response but also leads to downregulation of the ACE2 receptor. This downregulation is associated with increased levels of angiotensin II, which can lead to tissue damage and increases the risk of thrombosis formation and inflammation (Bourgonje et al., 2020; Gottlieb & Long, 2020).

CUTANEOUS MANIFESTATIONS

During the early phases of the pandemic, respiratory complaints were the most common.

However, more recently, several nonrespiratory manifestations have been reported including rashes and skin changes (AlSamman et al., 2020; Gottlieb & Long, 2020; Sachdeva et al., 2020). The exact reason for these skin manifestations is not fully understood. The reported skin changes may be reactive, inflammatory, or a direct result of the viral insult (Bourgonje et al., 2020; Gottlieb & Long, 2020; Sachdeva et al., 2020). It has been theorized that these skin findings may also be associated with vasculitis and microthrombi formation from a hypercoagulable state, which is sometimes seen with CoVID-19 (AlSamman et al., 2020; Gottlieb & Long, 2020; Sachdeva et al., 2020). It has been postulated that keratinocytes may also be a receptor target of the virus and/or inflammatory mediators (Sachdeva et al., 2020). Several case and literature reviews have evaluated and found variable timing regarding the onset of these dermatologic manifestations. Some patients' initial presentation and diagnosis were due to the rash and others developed a rash or skin color change after the diagnosis of CoVID-19 (Gottlieb & Long, 2020; Sachdeva et al., 2020). One question that has been asked: Is there a correlation between the dermatologic changes and the severity of the infection? This is also not clear (Sachdeva et al., 2020; Seirafianpour et al., 2020; Zhao et al., 2020). Another important question that has yet to be proven or answered is: Can CoVID-19 be spread by the skin (Zhao et al., 2020)? Patients with underlying skin conditions including eczema, rosacea, and atopic dermatitis have been reported to experience flares with CoVID-19 (Daneshgaran et al., 2020). The exact cause of these exacerbations is not clear.

Several skin manifestations have been reported to include urticarial and erythematous rashes, varicella-like vesicles, and discoloration of the digits, similar to chilblains (Bourgonje et al., 2020; Ladha, Luca, Constantinescu, Naert, & Ramien, 2020; Sachdeva et al., 2020). Initial reports from China showed a very low incidence (less than 0.5%) of dermatologic changes in

CoVID-19 patients, but from Italy, it was as high as 20% (AlSamman et al., 2020; Gottlieb & Long, 2020; Sachdeva et al., 2020). These skin manifestations may be painful and/or pruritic and generalized or may be isolated to one area with the trunk and then the extremities being the most common locations (Gottlieb & Long, 2020; Sachdeva et al., 2020). One item that confounds the understanding of these skin changes is that several of the medications, that is, hydroxychloroquine and antivirals, being used to manage CoVID-19 are associated with rashes or skin eruptions (AlSamman et al., 2020; Sachdeva et al., 2020; Seirafianpour et al., 2020). Of note, some of the published case studies and reviews include patients with skin changes who were not receiving any active treatment.

According to Sachdeva et al. (2020) and Seirafianpour et al. (2020), the most common rash reported was a maculopapular rash (see Figure 1), sometimes referred to as a mor-

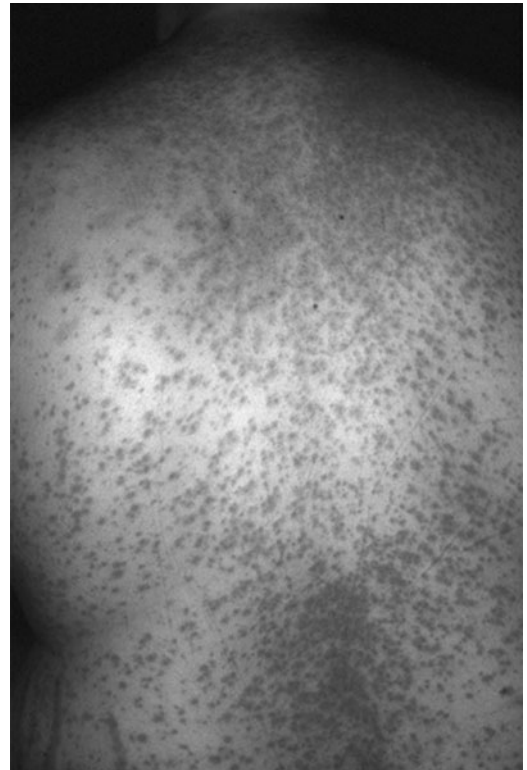

Figure 1. Maculopapular rash.

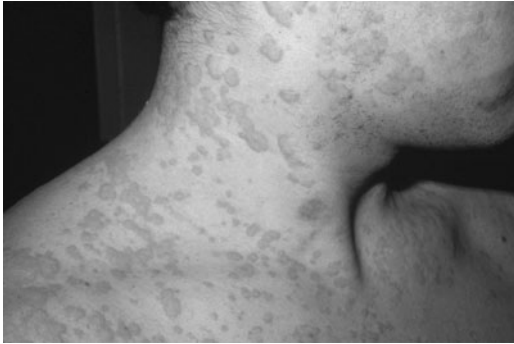


Figure 2. Urticarial rash.

billiform rash. This rash may be classic in presentation, as seen with measles, or may be in large plaque formations (Gottlieb & Long, 2020). Urticarial rashes (see Figure 2) were also commonly reported with most being located on the trunk with associated pruritus (Gottlieb & Long, 2020). Vesicular rashes (see Figure 3) have also been reported, some cases had a similar appearance and distribution such as varicella, and others were more monomorphic and had hemorrhagic characteristics (Gottlieb & Long, 2020).

Another dermatologic finding that has been reported is skin color changes to the distal extremities, similar to chilblains (see Figures 4 and 5; Gottlieb & Long, 2020; Ladha et al., 2020). Chilblains, sometimes called *pernio* or *kibes*, are usually caused by cold exposure and result from vasoconstriction (Gottlieb & Long, 2020; Ladha et al., 2020). Other reviews report that acral lesions, or

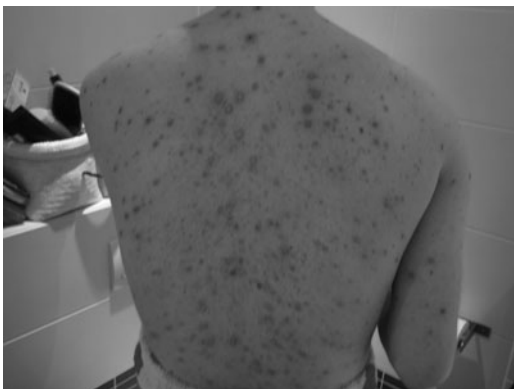

Figure 3. Vesicular rash.

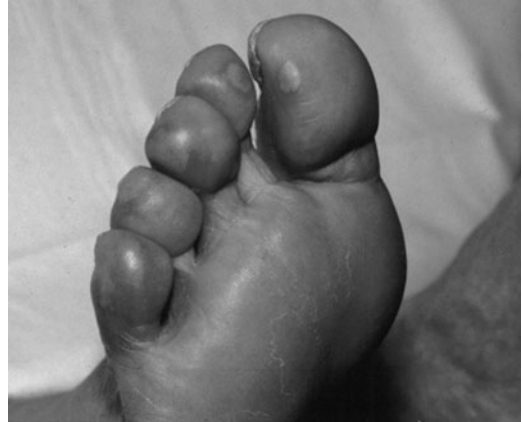

Figure 4. Chilblains.

chilblain-like lesions, were the most common dermatologic manifestations encountered in CoVID-19 patients (Daneshgaran et al., 2020; Gisondi et al., 2020). These findings have been coined by some as “CoVID toes” and may be encountered in patients with no other symptoms and are usually late presentations in mild cases of CoVID-19 (Ladha et al., 2020; Seirafianpour et al., 2020). Based on several reports, CoVID-19 chilblains are usually asymmetrical, are more common in younger patients, and mainly affect the feet (Daneshgaran et al., 2020; Gisondi et al., 2020; Ladha et al., 2020). Unlike typical chilblains, it is thought that CoVID-19 chilblains are less likely the result of ischemia or thrombosis (Ladha et al., 2020; Seirafianpour et al., 2020). Furthermore, it

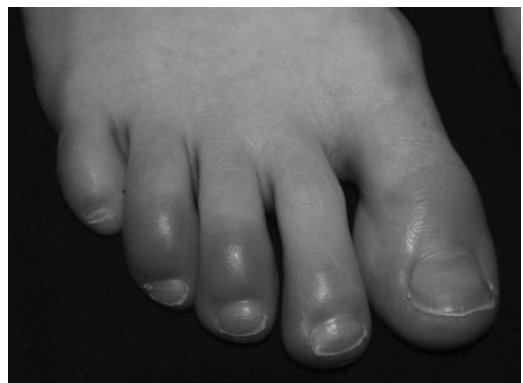

Figure 5. Chilblains.

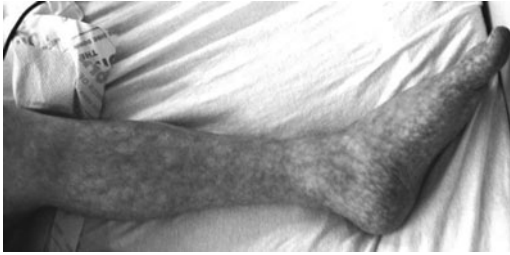

Figure 6. Livedo reticularis.

has been proposed that these chilblains may result from a delayed immune response (Gisoni et al., 2020; Seirafianpour et al., 2020).

Finally, mottling of the extremities, similar to livedo reticularis (see Figure 6), has been reported but is less common. These presentations are more likely associated with coagulopathies, occur in older patients, and are associated with a more serious disease state (Daneshgaran et al., 2020; Gisoni et al., 2020; Seirafianpour et al., 2020). It has been hypothesized that this mottling may occur because of the pooling of venous blood (Sachdeva et al., 2020). Some case studies have included patients who presented with a petechial-type rash (see Figure 7) and some have even been misdiagnosed as dengue fever (Gisoni et al., 2020; Seirafianpour et al., 2020).

MANAGEMENT

Even with a positive SARS-CoV-2 test, other differentials should be considered for dermatological findings. These may include autoimmune conditions such as lupus, vasculitis, environmental exposures, other viral pathogens, for example, herpes simplex and herpes zoster, medications, and malignancy to name a few (Ladha et al., 2020; Seirafianpour et al., 2020). Treatment for these dermatological changes associated with CoVID-19 is usually supportive. Topical steroids may be used to provide anti-inflammatory benefits, though this is not proven in CoVID-19 patients (Ladha et al., 2020). Pruritus may be treated with anti-

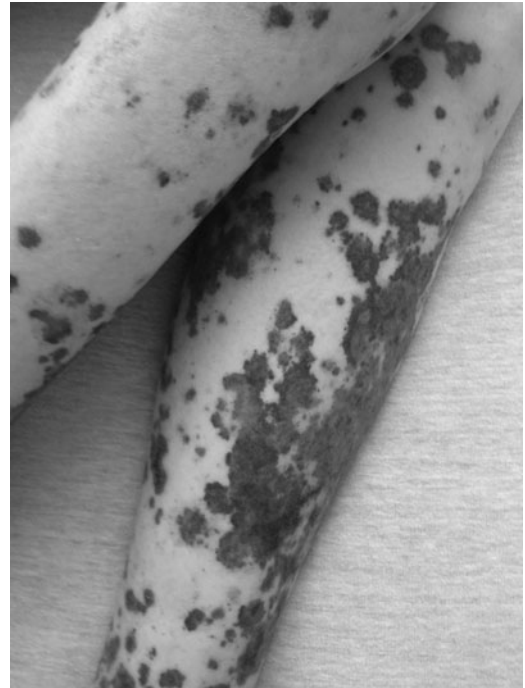

Figure 7. Petechial rash.

histamines (Seirafianpour et al., 2020). If there are concerns for thrombosis and ischemia, topical or systemic vasodilators and antiplatelets or anticoagulants may be indicated (Ladha et al., 2020). Patients with CoVID-19 chilblains may benefit from low-dose aspirin therapy to reduce the risk of thrombosis formation and ischemia (Ladha et al., 2020). Finally, it has been recommended that symptomatic patients with CoVID-19 on immunosuppressants hold their therapy for 2–4 weeks to reduce complications (Seirafianpour et al., 2020).

CASE CONCLUSION

Because of the reported dysosmia, the patient was tested for and was diagnosed with CoVID-19. She was educated on social distancing and quarantine recommendations. She was instructed to continue the oral antihistamines as need for the itching and informed that she could try over-the-counter topical corticosteroids if she wanted. She was given strict return instructions for any respiratory problems and discharged home. The

patient did not return to this emergency department or one in this hospital system.

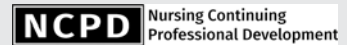
CONCLUSION

The CoVID-19 pandemic has challenged our health care system in many ways. Emergency nurse practitioners are on the frontline with other clinicians. It is important to recall that patients may present without any or only nonrespiratory signs and symptoms of CoVID-19. In addition to the common viral presentation, dermatological changes are becoming more common with CoVID-19. As emergency nurse practitioners, we must consider differentials with any patient's complaint. Even in patients without common viral complaints, we should consider CoVID-19 a differential when patients present with rashes or skin changes. Early recognition of dermatologic changes associated with CoVID-19 would empower emergency nurse practitioners to continue to play an integral role in preventing otherwise asymptomatic patients from exposing others to the virus.

REFERENCES

- AlSamman, M., Caggiula, A., Ganguli, S., Misak, M., & Pourmand, A. (2020). Non-respiratory presentations of COVID-19, a clinical review. *American Journal of Emergency Medicine*, 38(11), 2444-2454. doi:10.1016/j.ajem.2020.09.054
- Bourgonje, A. R., Abdulle, A. E., Timens, W., Hillebrands, J., Navis, G. J., Gordijn, S. J., ... van Goor, H. (2020). Angiotensin-converting enzyme 2 (ACE2), SARS-CoV-2 and the pathophysiology of coronavirus disease 2019 (COVID-19). *The Journal of Pathology*, 251(3), 228-248. doi:10.1002/path.5471
- Daneshgaran, G., Dubin, D. P., & Gould, D. J. (2020). Cutaneous manifestations of COVID-19: An evidence-based review. *American Journal of Dermatology*, 21(5), 627-639. doi:10.1007/s40257-020-00558-4
- Gisondi, P., Plasericco, S., Bordin, C., Alaibac, M., Girolomoni, G., & Naldi, L. (2020). Cutaneous manifestation of SARS-CoV-2 infection: A clinical update. *Journal of the European Academy of Dermatology and Venereology*, 34(11), 2499-2504. doi:10.1111/jdv.16774
- Gottlieb, M., & Long, B. (2020). Dermatologic manifestations and complications of COVID-19. *American Journal of Emergency Medicine*, 38(9), 1715-1721. doi:10.1016/j.ajem.2020.06.011
- Ladha, M. A., Luca, N., Constantinescu, C., Naert, K., & Ramien, M. L. (2020). Approach to chilblains during the COVID-19 pandemic. *Journal of Cutaneous Medicine and Surgery*, 24(5), 504-517. doi:10.1177/1203475420937978
- Sachdeva, M., Gianotti, R., Shah, M., Bradanini, L., Tosi, D., Veraldi, S., ... Dodiuk-Gad, R. P. (2020). Cutaneous manifestations of COVID-19: Report of three cases and a review of literature. *Journal of Dermatologic Science*, 98(2), 75-81. doi:10.1016/j.jdermsci.2020.04.011
- Seirafianpour, F., Sodagar, S., Mohammad, A. P., Panahi, P., Mozafarpour, S., Almasi, S., & Goodarzi, A. (2020). Cutaneous manifestations and considerations in COVID-19 pandemic: A systematic review. *Dermatologic Therapy*, e13986. doi:10.1111/dth.13986
- Zhao, Q., Fang, X., Pang, Z., Zhang, B., Liu, H., & Zhang, F. (2020). COVID-19 and cutaneous manifestations: A systematic review. *Journal of the European Academy of Dermatology and Venereology*, 34(11), 2505-2510. doi:10.1111/jdv.16778

For more than 101 additional continuing professional development articles related to Emergency Care topics, go to [NursingCenter.com/ce](https://www.nursingcenter.com/ce).

**TEST INSTRUCTIONS**

- Read the article. The test for this nursing continuing professional development (NCPD) activity is to be taken online at www.nursingcenter.com/CE/NP. Tests can no longer be mailed or faxed.
- You'll need to create an account (it's free!) and log in to access My Planner before taking online tests. Your planner will keep track of all your Lippincott Professional Development online NCPD activities for you.
- There's only one correct answer for each question. A passing score for this test is 7 correct answers. If you pass, you can print your certificate of earned contact hours and access the answer key. If you fail, you have the option of taking the test again at no additional cost.
- For questions, contact Lippincott Professional Development: 1-800-787-8985.
- Registration deadline is March 3, 2023.

PROVIDER ACCREDITATION

Lippincott Professional Development will award 2.0 contact hours and 0 pharmacology contact hours for this nursing continuing professional development activity.

Lippincott Professional Development is accredited as a provider of nursing continuing professional development by the American Nurses Credentialing Center's Commission on Accreditation.

This activity is also provider approved by the California Board of Registered Nursing, Provider Number CEP 11749 for 2.0 contact hours. Lippincott Professional Development is also an approved provider of continuing nursing education by the District of Columbia, Georgia, and Florida, CE Broker #50-1223. Your certificate is valid in all states.

Payment: The registration fee for this test is \$21.95.