



# Heidenhain Variant of Sporadic Creutzfeldt-Jakob Disease: First Reported Case from East Africa

This article was published in the following Dove Press journal:  
*International Medical Case Reports Journal*

Dilraj Sokhi<sup>1</sup>  
Fazal Yakub<sup>1</sup>  
Karishma Sharma<sup>1</sup>  
Sheila Waa<sup>2</sup>  
Peter Mativo<sup>1</sup>

<sup>1</sup>Department of Medicine, Aga Khan University Hospital, Aga Khan University Medical College of East Africa, Nairobi, Kenya; <sup>2</sup>Department of Radiology, Aga Khan University Hospital, Aga Khan University Medical College of East Africa, Nairobi, Kenya

**Abstract:** Sporadic Creutzfeldt-Jakob disease (sCJD) is a rare prion disease that causes rapidly progressive fatal neurodegeneration. The rarer Heidenhain variant of sCJD presents with visual symptoms and is rarely reported in the literature from sub-Saharan Africa. We report the case of a 57-year-old male with a three-week history of losing direction when driving home and visual hallucinations described as seeing rainbows. Magnetic resonance imaging (MRI) of the brain revealed unilateral parieto-occipital sulcal hyperintensities with restriction on diffusion-weighted imaging (DWI), and electroencephalography (EEG) showed right para-central slowing leading to an initial diagnosis of non-convulsive status epilepticus. He was treated with anti-epileptic medication but was re-admitted less than a month later with worsening spatial memory, aggression, ataxia, dysarthria, myoclonic jerks and a positive startle response, later developing generalised tonic-clonic seizures. Repeat MRI brain scan showed widespread posterior-predominant sulcal DWI restriction in a cortical ribboning pattern pathognomonic for sCJD. EEG showed diffuse slowing, and cerebrospinal fluid was analyzed for abnormal prion protein using real-time quaking-induced conversion but was inconclusive due to suboptimal sample collection. The patient fulfilled the diagnostic criteria for probable sCJD, Heidenhain variant; the family declined brain biopsy for definitive diagnosis. He was subsequently palliated at a local hospice where he died approximately three months after the onset of symptoms. Our case highlights the presence of a rare form of sCJD, and the diagnostic challenges faced in our resource-limited setting.

**Keywords:** Creutzfeldt-Jakob disease, prion, Heidenhain variant, sub-Saharan Africa

## Introduction

Creutzfeldt-Jakob disease is a rare prion disease characterized by transmissible spongiform encephalopathy resulting in rapidly progressive and invariably fatal neurodegeneration. Eighty-five percent of cases occur as sporadic Creutzfeldt-Jakob disease (sCJD).<sup>1</sup> The classical presentation of sCJD is of a rapidly progressive dementia with myoclonus and seizures; other non-cognitive neurological symptoms can also occur early on, e.g. cerebellar ataxia, psychiatric symptoms, stroke-like episodes and extrapyramidal symptoms.<sup>1</sup> Visual disturbances at onset, reflecting early posterior cortical involvement, occur in 4.9% of sCJD cases, termed the Heidenhain variant.<sup>2</sup> Given the myriad of presentations, it is important to exclude mimics and chameleons of sCJD during the diagnostic work-up.<sup>3</sup> The clinical picture, tissue analysis [including cerebrospinal fluid (CSF)], electroencephalography (EEG), and brain magnetic resonance imaging (MRI) are all required for fulfilling the international diagnostic criteria.<sup>4</sup> Definitive diagnosis of sCJD is

Correspondence: Dilraj Sokhi  
Department of Medicine, Aga Khan University Hospital, Aga Khan University Medical College of East Africa, Room 405, 4th Floor East Tower Block, Third Avenue Parklands, P.O. Box 30270, Nairobi, 00100 GPO, Kenya  
Tel +254 710 559 541  
Email Dilraj.Sokhi@aku.edu

made by histopathologic examination through post-mortem autopsy or ante-mortem biopsy.<sup>4</sup>

The annual incidence of sCJD is approximately 1 - per million population, but the epidemiology of sCJD is poorly reported outside Europe, Australia and North America.<sup>5</sup> From the African continent, there are only a few reported cases from North,<sup>6</sup> West,<sup>7</sup> and East<sup>8</sup> Africa, with one iatrogenic case from South Africa.<sup>9</sup> Out of the 18 published cases from Africa, only 2 had MRI brain imaging, of which none showed pathognomonic changes, and none of the patients were reported to present with the Heidenhain variant of sCJD.

## Materials and Methods

We present the first reported case of the Heidenhain variant of sCJD from the East Africa region, who was referred to our regional tertiary neurology referral center in Nairobi.

## Case Presentation

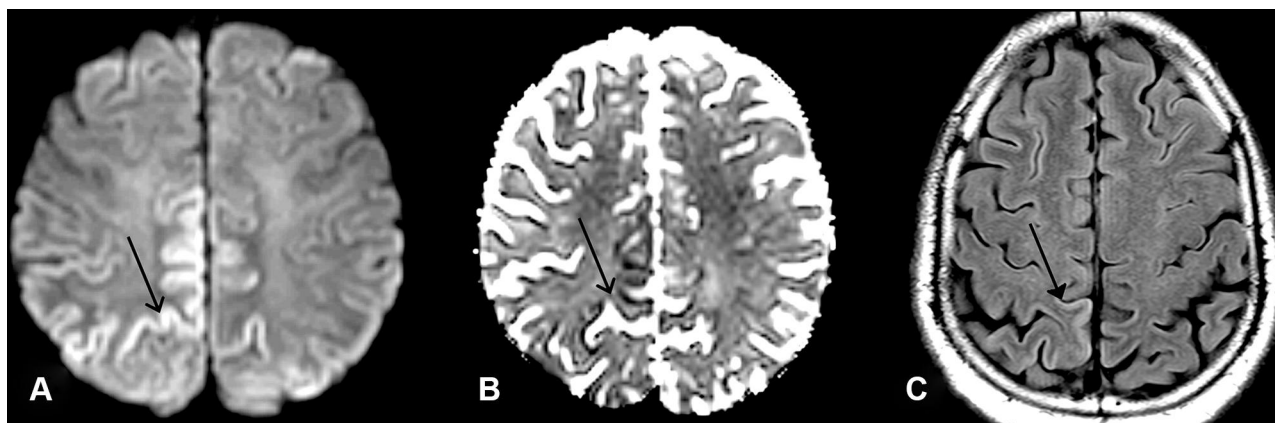
A 57-year-old male was admitted to our facility with a three-week history of visual hallucinations described as seeing rainbows, and losing direction when driving home. The family also reported a recent history of impaired short-term memory. He was known to have stable long-standing type 2 diabetes and hypertension. The patient had no past history of corneal grafting, dura mater transplantation, or pituitary growth hormone treatment, and there was no family history of dementia or rapid cognitive decline.

Full neurological examination revealed a left incongruous homonymous hemianopia, confirmed on formal ophthalmology review. Montreal cognitive assessment score was abnormal at 15/30 (normal >25/30). MRI brain scan (Figure 1) revealed restriction on diffusion weighted imaging (DWI) of

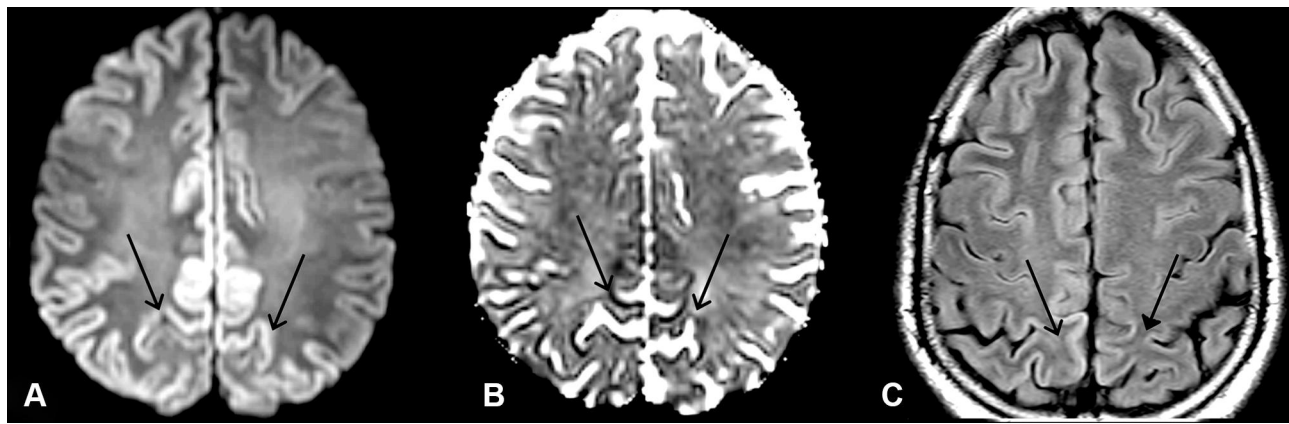
the right precuneus, and bilateral but right-predominant parietal cortices. EEG was suggestive of paracentral slowing with no periodic sharp wave complexes. Laboratory investigations including CSF analysis were all normal. He was diagnosed with non-convulsive status epilepticus and discharged on levetiracetam, and was to be followed up in clinic.

However, the patient was readmitted after four weeks with significantly worsening spatial memory, aggression with persecutory delusions, and reduced mobility. On repeat neurological examination he was confused and speaking in short gibberish phrases, and had now also developed spasticity in all limbs. He could not walk due to apraxia and ataxia, and had myoclonic jerks with a positive startle response, but no signs of hepatic decompensation. Repeat MRI brain scan (Figure 2) now showed symmetrical and more widespread restriction on DWI in bilateral parieto-temporal lobes, giving the “cortical ribboning” appearance pathognomonic of sCJD. We therefore proceeded to investigate the patient for diseases that mimic sCJD,<sup>3</sup> all of which were normal or negative. Table 1 summarizes all the investigations done on the patient during both admissions.

Repeat EEG revealed diffuse slowing again without periodic sharp waves. We treated for reversible causes with high-dose intravenous methylprednisolone over three days and re-loaded with intravenous levetiracetam and phenytoin, but there was no positive change noted in his clinical condition. He continued to deteriorate whilst in hospital and developed generalised tonic-clonic seizures and soon became mute and doubly incontinent. We made the diagnosis of sCJD, likely the Heidenhain variant given the predominant visual presentation, and invited two further independent neurologists to review his case who both agreed with the diagnosis. For confirmation, we



**Figure 1** MRI brain on first admission. (A) (diffusion weighted imaging, DWI) and (B) (apparent diffusion coefficient, ADC): right > left restricted diffusion of parietal lobe (open arrows). (C) (fluid-attenuated inversion recovery, FLAIR): hyper-intense signal in right precuneus and parietal lobe (closed arrow), sparing white matter.



**Figure 2** MRI brain on second admission one month later: (A) (DWI) (B) (ADC) and (C) (FLAIR): Bilateral symmetrical parietal cortical FLAIR hyperintense signals with restricted diffusion (open arrows) more marked in the parafalcine regions (closed arrow).

discussed with the family about brain biopsy who opted against it, but agreed to send CSF overseas for real-time quaking-induced conversion (RT-QuIC) analysis to detect the abnormal prion protein.<sup>10</sup> The results came back negative for the first admission sample, and inconclusive for the second admission sample, attributed to the storage and collection of the samples.

Given the rapid deterioration in the patient's condition, we involved the palliative team soon after establishing a clinical probable diagnosis of sCJD, and managed him with regular levetiracetam for seizures, clonazepam for myoclonus and risperidone for aggression. He was subsequently transferred to a hospice near his home where he died approximately three months after the onset of symptoms.

## Discussion

Our patient's clinical presentation fulfilled the criteria for Heidenhain variant of sCJD given the isolated visual disturbance at the onset of disease, cortical ribboning on MRI and his rapid clinical decline.<sup>2,4,11</sup> Other visual presentations reported in literature include blurred vision, visual field restriction, disturbed color perception, cortical blindness,<sup>11</sup> and even "Alice in Wonderland" syndrome consisting of visual metamorphosias.<sup>12</sup> There are reports of non-specifically altered vision associated with depressive symptoms but being mistaken for a primary psychiatric disease instead of sCJD.<sup>13</sup>

The pathognomonic MRI findings in the Heidenhain variant of sCJD are the DWI cortical ribboning appearances involving the occipital lobes,<sup>14</sup> temporal and parietal lobe involvement without basal ganglia signal change, as seen in our patient's neuro-imaging, have also been

described.<sup>15</sup> The differential diagnoses for these MRI abnormalities are relatively narrow,<sup>16</sup> which we investigated in our diagnostic work-up as per Table 1. The typical EEG findings of periodic sharp waves develop later in disease, so may not be picked up in the Heidenhain variant as it tends to have a sharper decline; if found, the EEG abnormalities tend to be more posterior predominant.<sup>11</sup>

The RT-QuIC test is part of the guidelines for diagnosing sCJD.<sup>4,10</sup> It detects abnormal prion protein and has >95% sensitivity and specificity. In our patient's case, the first admission sample was taken very early on from disease onset, and had been kept in normal storage conditions (refrigerated at 4°C) for more than eight days; the second admission sample had 1500 red cells/mm<sup>3</sup> due to a traumatic spinal tap, which also resulted in raised protein (0.59 g/dL, normal range 0.25–0.45). All these factors are known to lead to false negative RT-QuIC results.<sup>10</sup> We have since introduced a standardized protocol in our hospital on CSF investigations in suspected sCJD, with stipulations on storage at –80°C, analysis within eight days of sample collection, and repeat sampling if the CSF has high protein content and/or high red or white cell counts. We have also mandated analysis of 14-3-3 and tau proteins as a standard panel in addition to RT-QuIC in such cases.

Definitive diagnosis of sCJD requires histopathologic examination through post-mortem autopsy or ante-mortem biopsy.<sup>4</sup> We did not proceed to biopsy due to family wishes as well as a joint decision we made with our neurosurgical team given the risk of contaminating or indefinitely quarantining scarce neurosurgical equipment. Our patient had probable sCJD, and as per the diagnostic criteria we also had to exclude other mimicking secondary causes, investigations for which we followed published

**Table I** Investigations Performed to Exclude Mimics and Chameleons of CJD<sup>3</sup>

Differential Diagnosis for sCJD	Clinical and/or Laboratory Basis for Exclusion of Diagnosis
Auto-immune encephalitides including CNS lupus	<ul style="list-style-type: none"> <li>No recorded fever</li> <li>No pathognomonic movement disorders (dyskinesia in anti-NMDA, facio-brachial dystonic seizures in anti-VGKC)</li> <li>Negative for ANA, ANCA, anti-dsDNA, anti-NMDA, anti-VGKC, anti-GAD antibodies including in CSF</li> </ul>
Primary rapidly progressive neurodegeneration including mitochondrial disease, or delirium in the context of neurodegeneration	<ul style="list-style-type: none"> <li>No antecedent history suggestive of underlying neurodegeneration e.g. frontotemporal dementia</li> <li>MRI brain findings not compatible with dementia diagnosis</li> <li>No intercurrent illness (electrolyte disturbance, infection) found in blood or urine</li> <li>Normal CSF lactate levels</li> </ul>
Neuro-inflammatory conditions including CNS vasculitis and sarcoidosis	<ul style="list-style-type: none"> <li>Normal inflammatory markers including ESR, CRP and complement (C3, C4); normal serum angiotensin converting enzyme levels</li> <li>Normal CSF findings</li> <li>Normal CT chest and abdomen</li> <li>Contrast-enhanced MRI brain with angiography not in keeping with CNS vasculitis or lymphoma</li> <li>No response to intravenous methylprednisolone treatment</li> </ul>
Neurotoxicity syndromes including heavy metal exposure and hypoxic encephalopathy	<ul style="list-style-type: none"> <li>Serum lead, lithium and mercury levels not checked as no compatible occupational or exposure history according to the patient's family</li> <li>Clinical history and examination not in keeping with hypoxic injury</li> </ul>
Neurological malignancy including gliomatosis cerebri, carcinomatous meningitis, CNS lymphoma	<ul style="list-style-type: none"> <li>Normal CSF findings x2</li> <li>Normal CT chest and abdomen</li> <li>Patient's family could not afford PET/CT scan at the time</li> </ul>
CNS infections	<ul style="list-style-type: none"> <li>Negative serology for HIV, syphilis, cytomegalovirus; no fungi seen on CSF staining</li> <li>Lyme's disease is not endemic in Kenya therefore not tested and patient had no history of travel</li> <li>Pure sulcal involvement on MRI, and no evidence of immunosuppression excluded PML therefore JC virus not tested in CSF</li> <li>Measles in CSF not tested as sparing of white matter in MRI brain findings excluded SSPE</li> <li>Whipple's disease was not investigated for, but MRI brain findings were not classical and patient had no gastro-intestinal symptoms</li> </ul>
Metabolic, electrolyte, endocrine, hepatic and hematinic disturbances including subacute combined degeneration and extra-pontine myelinolysis	<ul style="list-style-type: none"> <li>Patient did not have a history of alcohol use.</li> <li>Normal full blood count, urea, electrolytes including sodium and potassium, calcium, magnesium, vitamin B12, folic acid, complete thyroid function including TSH, HbA1c, random blood glucose, liver function tests, hepatitis B, hepatitis C serology</li> <li>No sudden change in electrolytes</li> <li>Serum ammonia levels not available in our laboratory, but normal LFTs and liver imaging excluded hyperammonemia as a cause</li> </ul>
Functional/psychiatric disorders	<ul style="list-style-type: none"> <li>Abnormal MRI brain scan and EEG</li> </ul>

**Abbreviations:** ANA, antinuclear antibody; ANCA, antineutrophil cytoplasmic antibody; CNS, central nervous system; CRP, C-reactive protein; CSF, cerebrospinal fluid; CT, computed tomography; EEG, electroencephalography; ESR, erythrocyte sedimentation rate; HbA1c, glycosylated haemoglobin; GAD, glutamic acid decarboxylase; MRI, magnetic resonance imaging; NMDA, anti-N-methyl-D-aspartate receptor; PET, positron emission tomography; PML, progressive multifocal leukoencephalopathy; sCJD, sporadic Creutzfeldt-Jakob disease; SSPE, subacute sclerosing pan-encephalitis; TSH, thyroid stimulating hormone; VGKC, voltage-gated potassium channel.



recommendations.<sup>3</sup> Important differentials such as infective and auto-immune encephalitis are a part of our standard work-up in such cases,<sup>17</sup> whilst keeping in mind that false positive results can occur in sCJD (for example, encephalitis mediated by antibodies against glutamic acid decarboxylase,<sup>18</sup> which were negative in our patient). We could not perform genetic analysis of the PRNP gene locally due to unavailability of the test, although the lack of a similar condition having occurred in a first-degree relative made familial prion disease less likely.<sup>4</sup> Given the visual-onset presentation and the rapid decline it is likely our patient would have been homozygous for the MM1 subtype at codon 129.<sup>19</sup> We have since instituted PRNP genetic testing through an outsourced laboratory.

The majority of sCJD patients die within one year of onset of symptoms, and the Heidenhain variant confers a more devastating course, with death usually within a few months of symptom onset,<sup>20</sup> as demonstrated in our patient. The treatment of sCJD remains supportive, and we found early referral to palliative care was important for end-of-life management for the patient and his family.

## Conclusion

Our case highlights:

- The challenges associated with the diagnosis of sCJD, especially the Heidenhain variant.
- The need to look for reversible causes in the differential of sCJD.
- sCJD remains a rare condition in sub-Saharan Africa, and although reported worldwide, adds to the few published cases from our region.

## Data Sharing Statement

The clinical history and imaging data used to support the findings of this study are included within the article.

## Research Ethics and Consent

This study was conducted in accordance with the principles stated in the Declaration of Helsinki. The study is exempted from our formal institutional ethics review given it is a case report. Informed consent for the case details to be published was obtained from the registered next of kin and the son of the patient after the patient's demise, and we have documented and timestamped this in the patient's medical case file. The authors have removed all patient identifiable information from the manuscript.

## Acknowledgments

The authors would like to acknowledge the guidance of Professor Simon Mead (Medical Research Council Prion Unit at University College London, UK), and the help of Dr. Alison Green (National Creutzfeldt-Jakob disease Research & Surveillance Unit, University of Edinburgh, UK) in investigating our patient. We also acknowledge the independent opinion of Professor Erastus Amayo (consultant neurologist, University of Nairobi Department of Medicine and Therapeutics) and Dr. Juzar Hooker from our hospital for their clinical input as independent opinions of the case.

## Author Contributions

All authors made a significant contribution to the work reported, whether that is in the conception, study design, execution, acquisition of data, analysis and interpretation, or in all these areas; took part in drafting, revising or critically reviewing the article; gave final approval of the version to be published; have agreed on the journal to which the article has been submitted; and agree to be accountable for all aspects of the work.

## Funding

This case series did not receive any specific funding. The cases have been compiled as part of authors' current employment under the Aga Khan University Medical College of East Africa, Faculty of Health Sciences.

## Disclosure

The authors report no conflicts of interest for this work.

## References

1. Zerr I, Parchi P. Sporadic creutzfeldt-jakob disease. *Handb Clin Neurol.* 2018;153:155–174.
2. Baiardi S, Capellari S, Ladogana A, et al. Revisiting the heidenhain variant of creutzfeldt-jakob disease: evidence for prion type variability influencing clinical course and laboratory findings. *J Alzheimers Dis.* 2015;50(2):465–476. doi:10.3233/JAD-150668
3. Mead S, Rudge P. CJD mimics and chameleons. *Pract Neurol.* 2017;17(2):113–121. doi:10.1136/practneurol-2016-001571
4. CDC's Diagnostic Criteria for Creutzfeldt-Jakob Disease (CJD). *Centers for Disease Control and Prevention.* 2018.
5. Uttley L, Carroll C, Wong R, et al. Creutzfeldt-jakob disease: a systematic review of global incidence, prevalence, infectivity, and incubation. *Lancet Infect Dis.* 2020;20(1):e2–e10. doi:10.1016/S1473-3099(19)30615-2
6. Hajjaj I, Kissani N. First case of presumed sporadic creutzfeldt-jakob disease in Marrakech, Morocco. *Med Trop (Mars).* 2011;71(3):289–291.
7. Aka-Diarre ES-D, Sitting T, Kouame-Aswan B, et al. Application of the electroencephalogram (EEG) in the diagnosis of Creutzfeldt-Jakob Disease (CJD) in Africa. Description of three cases in Côte D'Ivoire. *Afr J Neurol Sci.* 2007;26(2):66–72.

8. Adam AM, Akuku O. Creutzfeldt-jakob disease in Kenya. *Trop Med Int Health*. 2005;10(7):710–712. doi:10.1111/j.1365-3156.2005.01435.x
9. Toovey S, Britz M, Hewlett RH. A case of dura mater graft-associated creutzfeldt-jakob disease in South Africa. *S Afr Med J*. 2006;96(7):592–593.
10. Green AJE. RT-QuIC: a new test for sporadic CJD. *Pract Neurol*. 2019;19(1):49–55. doi:10.1136/practneurol-2018-001935
11. Kropp S, Schulz-Schaeffer WJ, Finkenstaedt M, et al. The heidenhain variant of creutzfeldt-jakob disease. *Arch Neurol*. 1999;56(1):55–61. doi:10.1001/archneur.56.1.55
12. Naarden T, Ter Meulen BC, van der Weele SI, et al. Alice in wonderland syndrome as a presenting manifestation of creutzfeldt-jakob disease. *Front Neurol*. 2019;10:473. doi:10.3389/fneur.2019.00473
13. Restrepo-Martinez M, Chacón-González J, Oñate-Cadena N, et al. Neuropsychiatric symptoms in the heidenhain variant of creutzfeldt-jakob's disease mistaken for major depression and functional neurological disorder. *Aust N Z J Psychiatry*. 2019;53(12):1222–1223. doi:10.1177/0004867419850319
14. Fragoso DC, Gonçalves Filho ALDM, Pacheco FT, et al. Imaging of creutzfeldt-jakob disease: imaging patterns and their differential diagnosis. *Radiographics*. 2017;37(1):234–257. doi:10.1148/rg.2017160075
15. Sakuma T, Watanabe S, Ouchi A, et al. Three cases of creutzfeldt-jakob disease with visual disturbances as initial manifestation. *Case Rep Ophthalmol*. 2019;10(3):349–356. doi:10.1159/000503274
16. Finelli P. Diagnostic approach to restricted-diffusion patterns on MR imaging. *Neurol Clin Pract*. 2012;2(4):287–293. doi:10.1212/CPJ.0b013e318278bee1
17. Sokhi DS, Bhogal OS. autoimmune encephalitis is recognised as an important differential diagnosis in a Kenyan tertiary referral centre. *BMJ Military Health*. 2020;166(5):358. doi:10.1136/jramc-2019-001338
18. Urriola N, Soosapilla K, Herkes G, Nogajski J. Heidenhain variant sporadic creutzfeldt-jakob disease diagnosed as an autoimmune encephalitis due to a false-positive GAD autoantibody. *BMJ Case Rep*. 1999;56(5):5. doi:10.1136/bcr-2018-229018
19. Obergassel J, Lohmann L, Meuth SG, et al. An enigmatic case of cortical anosmia: antemortem diagnosis of a 14-3-3 negative heidenhain-variant MM1-sCJD. *Prion*. 2020;14(1):24–28. doi:10.1080/19336896.2019.1706703
20. Lenk J, Engellandt K, Terai N, et al. Rapid progressive visual decline and visual field defects in two patients with the heidenhain variant of creutzfeldt-jakob disease. *J Clin Neurosci*. 2018;50:135–139. doi:10.1016/j.jocn.2018.01.053

## International Medical Case Reports Journal

Dovepress

### Publish your work in this journal

The International Medical Case Reports Journal is an international, peer-reviewed open-access journal publishing original case reports from all medical specialties. Previously unpublished medical posters are also accepted relating to any area of clinical or preclinical science. Submissions should not normally exceed 2,000 words or 4

published pages including figures, diagrams and references. The manuscript management system is completely online and includes a very quick and fair peer-review system, which is all easy to use. Visit <http://www.dovepress.com/testimonials.php> to read real quotes from published authors.

Submit your manuscript here: <https://www.dovepress.com/international-medical-case-reports-journal-journal>