

# A German Prospective Study of the Safety and Efficacy of a Non-Invasive, High-intensity, Electromagnetic Abdomen and Buttock Contouring Device

by STEFFEN GIESSE, MD

Dr. Giesse is with the Aesthetic Lounge GmbH, Ludwigshafen in Rhein, Germany

*J Clin Aesthet Dermatol.* 2021;14(1):30–33.

## ABSTRACT

**OBJECTIVE:** This study evaluated the efficacy of a novel treatment method utilizing high-intensity focused electromagnetic field (HIFEM) in reducing fat and strengthening the muscles in the abdominal and gluteal areas. **METHODS:** A total of 14 patients, aged 23 to 49 years (mean: 33.2 years) received four treatments on the abdomen and/or buttocks, each lasting for 30 minutes. Ultrasound imaging was performed at baseline, immediately post-treatment, and eight weeks after the last treatment to examine the changes in thickness of the rectus abdominis and subcutaneous fat. Additionally, waist circumference, digital photographs, and patient satisfaction were collected at the same time points. The improvement in digital images was evaluated by practitioners and the patients themselves. **RESULTS:** Two months after the treatments, ultrasound measurements showed, on average, a 15.7-percent reduction of subcutaneous adipose tissue and an average increase in the thickness of the rectus abdominis muscle by 26.1 percent. The abdominal circumference of the treated patients showed an average decrease of 2.84 centimeters. Immediately following the final session, the patient's satisfaction was 87.5 percent; eight weeks later, it was 100 percent. During the patient evaluation of photographs, 25 percent of the patients rated their appearance as improved, 66.7 percent as significantly improved, and 8.3 percent as greatly improved. Using the Global Aesthetic Improvement Scale, the medical practitioners rated the patients as 100-percent improved. No relevant side effects of the treatment were documented. **CONCLUSION:** The data collected on the HIFEM procedure evaluated here are in line with the results from clinical studies and applications of this treatment in the United States. These results support the efficacy and tolerability of the HIFEM procedure. The treatment achieved high doctor and patient satisfaction.

**KEY WORDS:** Emsculpt™, body contouring, electromagnetic field treatment, HIFEM, muscle

An increased focus on physical appearance, partly due to the popularity of social networks like Instagram and Facebook, has, among some, heightened the desire for a flawless-appearing body.<sup>1</sup> Selfies are uploaded to these social media platforms only after undergoing edits using filters and special image processing programs that can change the contours of the body. This trend is also reflected in the increasing number of body shaping procedures in the recent years, which are published annually by the American Society for Aesthetic and Plastic Surgery (ASAPS) or by American Society for Plastic Surgeons (ASPS). According to both societies, in 2018, liposuction was the second-most common aesthetic surgery in the United States (US), with over 250,000 performed interventions.<sup>2,3</sup>

A study on body mass index (BMI) and body image (BI), among 308 Saudi Arabian students found that 81 percent of the respondents reported being dissatisfied with their body image, despite 56 percent of them having a BMI in the normal range and 4 to 5 percent of these participants having a lower-than-average BMI.<sup>4</sup>

Young adults are usually willing to undergo body shaping surgical interventions even though there are some considerable risks, such as infection, scarring, thrombosis, pulmonary embolism, or fat embolism during lipotransfer that leads to death. The task of doctors and the medical device industry should be developing treatment methods that are both safe and effective, so that the trend towards risky surgical procedures can be repressed.

Currently, there are five non-invasive body contouring techniques approved by the US Food and Drug Administration (FDA), including laser, cryolipolysis, radiofrequency, focused ultrasound, and high-intensity focused electromagnetic field (HIFEM) treatments. These five procedures have been demonstrated to be effective and have grown in popularity.<sup>5–31</sup> HIFEM, newest of these five techniques, is the least studied.<sup>32</sup>

The body contour is influenced by three factors: 1) the amount of subcutaneous adipose tissue present; 2) skin laxity; and 3) the muscle mass under the subcutaneous fat tissue. The body contours can thus be improved through targeting these three core structures. Various medical devices are mostly focused on the reduction of subcutaneous fat, while others are focused on skin laxity.<sup>33</sup> Until now, the only way of targeting the underlying muscle tissue was through physical exercise.

Electric and electromagnetic stimulation has long been used for muscle training in physiotherapy. Electromagnetic stimulation, unlike electric stimulation, is characterized by the absence of treatment pain or burns.<sup>34</sup> The Emsculpt™ (BTL Industries Inc.; Boston, Massachusetts) is a new device that utilizes HIFEM to induce tonic muscle contractions. Initial investigations of the device have shown that the application of a HIFEM field on porcine models leads to the apoptosis of adipocytes. The results suggest that HIFEM treatment affects fat metabolism.<sup>25</sup>

Additionally, clinical evidence shows that HIFEM

**FUNDING:** No funding was provided for this study.

**DISCLOSURES:** Dr. Giesse is a speaker for BTL Industries Inc.

**CORRESPONDENCE:** Steffen Giesse, MD; Email: SGiesse@gmx.de

**TABLE 1.** Patient demographics

PATIENT MEASUREMENTS	RANGE	Ø
Age (years)	22–64	33.2
Height (cm)	158–189	171
Weight (kg)	47–112	66.35
Body mass index (kg/m <sup>2</sup> )	17.6–32.8	22.54
Patients (n=14)		

therapy can induce an average reduction in the abdominal circumference of 4.37cm. Other current technologies attribute reductions in abdominal circumference to fat reduction alone, while with the HIFEM procedure, reductions in abdominal circumference appear to be attributed to a combination of fat reduction and reparation of the rectus musculature.<sup>28</sup> Although there is existing literature investigating the HIFEM procedure, data from European practices evidence are lacking. This is the first European study to evaluate the safety and efficacy of the HIFEM procedure.

## METHODS

A total of 14 patients seeking a body contouring procedure were prospectively included in the study. Patients were excluded from the study if they were pregnant or lactating or if they reported having any implanted electronic devices or other metal implants. A total of 14 patients were included. Ten out of the 14 patients received a HIFEM treatment on both the abdomen and buttocks. Three patients received abdominal treatments only, and one patient received buttock treatment only. The treatment was administered with the Emsculpt™ (BTL Industries Inc.; Boston, Massachusetts), a HIFEM device. The treatment procedure comprised four individual sessions, which were completed within two weeks with 3 to 4 days apart. Each treatment lasted for 30 minutes, during which the applicators generate an electromagnetic field penetrating into depths of up to 7cm, which leads to supramaximal muscle contractions. The treatment of the abdomen was administered with a patient lying in a supine position. The treatment of the buttocks was administered in the prone position, with the applicators placed over both sides of the glutes. The target muscles of the buttock treatments are the *M. gluteus maximus*, the *M. gluteus medius*, and the *M. gluteus minimus*. The applicators were fixed by elastic bands to avoid their movement during the intensive muscle contractions. In patients who received both abdominal and

**TABLE 2.** Patient weight and body mass index measurements

PATIENT MEASUREMENTS	BASELINE	EVALUATION (2 FU)	EVALUATION (8 FU)
Weight (kg)	47–112	47–112	48–111
Weight average (kg)	66.35	66.4	65.28
Body mass index (kg/m <sup>2</sup> )	22.54	22.56	22.15
Patients (n=14)			

buttock treatments, the treatment of the buttock immediately followed the treatment of the abdomen on the same day. No analgesia or sedation was necessary during the treatments. The intensity of the treatment was regulated by a touch screen on a control panel and ranged from 0 to 100 percent. At the beginning of the treatment, the practitioner carefully increased the intensity to 100 percent, depending on the patient's feedback. The time to reach 100 percent intensity has been documented.

Patient data was collected before the first treatment, including age, height, weight, and abdominal circumference. In addition, photos of the treated areas were taken. Ultrasound imaging was used to measure the thickness of subcutaneous fat and the thickness of the rectus abdominis muscle. The measurements were done at navel level. No ultrasound examinations were performed on the buttocks. After the treatment, the patients were asked for the pain assessment using a visual analogue scale (VAS).

Photographs of the treated areas, weight, abdominal circumference, and ultrasound measurements were taken again immediately after the fourth treatment and during the two-month follow-up visits. In addition, during the posttreatment visits, the patients were asked to report any adverse events and rate their satisfaction with the treatment outcomes using a satisfaction questionnaire.

The patient photographs were evaluated by three medical practitioners and the patient themselves. The collected ultrasound data was tested for statistical significance using paired t-test.

## RESULTS

All 14 patients involved in the study completed the entire treatment course and were attended all follow-up visits. The average age of the patients was 33.2 years (range: 22–64 years). The average BMI at the beginning of the study was 22.54 (range: 17.6–32.8) (Table 1). After the last treatment, average BMI was 22.56 (range: 17.3–33.4); at the two-month follow-up, it was

22.15 (range: 17.3–33.1) (Table 2).

No unwanted side effects or adverse events were observed throughout the study. None of the patients complained about continual muscle soreness. A mild feeling of pressure in the treated areas was reported by 13 out of the 14 patients but the feeling resolved within 48 hours after treatment in all of the patients without any interventions.

The time to reach the maximum intensity level of 100 percent was significantly reduced from session to session in all patients. During the first session it was, on average, 3.09 minutes, then decreased to 1.50 minutes during the second session, 0.77 minutes during the third session, and 0.68 minutes during the fourth session. All patients reached the maximum intensity level of 100 percent during all sessions. The pain score assessed by the visual analogue scale was 1.7 on average, corresponding to none or mild discomfort but no pain.

The average waist circumference decreased by 1.77cm (range 0–4cm) immediately after the fourth treatment. During the two-month follow-up, the average reduction in waist circumference was 2.84cm (range 0–6cm). No increase in abdominal circumference was documented in any patient. In three patients, the abdominal circumference remained unchanged, although these patients reported being very satisfied with their treatment results. Of note, these three patients had extremely low BMI measurements (19.2, 17.6, and 20.2) and showed an increase in muscle in the treated areas (50%, 25%, and 37.5%).

Initial posttreatment evaluations of ultrasound measurements showed a statistically significant ( $p < 0.05$ ) reduction of subcutaneous adipose tissue by an average of nine percent and a statistically significant ( $p < 0.05$ ) increase in the thickness of the rectus abdominis muscle by an average of 17.2 percent. At the second evaluation, eight weeks posttreatment, the subcutaneous adipose tissue was reduced on an average by 15.7 percent ( $p < 0.05$ ) and the rectus abdominis muscle was increased by 26.1 percent ( $p < 0.05$ ) in

**TABLE 3.** Treatment results

STUDY PARAMETER	EVALUATION (2 FU)	EVALUATION (8 FU)
Body mass index (kg/m <sup>2</sup> )	22.56	22.15
Average reduction of subcutaneous fat	-9.03%	-15.7%
Average increase of muscle	+17.21%	+26.1%
Average reduction in abdominal circumference	-1.77cm	-2.84cm

Patients (n=14)

comparison to baseline (Table 3).

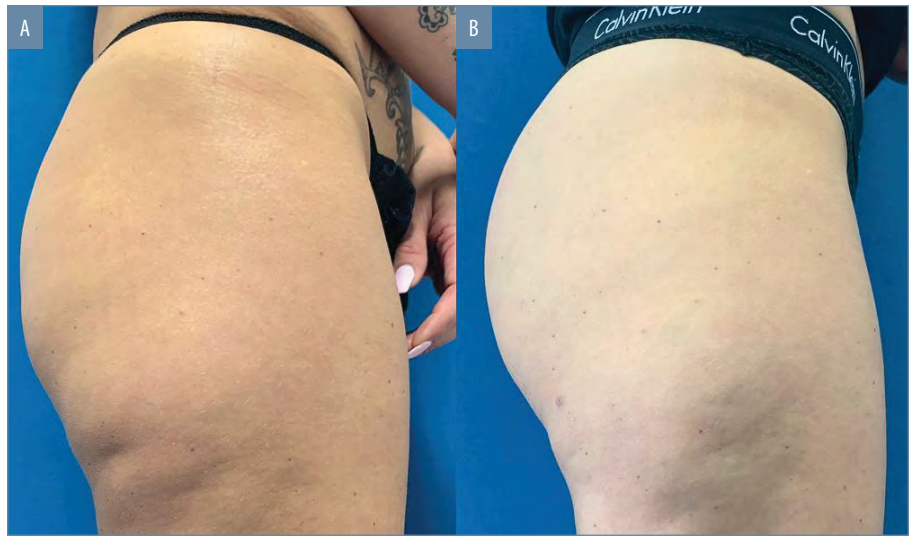
Immediately after the last session, patients' satisfaction with the treatment outcome was 87.5 percent, and, eight weeks later, it was 100 percent. Two patients, out of the total of 14 patients did not report any obvious effects after the last treatment.

The practitioners and the patients themselves evaluated photos taken at baseline and eight weeks after the treatment. The self-evaluation of the photo documentation was done by all 14 patients who assessed the improvement in all treated areas (abdomen 13x, buttocks 11x). Seven of the 24 (29.2%) body areas were described as improved, 14 of the 24 areas (58.3%) as significantly improved, and three of the 24 (12.5%) area as greatly improved. As a final assessment of the treatment, all patients stated that they would recommend the treatment to friends. An example of patient results can be seen in Figure 1.

The first practitioner rated 79 percent of the documented treatment outcomes as significantly improved and 21 percent as greatly improved. The second practitioner described 29 percent of the taken photos as improved, 63 percent as significantly improved, and 8 percent as greatly improved. The third and last practitioner, assessed 50 percent of the outcomes as significantly improved and 50 percent as greatly improved (Tables 4 and 5).

**DISCUSSION**

The primary aim of this study was to investigate the safety and efficacy of the HIFEM procedure, a newer method of noninvasive body contouring. In this study, we evaluated whether the HIFEM procedure could effectively improve the aesthetic appearance of the treated abdominal and gluteal body areas, even in patients with very low BMI. The results showed a very high patient satisfaction



**FIGURE 1.** Digital photographs of buttocks at A) baseline; and B) two months post-treatment; the figure illustrates the patient's results after four treatments using a high-intensity focused electromagnetic field device on the buttock area

**TABLE 4.** Assessment of photo documentation

EVALUATOR	NO CHANGE	IMPROVED	SIGNIFICANTLY IMPROVED	GREATLY IMPROVED
Patient	0%	29.2%	58.3%	12.5%
Doctor	0%	0%	79.2%	20.8%
Practitioner 1	0%	29.2%	62.5%	8.3%
Practitioner 2	0%	0%	50%	50%

**TABLE 5.** Scale of the satisfaction questionnaire

WORSENERD	NO CHANGE	IMPROVED	SIGNIFICANTLY IMPROVED	GREATLY IMPROVED
--	-	+	++	+++

after the last treatment and even after two months without any adverse events or side effects. The loss of abdominal circumference, in almost all patients, with simultaneously nearly unchanged BMI values shows the efficacy of the treatment in all patients.

Ultrasound evaluation showed positive effects on the treated muscles as well as on the adipose tissue. The documented effects were accomplished with very little pain and without any persisting side effects. In particular, it was patients with low BMI (below 25) achieved very good results. These are the patients who are not ideal candidates for other body shaping procedures, such as liposuction.

Other studies on noninvasive fat reduction procedures documented a reduction in abdominal circumference between 4.1 and 6.86cm.<sup>13-25,32</sup> Our documented average reduction of 2.84cm shows lower value. This may be due to the fact that a total BMI of less than 25 was found in 12 of the 14 examined patients. In the patients with lower

BMI, the simultaneous increase of muscle mass and reduction of the subcutaneous adipose tissue resulted in a smaller reduction of the abdominal circumference but with a more significant improvement in the visual appearance.

Several studies on HIFEM similarly evaluated the fat layer and rectus abdominis before and after HIFEM procedure. A study by Kinney et al<sup>26</sup> documented a reduction in fat thickness by 18.6 percent and thickening of the rectus abdominis by 15.4 percent.<sup>26</sup> Katz et al<sup>29</sup> reported fat reduction by 23.3 percent at three months posttreatment. Furthermore, Kent et al<sup>35</sup> found a fat reduction of 19.2 percent and muscle thickening of 15.8 percent. Our study observed a fat reduction of 15.7 percent and muscle increase by 26.1 percent, measured eight weeks posttreatment. The more prominent muscle thickening and lower fat reduction seen in this study could be attributed to the composition of the study group, which was of low BMI. These patients, due to a smaller fat

layer at baseline, may have been more prone to see increases in muscle rather than decreases in fat. Regarding the timing of the outcomes, from our experience, the increase in muscle can be seen earlier than the decrease in fat. Fat reduction is a metabolic reaction, and thus, takes some time to manifest; in contrary, increases in muscle can be seen faster and the feeling of increased muscle tightness can be often felt immediately after the first treatment. On the abdomen, the overall outcome is driven by both muscle thickening and fat reduction, since both of these effects help to flatten the abdomen through reducing fat bulges and correcting the muscle laxity responsible for convex shape of abdomen. In regards to the buttock area, the overall outcome is primarily due to the muscle increase, as the fat layer deposited on the buttocks is known to be less metabolically active than the adipose tissue of abdomen.<sup>36,37</sup>

The HIFEM procedure seems to be a suitable option for patients with lower BMI measurements, although people with a higher BMI, here up to 32.8, were also satisfied with the treatment outcome. Combination therapy with other fat-reducing procedures could also be considered an effective option for these patients.

## CONCLUSION

The results of our study suggest that the HIFEM procedure is a safe and effective option for noninvasive body shaping. Future studies with larger numbers of patients, possibly divided into subgroups according to BMI, should be conducted to further confirm our results.

## REFERENCES

- Salomon I, Brown CS. The Selfie Generation: Examining the Relationship Between Social Media Use and Early Adolescent Body Image. *J Early Adolesc.* 2019;39(4):539–560.
- American Society of Plastic Surgeons. Plastic Surgery Statistics Report. Plastic Surgery. <https://www.plasticsurgery.org/news/plastic-surgery-statistics>. Accessed January 6, 2020.
- The American Society for Aesthetic Plastic Surgery. 2018 Procedural Statistics. The Aesthetic Society. <https://www.surgery.org/sites/default/files/ASAPS-Stats2017.pdf>. Accessed January 6, 2020.
- Radwan H, Hasan HA, Ismat H, et al. Body Mass Index Perception, Body Image Dissatisfaction and Their Relations with Weight-Related Behaviors among University Students. *Int J Environ Res Public Health.* 2019;16(9).
- Caruso-Davis MK, Guillot TS, Podichetty VK, et al. Efficacy of low-level laser therapy for body contouring and spot fat reduction. *Obes Surg.* 2011;21(6):722–729.
- McRae E, Boris J. Independent evaluation of low-level laser therapy at 635 nm for non-invasive body contouring of the waist, hips, and thighs. *Lasers Surg Med.* 2013;45(1):1–7.
- Savoia A, Landi S, Vannini F, et al. Low-level laser therapy and vibration therapy for the treatment of localized adiposity and fibrous cellulite. *Dermatol Ther.* 2013;3(1):41–52.
- Nestor MS, Newburger J, Zarraga MB. Body contouring using 635-nm low level laser therapy. *Semin Cutan Med Surg.* 2013;32(1):35–40.
- Jackson RF, Stern FA, Neira R, et al. Application of low-level laser therapy for noninvasive body contouring. *Lasers Surg Med.* 2012;44(3):211–217.
- Gold M, Khatri K, Hails K, et al. Reduction in thigh circumference and improvement in the appearance of cellulite with dual-wavelength, low-level laser energy and massage. *J Cosmet Laser Ther Off Publ Eur Soc Laser Dermatol.* 2011;13:13–20.
- Jackson RF, Dedo DD, Roche GC, et al. Low-level laser therapy as a non-invasive approach for body contouring: a randomized, controlled study. *Lasers Surg Med.* 2009;41(10):799–809.
- Lach E. Reduction of subcutaneous fat and improvement in cellulite appearance by dual-wavelength, low-level laser energy combined with vacuum and massage. *J Cosmet Laser Ther Off Publ Eur Soc Laser Dermatol.* 2008;10(4):202–209.
- Garibyan L, Sipprell WH, Jalian HR, et al. Three-dimensional volumetric quantification of fat loss following cryolipolysis. *Lasers Surg Med.* 2014;46(2):75–80.
- Sasaki GH, Abelev N, Tevez-Ortiz A. Noninvasive selective cryolipolysis and reperfusion recovery for localized natural fat reduction and contouring. *Aesthet Surg J.* 2014;34(3):420–431.
- Dierickx CC, Mazer J-M, Sand M, et al. Safety, tolerance, and patient satisfaction with noninvasive cryolipolysis. *Dermatol Surg Off Publ Am Soc Dermatol Surg Al.* 2013;39(8):1209–1216.
- Ferraro GA, De Francesco F, Cataldo C, et al. Synergistic effects of cryolipolysis and shock waves for noninvasive body contouring. *Aesthetic Plast Surg.* 2012;36(3):666–679.
- Fritz K, Salavastru C. Long-term follow-up on patients treated for abdominal fat using a selective contactless radiofrequency device. *J Cosmet Dermatol.* 2017;16(4):471–475.
- Chilukuri S, Denjean D, Fouque L. Treating multiple body parts for skin laxity and fat deposits using a novel focused radiofrequency device with an ultrasound component: Safety and efficacy study. *J Cosmet Dermatol.* 2017;16(4):476–479.
- Adatto MA, Adatto-Neilson RM, Morren G. Reduction in adipose tissue volume using a new high-power radiofrequency technology combined with infrared light and mechanical manipulation for body contouring. *Lasers Med Sci.* 2014;29(5):1627–1631.
- Casabona G, Pereira G. Microfocused Ultrasound with Visualization and Calcium Hydroxylapatite for Improving Skin Laxity and Cellulite Appearance. *Plast Reconstr Surg Glob Open.* 2017;5(7):e1388.
- Goldberg DJ, Hornfeldt CS. Safety and efficacy of microfocused ultrasound to lift, tighten, and smooth the buttocks. *Dermatol Surg Off Publ Am Soc Dermatol Surg Al.* 2014;40(10):1113–1117.
- Ko EJ, Hong JY, Kwon T-R, et al. Efficacy and safety of non-invasive body tightening with high-intensity focused ultrasound (HIFU). *Skin Res Technol Off J Int Soc Bioeng Skin ISBS Int Soc Digit Imaging Skin ISDIS Int Soc Skin Imaging ISSI.* 2017;23(4):558–562.
- Ferrando G. Safety, tolerability, and efficacy evaluation of the SlimME device for circumference reduction. *Lasers Surg Med.* 2018;50(7):745–754.
- Shek SYN, Yeung CK, Chan JCY, et al. Efficacy of high-intensity focused ultrasonography for noninvasive body sculpting in Chinese patients. *Lasers Surg Med.* 2014;46(4):263–269.
- Weiss RA, Bernardy J. Induction of fat apoptosis by a non-thermal device: Mechanism of action of non-invasive high-intensity electromagnetic technology in a porcine model. *Lasers Surg Med.* 2019;51(1):47–53.
- Kinney BM, Lozanova P. High intensity focused electromagnetic therapy evaluated by magnetic resonance imaging: Safety and efficacy study of a dual tissue effect based non-invasive abdominal body shaping. *Lasers Surg Med.* 2019;51(1):40–46.
- Jacob C, Kinney B, Busso M, et al. High Intensity Focused Electro-Magnetic Technology (HIFEM) for Non-Invasive Buttock Lifting and Toning of Gluteal Muscles: A Multi-Center Efficacy and Safety Study. *J Drugs Dermatol JDD.* 2018;17(11):1229–1232.
- Jacob CI, Paskova K. Safety and efficacy of a novel high-intensity focused electromagnetic technology device for noninvasive abdominal body shaping. *J Cosmet Dermatol.* 2018;17(5):783–787.
- Katz B, Bard R, Goldfarb R, et al. Ultrasound Assessment of Subcutaneous Abdominal Fat Thickness After Treatments With a High-Intensity Focused Electromagnetic Field Device: A Multicenter Study. *Dermatol Surg Off Publ Am Soc Dermatol Surg Al.* 2019;45(12):1542–1548.
- Busso M, Denkova R. High-Intensity Focused Electromagnetic (HIFEM) Field Therapy Used for Non-Invasive Buttock Augmentation and Lifting: Feasibility Study. 2019:5.
- Array. Array. <https://www.surgery.org/media/statistics>. Published August 13, 2019. Accessed October 3, 2019.
- Mazzoni D, Lin MJ, Dubin DP, et al. Review of non-invasive body contouring devices for fat reduction, skin tightening and muscle definition. *Australas J Dermatol.* 2019;60(4):278–283.
- Alizadeh Z, Halabchi F, Mazaheri R, et al. Review of the Mechanisms and Effects of Noninvasive Body Contouring Devices on Cellulite and Subcutaneous Fat. *Int J Endocrinol Metab.* 2016;14(4).
- Nussbaum EL, Houghton P, Anthony J, et al. Neuromuscular Electrical Stimulation for Treatment of Muscle Impairment: Critical Review and Recommendations for Clinical Practice. *Physiother Can.* 2017;69(5):1–76.
- Kent DE, Jacob CI. Computed tomography (CT) based evidence of simultaneous changes in human adipose and muscle tissues following a high intensity focused electro-magnetic (hifem) application: a new method for non-invasive body sculpting. In: Dallas TX, USA; 2018.
- Björndal B, Burri L, Staalesen V, et al. Different adipose depots: their role in the development of metabolic syndrome and mitochondrial response to hypolipidemic agents. *J Obes.* 2011;2011:490650.
- Horowitz JF. Fatty acid mobilization from adipose tissue during exercise. *Trends Endocrinol Metab TEM.* 2003;14(8):386–392. **JCAD**