

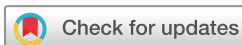Chronic inflammatory demyelinating polyradiculoneuropathy presenting as predominantly sciatic monomelic neuropathy

Shadi El-Wahsh,^{1,2} Cecilia Cappelen-Smith,^{2,3} Judith Spies^{1,4}

To cite: El-Wahsh S, Cappelen-Smith C, Spies J. Chronic inflammatory demyelinating polyradiculoneuropathy presenting as predominantly sciatic monomelic neuropathy. *BMJ Neurology Open* 2020;2:e000045. doi:10.1136/bmjno-2020-000045

► Additional material is published online only. To view please visit the journal online (<http://dx.doi.org/10.1136/bmjno-2020-000045>).

Accepted 16 March 2020



© Author(s) (or their employer(s)) 2020. Re-use permitted under CC BY-NC. No commercial re-use. See rights and permissions. Published by BMJ.

¹Department of Neurology, Royal Prince Alfred Hospital, Camperdown, New South Wales, Australia

²South Western Sydney Clinical School, University of New South Wales, Sydney, New South Wales, Australia

³Department of Neurology, Liverpool Hospital, Liverpool, New South Wales, Australia

⁴Brain and Mind Centre, University of Sydney, Sydney, New South Wales, Australia

Correspondence to

Dr Cecilia Cappelen-Smith; cecilia.cappelen-smith@health.nsw.gov.au

ABSTRACT

Background Chronic inflammatory demyelinating polyneuropathy (CIDP) is a common yet underdiagnosed cause of potentially treatable chronic sensorimotor neuropathy. The classical form of the disease is characterised by symmetrical weakness in both distal and proximal muscle groups accompanied by sensory dysfunction and diminished tendon reflexes lasting more than 2 months.

Method The diagnosis of CIDP is supplemented by electrodiagnostic studies and biopsy findings confirming demyelination, in accordance with well-established diagnostic criteria. Atypical presentations of CIDP often pose a diagnostic challenge.

Results In this paper, we present a case of isolated lower limb involvement due to CIDP to raise awareness of this focal lower limb variant. Of particular significance is the use of lumbosacral plexus MRI to assist in the diagnosis.

Conclusion Focal CIDP is an atypical presentation that should be considered in patients presenting with chronic monomelic neuropathy and should be investigated with electrodiagnostic studies, lumbar puncture, nerve biopsy and MRI of the nerve roots and plexuses.

CASE REPORT

A 29-year-old healthy woman presented with a 9-month history of progressive right lower limb weakness and dysesthesia. Initial presentation was marked by fatigue on walking long distances, followed by persistent paraesthesia in the right leg. She subsequently developed right knee weakness associated with loss of balance and falls. Finally, she developed a right foot drop over a period of 48 hours, resulting in hospital admission. Examination at the time revealed normal cranial nerve, upper limb and left lower limb neurological examinations. Right lower limb tone was normal and motor examination revealed MRC grade 5/5 hip flexion, 4/5 hip extension, 4-/5 knee flexion, 4+/5 knee extension, 4/5 ankle inversion/eversion, 3/5 ankle dorsiflexion and 4-/5 plantar flexion. Right knee and ankle jerks were absent with a down-going plantar response. Sensation to

light touch, pain and temperature was diminished below the right mid-shin. She required crutches to mobilise.

Routine blood tests, autoimmune/vascular screen, antiganglioside antibodies and myeloma and lymphoma panels were negative. Antineurofascin-155 and anti-contactin 1 antibody testing was not performed. Cerebrospinal fluid results were normal (protein 0.22 g/L (0.15–0.45), glucose 3.1 mmol/L (2.5–4.5), leucocytes $0 \times 10^9/L$). Nerve conduction studies (see online supplementary table 1) revealed 40% reduction in right tibial motor nerve amplitude compared with the left with reduced right sural nerve response. Right tibial motor conduction velocity was reduced and right tibial and peroneal F wave latencies were prolonged. Electromyography revealed positive sharp waves and fibrillations, and a single unit firing in isolation in the right medial gastrocnemius. Other sampled muscles showed mild chronic neurogenic changes. Electrodiagnostic findings were thus consistent with a partial right sciatic nerve lesion. MRI of the brain and full spine showed no significant abnormalities. MRI lumbosacral plexus and lower limbs showed swelling and T2 hyperintensity of the right L5 and S1 nerves in the pelvis, right sciatic nerve throughout the thigh, and right tibial and common peroneal nerves in the upper calf with sparing of the right sural nerve ([figure 1](#)). While the inflammatory process was restricted to more proximal parts of the sciatic nerve on MRI, the risk of sciatic nerve biopsy was considered unacceptable. Consequently, a right sural nerve biopsy was performed which showed a moderate reduction in myelinated fibre density, subperineural oedema, minor subperineural and epineurial perivascular inflammation, and scattered actively degenerating fibres. No features of ischaemic nerve injury or microvasculitis

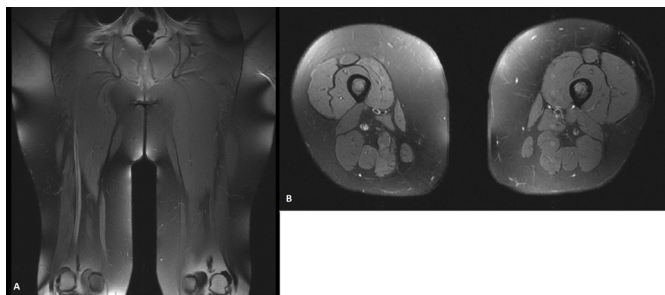


Figure 1 (A) Coronal and (B) axial T2-weighted MRI of the lower limbs showing hypertrophy and increased signal intensity in the right sciatic nerve throughout the thigh.

were seen. Congo red staining for amyloid was negative. Direct immunofluorescence staining for immunoglobulin and complement was negative. Electron microscopy was not performed.

On the basis of electrodiagnostic and imaging findings and supportive sural nerve biopsy results, the patient was diagnosed with atypical focal variant chronic inflammatory demyelinating polyneuropathy (CIDP) involving the right sciatic nerve. She was treated with pulse intravenous methylprednisolone (1g/day) for 3 days, followed by induction intravenous immunoglobulin therapy for 5 days (0.4g/kg/day). Maintenance 4-weekly intravenous immunoglobulin therapy was given. Gabapentin and amitriptyline were commenced for neuropathic pain.

At 12-month follow-up, she had improvement in right lower limb strength and was mobilising independently. As her symptoms had improved, she self-ceased the intravenous immunoglobulin therapy for 6 months and subsequently deteriorated clinically. A further intravenous immunoglobulin induction course was given and 4-weekly maintenance intravenous immunoglobulin was reinstated. At 36 months, pain and strength had improved. Motor examination in the right lower limb revealed 5/5 hip flexion, 4+/5 hip extension, knee flexion and knee extension, and 4/5 ankle movements. The right knee reflex was present, having been previously absent, but the right ankle jerk remained absent. Sensory examination revealed reduced pain sensation below the right knee. Progress MRI of the right thigh showed very mild persistent right sciatic nerve enlargement extending from the lesser trochanter to the distal femur, with T2 high signal but no contrast enhancement. At 72 months, power in the right lower limb had fully recovered, with persistent reduced pain sensation below the knee. She was independently ambulant on maintenance intravenous immunoglobulin. In the first few years following diagnosis, attempts to reduce intravenous immunoglobulin infusion frequency resulted in recurrence of fatigue, right leg weakness and electric shock-like pains. Progress nerve conduction studies showed increased right tibial nerve motor amplitudes, although right to left-sided variation persisted (see online supplementary table 1 for serial electrodiagnostic test results). At 96 months, the patient was living a fully independent life and was exercising on a

daily basis. Notably, she has remained well off intravenous immunoglobulin for more than 12 months as of the time of writing.

DISCUSSION

Focal CIDP is a rare yet well-established disease entity, with motor, sensory and mixed monomelic presentations described in the literature.¹⁻³ The existence of a multitude of diagnostic criteria for CIDP speaks to the diagnostic complexity and clinical heterogeneity of the condition.⁴ One of the most widely used criteria is the European Federation of Neurological Societies/Peripheral Nerve Society (EFNS/PNS) guidelines,⁵ which allows for diagnosis of typical and atypical CIDP variants with high sensitivity and specificity.⁶ Part of the difficulty in diagnosing atypical CIDP lies in the exclusion of mimic disorders, including multifocal motor neuropathy, paraproteinaemic demyelinating neuropathy and polyneuropathy, organomegaly, endocrinopathy, monoclonal proteins, skin changes syndrome.⁷⁻⁹

Using the EFNS/PNS guidelines, our patient met criteria for definite atypical focal CIDP. Clinically, she presented with focal symptoms and signs isolated to the right lumbosacral plexus. Electrodiagnostically, she fulfilled criteria for possible CIDP with prolongation of F-wave latency $\geq 30\%$ the upper limit of normal in at least one nerve. Supportive diagnostic criteria included abnormal sensory electrophysiology, nerve hypertrophy on MRI lumbosacral plexus/sciatic nerve and objective clinical improvement following immunomodulatory treatment. The occurrence of clinical and electrophysiological deterioration during attempts at weaning intravenous immunoglobulin earlier in the disease course further supported the diagnosis. The non-specific sural nerve biopsy findings are a common occurrence in CIDP; the lack of microvascular ischaemic changes in this case is important, as it makes the differential diagnosis of non-diabetic lumbosacral radiculoplexus neuropathy less likely.¹⁰ The combination of possible CIDP on electrophysiology with at least two supportive criteria established the diagnosis of definite focal CIDP.⁵

In conclusion, focal CIDP should be considered in patients presenting with chronic monomelic neuropathy. These patients should be investigated with electrodiagnostic studies, lumbar puncture, nerve biopsy and MRI of the nerve roots and plexuses to identify features to support the diagnosis.

Contributors All of the authors contributed to the manuscript and agree with the presented views.

Funding The authors have not declared a specific grant for this research from any funding agency in the public, commercial or not-for-profit sectors.

Competing interests None declared.

Patient consent for publication Obtained.

Provenance and peer review Not commissioned; internally peer reviewed.

Data availability statement All data relevant to the study are included in the article or uploaded as online supplementary information. The electrodiagnostic test results are included in a table in the supplementary materials section (submitted).

Open access This is an open access article distributed in accordance with the Creative Commons Attribution Non Commercial (CC BY-NC 4.0) license, which permits others to distribute, remix, adapt, build upon this work non-commercially, and license their derivative works on different terms, provided the original work is properly cited, appropriate credit is given, any changes made indicated, and the use is non-commercial. See: <http://creativecommons.org/licenses/by-nc/4.0/>.

REFERENCES

- 1 Mathey EK, Park SB, Hughes RAC, *et al*. Chronic inflammatory demyelinating polyradiculoneuropathy: from pathology to phenotype. *J Neurol Neurosurg Psychiatry* 2015;86:973–85.
- 2 Thomas PK, Claus D, Jaspert A, *et al*. Focal upper limb demyelinating neuropathy. *Brain* 1996;119:765–74.
- 3 Ayrignac X, Rodrigues Bienvenu S, Morales R, *et al*. Focal CIDP presenting as chronic progressive monomelic sensory neuropathy. *Muscle Nerve* 2013;47:143–4.
- 4 Köller H, Kieseier BC, Jander S, *et al*. Chronic inflammatory demyelinating polyneuropathy. *N Engl J Med* 2005;352:1343–56.
- 5 VandenBergh P, Hadden R, Bouche P, *et al*. European Federation of Neurological Societies/Peripheral Nerve Society Guideline on management of chronic inflammatory demyelinating polyradiculoneuropathy: report of a joint task force of the European Federation of Neurological Societies and the Peripheral Nerve Society--First Revision. *J Peripher Nerv Syst* 2010;15:356–63.
- 6 Rajabally YA, Nicolas G, Piéret F, *et al*. Validity of diagnostic criteria for chronic inflammatory demyelinating polyneuropathy: a multicentre European study. *J Neurol Neurosurg Psychiatry* 2009;80:1364–8.
- 7 Taylor BV, Wright RA, Harper CM, *et al*. Natural history of 46 patients with multifocal motor neuropathy with conduction block. *Muscle Nerve* 2000;23:900–8.
- 8 Niermeijer JMF, Fischer K, Eurelings M, *et al*. Prognosis of polyneuropathy due to IgM monoclonal gammopathy: a prospective cohort study. *Neurology* 2010;74:406–12.
- 9 Nasu S, Misawa S, Sekiguchi Y, *et al*. Different neurological and physiological profiles in POEMS syndrome and chronic inflammatory demyelinating polyneuropathy. *J Neurol Neurosurg Psychiatry* 2012;83:476–9.
- 10 Ng PS, Dyck PJ, Laughlin RS, *et al*. Lumbosacral radiculoplexus neuropathy: incidence and the association with diabetes mellitus. *Neurology* 2019;92:e1188–94.