

Available online at [www.sciencedirect.com](http://www.sciencedirect.com)

ScienceDirect

journal homepage: [www.elsevier.com/locate/radcr](http://www.elsevier.com/locate/radcr)

## Case report

# Inferior vena cava filter fracture and migration to the pulmonary artery

Jaehyung Kim, MD\*

Department of Radiology, Sanggye Paik Hospital, Inje University College of Medicine, Seoul, 01757, Republic of Korea

### ARTICLE INFO

#### Article history:

Received 23 January 2021

Revised 30 January 2021

Accepted 31 January 2021

#### Keywords:

IVC filter complication

Filter fracture

Filter strut migration to pulmonary artery

### ABSTRACT

Inferior vena cava (IVC) filters provide a safe and effective method for protecting against pulmonary embolisms in patients for whom standard anticoagulation therapy for acute deep vein thrombosis is contraindicated. Common complications of IVC filter placement include erosion through the wall of the vena cava, visceral perforation, and filter thrombosis, obstruction, and migration. In this report, we describe the case of a 60-year-old woman who presented with an IVC filter fracture and subsequent migration of the filter to the lung detected via chest radiography.

© 2021 The Authors. Published by Elsevier Inc. on behalf of University of Washington.

This is an open access article under the CC BY-NC-ND license (<http://creativecommons.org/licenses/by-nc-nd/4.0/>)

## Introduction

Inferior vena cava (IVC) filters may be considered for patients who experience acute deep vein thrombosis (DVT) and suffer complications with anticoagulation, failure of multiple anticoagulation therapies, or are at high risk of bleeding. Various complications of IVC filter placement have been reported, such as filter strut fracture, filter migration/embolization, IVC or aortic penetration, and thrombotic complications. [1] Herein, we present the case of a 60-year-old woman who presented with an IVC filter fracture and subsequent migration to the lung.

## Case description

A 60-year-old woman with chest wall pain after slipping presented at our hospital. An initial plain chest radiograph showed no bony fracture in the thorax; however, a single linear radio-opaque density was detected in the right lung field (Fig. 1A and B).

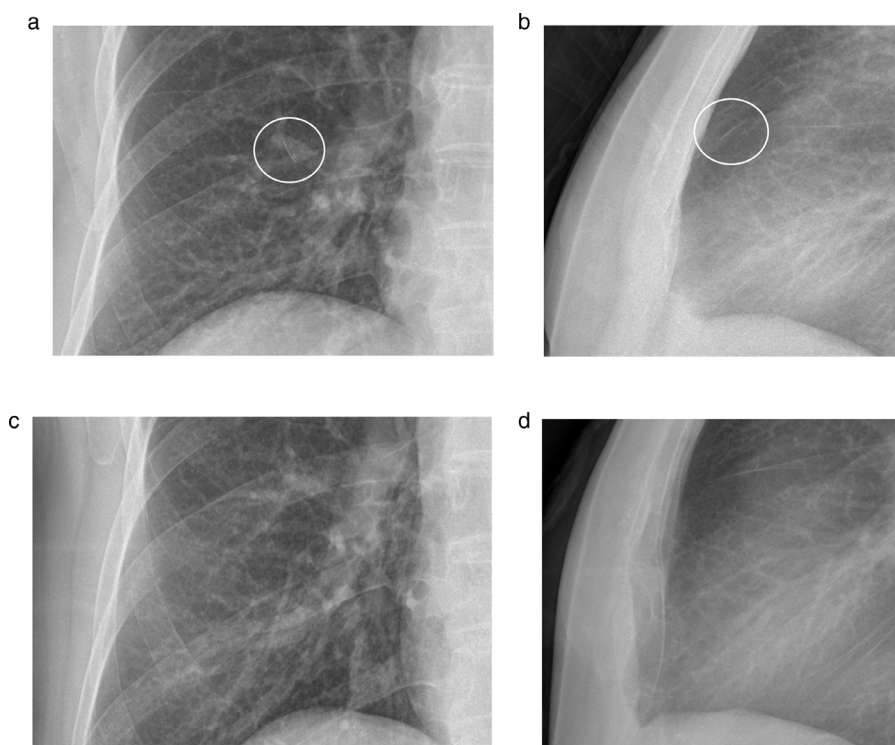
In past history, the patient underwent hysterectomy for a large myoma 8 years previously in our hospital. After the surgery, the patient developed a DVT in her left iliofemoral vein. Catheter-directed thrombolysis could not be performed due to immediate postoperative stage. She underwent IVC

\* Corresponding author.

E-mail address: [kimjaehyung@paik.ac.kr](mailto:kimjaehyung@paik.ac.kr)

<https://doi.org/10.1016/j.radcr.2021.01.061>

1930-0433/© 2021 The Authors. Published by Elsevier Inc. on behalf of University of Washington. This is an open access article under the CC BY-NC-ND license (<http://creativecommons.org/licenses/by-nc-nd/4.0/>)



**Fig. 1 – Plain chest PA (A) and lateral (B) radiographs 8 years after filter placement showing a single linear opacity in the right upper lung field (white circle). Plain chest PA (C) and lateral (D) radiographs 6 years after filter placement showing no abnormal finding in the same region.**

filter insertion to prevent pulmonary embolism (PE). On intraoperative IVC venogram before filter placement, there was no anomaly or injury in the vena cava. The operator selected OptEase filter (OptEase, Cordis, Miami Lakes, FL, USA) and it was placed via the right internal jugular vein using the Seldinger technique. The filter was successfully deployed under the fluoroscopy at the level of second lumbar vertebral body. After filter insertion, there was no evidence of complication. The patient was treated with low molecular weight heparin under careful clinical monitoring. Two weeks later, the patient was discharged after changing of medication to warfarin, but lost to follow-up. Chest radiograph obtained before discharge revealed no abnormality.

Six years after the placement of IVC filter, she presented our emergency department with headache. The plain chest radiograph showed no abnormal finding at that time (Fig. 1C and D). However, on this time, eight years after placement of the IVC filter, a plain chest radiograph showed a linear filter strut projecting over the right hemithorax. She underwent chest CT scan. An axial CT scan of the chest demonstrated a strut fracture in the IVC filter and a migrated fragment of the strut appearing as a bright radio-opaque structure within a branch of the right pulmonary artery (Fig. 2). On the abdominal radiograph, an irregularity or discontinuity of the IVC filter in the right upper quadrant of the abdomen (Fig. 3A) was detected. Three-dimensional reconstruction of the IVC filter demonstrates a more detailed structure of the fractured filter (Fig. 3B). And we add a picture show-

ing a normal structure of the OptEase IVC filter for reference (Fig. 4).

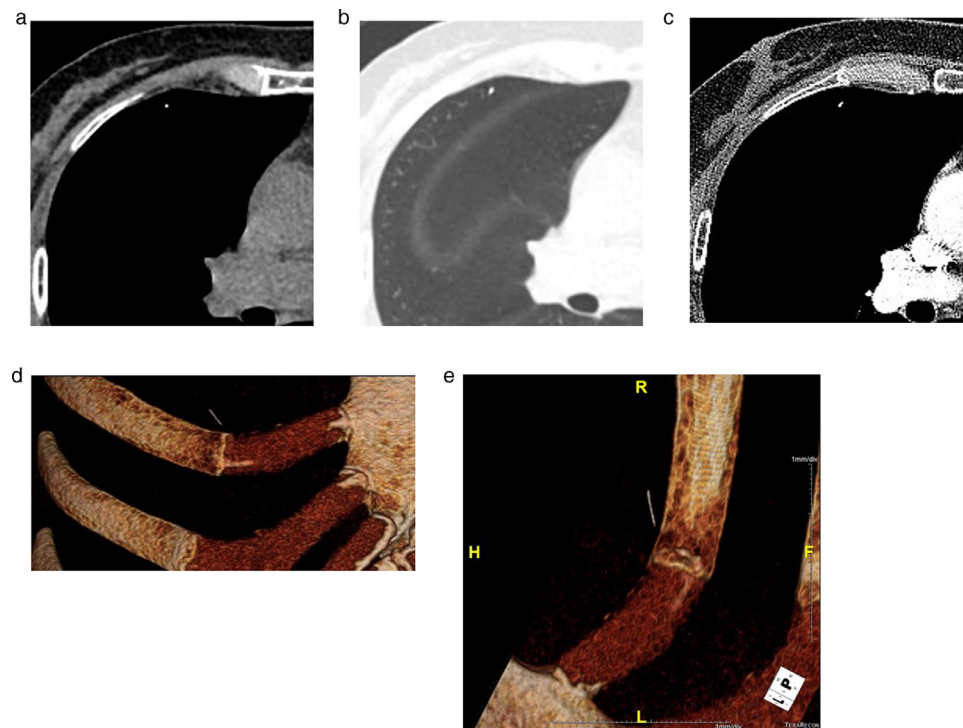
After this workup and conservative management, the patient was discharged without chest pain. No manipulation was attempted on the migrated strut and IVC filter and periodic follow-up was planned.

## Discussion

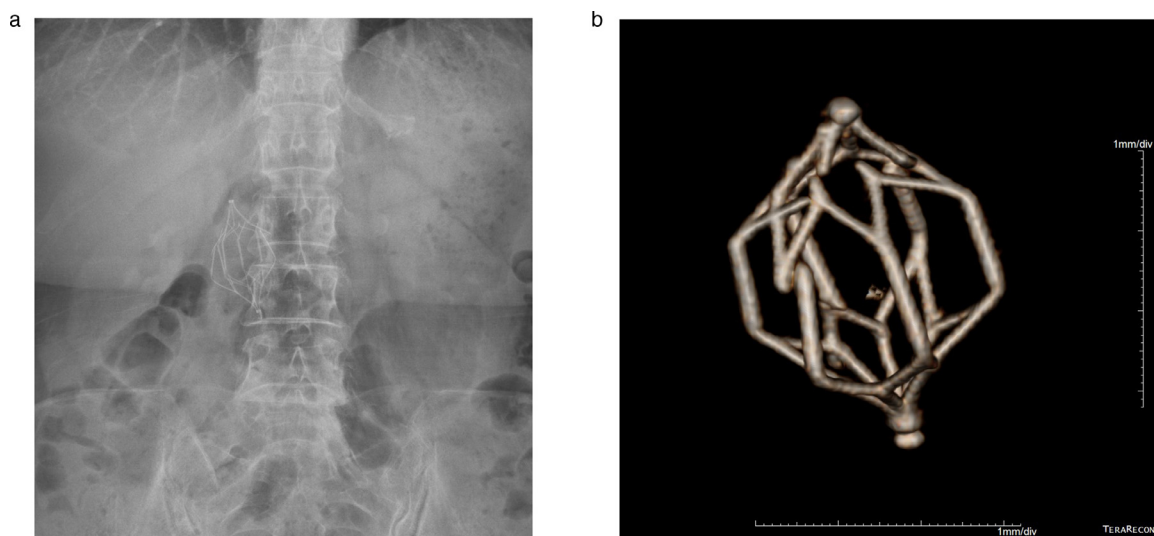
As various IVC filters have been developed, complications related to filter placement have decreased; however, complications can still occur during the vascular approach, deployments, and after procedure. [1] Late complications include IVC thrombosis, filter fracture, filter-induced IVC wall perforation, or recurrent PE. It tends to increase as the indwelling time of the IVC filter increases.

The fracture of filter is caused by metal fatigue. The risk factor of metal fatigue may be related to the tilt of the filter, which is result in continuous stress on the side struts of filter and causes flexion and structural fatigue. [2]

IVC filter strut fracture is rarely reported in the literature, Mitsunaga et al. reported a relatively low incidence of fracture with TrapEase filter (3.8%). [3] According to Ziegler et al., the incidence of filter fracture in OptEase filter was lower than that in other filters (2.0%, 3 of 150 patients). [4] Despite its rare occurrences, fractured filter fragment can reach anywhere in



**Fig. 2** – Precontrast (A), lung window (B), and postcontrast (C) axial CT scans of the chest demonstrating the fractured and migrated IVC filter strut as a bright radiopaque structure within a right pulmonary artery branch. Volume rendering images (D,E) showing a linear radiopaque structure within a right pulmonary artery branch.

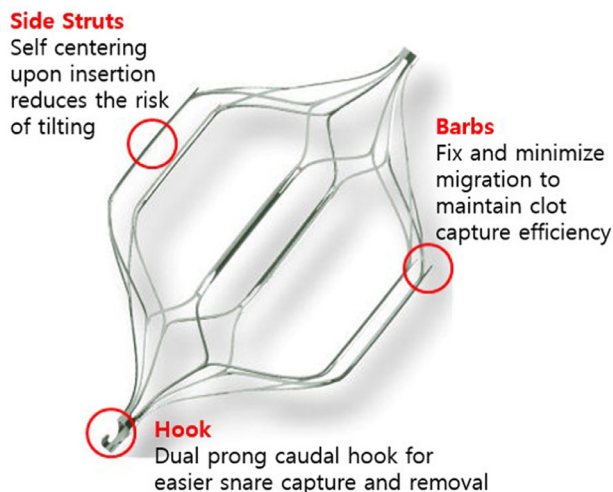


**Fig. 3** – Plain abdomen radiograph (A) and the 3D reconstructed image (B) showing the fractured OptEase IVC filter in the IVC.

the body along the venous flow, it could have fatal results, especially in heart and pulmonary artery. Cases of fracture and embolization of IVC filter strut leading to right ventricle perforation and cardiac tamponade were reported. [3,5] Therefore, early detection of filter complication is important to prevent possible fatal situation that may arise.

Plain radiography of the abdomen is a useful screening test for the detection of changes in filter position, location, orientation, and fracture. However, it is difficult to detect

fractured and migrated IVC filter struts in the thorax on chest radiography and chest CT because the strut fragment is too small to detect and the surrounding enhancing vessels are bright. In this patient, we could only detect linear white opacity in the right lower lung field. In addition, we could assume the possibility of filter fracture based on abdominal radiography. Therefore, radiologists should perform careful review of plain chest radiographs in patients with a history of IVC filter placement. And also, to prevent such long-term complica-



**Fig. 4 – Side view of the OptEase filter demonstrating a symmetrical double-basket design, which consist with the six straight struts engaged the proximal and distal baskets and anchoring barbs at the upper pole of each of the six straight struts.**

tions, removal of retrievable IVC filters should be considered if they are no longer needed.

Since migrated strut in the lung does not seem to cause clinical problems and surgical resection is the only way to remove it in this case, we decide to remain without removal. In the state of partial penetration of IVC filter into the IVC wall due to a long indwelling time and its radial force, and fracture discontinuity of IVC filter, it is difficult to remove the fractured filter percutaneously. And there is no functional problem of

fractured filter without entrapped thrombus, so it would be right to keep the status quo.

In this case report, we describe a case of IVC filter fracture detected on chest radiograph. It is a rare, but potentially fatal, and a difficult to detect condition on radiograph. Thus, radiologists and physicians should be familiar with the characteristic linear opacity in patients with IVC filter placement.

## Informed Consent

Written informed consent was obtained from the patient for publication of this case report.

## REFERENCE

- [1] Grewal S, Chamrathy MR, Kalva SP. Complications of inferior vena cava filters. *Cardiovasc Diagn Ther* 2016;6(6):632–41. doi:10.21037/cdt.2016.09.08.
- [2] Vossen JA, Thawait SK, Golia JS, Chamrathy M, Cholewczynski W, Velasco N. Recurrent fracture of a recovery inferior vena cava filter with pulmonary migration. *Yale j Biol Med* 2012;85(2):255–9.
- [3] Mitsunaga MM, Yoon H. Fracture rate and serious complications of vena cava filters. *Open J Rad* 2013;3(2):85–90. doi:10.4236/ojrad.2013.32013.
- [4] Ziegler JW, Dietrich GJ, Cohen SA, Sterling K, Duncan J, Samotowka M. PROOF trial: protection from pulmonary embolism with the OptEase filter. *J Vasc Interv Radiol* 2008;19(8):1165–70. doi:10.1016/j.jvir.2008.04.020.
- [5] Rogers NA, Nguyen L, Minniefield NE, Jessen ME, de Lemos JA. Fracture and embolization of an inferior vena cava filter strut leading to cardiac tamponade. *Circulation* 2009;119(18):2535–6. doi:10.1161/CIRCULATIONAHA.108.817247.