

Review Article

Surgery as a safe and effective treatment option for sphenoid-orbital meningioma: a systematic review and meta-analysis of surgical techniques and outcomes

Fleur L. Fisher,^{1†} Amir H. Zamanipoor Najafabadi,^{1†} Jan W. Schoones,² Stijn W. Genders^{3,4} and Wouter R. van Furth¹

¹Department of Neurosurgery, Leiden University Medical Center, Leiden, The Netherlands

²Walaeus Library, Leiden University Medical Center, Leiden, The Netherlands

³Department of Ophthalmology, Leiden University Medical Center, Leiden, The Netherlands

⁴Department of Ophthalmology, Amsterdam University Medical Centers, Amsterdam, The Netherlands

ABSTRACT.

Purpose.

The effectiveness and safety of surgery for sphenoid-orbital meningiomas remains subject of debate, as studies often describe different surgical approaches and reconstruction techniques with very heterogeneous outcomes. We aimed to systematically summarize and analyse the literature on sphenoid-orbital meningiomas regarding presenting symptoms, surgical techniques, outcomes and complications.

Methods.

Studies were retrieved from eight databases. Original articles were included if in ≥ 5 patients presenting symptoms, surgical treatment and outcomes were described. Fixed- and random-effects meta-analysis was performed to estimate weighted percentages with 95% CIs of presenting symptoms, outcomes and complications.

Results.

Thirty-eight articles were included describing 1486 patients. Proptosis was the most common presenting symptom (84%; 95% CI 76–91%), followed by unilateral visual acuity deficits (46%; 95% CI 40–51%) and visual field deficits (31%; 95% CI 20–43%). In 35/38 studies (92%), a pterional craniotomy was used. Decompression of the optic canal (82%) and the superior orbital fissure (66%) was most often performed, and usually dural (47%) and bony defects (76%) were reconstructed. In almost all patients, visual acuity (91%; 95% CI 86–96%), visual fields (87%; 95% CI 70–99%) and proptosis (96%; 95% CI 90–100%) improved. Furthermore, surgery showed improvement in 96% (95% CI 78–100%) for both diplopia and ophthalmoplegia. The most common surgical complications were hypesthesia (19%; 95% CI 10–30%), ptosis and diplopia (both 17%; 95% CI, respectively, 10–26% and 5–33%) and ophthalmoplegia (16%; 95% CI 10–24%).

Conclusion.

Patients with sphenoid-orbital meningioma usually present with proptosis or unilateral decreased visual acuity. Surgery shows to be effective in improving visual acuity and visual field deficits with mostly minor and well-tolerated complications.

Key words: cranial nerves – meningioma – neurosurgery – orbit – sphenoid-orbital – vision

We would like to acknowledge Jesse Weeda for his help in the screening of articles for inclusion in this systematic review and meta-analysis.

Acta Ophthalmol. 2021; 99: 26–36

© 2020 The Authors. Acta Ophthalmologica published by John Wiley & Sons Ltd on behalf of Acta Ophthalmologica Scandinavica Foundation

This is an open access article under the terms of the Creative Commons Attribution-NonCommercial-NoDerivs License, which permits use and distribution in any medium, provided the original work is properly cited, the use is non-commercial and no modifications or adaptations are made.

doi: 10.1111/aos.14517

Introduction

Meningiomas are central nervous system tumours, arising from the meninges (Whittle et al. 2004). Spheno-orbital meningiomas (SOM) represent 9–18% of all meningiomas (Cushing & Eisenhardt 1939; Maroon et al. 1994; Mirone et al. 2009; Leroy et al. 2016) and are characterized by substantial hyperostosis of the sphenoid wing with an en-plaque carpet-like soft-tissue component (Li et al. 2009). Due to the complex anatomical location in the anterior skull base and the tendency for invasion of the periorbit, intra-orbital growth, and sometimes the extensive hyperostosis of the optic canal, superior orbital fissure, and other cranial nerve foramina, resection of these tumours is challenging and is associated with possible neurological and visual deficits (Ringel et al. 2007). Due to this growth pattern, the most common presenting symptoms are progressive symptoms of proptosis, unilateral decrease of visual acuity and visual field deficits (Jiranukool et al. 2016). Aim of surgery is to improve or prevent further deterioration of these visual, neurological and cosmetic symptoms.

Studies published on spheno-orbital meningiomas are mostly small series, describing different surgical approaches and reconstruction techniques with very heterogeneous neurological and visual outcomes. As a result, the effectiveness and safety of spheno-orbital surgery, especially regarding visual outcomes, remains subject of debate. Therefore, the aim of this systematic review and meta-analysis was to systematically summarize the literature on used surgical approaches, extent of decompression/resection of hyperostotic bone, management of the periorbit, reconstruction techniques, visual and neurological outcomes, and complications in patients with spheno-orbital meningioma.

Methods

This systematic review and meta-analysis were reported according to the PRISMA criteria (Moher et al. 2009).

Search strategy

PubMed, Embase, Web of Science, COCHRANE Library, Emcare,

PsychINFO, Academic Search Premier and Science direct were searched for relevant literature on 8-2-2018, and the search strategy was updated on 31-7-2019. The search strategy included terms for meningioma, sphenoid wing and spheno-orbital, and derivatives or synonyms of these words. The complete search strategy can be found in the supplements (Table S1).

Inclusion and selection of articles

All articles were screened on title and abstract, and potentially relevant articles were included based on full-text screening (Fig. 1). Original articles were included if at least five SOM patients were included in the study, and if information regarding the presenting symptoms, or surgical treatment or outcomes was reported. Only English articles were included. Studies presenting aggregated information on various pathologies were excluded. Literature reviews were also excluded. In case of multiple articles describing overlapping cohorts, the article with the largest study population was included. In case of articles describing the exact same cohort with the same study size, the most recent article was included. The selection of articles and the data extraction was done by two independent reviewers (A.H.Z.N. and F.L.F.).

Data extraction

The extracted study characteristics consisted of study, patient, tumour and treatment characteristics: the institution, study period, number of patients, age and sex, definition used for hyperostotic SOMs, other tumour location in case of multiple meningioma, WHO grade, SOM tumour diameter, radiological findings of tumour location and invasion, surgical approach, percentage patients who underwent reoperation, extent of decompression and resection of hyperostotic bone, Simpson grade, management of periorbit, reconstruction technique of both the bony and dural defects, previous therapies, and postoperative radiotherapy. The following presenting symptoms and postoperative outcomes were also extracted from the included articles: unspecified visual deficits, visual acuity, visual fields, proptosis, cranial nerve deficits, complications of surgery (specific for SOM

surgery and general surgical complications), progression-free survival, and follow-up length. As there is no commonly accepted terminology for the anatomy, reconstruction material and visual outcomes, multiple different terms could have been used describing the same concepts. Therefore, we combined some of the terms for surgical approach, visual outcomes and reconstruction materials (Table S2).

Risk of bias

The risk of bias assessment for the individual articles was performed using a modified QUIPS (quality of prognostic factors) scale (Hayden et al. 2013), a standard tool of the Cochrane. Included elements in our assessment were patient population (description of study period, consecutive inclusion of patients and description of baseline demographics), clear description of intervention and outcome measurement (comparison of pre- and postoperative outcomes and reporting of reducible percentages), and less than 10% loss to follow-up (Table S3). An overall low risk of bias was given when seven or more points were scored out of a maximum of nine points. Low risk of bias for the separate components was given if the complete amount of points possible was scored.

Analyses

Estimated weighted percentages of presenting symptoms, clinical outcomes (improved/stable versus worsened) and complications were calculated using random-effects ($n \geq 5$ studies) or fixed-effects ($n < 5$ studies) models. Some articles only mentioned improvement of symptoms, and for these studies, only this outcome was pooled. The Freeman–Tukey arcsine transformation was used to prevent exclusion of studies with extreme outcomes (0 or 100%; Nyaga et al. 2014). The I^2 statistic was used for quantification of between-study heterogeneity for analysis with ≥ 5 articles. In case of < 5 studies, no reliable quantification of between-study heterogeneity can be estimated (Higgins et al. 2003; Hippel 2015). Pooled results are reported as percentages with 95% confidence intervals (95% CIs). Subgroup analysis was performed on outcomes and complications of studies using the pterional

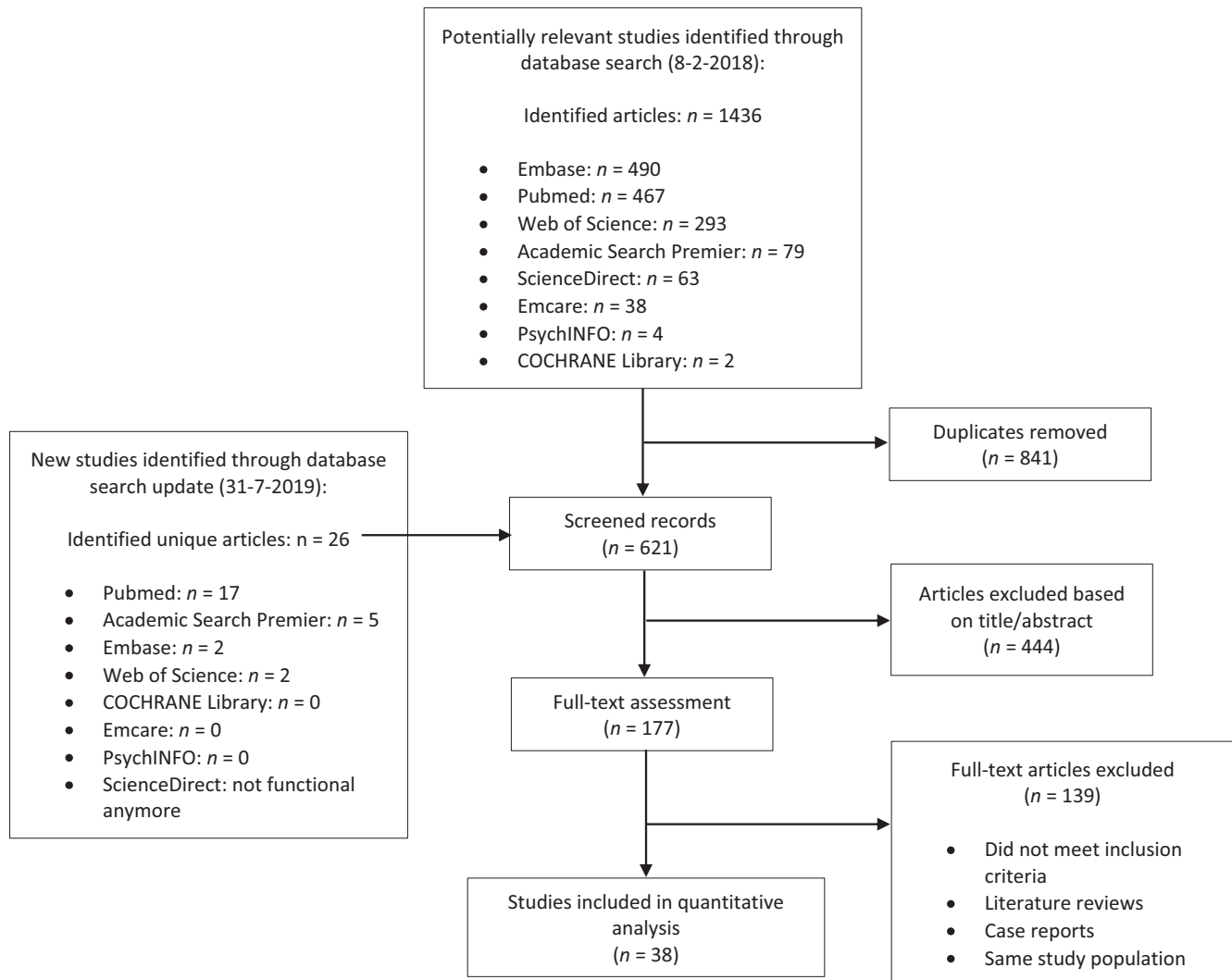


Fig. 1. Flow chart of study selection.

approach in more than 95% of the patients. Analyses were performed with STATA version 14.1 (StataCorp LLC, College Station, TX, USA). Reported information on surgical approaches, extent of resection and reconstruction techniques, including the periorbit, were not analysed through meta-analysis, but systematically summarized and presented. To assess the possible impact in heterogeneity in follow-up lengths and study period, number of operated cases per year and reporting quality, multiple additional subgroup analyses were performed for the main visual outcomes (proptosis, visual field and visual acuity), only including studies (1) with a minimum mean or median follow-up length of ≥ 2 years, (2) published after 2000, and (3) classified as low risk of bias. The cut-off of ≥ 2 years follow-up was based on our

own clinical experience, as deterioration in visual outcomes tend to happen after the first two years after surgery.

Results

A total of 621 unique articles were identified on 18-2-2018, of which 177 were read full text. Of those, 37 articles were included in the study. With the update of the literature search, 26 new unique articles were identified, of which one was included. Eventually, 38 articles were included in this study (Fig. 1) describing 1486 patients. All studies were retrospective cohort studies. The median sample size was 30 patients (range: 6–130) with a follow-up range between 3 and 135 months. For a median of 14% of patients (IQR 3–21%), outcomes were described of a reoperation. For all study characteristics, see Table 1.

Risk of bias individual studies

The scoring of the risk of bias assessment is shown in Table S4. For description of the patient population, 20/38 (53%) of the articles were classified as low risk of bias, for intervention 28/38 (74%), for outcome measurement 35/38 (92%) and for follow-up only 8/38 (21%). A total of 24 studies had an overall low risk of bias (24/38; 63%). For the complete scoring of risk of bias, see Table S4.

Presenting symptoms

Presenting symptoms regarding visual symptoms, cranial nerve palsies and other neurological deficits are depicted in Fig. 2.

The most common presenting symptoms were proptosis (84%; 95% CI 76–91%), unilateral visual acuity

Table 1. Study characteristics.

Name author	Year published	Study period	Study size	Follow-up period (mean)	Age (mean)	Female	Risk of bias	Re-resection (%)
Bonnal	1980	–	21	1–8 years*	–	–	Low	NC
Maroon	1994	1975–1992	15	16–95 months*	46	73%	Low	15 (100)
Gaillard	1996	1981–1993	20	7 years	–	–	High	5 (25)
Honeybul	2001	1991–1998	15	40 months	52	80%	Low	NC
De Jesus	2001	1990–1997	6	4 years	–	100%	High	NC
Shrivastava	2005	1991–2003	25	5 years	51	88%	High	0 (0)
Sandalcioğlu	2005	1988–2002	16	68 months	53	94%	Low	4 (25)
Leake	2005	1995–2002	22	15 months	53	77%	High	3 (14)
Roser	2005	–	82	66 months	52	77%	Low	NC
Schick	2006	1991–2002	67	46 months	58	79%	Low	10 (15)
Ringel	2007	1983–2003	63	54 months	51	79%	Low	9 (14)
Bikmaz	2007	1994–2004	17	36 months	72	88%	High	2 (13)
Mariniello	2008	1983–2003	60	116 months	47	85%	High	NC
Cannon	2009	2000–2007	12	31 months	51	92%	Low	NR
Heufelder	2009	1997–2006	21	67 months	61	–	High	NC
Mirone	2009	1986–2006	71	77 months	53	87%	Low	NC
Scarone	2009	1994–2005	30	61 months	51	100%	Low	0 (0)
Li	2009	1998–2009	37	36 months	46	60%	Low	2 (5)
Saeed	2011	–	66	102 months	46	92%	High	NC
Oya	2011	1994–2009	39	41 months	48	87%	High	6 (15)
Nochez	2012	1986–2006	40	7 months	50	93%	High	NR
Marcus	2013	2004–2012	19	5 years	44	90%	Low	3 (16)
Simas	2013	1998–2008	18	55 months	52	83%	Low	NC
Mariniello	2013	1986–2006	60	5 years	–	–	High	NC
Boari	2013	2000–2010	40	73 months	53	88%	Low	NC
Talacchi	2014	1992–2012	47	52 months	57	55%	Low	NC
Forster	2014	2003–2013	18	40–44 months*	50	100%	Low	2 (11)
Solmaz	2014	2006–2013	13	26 months	34	23%	High	0 (0)
Amirjamshidi	2015	1979–2013	88	135 months	46	65%	High	NC
Leroy	2016	1995–2012	70	57 months	52	92%	Low	0 (0)
Jiranukool	2016	2008–2012	26	52 months	44	96%	Low	0 (0)
Honig	2017	2001–2006	30	18 months	54	73%	High	4 (13)
Freeman	2017	2000–2016	25	45 months	51	92%	Low	7 (28)
Belinsky	2017	2000–2016	38	63 months	56	58%	Low	NR
Peron	2017	2013–2014	30	2 years	46	73%	Low	0 (0)
Gonen	2018	2005–2014	27	41 months	53	89%	Low	2 (7)
Terrier	2018	1996–2016	130	6.4 years	51	92%	Low	19 (14)
Nagahama	2019	1996–2017	12	74.4 months	49	58%	Low	3 (25)

NC = not clear; NR = not reported.

* No mean follow-up period could be calculated.

(VA) (46%; 95%CI 40–51%) and visual field (VF) (31%; 95%CI 20–43%) deficits. Patients suffered from ophthalmoplegia in 22% (95%CI 16–28%) of cases. Patients presented in 9% (95%CI 5–15%) of the cases with cognitive/neurological complaints, like mental change, concentration problems and memory problems. Seizures were reported as the first symptom in 4% (95%CI 2–7%) of the patients.

Surgical approach

Different surgical approaches were used to resect speno-orbital meningiomas. The (extended) pterional approach was the most used approach as used in 37 of 38 studies (97%). For a

schematic representation of the (extended) pterional approach, see Fig. 3. The surgeon's view after a pterional approach on the sphenoid bone is shown in Fig. 4. One article did not mention their surgical approach (2%). In 2008, the first approach other than pterional was described, the lateral orbitotomy. Since a few years, endoscopic resection in selected SOM patients is also performed and is described in three articles (3/38; 8%). For the complete table of surgical approaches, see Table S5.

Decompression/resection of hyperostotic bone

The extent of decompression or resection of hyperostotic bone per

article is shown in Fig. 5. The most frequently decompressed structure was the optic canal (31/38; 82%), followed by decompression of the superior orbital fissure (SOF, 25/38; 66%) and resection of the anterior clinoid process (ACP, 22/28; 58%) and the lateral orbital wall (21/38; 55%). There was no trend over the years in the extent of decompression or resection of hyperostotic bone (see Table S6).

Reconstruction

The most used reconstruction materials for dural defects were fascial grafts (7/38; 18%) and pericranium (6/38; 16%). The most used reconstruction materials for bony defects were titanium mesh

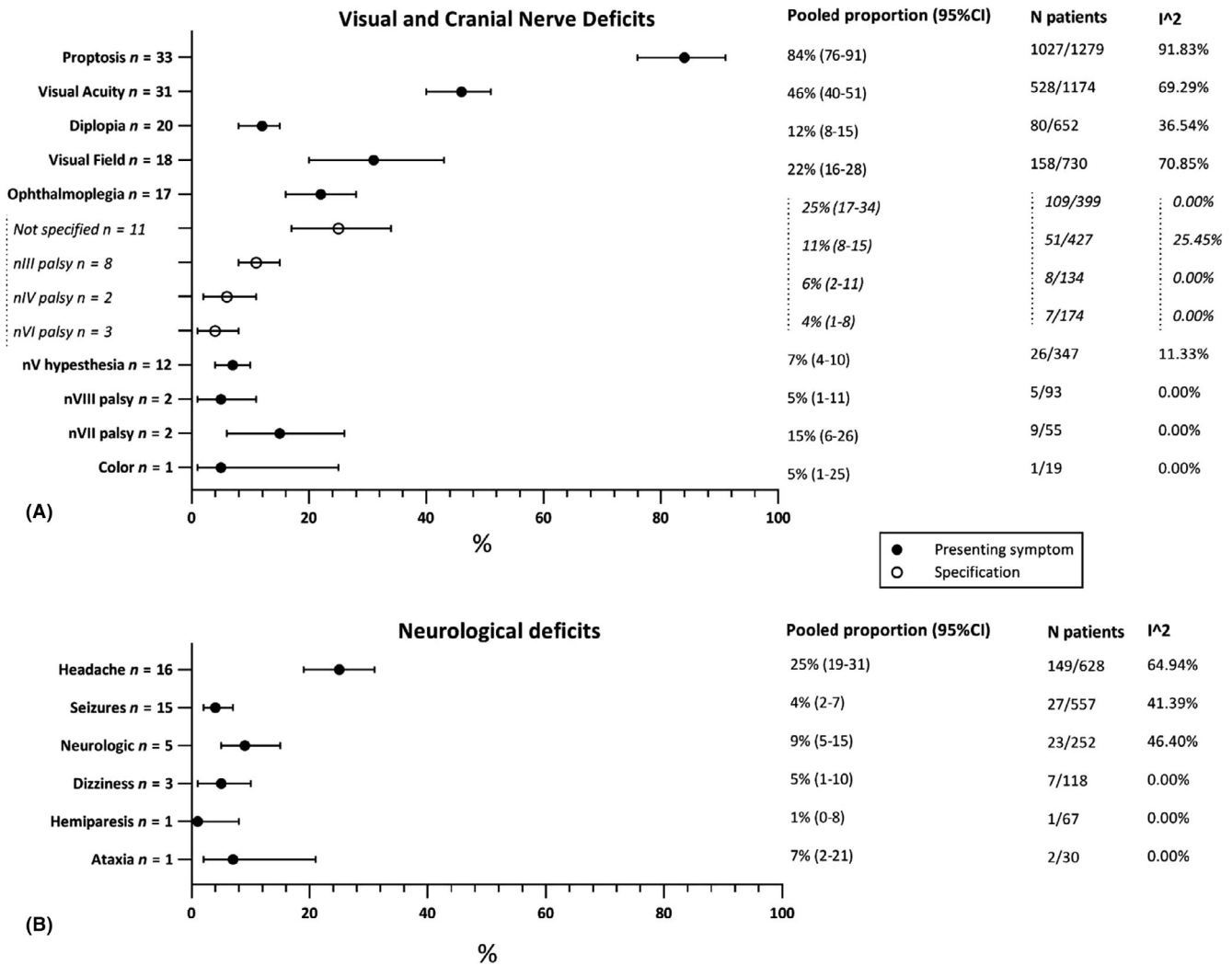


Fig. 2. Presenting symptoms: (A) visual and cranial nerve deficits; (B) other neurological deficits.

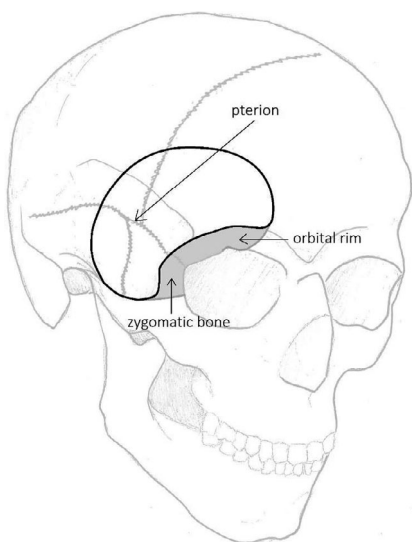


Fig. 3. Schematic presentation of the (extended) pterional approach [Inline Image Removed1] Pterional approach; [Inline Image Removed2] Extension of the pterional approach (orbitozygomatic).

(14/38; 37%), inner calvarial table grafts (11/38; 29%) and polymethylmethacrylate (10/38; 26%) (Fig. 6). Abdominal fat was used to fill up the remaining cavity in eight articles (9/38; 24%). In Table S7, the usage of reconstruction materials over time is presented. Regarding dural defect reconstruction, in recent years more artificial dural reconstruction materials were used.

Periorbit

In 22/38 articles (58%), infiltrated periorbit was resected in some cases. Eleven articles (11/38; 29%) reported they (sometimes) opened the periorbit (Fig. 7). It was maintained in only two of 38 articles (5%). Nine articles did not mention their management of the periorbit (24%). In Table S8, it is shown that resection of the periorbit has been performed from the early days

on. Only opening the periorbit was first reported in 2005 by Schick et al. (2006).

Clinical outcomes

For clinical outcomes, see Fig. 8. Surgery improved diplopia in 96% of patients (95%CI 78–100%). Ophthalmoplegia was improved in 96% (95%CI 78–100%). Visual acuity deficits improved in 91% of the cases (95%CI 86–96%) and visual field deficits in 87% (95%CI 70–99%). In 96% (95%CI 90–100%), proptosis improved.

In subgroup analysis only including studies using the (extended) pterional approach (Fig. S1), diplopia improved in 94% of the cases (95%CI 73–100%). In 93% (95%CI 69–100%), ophthalmoplegia improved. Existing visual acuity deficits improved in 91% (95%CI 86–95%) and visual field deficits in

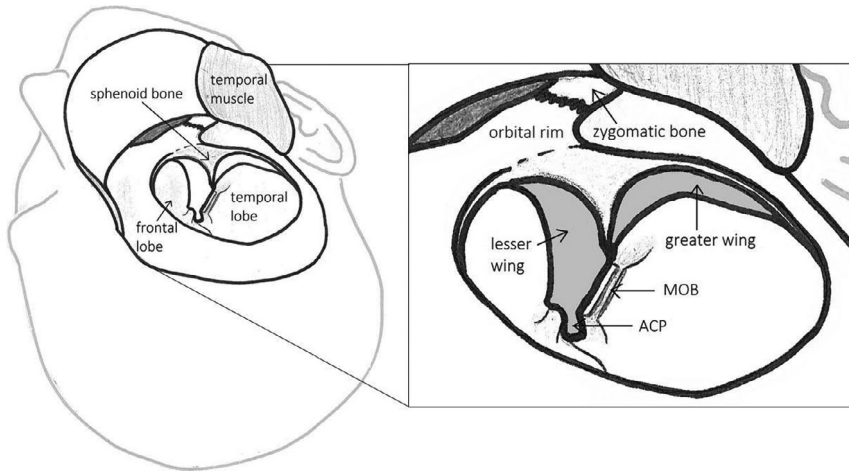


Fig. 4. Surgeon's view of the pterional approach after development of skin-muscle flap, detaching of part of the temporal muscle and craniotomy. ACP = anterior clinoid process; MOB = meningo-orbital band.

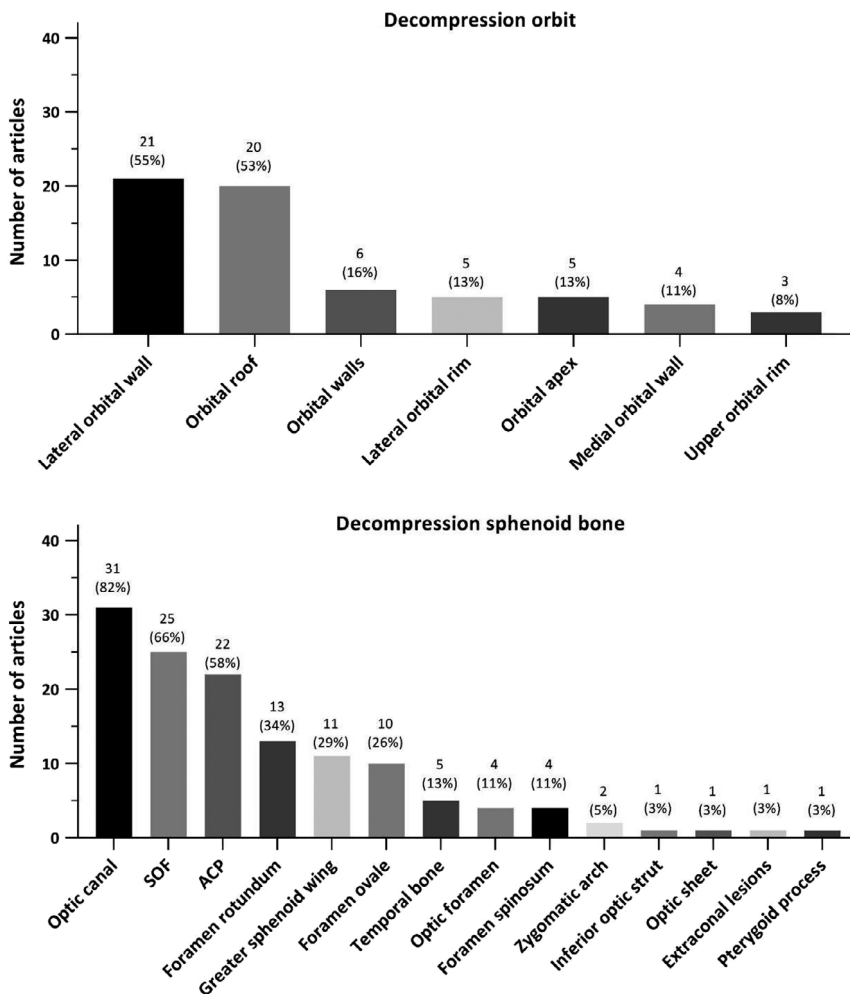


Fig. 5. (A) Decompression/resection of the orbit; (B) decompression/resection of the sphenoid bone. In these graphs, no distinction was made in whether decompression of the different structures was always performed or only in selected patients. The percentages represent the fraction of total articles, which performed decompression/resection of the different structures.

84% (95%CI 60–99%) of patients. Proptosis improved in 96% of the patients (95%CI 89–100%).

Outcomes of sensitivity analysis only including articles published after 2000, with a follow-up ≥ 2 years, and scored

with a low risk of bias were overall similar to the main analysis (Figs S2–S4).

Complications

Hypesthesia of CN V is the most common complication with an occurrence of 19% (95%CI 10–30%), followed by ptosis (17%; 95%CI 10–26%), unspecified CN deficit (17%; 95%CI 11–25%), diplopia (17%; 95%CI 5–33%) and ophthalmoplegia (16%; 95%CI 10–24%). Complications regarding visual acuity and visual field occurred in respectively 9% (95%CI 2–18%) and 4% (95%CI 1–8%) of the patients (see Fig. 9).

In subgroup analysis only including studies using the (extended) pterional approach, unspecified CN deficits occur most as a complication in 23% of patients (95%CI 14–32%), followed by ophthalmoplegia (20%; 95%CI 13–29%) and diplopia (17%; 95%CI 5–33%), ptosis (17%; 95%CI 8–28) and CN V hypesthesia (15%; 95%CI 8–24%). Complications regarding visual acuity and visual field in this group occurred in respectively 5% (95%CI 1–10%) and 4% (95%CI 1–8%) of the cases (Fig. S5).

For a table of comparison of the complete analysis and subgroup analysis, regarding clinical outcomes and complications, see Table S9.

Discussion

Resection of spheno-orbital meningioma is a safe and effective therapeutic option, as it results in excellent improvement of visual and neurological symptoms with low complication rates. Therefore, it is stimulated and advised to refer these patients for surgery to prevent further progression of their presenting visual and neurological symptoms. Over the years, there is no clear trend in change of surgical approach and reconstruction technique, except for opening of the periorbit instead of periorbit resection and the use of endoscopic and multiportal approaches in recent years for selected cases.

Surgical decompression and resection

While different surgical approaches are possible for SOMs, the aim of surgery should always be a maximum safe resection with improvement or

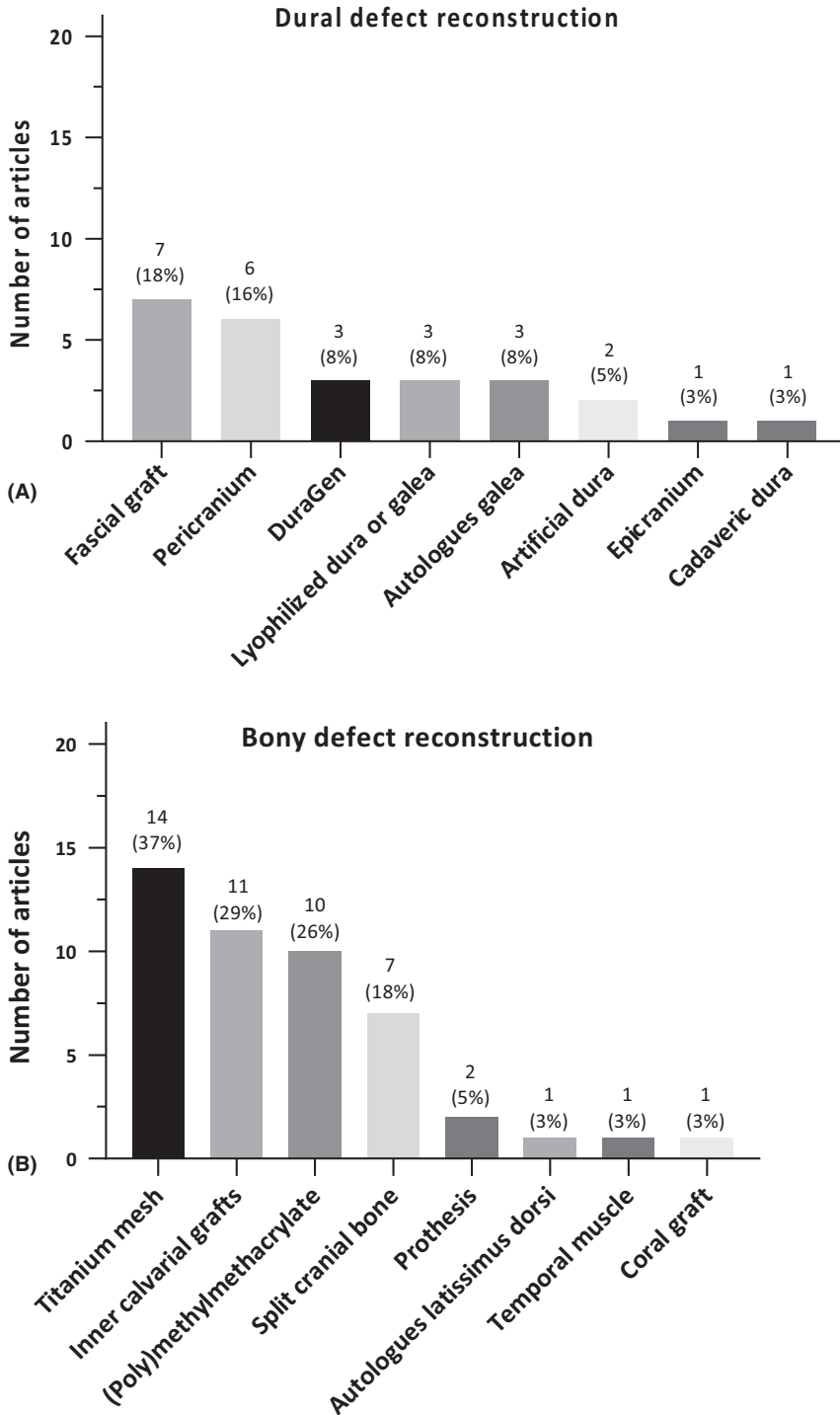


Fig. 6. (A) Reconstruction materials for dural defects; (B) reconstruction materials for bony defects. The percentages represent the part of the total articles, which performed this decompression/resection. The numbers given next to the bullets, represent the number of articles using this reconstruction material in this year.

retainment of patient’s HRQoL (Zamanipoor Najafabadi et al. 2017). Maximum safe decompression and resection of hyperostotic bone should be performed to improve presenting visual deficits or to prevent further deterioration, while minimizing the risk for complications such as development

of new cranial nerve deficits, possibly leading to an impaired HRQoL (Mirone et al. 2009; Gonen et al. 2018). Nevertheless, subtotal resection of affected bone increases the risk for recurrence and the possible need for second operation or radiotherapy with its potential risks. In addition, recent

PET-CT studies reported presence of pathological hyperostotic cells in areas not identified by surgeons, supporting the need for a maximum resection (Kunz et al. 2017).

There is especially strong evidence for the safety and effectiveness of the pterional approach. The pterional approach is specifically a useful approach, as it enables access to the middle cranial fossa, anterior cranial fossa and the orbit through one approach. Recently, transorbital approaches have been reported, primarily for decompression of hyperostotic bone for optimal cosmetic results and in combination with other approaches (i.e. multiportal approaches including transnasal approach) for optimal multi-angle surgical resection and decompression of hyperostotic bone (Zimmer & Theodosopoulos 2009; Dallan et al. 2015).

Reconstruction techniques

The primary goal of reconstruction of the orbital walls is to prevent enophthalmos, especially pulsatile enophthalmos, which after reconstruction occurs between 2,3% and 30,0% of patients (Gaillard et al. 1997; Honeybul et al. 2001; Bikmaz et al. 2007; Ringel et al. 2007; Mirone et al. 2009; Saeed et al. 2011; Amirjamshidi et al. 2015; Terrier et al. 2018). Reconstruction of dural defects is done to prevent CSF leaks, and reduce the risk of wound infection and meningitis (Talacchi et al. 2014; Leroy et al. 2016), which after reconstruction occurs in respectively 5%, 3% and 6% of patients. The periorbit can be opened or removed to gain access to intra-orbital tumour extension. However, possible complications for intra-orbital tumour resection are ophthalmoplegia (Maroon et al. 1994). Therefore, in the majority of cases the periorbit is only resected/opened when invaded. In these cases, resection of periorbit may be necessary to minimize the risk of recurrence and get significant proptosis reduction. Terrier et al also suggested that there is a correlation between opening the periorbita and the reduction of proptosis after surgery (Terrier et al. 2018).

Clinical outcomes, complications and predictors of outcomes

Results of this meta-analysis show strong evidence for improvement of

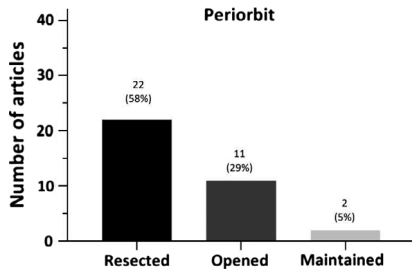


Fig. 7. Management of the periorbit.

most symptoms, especially proptosis and cranial nerve deficits which improved in almost all patients, but also visual acuity and visual field deficits which improved respectively in 91% and 87% of patients. While ophthalmoplegia is one of the most occurring complications in approximately 16%, almost all patients with ophthalmoplegia as a presenting symptom showed improvement (96%). Accordingly, the presence

of these symptoms and the aim to improve these symptoms seem a proper indication for surgery. There is no clear evidence in literature on the effect of timing of surgery on visual and neurological outcomes. However, Bikmaz et al. reports that surgery in an early stage will stabilize the condition of the patient, with a small risk for permanent visual complications (Bikmaz et al. 2007).

There are several predictors for postoperative visual outcomes, which should be taken into account during surgical decision-making. Invasion of the optic canal is a negative predictor for both postoperative visual acuity and visual field deficits. Extension into the periorbit is a negative predictor for postoperative visual acuity, and intracranial soft-tissue component for postoperative visual field (Yannick et al. 2012; Forster et al. 2014). Excision of the

periorbit seems to have a positive effect on the reduction of proptosis, while radiological involvement of the optic canal is a predictor for residual postoperative proptosis (Yannick et al. 2012; Terrier et al. 2018).

Strengths and limitations of this study

This is the first systematic review and meta-analysis systematically evaluating surgical aspects and clinical outcomes of SOM patients. While we performed an extensive and systematic literature search, there were no studies reporting results separately for other approaches than the pterional approach, and therefore, we could not compare outcomes of different surgical approaches. However, our systematic review showed that the pterional approach is the most used approach and sound analysis could be conducted to present

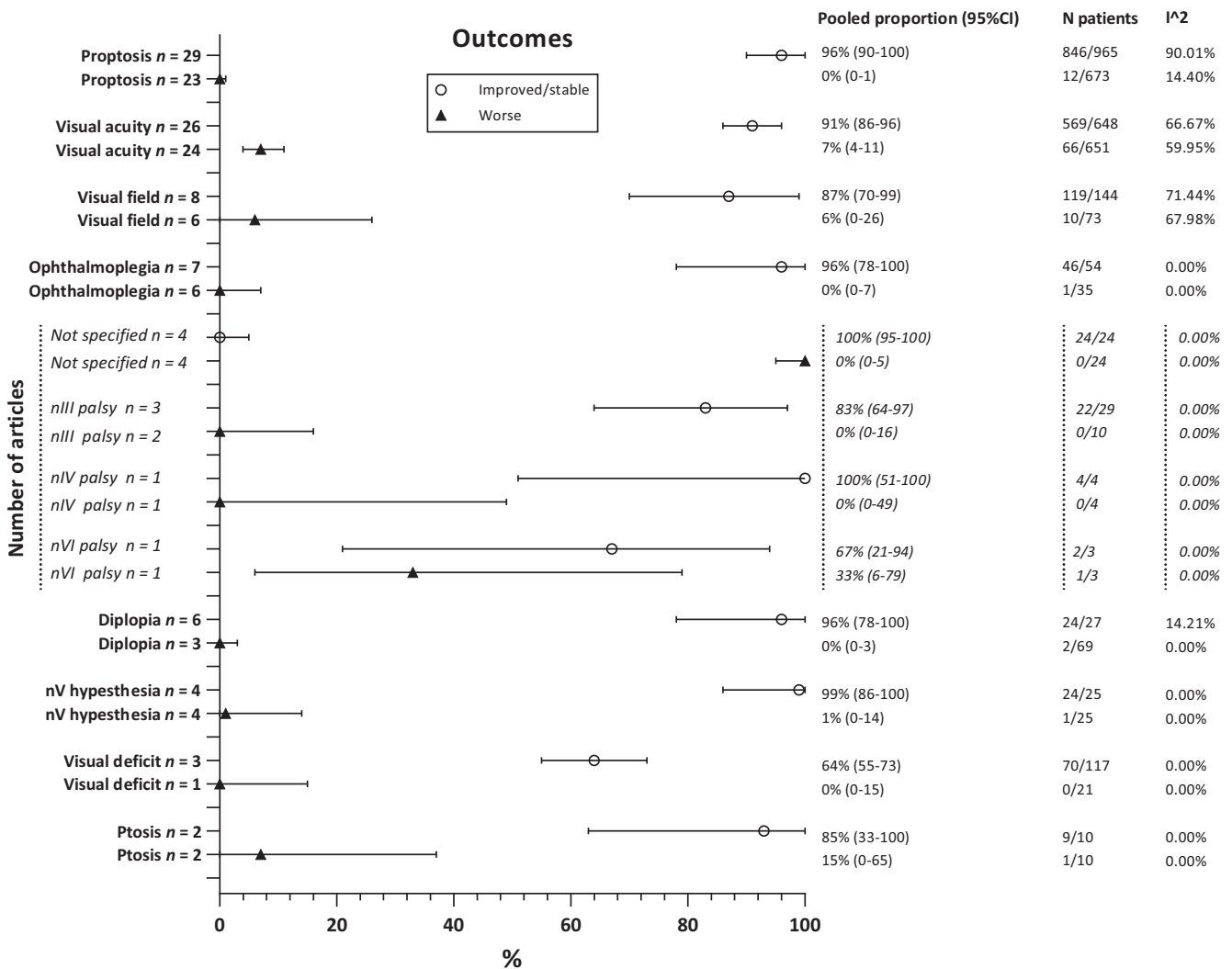


Fig. 8. Overall clinical outcomes.

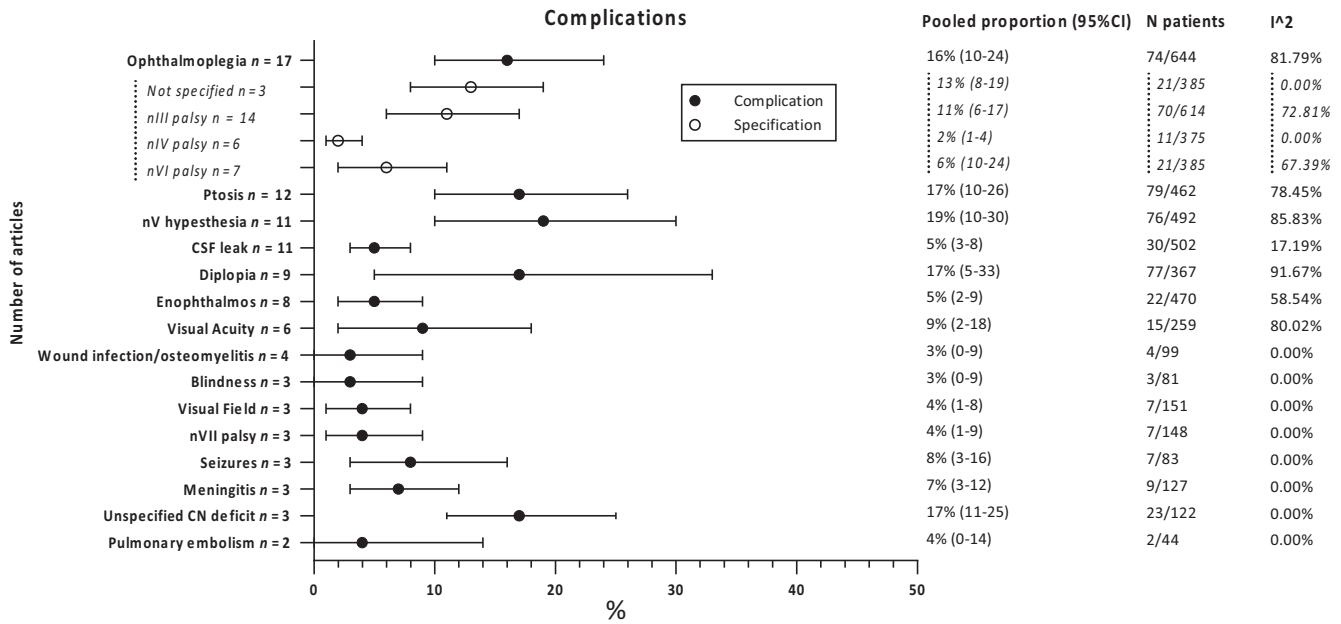


Fig. 9. Overall complications.

outcomes for this approach. In addition, the articles described heterogeneous case series regarding extent of resection and decompression, reconstruction techniques, and management of the periorbit, which therefore could not be analysed separately. Also, it was not possible to distinguish between transient and permanent complications and between transient and permanent improvements of signs and symptoms, because not all articles specified this in their results. Similarly, it was not possible to estimate outcomes separately for patients who underwent a first operation or reoperation. Similarly, most articles did not report separate percentages for patients with improved and normalized symptoms. Nevertheless, we could assess whether over the years there was a trend of change in these surgical aspects. Although multiple subgroup analyses were performed to assess the impact of between-study heterogeneity, which added to the robustness of the reported results, we were not able to perform additional analyses to assess the impact of important prognostic variables, such as tumour size, degree of hyperostosis and comorbidities, as these variables were scarcely reported in the included studies. International collaboration is needed to harmonize data collection and increase patient numbers of clinical studies to assess the impact of

important prognostic variables on surgical outcomes.

Implications and future perspective

This systematic review and meta-analysis showed that there is firm evidence that surgery, especially the pterional approach, is a rather safe and effective treatment option for sphenoidal meningioma patients presenting with visual or neurological deficits. While complications occur frequently, up to one in five patients, they are minor and well tolerated. We therefore encourage ophthalmologist to refer these patients for surgery. Over the last 40 years, no consensus emerged in the details of surgery; still a large variety is reported in the extent of resection or decompression of hyperostotic bone, management of the periorbit, and dural and bone reconstruction techniques. Also, the role of radiotherapy has not been clarified yet. The preferred surgical techniques and treatment strategies can therefore not yet be determined. Future studies are needed to assess how sphenoidal meningioma surgery can be optimized regarding these topics. As there is paucity in HRQoL data, these studies should not only focus on conventional outcomes, but also patient-reported outcomes (Zamanipoor Najafabadi et al. 2017).

References

Amirjamshidi A, Abbasioun K, Amiri RS, Ardalan A & Hashemi SM (2015): Lateral orbitotomy approach for removing hyperostosing en plaque sphenoid wing meningiomas. Description of surgical strategy and analysis of findings in a series of 88 patients with long-term follow up. *Surg Neurol Int* **6**: 79.

Belinsky I, Murchison AP, Evans JJ et al. (2018): Spheno-orbital meningiomas: an analysis based on World Health Organization classification and Ki-67 proliferative index. *Ophthalmic Plast Reconstr Surg* **34**: 143–150.

Bikmaz K, Mrak R & Al-Mefty O (2007): Management of bone-invasive, hyperostotic sphenoid wing meningiomas. *J Neurosurg* **107**: 905–912.

Boari N, Gagliardi F, Spina A, Bailo M, Franzin A & Mortini P (2013): Management of spheno-orbital en plaque meningiomas: clinical outcome in a consecutive series of 40 patients. *Br J Neurosurg* **27**: 84–90.

Bonnal J, Thibaut A, Brotchi J & Born J (1980): Invading meningiomas of the sphenoid ridge. *J Neurosurg* **53**: 587–599.

Cannon PS, Rutherford SA, Richardson PL, King A & Leatherbarrow B (2009): The surgical management and outcomes for spheno-orbital meningiomas: a 7-year review of multi-disciplinary practice. *Orbit* **28**: 371–376.

Cushing H & Eisenhardt L (1939): Meningiomas: Their classification, regional behaviour, life history, and surgical end results. *JAMA* **112**: 175.

Dallan I, Castelnovo P, Locatelli D, Turri-Zanoni M, AlQahtani A, Battaglia P, Hirt B

- & Sellari-Franceschini S (2015): Multiportal combined transorbital transnasal endoscopic approach for the management of selected skull base lesions: preliminary experience. *World Neurosurg* **84**: 97–107.
- De Jesús O & Toledo MM (2001): Surgical management of meningioma en plaque of the sphenoid ridge. *Surg Neurol* **55**: 265–269.
- Forster MT, Daneshvar K, Senft C, Seifert V & Marquardt G (2014): Sphenoorbital meningiomas: surgical management and outcome. *Neurol Res* **36**: 695–700.
- Freeman JL, Davern MS, Oushy S, Sillau S, Ormond DR, Youssef AS & Lillehei KO (2017): Spheno-orbital meningiomas: a 16-year surgical experience. *World Neurosurg* **99**: 369–380.
- Gaillard S, Pellerin P, Dhellemmes P, Pertuzon B, Lejeune JP & Christiaens JL (1997): Strategy of craniofacial reconstruction after resection of spheno-orbital “en plaque” meningiomas. *Plast Reconstr Surg* **100**: 1113–1120.
- Gonen L, Nov E, Shimony N, Shofty B & Margalit N (2018): Sphenoorbital meningioma: surgical series and design of an intraoperative management algorithm. *Neurosurg Rev* **41**: 291–301.
- Hayden JA, van der Windt DA, Cartwright JL, Côté P & Bombardier C (2013): Assessing bias in studies of prognostic factors. *Ann Intern Med* **158**: 280–286.
- Heufelder MJ, Sterker I, Trantakis C, Schneider JP, Meixensberger J, Hemprich A & Frerich B (2009): Reconstructive and ophthalmologic outcomes following resection of spheno-orbital meningiomas. *Ophthalmic Plast Reconstr Surg* **25**: 223–226.
- Higgins JP, Thompson SG, Deeks JJ & Altman DG (2003): Measuring inconsistency in meta-analyses. *BMJ* **327**: 557–560.
- von Hippel PT (2015): The heterogeneity statistic I^2 can be biased in small meta-analyses. *BMC Med Res Methodol* **15**: 35.
- Honeybul S, Neil-Dwyer G, Lang DA, Evans BT & Ellison DW (2001): Sphenoid wing meningioma en plaque: a clinical review. *Acta Neurochir (Wien)* **143**: 749–757; discussion 758.
- Honig S, Trantakis C, Frerich B, Sterker I, Schober R & Meixensberger J (2010): Spheno-orbital meningiomas: outcome after microsurgical treatment: a clinical review of 30 cases. *Neurol Res* **32**: 314–325.
- Jiranukool J, Iampreechakul P, Dhanachai M & Tirakotai W (2016): Outcomes of surgical treatment and radiation therapy in en plaque sphenoid wing meningioma. *J Med Assoc Thai* **99**(Suppl 3): S54–S61.
- Kunz WG, Jungblut LM, Kazmierczak PM et al. (2017): Improved detection of transosseous meningiomas using 68Ga-DOTA-TATE PET/CT compared with contrast-enhanced MRI. *J Nucl Med* **58**: 1580–1587.
- Leake D, Gunnlaugsson C, Urban J & Marentette L (2005): Reconstruction after resection of sphenoid wing meningiomas. *Arch Facial Plast Surg* **7**: 99–103.
- Leroy HA, Leroy-Ciocanea CI, Baroncini M, Bourgeois P, Labreuche J, Duhamel A & Lejeune JP (2016): Internal and external spheno-orbital meningioma varieties: different outcomes and prognoses. *Acta Neurochir (Wien)*. **158**: 1587–1596.
- Li Y, Shi JT, An YZ, Zhang TM, Fu JD, Zhang JL & Zhao JZ (2009): Sphenoid wing meningioma en plaque: report of 37 cases. *Chin Med J (Engl)*. **122**(20): 2423–2427.
- Marcus H, Schwindack C, Santarius T, Mannion R & Kirollos R (2013): Image-guided resection of spheno-orbital skull-base meningiomas with predominant intraosseous component. *Acta Neurochir (Wien)* **155**: 981–988.
- Mariniello G, Maiuri F, Strianese D, Donzelli R, Juliano A, Tranfa F, de Divitiis E & Bonavolantà G (2008): Spheno-orbital meningiomas: surgical approaches and outcome according to the intraorbital tumor extent. *Zentralbl Neurochir* **69**: 175–181.
- Mariniello G, Bonavolantà G, Tranfa F & Maiuri F (2013): Management of the optic canal invasion and visual outcome in spheno-orbital meningiomas. *Clin Neurol Neurosurg* **115**: 1615–1620.
- Maroon JC, Kennerdell JS, Vidovich DV, Abla A & Sternau L (1994): Recurrent spheno-orbital meningioma. *J Neurosurg* **80**: 202–208.
- Mirone G, Chibbaro S, Schiabello L, Tola S & George B. (2009): En plaque sphenoid wing meningiomas: recurrence factors and surgical strategy in a series of 71 patients. *Neurosurgery* **65**(6 Suppl): 100–108; discussion 108–109.
- Moher D, Liberati A, Tetzlaff J & Altman DG (2009): Preferred reporting items for systematic reviews and meta-analyses: the PRISMA statement. *J Clin Epidemiol* **62** (10): 1006–1012.
- Nagahama A, Goto T, Nagm A et al. (2019): Spheno-orbital meningioma: surgical outcomes and management of recurrence. *World Neurosurg* **126**: e679–e687.
- Nyaga VN, Arbyn M & Aerts M (2014): Metaprop: a Stata command to perform meta-analysis of binomial data. *Arch Public Health* **72**: 39.
- Oya S, Sade B & Lee JH (2011): Sphenoorbital meningioma: surgical technique and outcome. *J Neurosurg* **114**: 1241–1249.
- Peron S, Cividini A, Santi L, Galante N, Castelnovo P & Locatelli D (2017): Spheno-orbital meningiomas: when the endoscopic approach is better. *Acta Neurochir Suppl* **124**: 123–128.
- Ringel F, Cedzich C & Schramm J. (2007): Microsurgical technique and results of a series of 63 spheno-orbital meningiomas. *Neurosurgery* **60**(4 Suppl 2): 214–221; discussion 221–222.
- Roser F, Nakamura M, Jacobs C, Vorkapic P & Samii M (2005): Sphenoid wing meningiomas with osseous involvement. *Surg Neurol* **64**: 37–43; discussion 43.
- Saeed P, van Furth WR, Tanck M, Freling N, van der Sprenkel JW, Stalpers LJ, van Overbeeke JJ & Mourits MP (2011): Surgical treatment of sphenoorbital meningiomas. *Br J Ophthalmol* **95**: 996–1000.
- Sandalcioglu IE, Gasser T, Mohr C, Stolke D & Wiedemayer H (2005): Spheno-orbital meningiomas: interdisciplinary surgical approach, resectability and long-term results. *J Craniomaxillofac Surg* **33**: 260–266.
- Scarone P, Leclercq D, Hérain F & Robert G (2009): Long-term results with exophthalmos in a surgical series of 30 sphenoorbital meningiomas. Clinical article. *J Neurosurg* **111**: 1069–1077.
- Schick U, Bleyen J, Bani A & Hassler W (2006): Management of meningiomas en plaque of the sphenoid wing. *J Neurosurg* **104**: 208–214.
- Shapey J, Jung J, Barkas K, Gullan R, Barazi S, Bentley R, Huppa C & Thomas NW (2019): A single centre’s experience of managing spheno-orbital meningiomas: lessons for recurrent tumour surgery. *Acta Neurochir (Wien)* **161**: 1657–1667.
- Shrivastava RK, Sen C, Costantino PD & Della Rocca R (2005): Sphenoorbital meningiomas: surgical limitations and lessons learned in their long-term management. *J Neurosurg* **103**: 491–497.
- Simas NM & Farias JP (2013): Sphenoid Wing en plaque meningiomas: surgical results and recurrence rates. *Surg Neurol Int* **4**: 86.
- Solmaz I, Tehli O, Temiz C, Kural C, Hodaj I, Kutlay M, Gonul E & Daneyemez MK (2014): Surgical strategies for the removal of sphenoorbital meningiomas. *Turk Neurosurg* **24**: 859–866.
- Talacchi A, De Carlo A, D’Agostino A & Nocini P (2014): Surgical management of ocular symptoms in spheno-orbital meningiomas. Is orbital reconstruction really necessary? *Neurosurg Rev* **37**: 301–309; discussion 309–310.
- Terrier LM, Bernard F, Fournier HD, Morandi X, Velut S, Hénaux PL, Amelot A & François P (2018): Spheno-orbital meningiomas surgery: multicenter management study for complex extensive tumors. *World Neurosurg* **112**: e145–e156.
- Whittle IR, Smith C, Navoo P & Collie D (2004): Meningiomas. *Lancet* **363**: 1535–1543.
- Yannick N, Patrick F, Samuel M, Erwan F, Pierre-Jean P, Michel J & Stéphane V (2012): Predictive factors for visual outcome after resection of spheno-orbital meningiomas: a long-term review. *Acta Ophthalmol* **90**: e663–e665.
- Zamanipoor Najafabadi AH, Peeters MCM, Dirnel L et al. (2017): Impaired health-related quality of life in meningioma patients—a systematic review. *Neuro Oncol* **19**: 897–907.
- Zamanipoor Najafabadi AH, Peeters MCM, Lobatto DJ et al. (2017): Health-related quality of life of cranial WHO grade I meningioma patients: are current questionnaires relevant? *Acta Neurochir (Wien)* **159**: 2149–2159.
- Zimmer LA & Theodosopoulos PV (2009): Anterior skull base surgery: open versus

endoscopic. *Curr Opin Otolaryngol Head Neck Surg* 17: 75–78.

Received on January 7th, 2020.
Accepted on May 26th, 2020.

Correspondence:

Stijn W. Genders, MD
Department of Ophthalmology
Leiden University Medical Center
postal zone J3-S, Albinusdreef 2
2333ZA Leiden
The Netherlands
Tel: +31 (0)71 5262374
Fax: +31 (0)71 5248222
Email: s.w.genders@lumc.nl

†These authors contributed equally to this work.

We would like to acknowledge Jesse Weeda for his help in the screening of articles for inclusion in this systematic review and meta-analysis.

Supporting Information

Additional Supporting Information may be found in the online version of this article:

Figure S1. Outcomes subgroup (pterional + extended approach).

Figure S2. Sensitivity analysis only including articles published after 2000.

Figure S3. Sensitivity analysis only including articles with a follow-up ≥ 2 years.

Figure S4. Sensitivity analysis only including article scores with a low risk of bias.

Figure S5. Complications subgroup (pterional + extended approach).

Table S1. Search strategies used for the systematic review.

Table S2. Combined terms (surgical approaches, presenting symptoms and reconstruction materials).

Table S3. Description of risk of bias assessment.

Table S4. Risk of bias assessment.

Table S5. Surgical approach of included studies, presented per year of publication.

Table S6. Decompression/resection over time.

Table S7. Reconstruction materials over time.

Table S8. Management of the periorbit over time.

Table S9. Improved outcomes and complications of the whole patient population and of the subgroup (pterional + extended approach).